

# Management of Malignant Meningiomas

Danijela Levačić, David Nochlin, Thomas Steineke and Joseph C. Landolfi  
*JFK Brain Tumor Center, New Jersey Neuroscience Institute*  
USA

## 1. Introduction

Meningiomas are brain tumors that originate from arachnoid cap cells. They account for about one third of all brain tumors (CBTRUS, 2011), and their incidence increases with age. There are many histological subtypes of meningioma and they differ in their level of malignant behavior. The most commonly used World Health Organization (WHO) scheme (see 2.1) classifies them in three grades, which have distinct prognostic properties.

Malignant meningiomas (WHO grade III) are the most rare, but aggressive subtype of meningiomas. In comparison to other subtypes, they are understudied, likely due to their scarcity. The frequency of 1-3% among all intracranial meningiomas has been reported (Louis et al., 2007).

In this chapter, we are bringing a review of the available literature on malignant meningiomas. Because of the rarity of these tumors, patients with malignant meningiomas represent a very small part of any study population. Most studies analyze information on meningiomas of all subtypes, and the data on malignant ones had to be extracted from the larger population. In the lack of randomized clinical trials, these sporadic experiences and case reports became the foundation for the current clinical practices in diagnosis and treatment of patients with this rare disease. Our review includes the information on meningiomas in general, with focus on malignant meningiomas whenever specific data is available.

### 1.1 Frequency and Risk Factors

#### 1.1.1 Hormonal Factors

Meningiomas in general are more common in women, with female predominance of 2-3 to 1, but this tendency diminishes in atypical and anaplastic meningiomas, in children and in radiation-induced meningiomas (Marosi et al.; Park & McLaren, 2009). Hormonal factors have been considered to play a role in this predominance.

A study on 125 women with meningiomas investigated the risk of meningiomas in relation to exogenous and endogenous sex hormones (Jhawar et al., 2003). The relative risk for premenopausal women was 2.48 and for postmenopausal women who received hormone therapy was 1.86. There was a nonsignificant increased risk of meningioma in parous as opposed to nulliparous women. The risk also trended up with increased BMI. No

association was found for past or current use of oral contraceptives. The risk for meningiomas was increased among women exposed to either endogenous or exogenous sex hormones. However, an unexpected relationship with increase in age at menarche was also noted and remained unexplained.

Another study analyzed the relationship of exposure to female sex hormones and risk of brain tumors. It included 178 meningioma cases, 115 glioma cases and 323 controls (Wigertz et al., 2006). An increased relative risk of meningioma was found among postmenopausal women for ever use of hormone replacement therapy, with an odds ratio of 1.7. Women who had used long-acting hormonal contraceptives had an increased risk of meningioma. Hormone usage was not associated with glioma risk in this study. The findings suggest that the use of female sex steroids may increase the risk of meningioma.

A large retrospective review of data on 355,318 women evaluated for any medical issue (Blitshteyn et al. 2008) was done to investigate the association between meningioma and hormone replacement therapy (HRT). Five percent of this population (18,037 women) was documented as current or past HRT users. A positive correlation between diagnosis of meningioma and HRT use was found, with odds ratio of 2.2. The frequency of meningioma in women with either current or past HRT use was 865 in 100,000, whereas the frequency in women without the history of HRT use was 366 in 100,000. Therefore, HRT use may be a risk factor for meningioma.

### **1.1.2 Radiation**

Radiation-induced meningiomas have a higher rate of multiplicity and atypia, compared to sporadic meningiomas (Park & McLaren, 2009). Historically, low doses of irradiation were used in treatment of tinea capitis until 1950s, and the analysis of data on 10,834 treated children showed the sevenfold increase in the incidence of meningioma, with latency period shorter with higher doses of irradiation (Ron et al., 1988). A strong dose-response relation was found, with the relative risk approaching 20 after estimated doses of approximately 2.5 Gy. Recurrences were more common in patients with radiation-induced meningiomas as compared to the sporadic.

Another study on childhood cancer survivors (Neglia et al., 2006) showed that meningiomas developed in 0.5% of patients treated with cranial irradiation, with median time of diagnosis 17 years after the diagnosis of original malignancy and the risk was directly related to the dose of cranial irradiation.

An increased incidence of meningiomas was found in survivors of the atomic bomb explosions in Japan. The incidence was higher with higher radiation doses and in people who were younger at the time of exposure (Park & McLaren, 2009).

### **1.1.3 Genetic Factors**

There is also increased frequency of meningiomas in certain genetic diseases, like neurofibromatosis (NF type I and II) and familial meningioma. The association with other malignancies is suggestive of a common genetic basis.

Tumorigenesis of meningiomas involves activation of oncogenes and the loss of tumor suppressor genes. NF2 tumor suppressor gene has been found to be mutated in a large portion of meningiomas (Maxwell et al., 1998). Almost all cases of familial meningioma occur in association with NF2. The authors of a case report on two family members with spinal meningiomas, without any NF2 stigmata, conclude that a second tumor suppressor gene locus, other than NF2 acts in formation of familial sporadic meningioma. The conclusion is based on the presence of protein product merlin in specimens from both patients. Merlin has been implicated in the tumorigenesis of meningiomas.

#### 1.1.4 Head Trauma

There is some suggestion of increased risk of meningioma following head trauma. A large case-control study (Preston-Martin et al., 1998) was done to investigate this suggestion based on prior case reports. It involved 1178 patients with gliomas and 330 with meningiomas, matched to 2236 controls. Risks of ever having experienced a head injury was highest for male patients with meningiomas (odds ratio = 1.5), but was lower for "serious" injuries. Latency of 15 to 24 years significantly increased the risk of meningioma among males. Odds ratios were lower for males with gliomas for any injury and in females in general. This has shown that the brain tumor risk after head trauma was strongest for meningiomas in men.

Another case-control study was conducted among women (Preston-Martin et al., 1980). One hundred-eighty-eight women with meningiomas were matched with their neighbors, and their experiences were compared. A history of head trauma was found to be associated with meningioma occurrence, with odds ratio of 2.0.

## 2. Histopathology

### 2.1 WHO Classification

Meningiomas are classified according to the World Health Organization (WHO) schema, which is based upon morphologic criteria. The latest, 2007 version of WHO classification divides meningiomas into 3 groups (Louis et al., 2007; Park et al., 2010):

- WHO grade I – Tumors that do not meet criteria for a higher grade lesion, based upon morphologic criteria. They are subdivided into: meningothelial, fibrous, transitional, psammomatous, angiomatous, microcystic, secretory, lymphoplasmacyte-rich and metaplastic. They are all considered to be of low risk for recurrence or aggressive growth and the treatment approach for all subtypes is the same.
- WHO grade II – Tumors with increased mitotic activity ( $\geq 4$  mitoses per high powered field) and three or more of the following features: increased cellularity, small cells with a high nuclear/cytoplasmic ratio, prominent nucleoli, uninterrupted patternless or sheet-like growth, or foci of spontaneous or geographic necrosis. Subtypes include: atypical, chordoid and clear cell meningiomas. Alternative grading approaches identify individually scored parameters to arrive at a sum (Jääskeläinen et al., 1986; Louis et al., 2007), or simply combine hypercellularity with 5 or more mitoses per 10 high power fields.

- WHO grade III - Tumors with  $\geq 20$  mitoses per high-powered field and/or malignant characteristics resembling carcinoma, sarcoma or melanoma. Features that support the diagnosis of malignant meningioma include the loss of usual meningioma growth patterns, infiltration of underlying brain (Figure 1), abundant mitoses with atypical forms (Figure 2) and multifocal microscopic foci of necrosis (Figure 3). Subtypes include: papillary, rhabdoid and anaplastic (malignant) meningiomas. Although considered malignant, there are only isolated reports on any distant metastases. These tumors recur locally.

The WHO grading system has been revised over the years to better delineate the categories of patients with similar outcomes. With 2000/2007 classification, the differences in progression-free survival between histologic groups became significant, as compared to 1993. The major difference between 2000 and 2007 versions is that brain invasion became a criterion for classifying a meningioma as grade II or III, in a lesion that would otherwise be considered grade I.

Changes in classification criteria are to be considered when literature is reviewed, as they brought on a substantial shift with increasing the numbers of patients with WHO grade II tumors. The refined WHO criteria appear to be more accurate prognostically.

The likelihood of recurrence and/or aggressive behavior of meningioma increases with each higher grade. The proper classification of each tumor is very important in treatment planning. The tumors of lower grade can recur as a higher grade.

One hundred-sixteen patients were diagnosed with “malignant meningioma” (Perry et al., 1999) due to brain invasion, frank anaplasia (20 mitoses per 10 high-power fields or histology resembling carcinoma, sarcoma or melanoma) and/or extracranial metastasis. They were followed in a study, which concluded that histologic anaplasia, subtotal resection, 20 mitoses per 10 high-power fields and nuclear atypia were associated with poor survival. Survival time was highly variable, from 10 days to 24 years. Of 89 cases of meningioma that invaded the brain, 23% were otherwise benign, 61% were otherwise atypical and 17% were frankly anaplastic. Anaplastic meningiomas were usually fatal. Based on these findings it was suggested that the brain invasion constitutes an additional criterion for the diagnosis of atypical meningioma (WHO grade II), whereas frank anaplasia indicates high grade malignancy (WHO grade III)

## 2.2 Pathological Features

Papillary meningiomas are rare variant defined by the presence of perivascular pseudopapillary pattern in at least a part of the tumor. They tend to occur in children. Local invasion of the surrounding structures and invasion of the brain have been noted in 75% of these lesions, recurrence in 55% and metastasis in 20% (WHO, 2000).

Rhabdoid meningioma is an uncommon tumor containing patches or extensive sheets of rhabdoid cells, which are rounded tumor cells with eccentric nuclei, often with a prominent nucleolus, and prominent inclusion-like eosinophilic cytoplasm comprised of whorled intermediate filaments. Most rhabdoid meningiomas have high proliferative indices and additional histological features of malignancy (WHO, 2000).

Anaplastic (malignant) meningiomas are tumors exhibiting histological features of frank malignancy far in excess of the abnormalities present in atypical meningiomas. This includes either obviously malignant cytology or a high mitotic index ( $\geq 20$  mitoses per 10 high-power fields) (WHO, 2000). They are found to have a high proliferation rate as well (Figure 4).

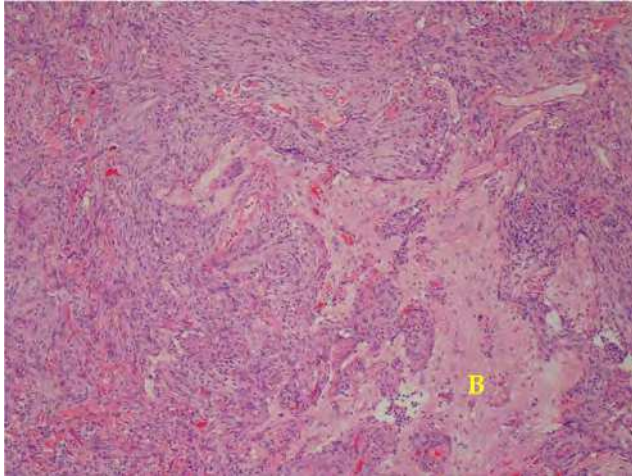


Fig. 1. Brain (B) Invasion. H&E, X10 (original magnification)

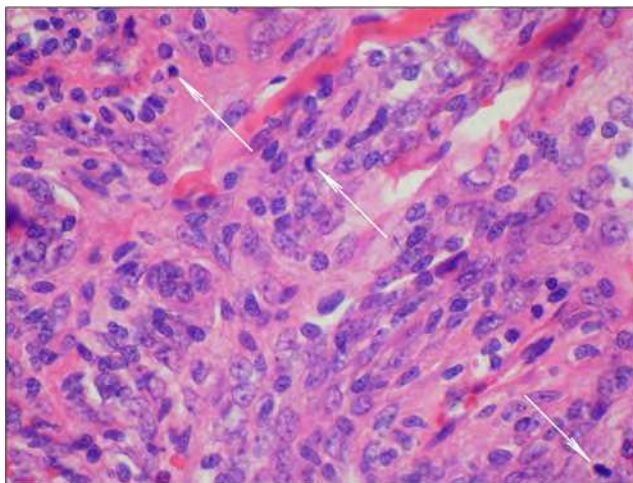


Fig. 2. Mitoses (white arrows). H&E, X60 (original magnification)

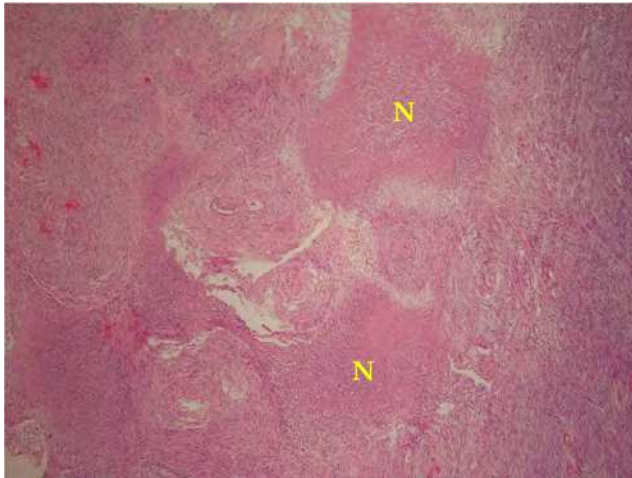


Fig. 3. Necrosis (N). H&E, X4 (original magnification)

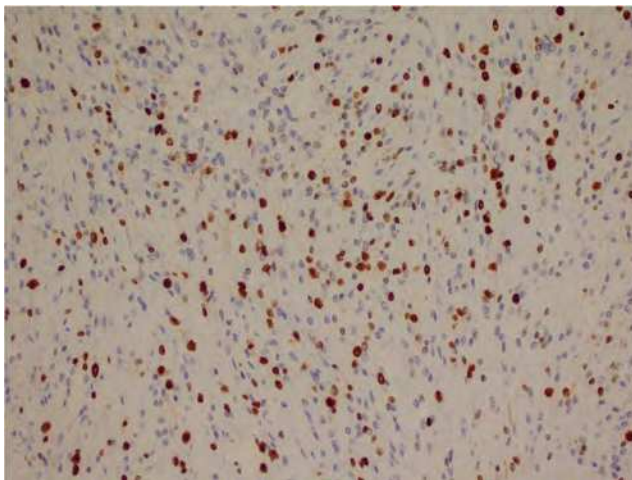


Fig. 4. High proliferation index. Ki67 (MIB-1) cell proliferation marker. Immunohistochemistry. DAKO Envision Flex+ with or without heat induced epitope retrieval techniques. X20 (original magnification)

### 3. Imaging Characteristics

Diagnostic process on patients with intracranial masses typically starts with brain imaging, after the initial clinical assessment. Oftentimes, intracranial masses can be incidental findings on the imaging done for unrelated reasons, such as work-up for head trauma. The most common clinical scenario is a finding of suspicious lesion on a plain computed tomography (CT), which is then followed by gadolinium enhanced magnetic resonance imaging (MRI).

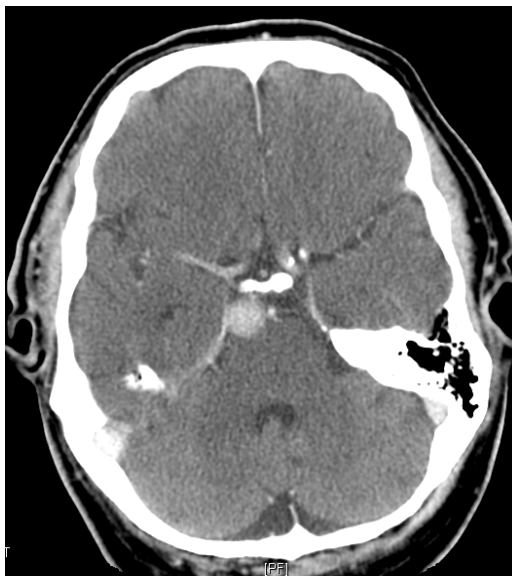

Fig. 5. Contrast enhanced CT image of clival meningioma in a 69-year-old man. Dural tail is visible.

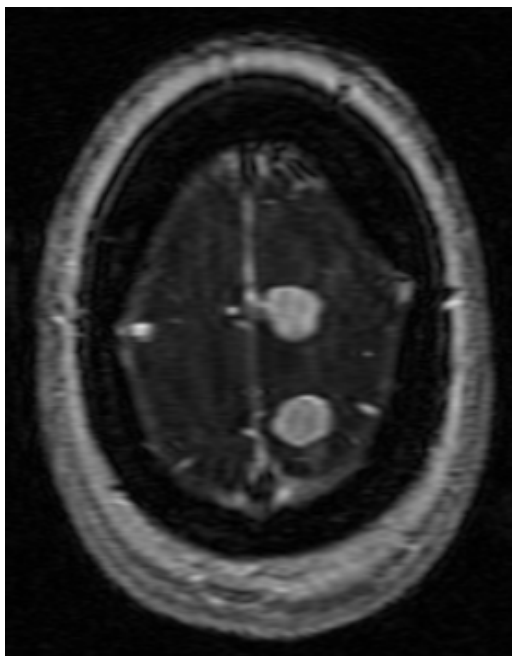


Fig. 6. Axial T1 MRI with gadolinium of the left sided convexity meningiomas in a 62-year old woman. Anterior lesion has visible dural tail.

This applies to meningiomas as well. Although a definitive diagnosis cannot be made solely based on imaging, there are some features that can be suggestive of meningiomas.

The most common locations for meningiomas (in descending order) are in parasagittal dura, convexities, sphenoid wing, cerebellopontine angle cistern, olfactory groove and planum sphenoidale. Ninety percent occur supratentorially. One percent of meningiomas occur outside the CNS, presumably from embryologic arachnoid rests. Because meningiomas arise from arachnoid cap cells, they can occur anywhere that arachnoid exists (Grossman & Yousem, 2003)

The grade of tumor cannot be determined based on imaging, but the benign lesions tend to appear as well demarcated, ovoid extradural masses. With increase in tumor grade, the lesions tend to lose their sharp contours, often demonstrating invasion of surrounding brain tissue, bone and/or venous sinuses. Necrotic centers and calcified portions can be seen as well.

A retrospective study on 75 patients who underwent intracranial meningioma resection was done to determine correlation between aggressive imaging features and advanced histopathological grade in meningiomas (Hsu et al., 2010). Six aggressive imaging features were evaluated: intratumoral cystic change, hyperostosis of the adjacent skull, bony destruction, extracranial tumor extension through the skull base foramina, arterial encasement and peritumoral brain edema. Fifty-nine tumors were classified as benign, according to WHO classification, and 16 as atypical/malignant. Only intratumoral cystic change and extracranial tumor extension through the skull base foramina were more prevalent in atypical/malignant meningiomas.

“Dural tail” is highly characteristic of meningioma and it has been seen in up to 72% of the cases (Grossman & Yousem, 2003). The dura is trailing off away from the lesion in crescentic fashion (Figures 5 & 6).

The degree of parenchymal edema is variable in meningiomas, and it is not necessarily proportionate to their size. It seems to correlate with location, because meningiomas adjacent to cerebral cortex tend to incite greater edema than those along the basal cisterns or planum. It may be caused by compressive ischemia, venous stasis, aggressive growth or parasitization of pial vessels (Grossman & Yousem, 2003).

Bony changes associated with meningiomas may be hyperostotic or osteolytic and occur in 20% to 46% of cases (44). They can be suggestive of malignant behavior, but the hyperostosis along the inner table only can be just the reactive changes rather than neoplastic invasion. Secondary bone involvement occurs in up to 50% of skull base meningiomas. It is uncommon in convexity tumors (Park & McLaren, 2009).

### **3.1 Magnetic Resonance Imaging (MRI)**

MRI is preferred in imaging meningiomas, as it is superior in demonstrating dural origin, as well as vascularity, edema, sinus and bone invasion. Meningiomas are typically isointense or hypointense to gray matter on T1 and isointense or hyperintense on T2 weighted images (Figure 7). They enhance with gadolinium, but they might have areas of necrosis and calcification, which do not enhance.



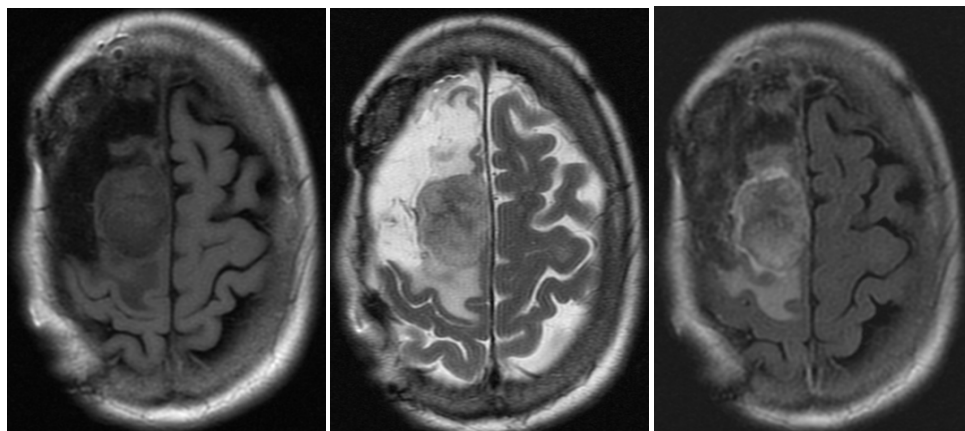


Fig. 7. Axial MRI of a right parasagittal anaplastic meningioma in a 72-year-old woman. Image on the left is FLAIR T1, in the middle is T2 and on the right is T2 FLAIR with gadolinium.

### 3.2 Computed Tomography (CT)

CT scans typically show well-defined, smooth-contoured extra-axial mass, which displaces the normal brain tissue. Sometimes meningiomas can be multilobulated or calcified. They can be isointense with the normal brain tissue, but they enhance uniformly with the intravenous contrast administration, making the diagnosis easier. This is more typical of benign meningiomas.

Characteristics suggestive of aggressive behavior (Figure 8) of the tumor are: indistinct margins, marked edema, mushroom-like projections from tumor, deep brain parenchymal infiltration and heterogenous enhancement (Shapir et al., 1985 as cited in Park & McLaren, 2009).

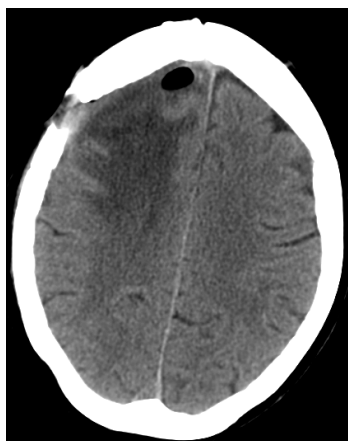

Fig. 8. CT image of a right parasagittal anaplastic meningioma in a 69-year-old woman (same patient as in Figure 7, three years earlier)

### 3.3 Positron Emission Tomography (PET)

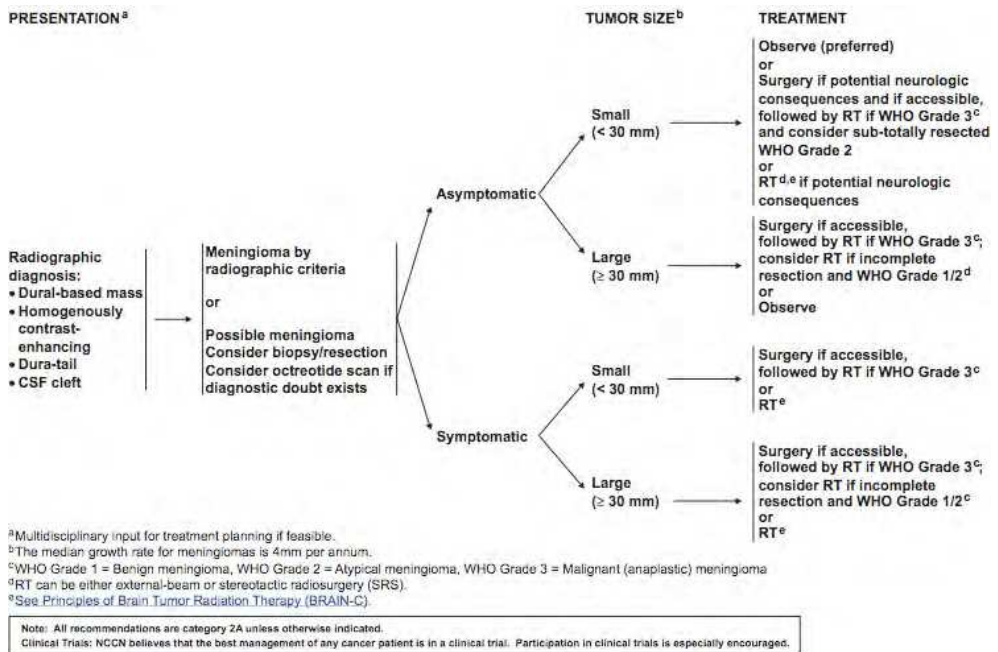
PET is not routinely used in diagnostics of meningiomas, but it has its place in diagnostics of malignant meningiomas, considering that it can help predict aggressiveness of a meningioma and the potential for recurrence (Di Chiro et al., 1987; Park & McLaren, 2009).

### 3.4 Angiography

Angiography was used more often prior to development of MRI and CT techniques. Findings of arterial supply from meningeal vessels and the delayed vascular blush were helpful in diagnosis of meningiomas. They have both dural and pial supply. Angiography is now mainly used as part of the pre-operative embolization procedures.

## 4. Treatment

The National Comprehensive Cancer Network® (NCCN®) guidelines summarize the contemporary approach to meningioma management (NCCN®, 2011):



Reproduced with permission from the NCCN Clinical Practice Guidelines in Oncology (NCCN Guidelines™) for Central Nervous System Cancers V.2.2011. © 2011 National Comprehensive Cancer Network, Inc. All rights reserved. The NCCN Guidelines™ and illustrations herein may not be reproduced in any form for any purpose without the express written permission of the NCCN. To view the most recent and complete version of the NCCN Guidelines, go online to NCCN.org. NATIONAL COMPREHENSIVE CANCER NETWORK®, NCCN®, NCCN GUIDELINES™, and all other NCCN Content are trademarks owned by the National Comprehensive Cancer Network, Inc.

This subchapter contains the review of available literature on various modalities of treatment supplemented with experiences from our own institution. The existing data on therapy most commonly comes from retrospective studies on patients with all types of meningiomas, with only small subgroups having malignant forms. The lack of hard evidence on efficacy of different treatment approaches makes it difficult to standardize the treatment algorithm for malignant meningioma. However, the general consensus is that surgical resection, as radical as possible, should be performed. If indicated, a pre-operative embolization should be done a day before resection. Radiation therapy following surgery is found to be beneficial, and therefore it became a standard of care for these patients. Various modalities of systemic therapy have been tried, mostly on patients who have exhausted all primary options, but unfortunately, their efficacy has not been very promising so far.

#### 4.1 Embolization

As malignant meningiomas are highly vascular tumors, preoperative embolization can make them more resectable. It is most applied to skull base meningiomas, a day prior to surgery (Carli et al., 2010; Matsuda et al., 2011; Oka et al., 1998; Rosen et al., 2002).

Again, the information on malignant meningiomas alone is very scarce. Available sources provide information on meningiomas in general.

A retrospective analysis on 167 cranial base meningiomas (Rosen et al., 2002), which were embolized showed that a good to excellent embolization was achieved in 91% of patients, without permanent neurological sequelae. Cranial base meningiomas were defined as tumors originating from olfactory groove, tuberculum sellae, medial sphenoid wing, petroclival region or foramen magnum. In 20 patients, embolization was not attempted due to the risk of new neurologic deficits or lack of an appropriate vessel for embolization. Fifteen patients (9%) experienced permanent neurologic deficits or medical morbidity as a result of embolization. The conclusion of this study points out that the benefits of embolization as an adjunct to cranial base surgery have to be weighted against the morbidity that comes with this procedure.

Another study involving 20 patients with skull-base meningiomas (Oka et al., 1998) revealed significantly smaller blood loss during surgical resection in patients who underwent pre-operative embolization. This only applied to tumors smaller than 6 cm. There was no difference in blood loss in tumors larger than 6 cm, perhaps because larger meningiomas tend to have tiny blood vessels that are unsuitable for pre-operative embolization. There was no difference in the length of surgery between the embolized and non-embolized group. However, the embolized group tended to show better clinical outcome.

The risks of widely used particle embolization (Carli et al., 2010) were analyzed on 198 patients (201 meningiomas). Indications for embolization were: pre-operative in 165 meningiomas, adjunctive to radiosurgery in 8 and sole therapy in 28. Complications were defined as any neurologic deficits or death that occurred during or after embolization. They occurred in 11 patients (5.6%); 10 were hemorrhagic and 1 ischemic. Complications of embolization resulted in death of 2 and dependency in 5 patients. The use of small particles (45-150  $\mu\text{m}$ ) was the only risk factor for complications. With the complication rate of 5.6% and the increased risks with small particles, the use of small polyvinyl alcohol particles is not recommended.

Another study (Matsuda et al., 2011) assessed the atypical and ischemic features of embolized meningiomas, comparing 29 patients that underwent pre-operative embolization with 29 who did not. Large polyvinyl alcohol particles (150-250  $\mu\text{m}$ ) were used for embolization via middle meningeal or occipital artery, until the stagnation of the contrast agent in the feeding artery was accomplished. The embolization material was invisible in tumors and the large particles were believed to remain in the feeding vessels. Small cells, clear cells, rhabdoid-like cells and pseudopapillary pattern were thought to be associated with embolization using the large particles, instead of development of necrosis. There were no complications of the embolization procedure. Embolization was done 3 to 355 hours before the surgical extirpation. The two groups of patients had no significant differences in gender, age, tumor location and recurrence or regrowth of tumor. However, the differences in histopathological features between the two groups were evident. They included higher mitotic activity, brain invasion, increased cellularity, prominent nucleoli, small cells with high nuclear/cytoplasmic ratio, sheet-like growth and geographic necrosis. Even more evident differences were noted in occurrence of cytoplasmic vacuoles, intercellular discohesion and perivascular cuffs. In accordance to WHO 2007 classification, 11 patients (38%) in embolized group were classified as grade II atypical meningioma, versus 7 patients (24%) in non-embolized group. There were no patients with anaplastic (grade III) meningiomas. It appears that the increased frequency of atypical features in pre-operatively embolized meningiomas could lead to prognostic inaccuracies and overly aggressive therapy. However, the possibility of patient selection bias rather than embolization artifacts leading to higher number of atypical meningiomas in embolized group cannot be excluded, especially considering a rather small patient sample. Proliferative activity in embolized meningiomas does not always reflect genuine tumor proliferation and should not be used to assess malignancy. Ischemic histologic features (including small cells with high N/C ratios, cytoplasmic vacuoles, intercellular discohesion and perivascular cuffs) were identified in embolized meningiomas. Therefore, histological findings and determination of grading should be evaluated cautiously in the cases of embolized meningiomas.

## 4.2 Surgical Options

Complete surgical resection, including its dural attachment is a preferred therapeutic approach for all meningiomas, including malignant. As delineated in NCCN Guidelines (NCCN, 2011; see above), surgery is the first line of treatment for all symptomatic and for large asymptomatic meningiomas. As meningiomas are highly vascular, pre-operative embolization is often used (see 4.1). With advances of modern imaging techniques, microsurgery and image-guided intraoperative approaches, this can be achieved in most tumors at accessible locations, minimizing the damage to normal brain tissue. However, malignant meningiomas often cannot be completely resected. Subtotal resection is then combined with radiation therapy (see 4.3). The extent of surgery is balanced with minimizing neurological deficits possibly caused by resection. Complete resection is usually attempted for tumors of the convexity, olfactory groove, anterior third of the sagittal sinus and some tentorial and posterior fossa tumors. Posterior sagittal region or clivus are less accessible, thus commonly allowing for partial resection, which is then followed by radiation therapy. Tumors involving medial sphenoid wing or cavernous sinus are deemed inaccessible, and surgery is generally not attempted.

### 4.2.1 Extent of Resection and Tendency for Recurrence

The extent of surgical resection is described with Simpson grading system (Simpson, 1957), still widely accepted since its publication:

- Grade I - Macroscopically complete removal of the tumor, with excision of its dural attachment and of any abnormal bone. Includes resection of venous sinus, if involved.
- Grade II - Macroscopically complete removal of the tumor and of its visible extensions, with coagulation of its dural attachment.
- Grade III - Macroscopically complete removal of the intradural tumor, without resection or coagulation of its dural attachment or its extradural extensions (e.g. an invaded sinus or hyperostotic bone).
- Grade IV - Partial removal, leaving intradural tumor in situ.
- Grade V - Simple decompression, with or without biopsy.

The author (Simpson, 1957) analyzed the post-operative results of two series of patients, one of 235 cases (operated on in Oxford, from 1938 to 1954) and one of 97 cases (London, from 1928 to 1938). A system of grading according to the scope of resection was presented and applied to those cases, 265 in all, surviving more than six months. Following 90 operations of grade I, there were 8 recurrences (9%). Following 114 grade II resections, there were 18 recurrences (19%, with cases treated within the last 5 years of study period being excluded). These recurrences became apparent after an average period of five years. Long-delayed recurrences, though clearly possible, appeared unusual. After incomplete resections, grades III-V, the incidence of symptomatic recurrence was naturally much greater, but a number of patients treated by limited excisions were given long periods of relief. In this study, the author emphasized that in the clinical sense, meningiomas may be benign, locally invasive or frankly malignant. The frequency of local infiltration of venous sinuses was found in 15% of cases, infiltration of bone in 20% and of brain in 3.7%. Haematogenous metastasis was found in two patients.

Though this study was conducted more than a half century ago, its general observations are still considered relevant and the new data is only confirming them. Simpson grading system for the extent of surgery is commonly used today in its original form. However, some authors propose adding grade 0 to it (Borovich et al., 1986), entailing a wide resection of the dura around the attachment zone of the meningioma.

More contemporary data reflect the advances of modern surgical techniques and overall medical treatment. Publications regarding malignant meningiomas specifically are still scarce and the few existing studies are retrospective. They all do point to the increased benefit of surgery followed by radiotherapy. With the lack of prospective studies on the use of post-operative radiotherapy for malignant meningiomas, it has nevertheless come to represent the standard of care at most institutions (Hanft et al., 2010).

One retrospective study of 38 patients with 48 malignant meningioma resections (28 total and 20 subtotal) was done to determine the time to recurrence, among other parameters (Dziuk et al., 1998). Twenty-five lesions were treated at initial presentation and 23 were treated as recurrent disease (13 had transformed from previously benign meningiomas). Nineteen patients received post-operative radiation therapy. Histological subtypes included 32 anaplastic meningiomas, 11 hemangiopericytomas, 2 meningiosarcomas and 3 papillary

meningiomas. One patient presented with multicentric disease, and 4 had multicentric disease at recurrence. Tumors were located on frontal/parietal convexity in 33%, falx/parasagittal sinus in 26%, temporal convexity in 10%, tentorium and posterior fossa in 5% each, and in occipital convexity, sphenoid wing, olfactory groove, tuberculum sellae and foramen magnum in 3% of lesions per each location. Eight percent of patients had lesions at multiple sites. Follow-up ranged from 3 to 144 months, with 5 patients excluded from analysis. Disease free survival (DFS) at 24 months for all patients was 74%, and at 5 years it was 25%. DFS at 5 years was 39% following total resection versus 0% after subtotal resection. For all totally resected lesions, the 5-year DFS was improved from 28% for surgery alone to 57% with adjuvant radiotherapy. As there were no distant failures, local control was equated to actuarial DFS. Twenty out of 26 surgery alone meningiomas recurred, as did 7 of 17 receiving adjuvant radiotherapy. Combined results for surgery with and without adjuvant radiation revealed the following: When analyzed by extent of resection, there was a trend to increased DFS at 24 months, 80% for total resection versus 66% for subtotal resection. It was significant at 5 years, with 39% versus 0%. Initially treated lesions displayed a higher rate of local control versus recurrent lesions, with a 5-year DFS of 33% versus 19% respectively. Totally excised lesions treated with surgery alone had 5-year DSF of 28%, compared to 0% for the subtotally excised lesions. The 5-year DFS of surgery alone patients was essentially the same for initial versus recurrent resections. However, the median time to local failure was significantly longer for initial versus recurrent disease, 43.5 months versus 18 months, respectively.

Recurring lesions have an increased tendency toward multicentricity, and multicentric lesions have an increased tendency for recurrence. Once disease has recurred, there is an increased probability for a subsequent local failure, and the disease/progression-free interval is shortened (Salazar, 1988 as cited in Dziuk et al., 1998).

Probability for local control was once again shown to be dependent upon the extent of resection. The meningioma location impacts the potential for total resection: the most accessible convexity lesions are completely resected in 96% of cases, parasagittal/falx tumors 80%, olfactory groove 70%, sphenoid ridge 50%, tuberculum sellae 48% and posterior fossa 43% (Salazar, 1988 as cited in Dziuk et al., 1998). However, total resectability by location does not translate into decreased recurrence by location: the parassagittal region is commonly reported to have the highest recurrence rate. The difference is presumed due to the resection of as little dura as possible in the meningiomas of the middle and posterior sagittal sinus to avoid occlusion.

The tendency of meningiomas to recur even after they appeared to the naked eye as completely surgically removed (Simpson grade I) is attributed in some cases to malignancy and more commonly to an erroneous belief that the excision was total (Borovich & Doron, 1986). In a study on 14 patients with globular meningiomas (Borovich & Doron, 1986), authors examined the dura mater around the meningiomas for evidence of regional multifocality. Meningotheliomatous cell aggregates were demonstrated in 100% of dural strips, which were removed from the line of attachment of each globular meningioma. The cell aggregates were in the form of dural clusters or nodes protruding from the inner aspect of the dura. They appeared benign. Control strips of convexity dura mater taken from 10 neurosurgical patients without meningioma failed to show these meningotheiomatous conglomerates. These findings indicate that solitary globular meningiomas represent only

the most visible growth in the midst of a neoplastic field change spreading over a wide area of dura mater.

Regional multiplicity in meningiomas would thus seem to be rule (Borovich et al., 1986). The authors of this study proposed dividing recurrences after grade I resections into true local and false regional. A local recurrence would be defined as a regrowth within the limits of the previous dural flap. Regional recurrence would be the new growth outside the previous craniotomy site, which should not be considered as a recurrence but as a new primary site. With the idea that a wider resection of the dura around the attachment zone of the meningioma would reduce the incidence of recurrence, the authors proposed adding Simpson grade 0 to the existing classification, defining more radical total resection.

In a large cohort study (Sughrue et al., 2010) of 63 patients with WHO grade III meningiomas, all the patients underwent post-operative radiation therapy after the primary surgery and they were followed for median time of 5 years. Fifty-eight percent of those patients who underwent a second surgery for recurrent meningioma received either <sup>125</sup>I brachytherapy implants or gamma-knife radiosurgery. Nearly 50% of patients had radiographic recurrence. The 2-, 5- and 10-year overall survival rates following initial surgery were 82, 61 and 40%, respectively. There was a significant survival benefit with repeat surgery for recurrent meningiomas (median survival of 53 months versus 25 months). Interestingly, patients treated with near-total resection experienced improved overall survival when compared with patients treated with gross-total resection at initial and repeat operations. Twelve (19%) of 63 patients experienced significant neurological morbidity referable to the resection of their tumors.

#### **4.2.2 Surgical Morbidity and Mortality**

The reported incidence of neurologic deficits as a direct complication of surgery ranges from 2 to 30%, depending on the location of the tumor and the extent of resection. Cortical brain injury may occur if the arachnoid and pia are adherent to the tumor and the pial vasculature is disrupted. Surgeries for skull base meningiomas pose risk for cranial nerve deficits.

The reports on overall surgical mortality vary with patient selection, as well as with changes in surgical care.

The cumulative observed survival rate of 935 patients who underwent surgery for intracranial meningioma (operated on between 1953 and 1980) was 91% at 3 months, 89% at 1 year and 63% at 15 years (Kallio et al., 1992). Significant risk factors for operative mortality (7%) for the 652 patients (operated on from 1966 to 1980) were poor preoperative clinical condition, absence of epilepsy, old age, incomplete tumor removal, pulmonary embolism and intracranial hematoma requiring evacuation. In 828 patients who survived the first post-operative year, the excess risk of death for up to 15 years was related to incomplete tumor removal, poor pre- and post-operative clinical condition, anaplasia of the tumor and hyperostosis. Patients with partial resections had a 4.2-fold relative excess risk of death as compared to patients with complete resections of tumors. Also, patients with malignant tumors had a 4.6-fold risk as compared with those who had benign tumors.

The higher mortality in older age population can be found in many older reports. However, the advances in surgical techniques as well as a careful selection of surgical candidates

among the elderly have the potential of changing this picture. A retrospective study on 17 patients who underwent surgery for intracranial meningioma in their 9<sup>th</sup> decade of life (Mastronardi et al., 1995) showed that severe systemic disease and functional limitations had a major post-operative morbidity and mortality. The risk of post-operative morbidity was higher when the maximum diameter of the tumor was >5 cm.

#### **4.2.3 Peri-operative Management**

Seizures can be the sole symptom at the initial presentation of patients with meningioma, as well as the part of the more complex presentation. They can also occur post-operatively. Prophylaxis with anticonvulsant medications prior to surgery in patients who never had seizures is not indicated. Post-operative prophylaxis on patients undergoing resections of supratentorial tumors is indicated, with gradual tapering and discontinuing the medication in patients who had no seizures.

Cerebral edema is managed with administration of corticosteroids, which are post-surgically tapered if clinically feasible.

Deep venous thrombosis (DVT) appears to be especially problematic in patients with meningiomas, both because of the generally increased risks of DVT in patients undergoing any brain surgery and because meningiomas can produce hypercoagulable state. In 46 patients who underwent brain tumor resections, the incidence of DVT was 72% for meningioma patients, 60% for glioblastoma patients and 20% for brain metastasis patients (Sawaya et al., 1992). There was no correlation between the occurrence of DVT and the “usual suspects” among the risk factors for DVT. This finding, along with the marked variation in the incidence of DVT between the different brain tumor groups, strongly suggests that biological factors play more important role than clinical factors in developing post-operative thrombosis. Pre-operative hemostatic profile was further investigated on 42 brain tumor patients (Sawaya & Glas-Greenwalt, 1992) and the occurrence of DVT was found to be higher with increased prothrombin time, plasminogen and total fibrinolytic activity and with decreased fibrinogen level. This overall trend in the group of patients with DVT after brain tumor resection lead to the conclusion that this hemostatic disorder is most closely related to a subclinical form of chronic disseminated intravascular coagulation syndrome. Pneumatic compression boots and prophylactic anticoagulation post-operatively for all patients with brain tumors should be considered.

#### **4.3 Radiation Therapy**

Radiation therapy is used in addition to subtotal surgical resection of meningiomas, as a sole therapy for unresectable tumors and oftentimes for completely resected tumors with high risk of recurrence per their histopathological features. Like with other therapeutic modalities used for the treatment of meningioma, there are no randomized trials providing evidence of its efficacy and safety. The available observational studies uniformly show the improvement in progression-free survival of patients who received radiation as compared to those who did not.

##### **4.3.1 Effectiveness of Radiation Therapy**

There is no general agreement on the use of radiation for partially removed tumors immediately after the initial surgery or upon the development of recurrence. Just like in



surgical therapy, the techniques in radiation therapy have significantly improved overtime. The improvement of imaging techniques have contributed to better results as well.

This was clearly shown in a retrospective analysis of 140 patients who received radiation therapy as an adjuvant to subtotal resection of intracranial meningiomas, from 1967 to 1990 (Goldsmith et al., 1994). Of 140 meningiomas, 117 were benign and 23 were malignant. The overall survival rate at 5 years was 85% for the benign and 58% for the malignant tumor groups; the 5-year progression-free survival (PFS) rates were 89% and 48%, respectively. The 10-year overall and PFS rates for patients with benign meningiomas was 77%. Improvement in this rate was not related to tumor size, but to a younger age and treatment after 1980 (when CT and MRI became available for planning therapy). Prior to 1980, the radiation therapy volumes were based exclusively upon the surgeon's assessment of the site and volume of residual disease. Availability of CT and/or MRI allowed for incorporating more precise information about the residual tumor into the radiation planning. The 5-year PFS rate for patients with benign meningiomas treated after 1980 was 98% versus 77% for patients treated before 1980. Survival also improved with increasing the minimum radiation dose. None of these factors affected the survival rates of patients with malignant meningiomas.

The objective of the study on 101 patients with skull base meningiomas was to analyze long-term local control and complications after radiotherapy (Mendenhall et al., 2003). Sixty-six patients were treated with radiotherapy alone and 35 were treated with radiotherapy after subtotal surgical resection. Sixty-one patients had previously untreated tumors and 40 had tumors that recurred after prior surgery. The long-term local control rates were 95% at 5 years, 92% at 10 years and 92% at 15 years. The probability of long-term progression-free survival after radiotherapy exceeded 90% and was comparable to the results of complete resection and radiosurgery.

The effectiveness of radiotherapy was assessed in a retrospective study of 119 patients with atypical (69%) or malignant (31%) meningiomas treated with external beam radiotherapy (EBRT) after initial complete resection in 94 cases and for recurrence in 25 patients (Pasquier et al., 2008). The overall survival rates at 5 and 10 years were 65% and 51%, respectively. They were influenced by age over 60 years, low Karnofski performance status and high mitotic rate. The 5- and 10-year disease-free survival rates were 58% and 48%, respectively and were significantly affected by Karnofski performance status and high mitotic rate.

In a study on 936 primary intracranial meningiomas (Jääskeläinen et al., 1986), 94.3% were histologically benign (WHO grade I), 4.7% were atypical (grade II) and 1% were anaplastic (grade III). Only 26% of atypical or anaplastic meningiomas appeared completely innocent on a CT scan. Five years after complete removal, the recurrence rate was 3% for benign meningiomas, 38% for atypical and 78% for anaplastic ones. In spite of post-operative radiotherapy, four out of five anaplastic meningiomas recurred. This data supports the widely accepted practice of using radiation as adjuvant therapy for meningiomas of WHO grade II and III even after gross total resection, due to the increased rate of recurrence of these tumors, even though the effectiveness for malignant meningiomas specifically appears modest.

Previously cited analysis of 38 patients with malignant meningiomas, 19 of which received post-operative radiotherapy (Dziuk et al., 1998, see 4.2.1), showed that the adjuvant

radiation following initial resection increased the 5-year disease-free survival (DFS) rates from 15% to 80%. When administered for recurrent lesions, adjuvant radiotherapy improved the 2-year DFS from 50% to 89%, but had no impact on 5-year DFS. Multivariate analysis indicated that the extent of resection, adjuvant radiotherapy and recurrence status were independent prognostic factors.

#### 4.3.2 Dosage and Toxicity

The authors of the above-mentioned study (Dziuk et al., 1998) also pointed out the importance of treatment volume, recommending 3-4 cm margins around the pre-operative tumor volume. The dose response was established, with recommendation of 60 Gy at conventional fractionation. The adjuvant radiotherapy for the 9 subtotally resected lesions in this study did not provide long-term benefit, but 7 of them received 54 Gy or less.

The importance of radiation dose is illustrated by a retrospective series of 140 patients with benign or malignant meningiomas (Goldsmith et al., 1994), as described above (see 4.3.1). Of 117 patients with benign meningiomas, those treated with doses >52 Gy had better 10-year survival (93% versus 65% with  $\leq 52$  Gy). Similarly, among the patients with malignant meningiomas, the 5-year progression-free survival was better with doses >54 Gy (63% versus 17% with doses  $\leq 53$  Gy).

Available literature uniformly recognizes the increased efficacy of radiotherapy that comes with the increased doses, which of course, has to be balanced with the risks of injury for surrounding tissue. There is, however, little variation on recommended dose. Per (Park et al., 2010), when radiation therapy is applied post-operatively for residual disease, a dose of 54 Gy is used in daily fractions of 1.8 to 2 Gy for benign meningiomas. Atypical and anaplastic meningiomas are treated with higher doses, typically 59.4 Gy.

The recommended dose of adjuvant radiotherapy for best long-term control per (Dziuk et al., 1998) is 60 Gy (especially for subtotally resected disease) and it should be administered simultaneously with an initial complete resection. A 4 cm margin for the initial 50 Gy is advised.

#### 4.3.3 Types of Radiotherapy

The goal of any type of radiation therapy is to deliver maximum dose of radiation to the lesion, while sparing the surrounding viable tissue. The commonly used techniques are stereotactic radiosurgery (SRS), stereotactic radiotherapy (SRT) and intensity-modulated radiation therapy (IMRT) (50). There is some preliminary data on proton beam therapy, which might be useful. Boron neutron capture therapy (BNCT) was tried on two patients, one of whom had anaplastic meningioma (Aiyama et al., 2011). The conclusion was that BNCT could be a safe palliative therapy for malignant brain tumors.

SRS utilizes multiple convergent beams to deliver a high single dose of radiation to a radiographically discrete treatment volume, thereby minimizing injury to adjacent structures (Park et al., 2010b). It is used for tumors in close proximity to critical structures (ex. optic nerve). Radiation alone can be also used for tumors in inaccessible locations like cavernous sinus or medial sphenoid wing. The most well-known machine used is Gamma-Knife®, utilizing cobalt-60. It is best used on lesions of  $\leq 3.5$  cm in size. The typical dose used to treat meningiomas is 12-14 Gy to the 50% Isodose line. This is done at a single sitting.

SRT is similar to SRS, using focused radiation, only fractionated over a series of sessions (Park et al., 2010b). Fractionation improves normal tissue tolerance of radiation, so SRT may be a reasonable alternative for patients with surgically inaccessible lesions. These machines are linear accelerator based and they are more suitable for use on tumors > 3.5 cm in size. The most common machines are CyberKnife® and Novalis Tx®.

IMRT relies upon software and modification of standard linear accelerator output to vary the radiation intensity across each treatment field (Park et al., 2010b). Similarly to SRS and SRT, it is useful for targets juxtaposed to radiation-sensitive structures. It is also particularly valuable for treatment of lesions with complex shape, such as those involving the skull base.

#### 4.4 Systemic Treatment

Despite advances in surgery, radiation therapy and radio-surgery, there remains a small but important subset of patients with meningiomas who develop recurrent disease refractory to conventional therapies. To date, chemotherapies have shown minimal activity and hormonal therapies have proven to be largely ineffective. Progress in identifying alternative forms of therapy for these patients has been limited by poor understanding of the molecular pathogenesis of meningiomas and the critical molecular changes driving tumor growth, and by the lack of meningioma cell lines and tumor models for preclinical studies (Wen et al., 2010).

Most data is collected from observational studies, and unfortunately, none of the agents have proven efficacy in progression-free overall survival.

##### 4.4.1 Hormonal Therapy

Epidemiologic data on meningiomas is suggestive of a link between hormonal factors and development or progression of these tumors. The data has been controversial, with meningiomas being more frequent among women who had multiple pregnancies and among patients with history of breast cancer. However, early menarche and late menopause have not increased the risk of developing meningioma (Grunberg et al., 1991; Wen et al., 2010). Progesterone and androgen receptors are expressed on approximately two thirds of meningiomas and estrogen receptors are expressed on approximately 10% (Wen et al., 2009). Progesterone receptors are predominantly expressed in benign meningiomas with low proliferation indices and they are infrequently expressed in atypical and malignant meningiomas (Wolfsberger et al, 2004). Again, data for malignant meningiomas specifically is limited, likely due to their scarcity. Inhibition of sex hormone receptors has been tried in attempt to alter the course of recurrent meningioma, but without significant success.

###### 4.4.1.1 Progesterone Receptor Inhibition

Progesterone receptor inhibition initially appeared promising, as several small studies showed some efficacy of anti-progestational drug *mifepristone*.

A group of 10 patients with 12 recurrent or primary inoperable meningiomas with recent evidence of tumor growth received 200 mg of mifepristone daily for 12 months (Lamberts et al., 1992). Progression of growth of 5 tumors in 4 patients, stable disease in 3 patients and regression of 4 tumors in 3 patients was shown on CT scan analysis. Five patients had

subjective improvement in headache and general well-being. Mifepristone treatment resulted in control of tumor growth in 6 out of 10 patients. Three of them were noted to have tumor shrinkage.

Another study followed 14 patients with unresectable meningiomas treated with 200 mg of mifepristone daily for 2 to over 31 months (Grunberg et al., 1991). Five patients have shown signs of objective response, 3 have experienced subjective improvement.

These results prompted more comprehensive investigations. A phase III double-blind placebo-controlled randomized study analyzed data on 160 patients with unresectable non-malignant meningiomas, which have appeared or progressed within two years prior to enrollment (Grunberg et al., 2001). Patients were randomized to mifepristone and placebo group, 80 patients per arm. There was no significant difference in response: two mifepristone-treated patients and one placebo-treated patient had partial or unconfirmed responses.

A study following 28 patients with unresectable meningiomas treated with mifepristone for median duration of 35 months (Grunberg et al., 2006) has shown minor responses in 8 patients, 7 of whom were male or premenopausal female. The most common side effects were fatigue, hot flashes and gynecomastia/breast tenderness. Endometrial hyperplasia or polyps were noted in 3 patients and one patient developed peritoneal adenocarcinoma after 9 years of therapy.

Overall, the long-term administration of mifepristone appears to be clinically well tolerated, with modest effect on tumor control, better in subgroup of male and premenopausal female patients. Mifepristone's lack of efficacy may be explained in part by the loss of progesterone receptor expression in meningiomas with increased proliferation index and histologic grade. This is relevant because these advanced tumors are the type most likely to be enrolled into clinical studies (Grunberg et al., 2006; Wen et al., 2010).

#### 4.4.1.2 Estrogen Receptor Inhibition

Estrogen receptor inhibition has been tried in a study on twenty-one patients with non-resectable refractory meningiomas (Goodwin et al., 1993). *Tamoxifen* 40 mg/m<sup>2</sup> was given BID for 4 days, then 10mg BID thereafter. Out of 19 patients that were eligible to continue the study, 1 achieved an MRI-documented partial response, while 2 had a minor CT-documented response of short duration (4 and 20 months). Six patients remained stable for a median duration of 31 months, while 10 (53%) demonstrated progression. This study, as well as the other rare reports fail to prove the benefits of estrogen receptor inhibition in treatment of meningiomas.

#### 4.4.1.3 Androgen Receptor Inhibition

Androgen receptor inhibition with *flutamide* has been tried on a group of 6 patients with no response (Wen et al., 2010). There have been no published trials on androgen receptor antagonists in meningiomas.

### 4.4.2 Chemotherapy

As with other modalities of systemic treatment, chemotherapy has been mainly used for recurrent tumors after the surgical and radiation options have been exhausted. Available

data comes from small clinical trials and case series. Further difficulty in interpreting the efficacy of chemotherapy is posed by the lack of data regarding the natural history of untreated meningiomas (Wen et al., 2010). Overall, most chemotherapeutics have only minimal activity against meningiomas.

#### **4.4.2.1 Dacarbazine, Adriamycin, Ifosphamide and Mesna**

Dacarbazine, adriamycin, ifosphamide and mesna were ineffective in treatment of meningiomas.

#### **4.4.2.2 Combination of Cyclophosphamide, Adriamycin and Vincristine (CAV)**

*Combination of cyclophosphamide, adriamycin and vincristine (CAV)* was studied on 14 patients with primary malignant meningiomas (Chamberlain, 1996). They all underwent surgery (gross-total in 4 and sub-total in 10), followed by radiotherapy. Two to four weeks after radiotherapy, all patients were treated with adjuvant chemotherapy that included CAV. Myelosuppression was the main serious adverse effect. Neuroradiographic response included 3 partial responses and 11 with stable disease. The median time to tumor progression was 4.6 years and median survival was 5.3 years. The conclusion was that the CAV therapy for malignant meningiomas is associated with acceptable toxicity and a modest improvement in survival when compared to patients treated with surgery alone.

#### **4.4.2.3 Temozolomide (TMZ)**

*Temozolomide (TMZ)* has been ineffective. A phase II study (Chamberlain et al., 2004) was conducted on 16 patients with refractory meningioma, previously treated with surgery and radiotherapy, but no prior chemotherapy. Temozolomide was administered orally for 42 consecutive days every 10 weeks. TMZ-related toxicity included anemia (25%), fatigue (18.7%), neutropenia (37.5%), seizures (6.3%) and thrombocytopenia (18.7%). None of the patients demonstrated a neuroradiographic complete or partial response.

#### **4.4.2.4 Irinotecan**

*Irinotecan* has shown inhibition of meningioma cell growth in vitro, but it was ineffective in vivo (Wen et al., 2010).

#### **4.4.2.5 Hydroxyurea**

*Hydroxyurea*, an oral ribonucleotide reductase inhibitor, arrests meningioma cell growth in the S phase of the cell cycle and induces apoptosis. Preliminary reports on use of hydroxyurea appeared promising, but the phase II studies that followed these initial results failed to prove significant efficacy. Many of the patients treated with hydroxyurea also received radiation therapy, making the interpretation of the results even more difficult (Wen et al., 2010). A phase II study of hydroxyurea for unresectable meningiomas (Swinnen et al., 2009) included patients with unresectable, measurable, residual or recurrent, histologically proven benign meningiomas. The study was closed after 29 patients were accrued, due to the slow subject recruitment rate. The objective response rate to chronic hydroxyurea therapy was estimated to  $\leq 12\%$ . Whether the stable disease rate seen differs in any way from what can be expected from the natural history of meningioma could not be determined from this phase II study design.

Another phase II study of hydroxyurea (Fuentes et al., 2004) included 43 patients presenting with unresectable meningioma with clinically and/or neuroradiologically documented

progression. They received 20 mg/kg/day of hydroxyurea orally and were followed every 3 months with physical exam, MRI or CT imaging. Twenty-eight patients underwent surgery. Histology was benign in 18 and atypical in 10 patients. Objective response to hydroxyurea was found in only 3 patients (7%). Progressive disease was observed clinically or radiologically in 26 patients (60.5%). Of the eligible population (n=36 with clinically and/or radiologically proved progression of the disease at the time of entering the study), 2 achieved an objective response and 13 (36%) exhibited stabilization under hydroxyurea therapy, while 21 (58%) progressed under treatment. Overall tolerance of treatment was good, but anemia was observed in 28%, asthenia in 23.5% patients and skin toxicity in one patient. This study did not include any patients with known malignant meningiomas (WHO grade III).

#### 4.4.2.6 Combinations of Hydroxyurea with Imatinib and with Verapamil

There are ongoing phase II clinical trials investigating combinations of hydroxyurea with imatinib and with verapamil.

#### 4.4.3 Interferon $\alpha$

Recombinant interferon alpha inhibits the growth of meningioma cells in vitro. There are several reports on small groups of patients (up to 12) showing resultant stable disease (Wen et al., 2010). A group of 6 patients with either a recurrent malignant meningioma or an unresectable meningioma was treated with interferon- $\alpha$  (Kaba et al., 1997). Two of the six meningiomas were regular, one was atypical and three were malignant. Five of six patients exhibited positive response to treatment, with stabilization of the size of the tumor in four patients and slight regression in one. The toxicity related to interferon was mild and well tolerated, mainly including flu-like symptoms in the beginning of therapy and pain at the injection site thereafter.

A phase II study of patients with recurrent, treatment-refractory, WHO grade I meningiomas (Chamberlain & Glantz, 2008) included 35 patients who all received prior surgery, radiotherapy and chemotherapy. On radiographic documentation of progressive disease, interferon- $\alpha$  was initiated at a dose of 10 million IU/m<sup>2</sup>, subcutaneously every other day in 4-week long cycles. Concurrent dexamethasone was permitted for control of neurologic signs and symptoms. It was given orally to 12 patients. All the patients were followed with complete blood count, chemistry panel and MRI every 3 months. The main toxicities were fatigue, anemia and leucopenia, which required discontinuation in 3 patients and dose reduction in 7 patients. No patients demonstrated a neuroradiographic complete or partial response. Twenty-six patients demonstrated stable disease after the first 3 cycles of interferon, and 9 had progressive disease. The median time to tumor progression was 7 months. All but 3 patients died of disease progression. The median overall survival was 8 months (range 3-28 months). In contrast to previous small studies, this study was confined to patients who had histologically documented WHO grade I meningiomas that had recurred despite undergoing 1 or more prior surgeries. In addition, all patients had failed external beam radiotherapy, half had received stereotactic radiotherapy, and nearly all (34 of 35 patients) had progressed despite previous chemotherapy. Malignant transformation to a higher grade meningioma may have occurred, and the results may be reflective of treating mixed grades of meningiomas. Interferon- $\alpha$  appears to have citostatic activity against heavily pretreated, recurrent meningiomas and could be considered as a palliative therapy for patients who have failed previous surgery and radiotherapy.

#### 4.4.4 Somatostatin Analogs

Somatostatin receptors are expressed in nearly 90% of meningiomas (Norden et al., 2011; Wen et al., 2010).

##### 4.4.4.1 Octreotide

There have been anecdotal reports of *octreotide* (long-acting somatostatin agonist) inhibiting growth in human meningiomas, but the small number of patients make the results difficult to interpret.

A report on three patients (Garcia-Luna et al., 1993) diagnosed with unresectable meningioma, which were treated with octreotide showed almost perfect tolerance to the drug. No change was observed by CT scan at the end of treatment course. The treatment was given for 6 to 16 weeks to each patient and the authors considered the short duration of the treatment to be a possible culprit in not seeing more favorable results.

A case report on a 54-year-old female with suspected pituitary adenoma (Jaffrain-Rea et al., 1998) has shown significant clinical and visual improvement during short-term octreotide therapy, contrasting with the lack of neuroradiological evidence of tumor shrinkage. The patient subsequently underwent transcranial surgery with a final diagnosis of meningioma.

In a study of 16 patients with recurrent meningiomas (Chamberlain et al., 2007) who had progressed radiographically after prior surgery, radiotherapy and chemotherapy, presence of somatostatin receptors was confirmed using octreotide and SPECT scanning. Patients were prospectively treated with octreotide, 2-15 cycles on a monthly schedule, with minimal toxicity. The overall progression-free survival was 44% (7 patients) at 6 months. Thirty-one percent of patients demonstrated a partial radiographic response. Toxicity was minimal, suggesting that somatostatin analogues may offer novel, relatively non-toxic alternative treatment for recurrent meningiomas.

##### 4.4.4.2 Pastreotide

*Pastreotide* is a long-acting somatostatin analog with a higher binding affinity for most somatostatin receptor subtypes than octreotide. In an open label, single arm phase II trial (Norden et al., 2011) pastreotide was given intramuscularly on monthly basis to patients with recurrent or progressive intracranial meningioma. Twenty-six participants have been accrued, 17 of whom (65%) have atypical/malignant meningiomas with previous radiation therapy. Twenty-two tumors show at least intermediate octreotide uptake. There are no radiographic responses. Of 22 evaluable patients, 16 (73%) achieved stable disease. Toxicity included hyperglycemia in 6 patients and elevated lipase in 2 patients. Pastreotide appears to be well tolerated somatostatin analog that is under investigation for heavily pre-treated recurrent meningiomas.

#### 4.4.5 Molecularly Targeted Agents

An increased understanding of the cell signaling pathways has led to the identification of other potential targets for therapeutic intervention. Molecular drugs are designed to target the pathways involved in cell growth, proliferation and angiogenesis. Unlike gliomas, where the blood-brain barrier limits the penetration of many therapeutic agents, the penetration of targeted agents in meningiomas is unlikely to be a major issue (Wen et al.,

2010). As with the other therapies, data for molecularly targeted agents used on malignant meningiomas specifically is unavailable.

#### 4.4.5.1 Platelet Derived Growth Factor (PDGF)

Platelet derived growth factor (PDGF) stimulates tumor cell growth in various tumors. PDGF receptors are expressed in most meningiomas. In a study of expression of PDGF and its receptor in 61 meningiomas by immunohistochemistry and in situ hybridization (Yang & Xu, 2001), it was found that almost all expressed PDGF $\beta$  and PDGF $\beta$  receptor and the positive rate of PDGF $\alpha$  was 49%. Only 2 meningiomas expressed PDGF $\alpha$  receptor. The positive rate and immunostaining intensity of PDGF $\beta$  and PDGF $\beta$  receptor were higher in atypical meningiomas than in benign types. The proliferative activity was found to be higher in atypical meningiomas than in benign types, as evaluated by proliferating cell nuclear antigen labeling index (PCNA LI). The expression of PDGF $\beta$  and PDGF $\beta$  receptor was increasing with increase of PCNA LI. Therefore, the conclusion was that the overexpression of PDGF $\beta$  and PDGF $\beta$  receptor in meningiomas correlates with grade of meningiomas and the proliferative activity of meningiomas; PDGF $\beta$ /R $\beta$  autocrine loop may play critical role in the pathogenesis of meningiomas.

Inhibition of PDGF receptors with *imatinib* was tried in a phase II study, which enrolled 23 patients with recurrent meningiomas (Wen et al., 2009). Out of 22 eligible patients, 13 had benign, 5 atypical and 5 malignant meningiomas. Imatinib was given at a dose of 600 mg/day for the first 4-week cycle, and then gradually increased to 800 mg/day for subsequent cycles. Tissue was available only from minority of patients, but in these specimens there was uniform distribution of PDGF receptors. Out of 19 patients evaluable for response, 10 had progression at first scan and 9 were stable. There were no complete or partial responses. For atypical and malignant meningiomas, median progression-free survival was 2 months. The study was closed due to slow subject accrual. It has shown that imatinib was well tolerated, but ineffective in treatment of recurrent meningiomas.

A recent in vitro trial on primary meningioma cells is suggesting synergistic activity of *imatinib* and protease inhibitor and pro-apoptotic agent *nelfinavir* (Gupta et al., 2007). Primary meningioma cells responded better to combination therapy than to imatinib alone. Combination was also more effective than imatinib alone on in vivo models. The investigation of this combination has still not reached clinical phase.

The combination of *imatinib* and *hydroxyurea* for treatment of recurrent meningioma has been tried in a phase II study at Duke University (Wen et al., 2010). The results are not available yet.

Several other PDGFR inhibitors are undergoing evaluation: *tandutinib*, *dasatinib*, *nilotinib*, *sunitinib*, *pazopanib* and *CHIR 265*. They are tried for variety of cancers, and some of them might be effective for treatment of meningiomas.

#### 4.4.5.2 Epidermal Growth Factor Receptor (EGFR) Inhibitors and Antibodies

Epidermal growth factor receptor (EGFR) is overexpressed in over 60% of meningiomas (Johnson & Toms, 2005; Wen et al., 2010). EGF and transforming growth factor  $\alpha$  (TGF $\alpha$ ) activate these receptors stimulating meningioma cell proliferation in vitro (Johnson & Toms, 2005). Increased TGF $\alpha$  immunoreactivity in meningioma has been associated with aggressive growth. TGF $\alpha$  is also present in the surrounding cerebrospinal fluid. In contrast,



one immunohistochemical study on 84 meningiomas (36 benign, 29 atypical and 19 malignant) suggested that atypical meningiomas without EGFR expression had a statistically worse prognosis compared to atypical EGFR-expressing tumors (Smith et al., 2007). The same tendency was not evident in cases of benign or malignant meningiomas. It is suspected that the atypical tumors lacking EGFR reactivity utilize potent alternative growth-stimulatory pathways.

EGFR inhibitors *erlotinib* and *gefitinib* were evaluated in an open label, single arm, phase II study for recurrent malignant meningiomas (Norden et al., 2010). Twenty-five eligible patients were enrolled. Sixteen (64%) of them received gefitinib and nine (36%) erlotinib. Eight patients (32%) had benign tumors, nine (36%) atypical and eight (32%) malignant. There were no objective imaging responses, but 8 patients (32%) maintained stable disease. Although treatment was well tolerated, neither gefitinib nor erlotinib appear to have significant activity against recurrent meningioma.

In addition to gefitinib and erlotinib, there is a number of other EGFR inhibitors currently undergoing evaluations (*lapatinib*, *neratinib*, *BIBW2992*, *PF00299804*, *ZD6474*). These inhibit EGFR more effectively or inhibit other tyrosine kinases also, potentially increasing their therapeutic benefit (Wen et al., 2010).

*EGFR monoclonal antibodies* have been effective for some systemic malignancies, but they have not been generally used for brain tumors because of the concern regarding the ability to cross blood-brain barrier in sufficient concentration. However, crossing the blood-brain barrier is not a factor in most meningiomas, so it is possible that these antibodies may be effective in these tumors (Wen et al., 2010).

#### 4.4.5.3 Angiogenesis Inhibitors

Inhibition of angiogenesis has been an increasingly important approach to treating various cancers. Meningiomas are highly vascular tumors that derive their blood supply predominantly from meningeal vessels supplied by external carotid artery, with additional supply from cerebral pial vessels (Wen et al., 2010). Data on angiogenesis inhibition in treatment of meningioma is very limited. Vascular endothelial growth factor (VEGF) plays a central role in tumor angiogenesis. Anti-VEGF monoclonal antibody *bevacizumab* has significantly improved outcome in several systemic malignancies as well as in glioblastoma. At least one case report described a partial response in a patient with a progressing anaplastic meningioma (Puchner et al., 2010). Inhibitors of VEGF receptors, such as *sorafenib* and *sunitinib* have prolonged survival in renal cell carcinoma and GIST. Expression of VEGF and VEGFR on meningiomas increases with tumor grade (10-fold in malignant meningioma as compared to benign) (Lamszus et al., 2000). VEGF also plays an important role in the formation of peritumoral edema, which adds to the morbidity of these tumors (Provias et al., 1997). Inhibitors of VEGF and VEGFR have the potential to inhibit angiogenesis, as well as to decrease peritumoral edema.

## 5. Prognosis

WHO grade III tumors, including malignant meningiomas, are significantly more likely to be invasive and have a local recurrence following the initial treatment (even gross total resection). Prognosis worsens with the more poor differentiation of the tumors (Palma et al., 1997; Park & McLaren, 2009; Pasquier et al., 2008). High mitotic rate is a

significant prognostic factor, as well as the poor Karnofski performance status (Pasquier et al., 2008). This leads to overall shorter survival as compared to patients with WHO grade I and II tumors. Several trials have elucidated this observation.

In a study of 1098 surgically treated patients (Yang et al., 2008), 40 were classified as atypical and 24 as anaplastic. 10-year survival and recurrence-free survival rates for patients with atypical tumors (WHO grade II) were 90 and 87%, respectively. In contrast, the patients with anaplastic (WHO grade III), 3 and 5-year recurrence-free survival rates were 50 and 29%, respectively.

Prognosis is also worse for partially resected tumors as compared to completely resected ones. However, the most available data was collected prior to development of adjuvant therapies, which do improve prognosis.

Simpson grade I resection can be reliably performed on convexity meningiomas and regardless of malignant histological findings, it can improve prognosis (Wen et al., 2010).

To better understand the prognostic differences between atypical and malignant meningiomas and the influence of extent of surgical excision on post-operative course, 42 cases of atypical and 29 of malignant meningiomas were studied (Palma et al., 1997). Survival at 5 and 10 years was 95% and 79%, respectively in patients with atypical meningiomas. It was 64.3% and 34.5% in patients with malignant meningiomas. Recurrence-free survival and median time to recurrence were also significantly longer in patients with atypical meningiomas than in patients with malignant tumors: 11.9 versus 2 years and 5 versus 2 years, respectively. Six (26%) of the atypical meningiomas became malignant. Simpson grade I resection and location in the cerebral convexity, which were closely related, were found to be associated with a significantly better clinical course in the entire series. Patients with atypical meningiomas fared better than those with malignant meningiomas after incomplete surgical resection, but the difference was not statistically significant. This study has shown that radical extirpation and histological findings were significantly related to prolonged survival.

Another study on 13 patients with grade III meningiomas (as defined by WHO 2007 classification), evaluated their outcomes (Rosenberg et al., 2009). A total of 24 surgeries were performed, including 13 primary, 7 salvage and 4 second salvage. Also, 14 courses of radiotherapy were administered. A trend was seen toward longer survival for patients who had received adjuvant radiotherapy after initial surgery as compared to those treated with surgery alone. This study confirmed the older observations of generally poor outcomes for malignant meningiomas and the tendency for extended survival in patients receiving adjuvant radiotherapy in comparison to those treated only surgically.

Hisopathological characteristics of tumors have a leading role in bringing the prognosis. It is important to keep in mind that tumors that were embolized prior to resection can change their microscopic appearance making histological analysis more difficult (Matsuda et al., 2011; see 4.1).

## 6. Conclusion

Malignant meningiomas display a tendency for post-surgical recurrence, which significantly increases for multicentric and recurrent disease. Compared to benign meningiomas,

malignant meningiomas also display a shorter interval to recurrence. The information on malignant meningiomas as an entity separate from their benign and atypical counterparts is scarce, due to their rare occurrence. Furthermore, the classification of tumors has changed over the years, making it more difficult to compare the older observations with the new ones. There are no randomized prospective trials evaluating any aspect of management of these tumors.

However, from all the available data some general conclusions can be made. The patients who undergo complete surgical resection tend to have longer survival than those with partial resection. Pre-operative embolization, when feasible, can be helpful in achieving better surgical results. Adjuvant radiotherapy has shown significant benefits when it comes to progression-free survival rates and overall survival. In unresectable tumors, radiation alone can be helpful as well. Systemic therapy, including hormonal, chemotherapy, interferon and somatostatin analogs, has for the most part failed to show much benefit. The molecularly targeted agents have shown efficacy in tumors requiring systemic treatment. Further investigations on malignant meningiomas is warranted in order to improve the current treatment practices and ultimately ameliorate the prognosis for patients affected by these rare tumors.

## 7. Acknowledgement

We would like to thank our medical student Khurram Tariq for his kind help with this chapter.

## 8. References

- Aiyama H, Nakai K, Yamamoto T, Narai T, Kumada H, Ishikawa E, Isobe T, Endo K, Takada T, Yoshida F, Shibata Y & Matsumura A (2011). *A Clinical Trial Protocol for Second Line Treatment of Malignant Brain Tumors with BNCT at University of Tskuba*, Appl Radiat Isot. 2011 Jul 19. (Epub ahead of print)
- Blitshteyn S, Crook JE & Jaeckle KA (2008). *Is There an Association Between Meningioma and Hormone Replacement Therapy?*, J Clin Oncol. 2008; 26(2): 279
- Borovich B & Doron Y (1986). *Recurrence of Intracranial Meningiomas: The Role Played by Regional Multicentricity*, J Neurosurg. 1986 Jan; 64(1): 58-63
- Borovich B, Doron Y, Braun J, Guilburd JN, Zaaroor M, Goldsher D, Lemberger A, Gruskiewicz J & Feinsod M (1986). *Recurrence of Intracranial Meningiomas: The Role Played by Regional Multicentricity. Part 2: Clinical and Radiological Aspects*, J Neurosurg. 1986 Aug; 65(2): 168-71
- Carli DF, Sluzewski M, Beute GN & van Rooij WJ (2010). *Complications of Particle Embolization of Meningiomas: Frequency, Risk Factors and Outcome*, AJNR Am J Neuroradiol. 2010 Jan; 31(1): 152-4. Epub 2009 Sep 3
- CBTRUS (2011). <http://www.cbtrus.org/2007-2008/2007-20081.html> (accessed on 10 Aug 2011)
- Chamberlain MC (1996). *Adjuvant Combined Modality Therapy for Malignant Meningiomas*, J Neurosurg. 1996; 84(5): 733
- Chamberlain MC, Tsao-Wei DD & Groshen S (2004). *Temozolamide for Treatment-Resistant Recurrent Meningioma*, Neurology, 2004; 62(7): 1210

- Chamberlain MC, Glantz MJ & Fadul CE (2007). *Recurrent Meningioma: Salvage Therapy With Long-Acting Somatostatin Analogue*, *Neurology*, 2007; 69(10): 969
- Chamberlain MC & Glantz MJ (2008). *Interferon-Alpha For Recurrent World Health Organization Grade I Intracranial Meningiomas*, *Cancer*, 2008; 113(8): 2146
- Di Chiro G, Hatazawa J, Katz DA, Rizzoli HV & De Michele DJ (1987). *Glucose Utilization by Intracranial Meningiomas as an Index of Tumor Aggressivity and Probability of Recurrence: A PET Study*, *Radiology*. 1987 Aug; 164(2): 521-6
- Dziuk TW, Woo S, Butler EB, Thornby J, Grossman R, Dennis WS, Lu H, Carpenter LS & Chiu JK (1998). *Malignant Meningioma: An Indication for Initial Aggressive Surgery and Adjuvant Radiotherapy*, *Journal of Neuro-Oncology* 37: 177-188, 1998
- Fuentes S, Chinot O, Dufour H, Paz-Paredes A, Métellus P, Barrie-Attarian M & Grisoli F (2004). *Hydroxyurea Treatment for Unresectable Meningioma*, *Neurochirurgie*, 2004 Sep; 50(4): 461-7
- Garcia-Luna PP, Relimpio F, Pumar A, Pereira JL, Leal-Cerro A, Trujillo F, Cortés A & Astorga R (1993). *Clinical Use of Octreotide In Unresectable Meningiomas. A Report of Three Cases*, *J Neurosurg Sci*. 1993; 37(4): 237
- Goodwin JW, Crowley J, Eyre HJ, Stafford B, Jaeckle KA & Townsend JJ (1993). *A Phase II Evaluation of Tamoxifen in Unresectable or Refractory Meningiomas: A Southwest Oncology Group Study*, *J Neurooncol*. 1993; 15(1): 75
- Goldsmith BJ, Wara WM, Wilson CB & Larson DA (1994). *Postoperative Irradiation for Subtotally Resected Meningiomas. A Retrospective Analysis of 140 Patients Treated from 1967 to 1990*, *J Neurosurg*. 1994 Feb; 80(2): 195-201
- Grossman, RI & Yousem DM (2003), *Neoplasm of the Brain*, in *Neuroradiology: The Requisites*, Thrall JH, pp 97-105, Mosby, ISBN-13: 978-0-323-00508-1, ISBN-10: 0-323-00508-X, USA
- Grunberg SM, Weiss MH, Spitz IM, Ahmadi J, Sadun A, Russell CA, Lucci L & Stevenson LL (1991). *Treatment of Unresectable Meningiomas with the Antiprogestosterone Agent Mifepristone*, *J Neurosurg*. 1991 Jun; 74(6): 861-6.
- Grunberg SM, Weiss MH, Russell CA, Spitz IM, Ahmadi J, Sadun A, Sitruk-Ware R (2006). *Long-Term Administration of Mifepristone (RU486): Clinical Tolerance During Extended Treatment of Meningioma*, *Cancer Invest*. 2006 Dec; 24(8): 727-33.
- Grunberg SM, Rankin C, Townsend J, Ahmadi J, Feun L, Fredericks R, Russell C, Kabbinavar F, Barger GR & Stelzer KJ (2001). *Phase III Double-Blind Randomized Placebo-Controlled Study of Mifepristone (RU) for the Treatment of Unresectable Meningioma*, *Proc Am Soc Clin Oncol* 20: 2001 (abstr 222)
- Gupta V, Samuleson CG, Su S & Chen TC (2007). *Nelfinavir Potentiation of Imatinib Cytotoxicity in Meningioma Cells via Survivin Inhibition*, *Neurosurg Focus*. 2007;23(4):E9
- Hanft S, Canoll P & Bruce JN (2010). *A Review of Malignant Meningiomas: Diagnosis, Characteristics and Treatment*, *J Neurooncol* (2010) 99: 433-443
- Hsu CC, Pai CY, Kao HW, Hsueh CJ, Hsu WL & Lo CP (2010). *Do Aggressive Imaging Features Correlate with Advanced Histopathological Grade in Meningiomas?*, *J Clin Neurosci*. 2010; 17(5): 584
- Jääskeläinen J, Haltia M & Servo A (1986). *Atypical and Anaplastic Meningiomas: Radiology, Surgery, Radiotherapy and Outcome*, *Surg Neurol*. 1986 Mar; 25(3): 233-42


- Jaffrain-Rea ML, Minniti G, Santoro A, Bastianello S, Tamburrano G, Gulino A & Cantore G (1998). *Visual Improvement During Octreotide Therapy in a Case of Epissellar Meningioma*, Clin Neurol Neurosurg. 1998; 100(1): 40
- Jhavar BS, Fuchs CS, Colditz GA & Stampfer MJ (2003). *Sex Steroid Hormone Exposures and Risk for Meningioma*, J neurosurg. 2003; 99(5): 848
- Johnson M & Toms S (2005). *Mitogenic Signal Transduction Pathways in Meningiomas: Novel Targets for Meningioma Chemotherapy?*, J Neuropathol Exp Neurol. 2005 Dec; 64(12):1029-36
- Kaba SE, DeMonte F, Bruner JM, Kyritsis AP, Jaeckle KA, Levin V & Young WKA (1997). *The Treatment of Recurrent Unresectable And Malignant Meningiomas With Interferon Alpha-2B*, Neurosurgery, 1997; 40(2): 271
- Kallio M, Sankila R, Hakulinen T & Jääskeläinen J (1992). *Factors Affecting Operative and Excess LongTerm Mortality in 935 Patients with Intracranial Meningioma*, Neurosurgery: July 1992 - Volume 31 - Issue 1 - p 2-12
- Lamberts SW, Tanghe HL, Avezaat CJ, Braakman R, Wijngaarde R, Koper JW & de Jong H (1992). *Mifepristone (RU 486) Treatment of Meningiomas*, J Neurol Neurosurg Psychiatry. 1992 June; 55(6): 486-490
- Lamszus K, Lengler U, Schmidt NO, Stavrou D, Ergün S & Westphal M (2000). *Vascular Endothelial Growth Factor, Hepatocyte Growth Factor/Scatter Factor, Basic Fibroblast Growth Factor, and Placenta Growth Factor in Human Meningiomas and Their Relation to Angiogenesis and Malignancy*, Neurosurgery. 2000 Apr;46(4):938-47; discussion 947-8
- Marosi C, Hassler M, Roessler K, Reni M, Sant M, Mazza E & Vecht C (2008). *Meningioma*, Crit Rev Oncol Hematol. 2008; 67(2): 153
- Matsuda K, Takeuchi H, Arai Y, Kitai R, Hosoda T, Tsunetoshi K, Arishima H, Sato K & Kikuta K (2011). *Atypical and Ischemic Features of Embolized Meningiomas*, Brain Tumor Pathol DOI 10.1007/s10014-011-0058-9
- Mastronardi L, Ferrante L, Qasho R, Ferrari V, Tatarelli R & Fortuna A (1995). *Intracranial Meningiomas in the 9th Decade of Life: A Retrospective Study of 17 Surgical Cases*, Neurosurgery. 1995 Feb; 36(2): 270-4.
- Maxwell M, Shih SD, Galanopoulos T, Hedley-Whyte ET & Cosgrove GR (1998). *Familial Meningioma: Analysis of Expression of Neurofibromatosis 2 Protein Merlin. Report of Two Cases*, J Neurosurg. 1998; 88(3): 562
- Mendenhall WM, Morris CG, Amdur RJ, Foote KD & Friedman WA (2003). *Radiotherapy alone or after subtotal resection for benign skull base meningiomas*, Cancer. 2003 Oct 1; 98(7): 1473-82
- National Comprehensive Cancer Network® (NCCN) (2011). *NCCN Guidelines™ Version 2.2011 Central Nervous System Cancers, MENI-1*, [http://www.nccn.org/professionals/physician\\_gls/f\\_guidelines.asp#site](http://www.nccn.org/professionals/physician_gls/f_guidelines.asp#site)
- Neglia JP, Robison LL, Stovall M, Liu Y, Packer RJ, Hammond S, Yasui Y, Kasper CE, Mertens AC, Donaldson SS, Meadows AT, Inskip PD (2006). *New Primary Neoplasms of the Central Nervous System in Survivors of Childhood Cancer:Aa Report from the Childhood Cancer Survivor Study*, J Natl Cancer Inst. 2006 Nov 1; 98(21): 1528-37
- Norden AD, Raizer JJ, Abrey LE, Lamborn KR, Lassman AB, Chang SM, Yung WK, Gilbert MR, Fine HA, Mehta M, Deangelis LM, Cloughesy TF, Robins HI, Aldape K,

- Dancey J, Prados MD, Lieberman F & Wen PY (2010). *Phase II Trials of Erlotinib or Gefitinib in Patients With Recurrent Meningioma*, J Neurooncol. 2010; 96(2): 211
- Norden AD, Hammond S, Drappatz J, Phuphanich S, Reardon DA, Wong E, Plotkin SR, Lesser GJ, Raizer JJ, Batchelor T, Quant EC, Beroukhi R, Kaley TJ, Muzikansky A, Ciampa AS, Doherty LM, Smith KH, Gerard M, Sceppa C & Wen PY (2011). *Phase II Study of Monthly Pasireotide LAR (SOM230C) for Recurrent or Progressive Meningioma*, J Clin Oncol 29: 2011 ASCO Annual Meeting, abstract No 2040
- Oka H, Kurata A, Kawano N, Saegusa H, Kobayashi I, Ohmomo T, Miyasaka Y & Fujii K. (1998) *Preoperative Superselective Embolization of Skull-Base Meningiomas: Indications and Limitations*, J Neurooncol. 1998 Oct; 40(1): 67-71
- Palma L, Celli P, Franco C, Cervoni L & Cantore G (1997). *Long-Term Prognosis for Atypical and Malignant Meningiomas: A study of 71 Surgical Cases*, J Neurosurg. 1997; 86(5): 793
- Park JK & McLaren Black P (2009). *Biology and Clinical Features of Meningioma*, www.uptodate.com, October 21, 2009
- Park JK, McLaren Black P & Shih H (2010b). *Treatment of Meningiomas*, www.uptodate.com, January 12, 2010
- Park JK, McLaren Black P & Wrensch (2010a). *Meningioma: Epidemiology, Risk Factors and Pathology*, www.uptodate.com, November 18, 2010
- Pasquier D, Bijmolt S, Veninga T, Rezvoy N, Villa S, Krengli M, Weber DC, Baumert BG, Canyilmaz E, Yalman D, Szutowicz E, Tzuk-Shina T & Mirimanoff RO (2008). *Atypical and Malignant Meningioma: Outcome and Prognostic Factors in 119 Irradiated Patients. A multicenter, Retrospective Study of the Rare Cancer Network*, Int J Radiat Oncol Biol Phys. 2008 Aug 1; 71(5): 1388-93. Epub 2008 Mar 4
- Perry A, Scheithauer BW, Stafford SL, Lohse CM & Wollan PC (1999). *"Malignancy" in Meningiomas: A Clinicopathologic Study of 116 Patients, with Grading Implications*, Cancer. 1999; 85(9): 2046
- Preston-Martin S, Paganini-Hill A, Henderson BE, Pike MC & Wood C (1980). *Case-Control Study of Intracranial Meningiomas in Women in Los Angeles County, California*, J Natl Cancer Inst. 1980; 65(1): 67
- Preston-Martin S, Pogoda JM, Schlehofer B, Blettner M, Howe GR, Ryan P, Menegoz F, Giles GG, Rodvall Y, Choi NW, Little J & Arslan A (1998). *An International Case-Control Study of Adult Glioma and Meningioma: The Role of Head Trauma*. Int J Epidemiol. 1998; 27(4): 579
- Provias J, Claffey K, delAguila L, Lau N, Feldkamp M & Guha A, Meningiomas (1997). *Role of Vascular Endothelial Growth Factor/Vascular Permeability Factor in Angiogenesis and Peritumoral Edema*, Neurosurgery: May 1997 - Volume 40 - Issue 5 - pp 1016-102
- Puchner MJA, Hans VH, Haratl A, Lohmann F, Glas M & Herrlinger U (2010), *Bevacizumab-Induced Regression of Anaplastic Meningioma*, Annals of Oncology, 2010 Dec; Vol 21, Issue 12, pp 2445-2446
- Ron E, Modan B, Boice JD Jr, Alfandary E, Stovall M, Chetrit A & Katz L (1988). *Tumors of the Brain and Nervous System After Radiotherapy in Childhood*, N Engl J Med. 1988; 319(16): 1033

- Rosen CL, Ammerman JM, Sekhar LN & Bank WO (2002). *Outcome Analysis of Preoperative Embolization in Cranial Base Surgery*, Acta Neurochir (Wien). 2002 Nov; 144(11): 1157-64
- Rosenberg LA, Prayson RA, Lee J, Reddy C, Chao ST, Barnett GH, Vogelbaum MA & Suh JH (2009). *Long-Term Experience with World Health Organization Grade III (Malignant) Meningiomas at a Single Institution*, Int J Radiat Oncol Biol Phys. 2009; 74(2): 427
- Salazar OM (1988). *Ensuring Local Control in Meningiomas*, Int J Radiat Oncol Biol Phys. 1988 Aug; 15(2): 501-4
- Sawaya R, Zuccarello M, Elkalliny M & Nishiyama H (1992). *Postoperative Venous Thromboembolism and Brain Tumors: Part I. Clinical Profile*, J Neurooncol. 1992 Oct; 14(2): 119-25
- Sawaya R & Glas-Greenwalt P (1992). *Postoperative Venous Thromboembolism and Brain Tumors: Part II. Hemostatic Profile*, J Neurooncol. 1992 Oct; 14(2): 127-34
- Shapir J, Coblenz C, Malanson D, Ethier R & Robitaille Y (1985). *New CT Finding in Aggressive Meningioma*, AJNR Am J Neuroradiol. 1985 Jan-Feb; 6(1): 101-2
- Simpson, D (1957). *The Recurrence of Intracranial Meningioma After Surgical Treatment*, J. Neurol. Neurosurg. Psychiat., 1957, 20, 22
- Smith JS, Lal A, Harmon-Smith M, Bollen AW & McDermott MW (2007). *Association Between Absence of Epidermal Growth Factor Receptor Immunoreactivity and Poor Prognosis in Patients with Atypical Meningioma*, J Neurosurg. 2007 Jun; 106(6):1034-40
- Sughrue ME, Sanai N, Shangari G, Parsa AT, Berger MS & McDermott MW (2010). *Outcome and Survival Following Primary and Repeat Surgery for World Health Organization Grade III Meningiomas*, J Neurosurg. 2010 Aug; 113(2): 202-9.
- Swinnen LJ, Rankin C, Rushing EJ, Laura HF, Damek DM & Barger GR (2009). *Phase II Study of Hydroxyurea for Unresectable Meningioma (Southwest Oncology Group S9811)*, Journal of Clinical Oncology 2009, Vol 27, No 15S
- Wen PY, Quant E, Drappatz J, Beroukhir R & Norden AD (2010). *Medical Therapies for Meningiomas*, J Neurooncol, 2010; 99(3): 365-378
- Wen PY, Yung WK, Lamborn KR, Norden AD, Cloughesy TF, Abrey LE, Fine HA, Chang SM, Robins HI, Fink K, Deangelis LM, Mehta M, Di Tomaso E, Drappatz J, Kesari S, Ligon KL, Aldape K, Jain RK, Stiles CD, Egorin MJ & Prados MD (2009). *Phase II Study of Imatinib Mesylate for Recurrent Meningiomas (North American Brain Tumor Consortium Study 01-08)*, Neuro Oncol. 2009; 11(6): 853
- WHO Classification of Tumors of the Central Nervous System (2007), Louis DN, Ohgaki, H, Wiestler OD & Cavenee WK, ISBN978-92-832-2430-2, Lyon (France)
- Wigertz A, Lönn S, Mathiesen T, Ahlbom A, Hall P & Feychting M (2006). *Risk of Brain Tumors Associated with Exposure to Exogenous Female Sex Hormones*, Am J Epidemiol. 2006; 164(7): 629
- Wolfsberger S, Doostkam S, Boecher-Schwarz HG, Roessler K, van Trotsenburg M, Hainfellner JA & Knosp E (2004). *Progesterone-Receptor Index in Meningiomas: Correlation with Clinico-Pathological Parameters and Review of the Literature*, Neurosurg Rev. 2004 Oct; 27(4): 238-45. Epub 2004 May 27
- World Health Organization Classification of Tumors (WHO OMS), International Agency for Research on Cancer (IARC) (2000), Meningeal Tumors, in *Pathology and Genetics of*

- Tumors of The Nervous System*, Kleihues P & Cavenee WK, pp 175-184, IARC Press, ISBN 92 832 2409 4, Lyon (France)
- Yang SY, Park CK, Park SH, Kim DG, Chung YS & Jung HW (2008). *Atypical and Anaplastic Meningiomas: Prognostic Implications of Clinicopathological Features*, J Neurol Neurosurg Psychiatry. 2008 May; 79(5): 574-80. Epub 2007 Aug 31
- Yang SY & Xu GM (2001). *Expression of PDGF and Its Receptor as well as Their Relationship to Proliferating Activity and Apoptosis of Meningiomas in Human Meningiomas*, J Clin Neurosci. 2001 May; 8 Suppl 1:49-53.





## **Meningiomas - Management and Surgery**

Edited by Dr. Daniel Monleon

ISBN 978-953-51-0175-8

Hard cover, 136 pages

**Publisher** InTech

**Published online** 02, March, 2012

**Published in print edition** March, 2012

This book is aimed at neurosurgeons with an interest in updating their knowledge on the latest state of meningiomas surgery and management. The book is focused at performing a portrait of that what is state of the art in management of meningiomas. All the chapters have been developed with high quality and including the most modern approaches for the different aspects they deal with. The book concentrates on those problems that, although perhaps less common in the day to day routine of the average neurosurgeon, when present pose a special challenge. This is neither a "how to" book nor a book about meningioma biology. It presents some of the most relevant aspects in the latest developments for meningioma surgery and management in a clear and professional manner.

### **How to reference**

In order to correctly reference this scholarly work, feel free to copy and paste the following:

Danijela Levačić, David Nochlin, Thomas Steineke and Joseph C. Landolfi (2012). Management of Malignant Meningiomas, Meningiomas - Management and Surgery, Dr. Daniel Monleon (Ed.), ISBN: 978-953-51-0175-8, InTech, Available from: <http://www.intechopen.com/books/meningiomas-management-and-surgery/management-of-malignant-meningiomas>

**INTECH**  
open science | open minds

### **InTech Europe**

University Campus STeP Ri  
Slavka Krautzeka 83/A  
51000 Rijeka, Croatia  
Phone: +385 (51) 770 447  
Fax: +385 (51) 686 166  
[www.intechopen.com](http://www.intechopen.com)

### **InTech China**

Unit 405, Office Block, Hotel Equatorial Shanghai  
No.65, Yan An Road (West), Shanghai, 200040, China  
中国上海市延安西路65号上海国际贵都大饭店办公楼405单元  
Phone: +86-21-62489820  
Fax: +86-21-62489821

© 2012 The Author(s). Licensee IntechOpen. This is an open access article distributed under the terms of the [Creative Commons Attribution 3.0 License](#), which permits unrestricted use, distribution, and reproduction in any medium, provided the original work is properly cited.