

Head and Neck Cancer and Neck Dissection - A Personal View

Raja Kummoona
*Professor Emeritus of Maxillofacial Surgery,
Acting Chairman of Maxillofacial Surgery,
Iraqi Board for Medical Specializations,
Baghdad,
Iraq*

Head and neck cancer represent nearly 12% of total malignancies, including the face, the oropharynx, the parotid gland and other salivary glands, the orbit, the jaw, the sinuses and other parts of the face including the skin. These anatomical sites might be affected by other varieties of cancer, such as basal cell carcinoma, squamous-cell carcinoma, fibro sarcoma, osteogenic sarcoma and jaw lymphoma, and non-Hodgkin's lymphoma and Hodgkin's lymphoma. Jaw lymphoma is nominated from other parts of the world and Africa, such as Burkitt lymphoma. Jaw lymphoma is quite different from Burkitt lymphoma in its clinical features, aetiology and even with regard to its treatment. Jaw lymphoma is presented as having a very rapid onset with a fast spread to internal organs and the brain, while Burkitt lymphoma is a slowly growing tumour; it is well known that Burkitt lymphoma can be treated successfully by a few courses of cyclophosphamide (40 mg/square meter) but jaw lymphoma requires a more complicated regimen with combination of many chemotherapeutic agents, such as CHOP(therapeutic regimen of jaw lymphoma consist of eight doses over 24 weeks including 1.5mg/m² Vincristine, 50mg/m² Adriamycin, 1000mg/m² Cyclophosphomide, 10mg/m² Methotroxate and 50mg/m² prednisolone) and it rarely deposits its tumour to the lymph nodes. Cancer of the head and neck constitute an important section of the total cancers affecting the body, and oral cancer represents about 4% of this; it is not necessary that all such cancers have nodal deposits in the neck, such jaw lymphoma or Burkitt Lymphoma. Malignant tumours such as squamous cell carcinoma - which form about 95% of oral cancers - and Melanoma - a highly malignant tumour with early metastasis - are rare and aggressive types of tumours and the survival rate is very low. Other malignant tumours, such as adenocarcinoma - which is a slowly growing malignant tumour - have less of a tendency for cervical node metastasis.

Cancer of the paranasal sinuses is considered to be an aggressive type of malignancy with a tendency to invade the orbit and the base of the skull. The most common tumour of the sinuses is squamous cell carcinoma rather than adenocarcinoma, as a result of cellular changes from respiratory columnar type to squamous type due to the recurrence of infection and other irritating agents. These types of tumour metastasise in the cervical lymph nodes. Cancer of the oral cavity represents somewhat less than 4% of total cancer incidence but this might increase to more than 40% - as in India due to dietary causes such as spicy foods and

smoking – and these tumours appear as a fissure or exophytic growth or ulcer with white leukoplakia, and the most common site which is affected is the tongue and floor of the mouth. Both of these lesions in early metastasis affect the deep chain of the cervical lymph nodes, and the managements of these cases was based on a combination of three modalities in the form of radical surgery, chemotherapy and deep x-ray therapy. There is no possibility of a single technique for treatment in these cases. A frozen section in theatre is required for any assessment of the complete eradication of tumours

Nowadays, chemotherapy has played an important role in the management of head and neck cancers due to advances in the manufacturing of these drugs and DXT (deep x-ray therapy) which have become more specific and more precise in targeting cancer tumours. One technique of note is the use of the gamma Knife (Cobalt 60) in the management of brain tumours and intraocular malignancies without evisceration of the eye ball (which can be very depressing and inconvenient for patients).

The advancement of surgical management of head and neck tumours was based on advances in flap surgeries, such as a pedicle flaps like the forehead flap, the lateral cervical flap, the deltopectoral flap and the trapezius flap, or else by using free flaps like the forearm flap and the tapes dorsalis flap; these flaps are required for microanastomosis for the reconstruction the surgical defects after radical cancer surgery. We have not forgotten that the traditional use of radical neck dissection as a method of treatment for cervical lymph node metastasis has not often been used as a surgical procedure for the total radical excision of cervical lymph nodes with the radical excision of the sternomastoid muscle, the accessory nerve, deep cervical fascia and internal jugular vein ligation. This procedure has become less popular due to the creation of an obvious vertical band of scars extending all over the neck and dropping off the shoulder with a superficial exposure of the carotid tree just below the skin. This problem was overcome by the advancement of the trapezius flap so as to cover the carotid tree and so avoid any traumatic injuries to carotid content. These complications have been avoided by advances in other techniques, such as selective neck dissection, functional neck dissection and supraomohyoid neck dissection.

The advancements of different diagnostic tools for detection of any cervical lymph node metastasis and assessment of these deposit been used by application of ultra sonography , MRI and CT scan with protocol for management of cervical lymph nodes metastasis is the basis for management of cervical lymph node metastasis.

The most common malignant tumours of the orofacial region is basal cell carcinoma affecting the skin of the face and this is more common among white people who have less melanin pigment in their skin and who have continuous exposure to sun light. This tumour is a slowly growing type with a tendency to invade the underlying structures and it does not metastasis to the cervical lymph nodes. Squamous cell carcinoma represents about 95% of the total oral malignancies mainly affecting the tongue and the floor of the mouth with tendency for cervical lymph node deposits. The management of these tumours requires the application of all modalities of treatment, surgery, DXT and chemotherapy.

Adenocarcinoma is less common in the oral cavity and affects the minor salivary glands – it is more common in the maxilla and it is a slowly growing tumour that rarely metastasises in the cervical lymph nodes and is less aggressive than adenocarcinoma of the gastro-intestinal tract, which is a highly malignant tumour with early metastasis in mesenteric lymph nodes. The eradication of these tumours is rather difficult due to their early metastasis and the complicated anatomy of the area, which makes radical surgery rather difficult. Recent

advances in chemotherapy have seen the application of Gemzar (gencitabin) (this drug interferes with the growth and spread of cancer cells by inducing apoptosis and ant metabolite and also been used with Carboplatin) - which is a specific chemotherapy for this type of malignancy and was a promising type of chemotherapy even in cases of fourth-stage of pancreatic adenocarcinoma. In the parotid glands, adenocarcinoma is common and also is mucoepidermoid carcinoma and other malignancies; only rarely is the parotid affected by malignant oncocytoma, this type of tumour metastasises in cervical lymph nodes and requires radical resection of the tumour with chemotherapy and DXT.

The majority of head and neck tumours require neck dissection at once, affecting the oral cavity and parotid region. However, tumours affecting the middle third of the face - such as the maxilla or the orbit - require radical surgery with flap reconstruction followed by DXT and chemotherapy, rather than radical neck dissection and as there is rarely any metastasis in the cervical lymph nodes.

Melanoma of the orofacial tumour is a highly malignant type of tumour with a high tendency for early cervical metastasis, and the prognosis is not very promising. It requires multiple therapies for controlling its tumours, including chemotherapy and radical surgery, while melanoma of the lower limbs is less aggressive and responds to radical surgery and is diagnosed with lymphoscintigraphy.

Current cancer research focused now a days on understanding on the response and resistance to treatment and apoptosis. Cancer treatment depend not only on cellular damages as achieved by chemotherapy and DXT but also on the ability of the cell to respond to damages by inducing apoptotic changes and mutation in apoptotic pathway to end with resistance to chemotherapy drugs and radiation. Mitochondria and cell surface receptors

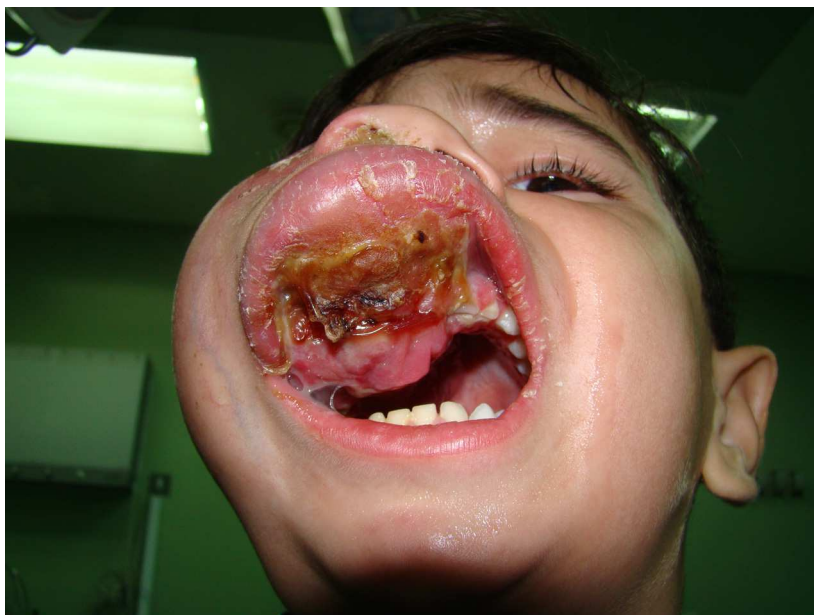

Fig. 1. Jaw lymphoma of the right side of the face of a 2 year old boy with a history of one month.

mediate the pathway of apoptosis and this pathways mediated by Bcl-2 family protein and the final excursion of cell death is performed by caspase cascade which is triggered by release cytochrome C from mitochondria. Most of the activity in the development of apoptosis drugs was concentrated on apoptosis inducers for treatment of malignancies.

The future might be very promising for the control of lymph node deposits by using different methods of accessing neck dissection as well as the recent application of robot surgery (the da Vinci surgical robot system) which is more widely used in prostatic eradication than in any other specialty and which might be used in general surgery. However, this technique is limited in its application in all fields and even in head and neck malignancies. Expanding the role of DXT and chemotherapy as the first line of treatment and as a curative therapy without the need for radical neck dissection, either as an adjuvant with surgery or without as in jaw lymphoma (which is the only line of treatment for such a highly malignant tumour, being a fast spreading and fatal tumour).


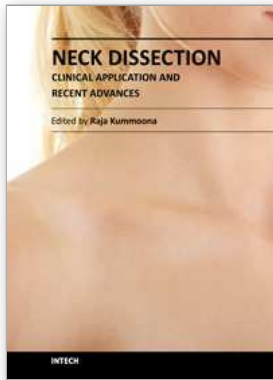


Fig. 2. Post-therapy after 2 years of treatment of jaw lymphoma by 6 courses of chemotherapy, with the collaboration with Prof. Selma Al Hadad, Paediatric Oncologist, Medical City Baghdad.



Neck Dissection - Clinical Application and Recent Advances

Edited by Prof. Raja Kummoona

ISBN 978-953-51-0104-8

Hard cover, 164 pages

Publisher InTech

Published online 22, February, 2012

Published in print edition February, 2012

Neck Dissection - Clinical Application and Recent Advances is a leading book in neck surgery and represents the recent work and experiences of a number of top international scientists. The book covers all techniques of neck dissection and the most recent advances in neck dissection by advocating better access to all techniques of neck dissection; e.g. Robotic surgery (de Venice) system, a technique for detection of lymph node metastasis by ultra sonography and CT scan, and a technique of therapeutic selective neck dissection in multidisciplinary treatment. This book is essential to any surgeon specializing or practicing neck surgery, including Head Neck Surgeons, Maxillofacial Surgeons, ENT Surgeons, Plastic and Reconstructive Surgeons, Craniofacial Surgeons and also to all postgraduate Medical & Dental candidates in the field.

How to reference

In order to correctly reference this scholarly work, feel free to copy and paste the following:

Raja Kummoona (2012). Head and Neck Cancer and Neck Dissection - A Personal View, Neck Dissection - Clinical Application and Recent Advances, Prof. Raja Kummoona (Ed.), ISBN: 978-953-51-0104-8, InTech, Available from: <http://www.intechopen.com/books/neck-dissection-clinical-application-and-recent-advances/head-and-neck-cancer-and-neck-dissection-a-personal-view>

INTECH
open science | open minds

InTech Europe

University Campus STeP Ri
Slavka Krautzeka 83/A
51000 Rijeka, Croatia
Phone: +385 (51) 770 447
Fax: +385 (51) 686 166
www.intechopen.com

InTech China

Unit 405, Office Block, Hotel Equatorial Shanghai
No.65, Yan An Road (West), Shanghai, 200040, China
中国上海市延安西路65号上海国际贵都大饭店办公楼405单元
Phone: +86-21-62489820
Fax: +86-21-62489821

© 2012 The Author(s). Licensee IntechOpen. This is an open access article distributed under the terms of the [Creative Commons Attribution 3.0 License](#), which permits unrestricted use, distribution, and reproduction in any medium, provided the original work is properly cited.