

Ankylosing Apondylitis of Temporomandibular Joint (TMJ)

Raveendra Manemi¹, Rooprashmi Kenchangoudar¹ and Peter Revington²

¹*Dept. of Oral and Maxillofacial Surgery,
Gloucestershire Royal Hospitals NHS Trust, Gloucester,*

²*Dept. of Oral and Maxillofacial Surgery
North Bristol NHS Trust, Bristol
UK*

1. Introduction

The ankylosing spondylitis (AS) (Bechterew's disease) is a chronic inflammatory rheumatoid disease with predilection in the axial structures. Often the first clinical indication of the condition is lumbo-sacral pain and discomfort with limited range of motion. The prevalence in Caucasian population is 1-2% with slight male predominance [1, 31, and 32]. Peak age of onset is between 20–30 years, with an average 5–6-year delay in diagnosis reported in the literature. A familial tendency has been strongly suggested by recent evidence. Immunologic activity is suggested by the presence of histocompatibility antigen HLA-B27 (in more than 90 percent of patients with this disease) and circulating immune complexes.

The disease course, although highly variable, will progress to severe disability in one third of patients. Progressive synovial changes eventually involve all of the axial joints including the temporomandibular joint [2]. Literature shows the temporomandibular joint (TMJ) is involved in 4% to 32% of cases [1, 31, and 32]. The severity of the disease may range from sore TMJ to complete ankylosis leading to restricted mouth opening. Ankylosis of the TMJ is exceptional; the involvement of TMJ has not been very well investigated. This chapter describes the incidence, clinical features, pathophysiology, signs, symptoms and current management of TMJ ankylosing spondylitis

2. Anatomy of TMJ

The Temporo-Mandibular joint (TMJ) is the joint of the jaw and is frequently referred to as TMJ [3]. There are two TMJs, one on either side, working in unison. The name is derived from the two bones which form the joint: the upper temporal bone which is part of the cranium (skull), and the lower jaw bone called the mandible. The unique feature of the TMJs is the articular disc. The disc is composed of fibrocartilagenous tissue (like the firm and flexible elastic cartilage of the ear) which is positioned between the two bones that form the joint. The TMJs are one of the only synovial joints in the human body with an articular disc, another being the sternoclavicular joint. The disc divides each joint into two. The lower joint compartment formed by the mandible and the articular disc is involved in rotational

movement—this is the initial movement of the jaw when the mouth opens. The upper joint compartment formed by the articular disk and the temporal bone is involved in translational movement—this is the secondary gliding motion of the jaw as it is opened widely.

The part of the mandible which mates to the under-surface of the disc is the condyle and the part of the temporal bone which mates to the upper surface of the disk is the glenoid (or mandibular) fossa.

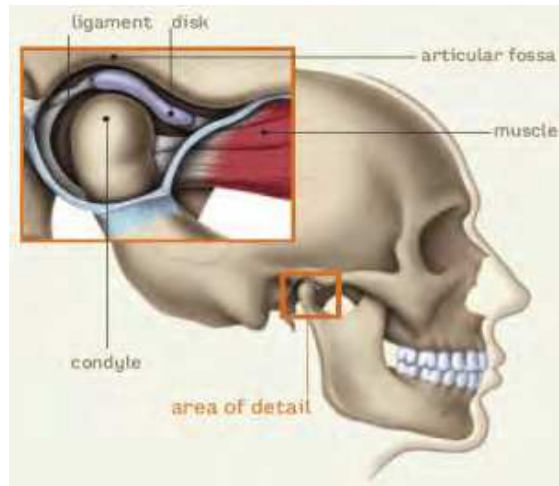


Fig. 1.

The TMJ is a hinge and gliding joint and is the most constantly used joint in the body. The round upper end of the lower jaw, or the movable portion of the joint, is called the condyle; the socket is called the articular fossa. Between the condyle and the fossa is a disk made of cartilage that acts as a cushion to absorb stress and allows the condyle to move easily when the mouth opens and closes.

3. Pathophysiology

Ankylosing spondylitis (AS) is a systemic rheumatic disease, meaning it affects the entire body. Approximately 90% of AS patients express the HLA-B27 genotype, meaning there is a strong genetic association. However, only 5% of individuals with the HLA-B27 genotype contract the disease. Tumor necrosis factor-alpha (TNF α) and Interleukin-1(IL-1) are also implicated in ankylosing spondylitis. Autoantibodies specific for AS have not been identified. Antineutrophil cytoplasmic antibodies (ANCA) are associated with AS, but do not correlate with disease severity.

TMJ involvement in patients with ankylosing spondylitis has been described previously in very few journals[16] Its reported frequency varies from 1% to 35%, depending on the diagnostic criteria, the population studied, and the tools used to assess TMJ involvement[17]. However, the majority of the reports included patients with long lasting ankylosing spondylitis from tertiary care centres, and while they focus on TMJ involvement, little information on the characteristics of the ankylosing spondylitis is given.

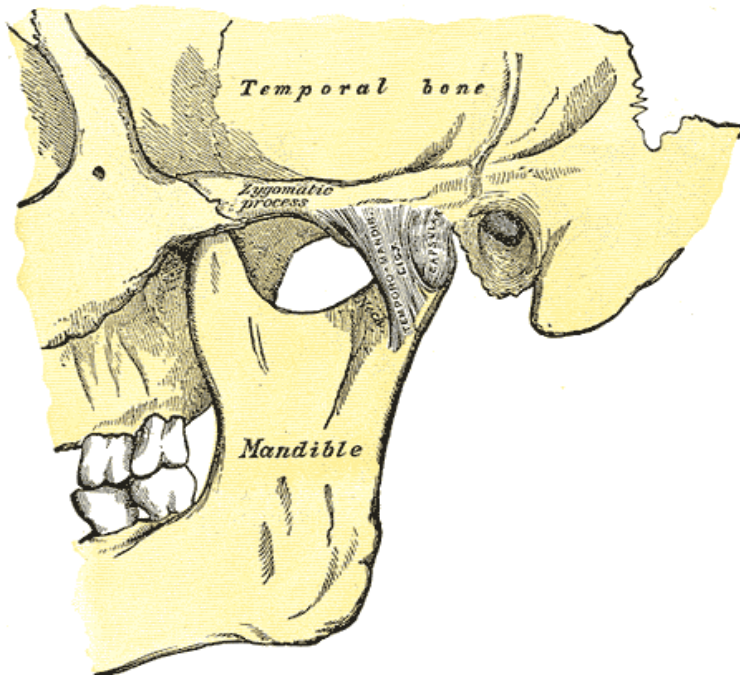


Fig. 2. Lateral view of TMJ (Courtesy: Gray's anatomy).

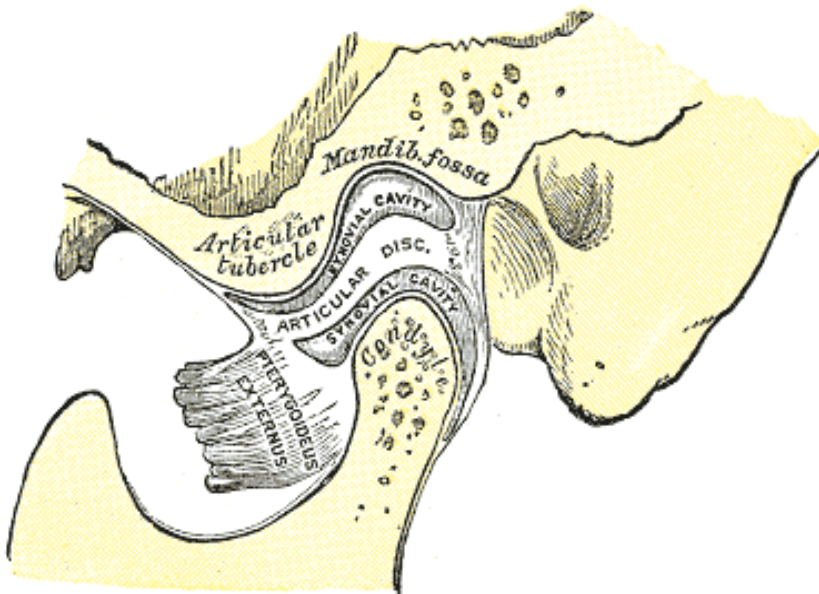


Fig. 3. Sagittal section of the articulation of the mandible. (Courtesy: Gray's anatomy).

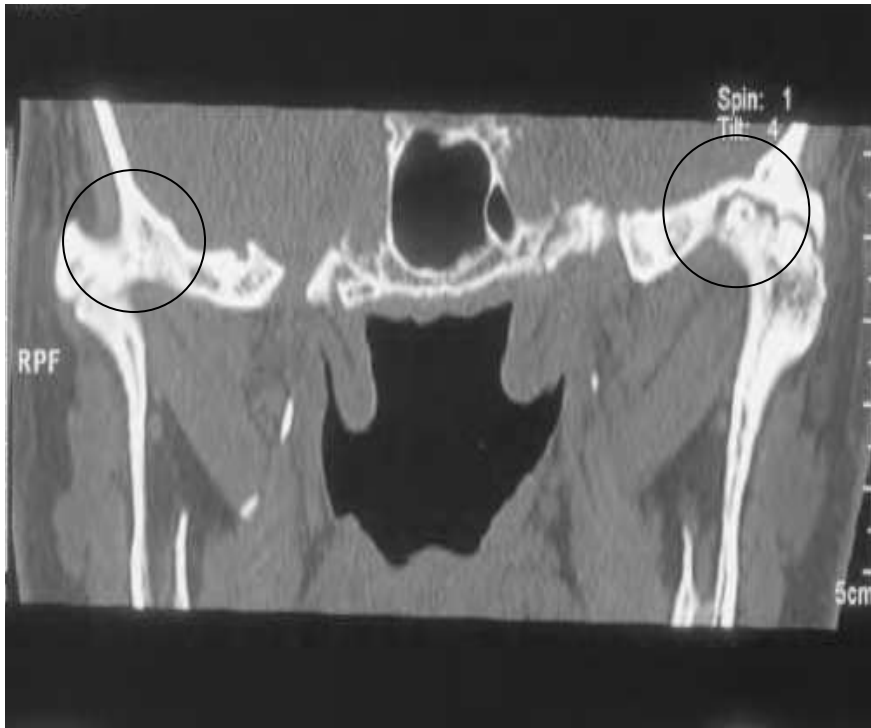

Fig. 4. CT scan shows complete ankylosis of bilateral TMJs in AS (marked areas showing reduced joint space and fusion of condylar head with glenoid fossa).

4. Signs and symptoms [4, 18]

- Chronic pain in the muscles of mastication described as a dull ache, typically unilateral may become bilateral in later stages.
- Pain may radiate to the ear and jaw and is worsened with chewing
- Headache and/or neck ache: In some cases, patients may complain of headache without localized pain in the temporomandibular joint.
- A bite that feels uncomfortable or different from usual
- Associated neck, shoulder, and back pain
- Increasing pain over the course of the day
- Limitation of jaw opening (normal range is at least 40 mm as measured from lower to upper anterior teeth) worsens as the disease progresses.
- Clicking or popping in the TMJ
- Tenderness to palpation of the TMJ

5. Diagnosis

This problem is diagnosed through a combination of clinical history, examination, imaging and the finding of HLA-B27 in the blood.

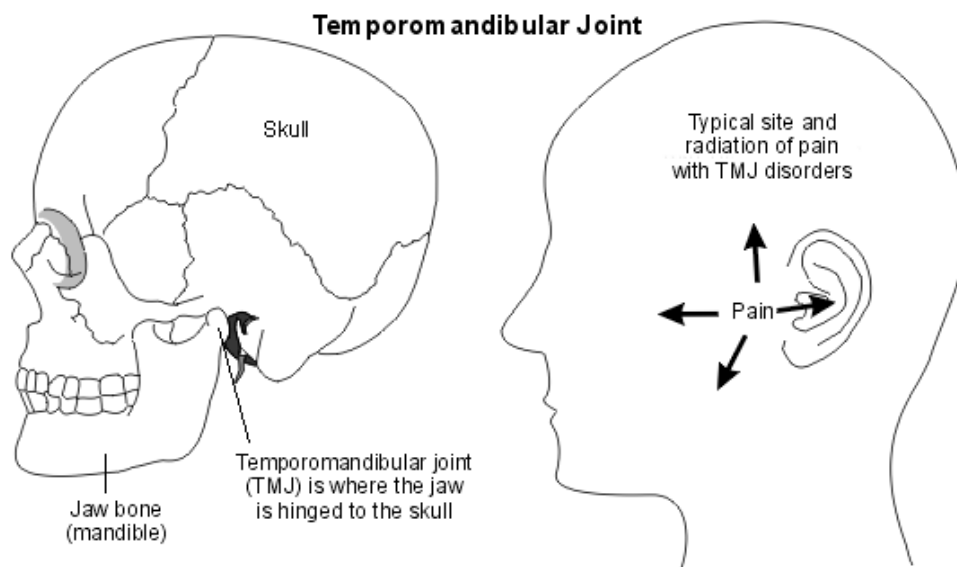


Fig. 5.

Radiographic findings in TMJ depend on the etiology, in cases of AS, rheumatoid arthritis and seronegative spondyloarthropathies, plain films show erosions, osteophytes, subchondral bony sclerosis, and condylar-glenoid fossa remodeling[1].It is difficult to to differntiate AS of TMJ with other degenerative conditions affecting this joint as there is significant correlation between the radiological findings of AS and other degenerative disorders[19]CT scans can explore both bony structures and muscular soft tissues. Of interest, there is utility with cone beam computed tomography (CBCT). The patient is scanned with the mouth open and closed. Specifically, CBCT can aid in the diagnosis of this condition along with history and physical examination.

Magnetic resonance imaging (MRI) is now clearly established as a sensitive and specific tool to detect sacroiliitis [20] but minimal literature found on MRI sensitivity of TMJs in AS hence MRI should be used as the study of choice if TMJ articular or meniscal pathology is suspected and an endoscopic or surgical procedure is contemplated.

Diagnostic arthroscopy is an invasive diagnostic approach and should be used mainly in patients suffering from internal TMJ derangements recalcitrant to conservative measures.TMJ can be approached via pre auricular incisions.

6. Management

The treatment modalities mainly aim for relief of the symptoms and may be to prevent the progression of the disease [21]. The management of AS includes non-pharmacological, pharmacological, invasive and surgical interventions that should be tailored to each patient's disease manifestations, current symptoms, clinical findings and prognostic indicators [22]. The non-surgical treatment of temporomandibular disorder secondary to AS continues to be the most effective way of managing over 80 per cent of patients who present with symptoms of temporomandibular pain and dysfunction. Non-steroidal anti-inflammatory drugs (NSAIDs) are recommended as first-line pharmacological treatment.

7. Non-pharmacological treatment

Non-pharmacological treatment of AS includes fabrication of intra-oral splint, physiotherapy and patient education. The most recent systematic review of physiotherapy for AS reviewed six randomised controlled trials (RCTs), showing that home exercise improved function in the short term compared with no intervention.

Fabrication and insertion of an Intra-oral Orthotic (also known as splint or bite-guard):

The purpose of these Orthotics, which may be fitted to either the upper or lower jaws, and in some cases to both, is to re-position the condyle head in the joint space to a more normal position, thereby relieving the stresses, and pressures, being placed on the tissues of the joints, and their related supporting structures allowing them to heal.

Physiotherapy Therapy: These treatments might include Ultra-sound, TENS (transcutaneous electrical nerve stimulation) and home exercises.

Ultrasound therapy is part of a physical therapy treatment using sound waves at a remarkably exorbitant frequency to penetrate the skin deep to the soft tissue of painful area. It involves employing a hand held probe provided a rounded make every effort which is attached to an ultrasound machine. A gel would be rubbed onto the skin and the probe head will be moved over the affected area in small circular movements. The high-frequency (ultrasonic) waves are produced by vibration on the run of the probe. The waves travel with the skin bringing about vibration to the tissue in the affected area. The vibration causes a heating up of the tissue that has a beneficial effect on the TMJ. The ultrasound therapy is safe when administered by a professional or person who has had training as it can have its dangers of skin burns.

TENS in which a low voltage, low amperage current is applied to the preauricular region which is to relax the masticatory muscles, which are in a state of hyperactivity, fatigue or in spasm secondary to pain. It is like an electronic massage of the facial muscles.

In exercise rehabilitation program, patient has to roll back the tongue to touch the roof of the mouth and asked to open and close the jaw by holding the tongue in same position. In another technique patient is asked to slowly open and close the mouth by keeping the palm of the hand against chin with gentle pressure. These exercises mainly aid in improving the mouth opening and to strengthen the muscles of mastication and TMJ ligaments.

Patient education: has been shown to have short term benefit for function in AS in one controlled trial. There are no studies examining the effect of education on pain. Education

and behavioural therapy have, however, been shown to be beneficial for other outcomes such as motivation and anxiety. Patient associations and self help groups have not been studied for their effect on pain or functional outcomes.

8. The pharmacological management

The pharmacological management of AS of TMJ is essentially same as general management of AS which include Nonsteroidal Anti-inflammatory Drugs (NSAIDs), Coxibs, and Corticosteroids. Literature also shows use of Disease-Modifying Antirheumatic Drugs (DMARDs) and anti-tumour necrosis factor (TNF) agents are recommended in the case of NSAID failure. There is insufficient evidence to support or not support the effectiveness of the reported drugs for the management of pain due TMD (Temporo-Mandibular Disorders). There is a need for high quality RCTs to derive evidence of the effectiveness of pharmacological interventions to treat pain associated with TMD [23] However it has been noticed that most patients respond well to medications given to reduce pain and inflammation, combined with mouth opening exercises to maintain adequate mouth opening and strengthen muscles of mastication to counteract possible ankylosis.

9. The surgical management

The surgical management is indicated in patients with marked trismus (decreased mouth opening) and in case of failure of other non surgical modalities. The surgical treatment may include injection of steroid, joint lavage and total joint replacement. TMJ intra-articular steroid injections use 0.5-1ml of Triamcinolone acetate or methyl prednisolone which is mixed with normal saline. These injections can be performed under local anaesthesia or general anaesthesia. Many patients reported quick relief of symptoms from steroid injections [24, 25] and joint lavage.

Total joint replacement is considered as a last resort if the other treatment modalities fail. The first TMJ total joint replacement was performed about twenty years ago [26]. The principles, which were learned in total hip and knee replacement, have been successfully applied to the TMJ. Prosthetic replacement of the TMJ is a procedure that has undergone a technological revolution over the last decade. In spite of the high frequency of TMJ involvement, ankylosis secondary to AS seems to seldom ensue, and relatively few patients develop such severe degenerative TMJ disease that they require total joint replacement. This is reflected in the paucity of literature on the topic, with approximately 11 cases reported worldwide involving the TMJs bilaterally [8, 26, and 27].

However, when the TMJ ankylosis occurs, it is an extremely disabling affliction that causes problems with mastication, digestion, speech, appearance, and access to routine dentistry. It also has an impact on the psychological development of the patient with concerns related to an inability to open the mouth. Therefore, in patients with ankylosing spondylitis, the total replacement of the TMJ with an alloplastic joint system has become the treatment of choice. These allow closer reproduction of the natural anatomy, avoids donor site morbidity, decreases the risk of reankylosis, and reduces operation time. Furthermore, they allow for immediate physiotherapy and rehabilitation with consequent increased benefit to the patient. [28].

TMJ concepts prosthesis (formerly Techmedica) has up to 17 years follow-up with 90% success rates [29]. These are computer-aided design/computer-aided manufacture (CAD/CAM) custom-made prostheses constructed on a stereolithographic model following a 3D CT scan. The glenoid fossa component is constructed from titanium mesh bonded to the articular surface of high-molecular-weight polyethylene. The condylar component head is cobalt-chrome alloy, and the remainder of the body is titanium and is secured to the ramus of the mandible by screws. Lorenz also makes a stock prosthesis with similar components to the TMJ concepts prosthesis. Whichever operative strategy is employed, it is important to note that these techniques all rely on aggressive postoperative physiotherapy to maintain optimal results [28].

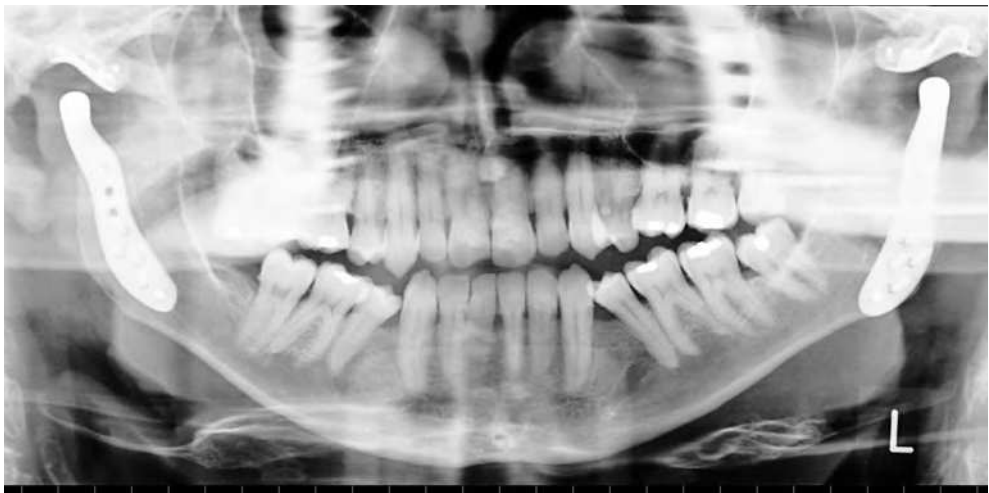

Fig. 6. Dental panoramic view showing bilateral TMJ replacement with TMJ prostheses in AS patient.

10. Discussion

Ankylosing spondylitis has the tendency to involve fibro cartilaginous structures such as symphysis pubis, intervertebral discs, sternomanubrial and sternoclavicular joints. The involvement of TMJ has not been very well investigated and its incidence is disputed. Former studies have reported the involvement of the TMJ in AS between 4% and 32%. However, these studies were either only radiological [31] or used only insufficient clinical [32] or radiological [33] examination methods. Ehrlich (1930) reported on 753 cases, where

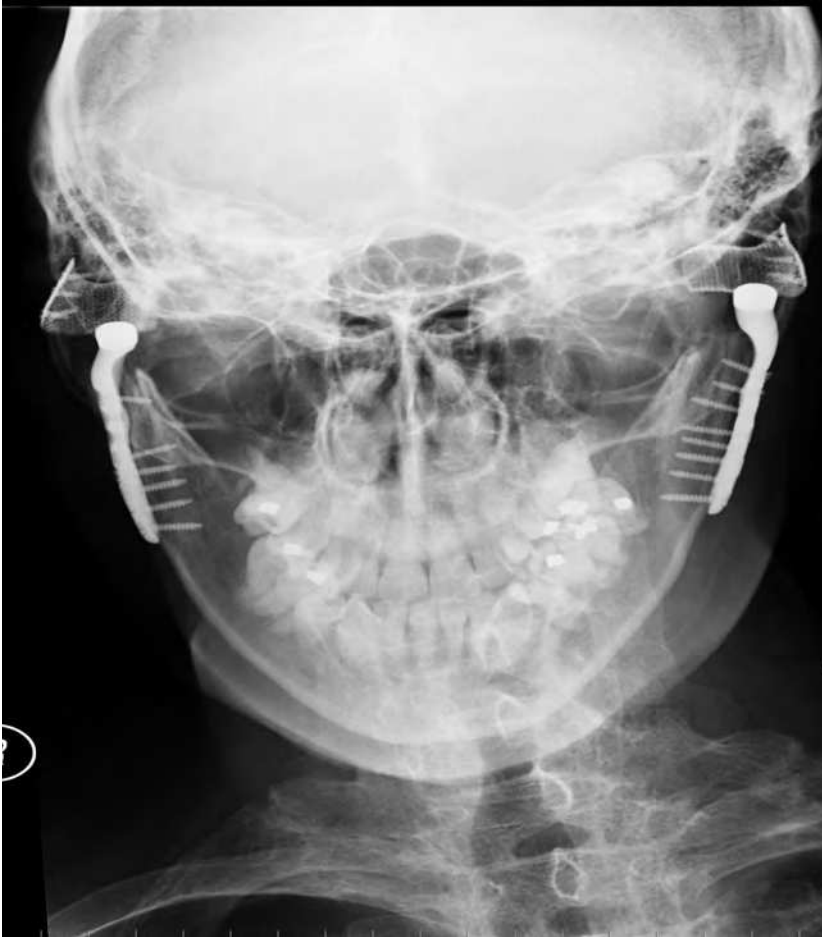

Fig. 7. Postero-Anterior (PA) mandible view showing total TMJ replacement using TMJ concepts prostheses.

he found 124 patients (16.5%). forestier et al (1951) found TMJ involvement in 6% of 200 patients. Nagel (1968) reviewed 1000 patients in which TMJ involvement was only 1%. [17]

Due disparity in clinical and radiological signs suggests that the TMJ rarely seems to be a severe problem for AS patients. It is felt that most TMJ symptoms may be secondary to muscle spasm, occlusal factors, and postural imbalance [34], and the literature is only sparsely populated with cases of true ankylosis of TMJ secondary to AS.

11. Conclusion

In conclusion we recommend routine clinical examinations of TMJ in patients with AS to detect rare complications like severe trismus and ankylosis. Both pharmacological and non pharmacological modalities are found to be effective in the treatment of AS of TMJ

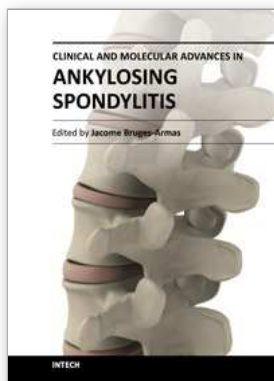
depending on the time and progression. One should have high index of suspicion of TMJ ankylosis in AS for an early detection. This could avoid the need of expensive and technique sensitive joint surgeries. Complementary explorations like joint lavage or arthroscopy should be undertaken in ankylosing spondylitis patients with clinical symptoms suggestive of TMJ lesions in order to establish the diagnosis and initiate treatment and avoid the development of ankylosis forms.

12. References

- [1] M.C. Locher, M. Felder, H.F. Sailer Involvement of TMJ in Ankylosing spondylitis (Bechterew's disease) *Journal of Cranio-Maxillofacial Surgery*, Volume 24, Issue 4, August 1996, Pages 205-213
- [2] Ankylosing Spondylitis affecting TMJ-Case report; *International journal of Oral and maxillofacial Surgery*. Vol. 26, Supplement 1, 1997, Page 162
- [3] Rodríguez-Vázquez JF, et al., JF; Mérida-Velasco, JR; Mérida-Velasco, JA; Jiménez-Collado, J (1998). "Anatomical considerations on the discomalleolar ligament". *J Anat.* 192 (Pt 4): 617-621.
- [4] Robert.J, R.J.Loiselle TMJ Symptoms and Ankylosing Spondylitis. *JADA* 1972; 83:630-633.
- [5] Miller GA, Page HL Jr, Griffith CR. Temporomandibular joint ankylosis: Review of the literature and report of 2 cases of bilateral involvement. *J Oral Surg* 1975; 33(10): 792-803.
- [6] Guralnick WC, Kaban LB. Surgical treatment of mandibular hypomobility. *J. Oral Surg* 1976; 34(4): 343-8.
- [7] Figueroa AA, Gans BJ, Pruzansky S. Long-term follow-up of mandibular costochondral graft. *Oral Surg Oral Med Oral Pathol* 1984; 58(3): 257-68.
- [8] Moriconi ES, Popowich LD, Guernsey LH. Alloplastic reconstruction of the temporomandibular joint. *Dent Clin North Am* 1986; 30(2): 307-25.
- [9] Kaban LB, Perrott DH, Fisher K. A protocol for management of temporomandibular joint ankylosis. *J Oral Maxillofacial Surg* 1990; 48(11): 1145-51; discussion 1152.
- [10] Mauno Kononen, Bengt Wenneberg: Craniomandibular Disorders in Rheumatoid Arthritis, Psoriatic Arthritis and Ankylosing Spondylitis, *ACTA ODONTOL SCAND*; 1992,50:281-287.
- [11] Chowk TK, Ng.WL. *Scand J Rheumatology*. 1997; 26(2): 133-4.
- [12] Fonseca RJ. *Oral and Maxillofacial Surgery: Temporomandibular Disorders*. Philadelphia (PA): W.B. Saunders Company; 2000. p. 309-13.
- [13] Ju Seop Song, Kwan Joon-Koh, ankylosing spondylitis associated with bilateral TMJ ankylosis. *Korean Journal of Oral and Maxillofacial Surgery* 2000,30. 217-222.
- [14] Khan MA. 2002. *Ankylosing spondylitis: The facts*. Oxford University Press. ISBN 0192632825.
- [15] Benazzou S, Maagoul R *Rev Stomatol Chir Maxillofac*. 2005 Nov; 106(5): 08-10.
- [16] Qin L, Long X, Li X, Bilateral fibrous ankylosis of temporomandibular joint associated with ankylosing spondylitis: a case report. *Joint Bone Spine*. 2006 Feb 17;

- [17] Manemi R V, Fasanmade A, Revington PJ; Bilateral ankylosis of the jaw treated with total alloplastic replacement using the TMJ concepts system in a patient with ankylosing spondylitis; *Br J Oral Maxillofac Surg*. 2009 Mar;47(2):159-61.
- [18] Vivian Tsai; Rick Kulkarni; Temporomandibular Joint syndrome; <http://emedicine.medscape.com/article/809598-overview>. Feb 2010
- [19] L. Miia J. Helenius , DDS, MB,a Dorrit Hallikainen, MD, DDS,b Ilkka Helenius, MD, PhD, Clinical and radiographic findings of the TMJ in patients with various rheumatic diseases. *Oral Surg Oral Med Oral Pathol Oral Radiol Endod* 2005; 99:455-63.
- [20] Saeed A. Shaikh, MD, Ankylosing spondylitis: recent breakthroughs in diagnosis and treatment *J Can Chiropr Assoc*. 2007 December; 51(4): 249-260.
- [21] Mansour.M, Cheema. G.S,Naqw A, Greenspan.A,Ankylosing spondylitis: a contemporary perspective on diagnosis and treatment. *Semin Arthritis Rheum*. 2007 Feb; 36(4):210-23. Epub 2006 Sep 29
- [22] <http://www.spine-health.com/conditions/arthritis/ankylosing-spondylitis-physical-therapy-and-exercise>.
- [23] Mujakperuo HR, Watson M, Morrison R, Macfarlane TV; Pharmacological interventions for pain in patients with temporomandibular disorders. *Cochrane Database Syst Rev*. 2010 Oct 6;(10):CD004715
- [24] B Arabshahi, et al, *Arthritis Rheum*. 2006;
- [25] S Ringold, et al. *J Rheumatol*. 2008; 35(6):1157-1164
- [26] Speculand B, Hensher R, Powell D, Total prosthetic replacement of the TMJ: experience with two systems 1988-1997, *The British Journal of Oral & Maxillofacial Surgery* 38,360-369;2000
- [27] Andrew M. Felstead, Peter J. Revington, Surgical management of TMJ Ankylosis in Ankylosing spondylitis, *Int J Rheumatol*. 2011;Published online 2011 March 24. doi: 10.1155/2011/854167
- [28] Roychoudhury A, Parkash H, Trikha A. Functional restoration by gap arthroplasty in temporomandibular joint ankylosis a report of 50 cases. *Oral Surgery, Oral Medicine, Oral Pathology, Oral Radiology, and Endodontics*.1999;87(2):166-169
- [29] Mercuri LG, Edibam NR, Giobbie-Hurder A. Fourteen-year follow-up of a patient-fitted total temporomandibular joint reconstruction system. *Journal of Oral and Maxillofacial Surgery*. 2007;65(6):1140-1148.
- [30] Agarwal A. Preankylosing spondylitis. In: Moll JMH, editor. *Ankylosing Spondylitis*. Edinburgh, UK: Churchill Livingstone; 1980. pp. 69-75
- [31] Maes HJ, Dihlmann W. Affection of the temporomandibular joints in spondylitis ankylopoetica Befall der Temporomandibulargelenke bei der Spondylitis ankylopoetica. *Fortschritte auf dem Gebiete der Rontgenstrahlen und der Nuklearmedizin*. 1968;109(4):513-516. [PubMed]
- [32] Resnick D. Temporomandibular joint involvement in ankylosing spondylitis. Comparison with rheumatoid arthritis & psoriasis. *Radiology*. 1974; 112(3):587-591. [PubMed]

- [33] Davidson C, Wojtulewski JA, Bacon PA, Winstock D. Temporomandibular joint disease in ankylosing spondylitis. *Annals of the Rheumatic Diseases*. 1975;34(1):87-91. [PubMed]
- [34] Crum RJ, Loiselle RJ. Temporomandibular joint symptoms and ankylosing spondylitis. *The Journal of the American Dental Association*. 1971;83(3):630-633. [PubMed]



Clinical and Molecular Advances in Ankylosing Spondylitis

Edited by Dr. Jacome Bruges-Armas

ISBN 978-953-51-0137-6

Hard cover, 164 pages

Publisher InTech

Published online 22, February, 2012

Published in print edition February, 2012

The first section of the book entitled Clinical and Molecular Advances in Ankylosing Spondylitis is a review of the clinical manifestations of Ankylosing Spondylitis (AS) and Spondyloarthritis (SpA). The book includes chapters on Bone Mineral Density measurements, two chapters on the temporomandibular joints, axial fractures, clinical manifestations, diagnosis, and treatment. Molecular genetics and immune response are analyzed in the second section of the book; information on HLA-B*27, other MHC genes and the immune response of AS patients to bacteria is reviewed and updated. Two chapters are dedicated to recent information on non-MHC genes in AS susceptibility, and to new data on disease pathways generated from gene expression studies on peripheral blood.

How to reference

In order to correctly reference this scholarly work, feel free to copy and paste the following:

Raveendra Manemi, Rooprashmi Kenchangoudar and Peter Revington (2012). Ankylosing Apondylitis of Temporomandibular Joint (TMJ), Clinical and Molecular Advances in Ankylosing Spondylitis, Dr. Jacome Bruges-Armas (Ed.), ISBN: 978-953-51-0137-6, InTech, Available from:

<http://www.intechopen.com/books/clinical-and-molecular-advances-in-ankylosing-spondylitis/ankylosing-spondylitis-of-temporomandibular-joint-tmj>

INTECH

open science | open minds

InTech Europe

University Campus STeP Ri
Slavka Krautzeka 83/A
51000 Rijeka, Croatia
Phone: +385 (51) 770 447
Fax: +385 (51) 686 166
www.intechopen.com

InTech China

Unit 405, Office Block, Hotel Equatorial Shanghai
No.65, Yan An Road (West), Shanghai, 200040, China
中国上海市延安西路65号上海国际贵都大饭店办公楼405单元
Phone: +86-21-62489820
Fax: +86-21-62489821

© 2012 The Author(s). Licensee IntechOpen. This is an open access article distributed under the terms of the [Creative Commons Attribution 3.0 License](#), which permits unrestricted use, distribution, and reproduction in any medium, provided the original work is properly cited.