

The Effect of Breast Reconstruction on Maintaining a Proper Body Posture in Patients After Mastectomy

Sławomir Cieśla¹ and Małgorzata Bąk²

¹*Oncoplastic Division of General Surgery Department Hospital Leszno,*

²*Institute of Physical Education, Higher Vocational State School Leszno, Poland*

1. Introduction

Breast cancer remains the most common malignant neoplasm in women. Surgical treatment options include radical mastectomy (RM), breast conservative treatment (BCT), radical mastectomy and immediate (IBR) or delayed breast reconstruction (DBR). Treatment of breast malignancies is currently focused on reducing surgical intervention while still eradicating the neoplasms.

Sentinel lymph node biopsy (SLNB) has been explored as a method to determine the need for axillary lymph node dissection (ALND) in breast cancer patients. In theory, a properly performed negative SLNB should accurately identify those patients without axillary node involvement, thereby obviating the need for a more morbid ALND. The risk of arm morbidity, particularly lymphedema, chronic pain, shoulder-arm dysfunctions and other complications is significantly lower after SLNB than ALND.

Despite an increasing proportion of indications to surgical intervention with breast conservation in early breast cancer stages, as many as 10% of stage I and 30% of stage II patients do not qualify for BCT (Morrow M et al., 2001). In addition to difficulties in offering each patient a 5-week course of radiotherapy, the number of unwilling patients, and the difficulties in staging the disease before surgery, there are many women who still undergo RM in early stages of the disease (Parker PA et al., 2007).

A strong family history of breast or ovarian carcinoma indicates a genetic predisposition to the disease and should prompt investigation of mutations in the BRCA gene. Women with identified BRCA1 or BRCA2 mutation have a high risk of breast cancer and are prime candidates for prophylactic bilateral total mastectomy. Still currently in Europe 40% to 60% of women diagnosed with breast cancer undergo amputation (Ferlay et al., 2007). In such cases, breast reconstruction minimalises scarring. Most women, who have had a mastectomy and are in otherwise good health, are candidates for breast reconstruction that can be done immediately (IBR - immediate breast reconstruction) or in delayed fashion (DBR - delayed breast reconstruction). Nowadays the rate of breast reconstruction after mastectomy ranges between 8% to 42%. This wide variation is attributed to geographic

locations, ethnicity, patient's age, education & social status as well as cancer stage. The goal of breast reconstruction is to create a breast mound that matches the opposite breast and to achieve symmetry (Rietman et al., 2003; Elder et al., 2005). Breast reconstruction attempts to restore a patient's breast(s) as closely as possible to pre-mastectomy size, shape and appearance.

There are several surgical methods used to perform breast reconstruction and they include:

- patient's own tissues only (TRAM, LD, DIEP, free flaps)
- tissue expanders or silicon prosthesis
- connecting both procedures -using autologous tissue and implants for breast reconstruction.

To date, the benefits of breast reconstruction have been mainly associated with the improvement of quality of life and breast appearance, both factors leading to better self-esteem and emotional well-being in women after mastectomy.

There have been almost no attempts to determine the effect of mastectomy and breast reconstruction on maintaining the proper body posture after the surgery. A huge number of women after mastectomy complain of increased back pain a few months to years after surgery even when they use external breast prosthesis in a professionally fitted bra or self-adhesive directly stack to the chest wall. Moreover recent investigations show that only 75% of mastectomised women wear the external breast prosthesis every day and only a few percent during the night (Bağ et al., 2000). In addition the full weight of the external prosthesis is carried by the bra, which causes higher pressure from the straps to the shoulder, pulling the shoulder down at the operated side.

2. Proper body posture

The proper body posture is vital to human health. It is closely linked to balance and fundamentally affects the key functions of a human being: the correct movement, correct breathing and efficient cardiovascular system.

Disturbances in proper body posture can lead to many health issues like scoliosis, headaches, dizziness, lower back problems, stuck energy feeling, functional impairment of respiratory and circulatory systems.

Posture is the position in which human body holds upright against force of gravity while standing, sitting, moving or lying down. Good posture requires the least amount of muscle activity to maintain an upright position and people have to train their bodies to place the least strain on supporting muscles and ligaments during movement or weight-bearing activities. Proper posture keeps bones and joints in the correct alignment so that muscles are being used properly, helps to decrease the abnormal wearing of joint surfaces that could result in arthritis, decreases the stress on the ligaments holding the joints of the spine together, prevents the spine from becoming fixed in abnormal positions and reduces fatigue because muscles are being used more efficiently, allowing the body to use less energy, avoiding strain, backache and muscular pain. The posture constantly changes depending on the human activity; the musculoskeletal system is constantly working to maintain alignment whether sitting or standing for long periods of time or dancing.

In maintaining a good posture, two groups of factors are important:

- related to the anatomy: bones of the spine, joints, intervertebral discs, nerves and soft tissues - ligaments, fascia and muscles
- associated with managing the above structures: central and peripheral nervous system that keeps changing and adjusting the tension of individual muscle groups, both in motion and at rest (while standing, sitting and lying).

The spine allows the agile movement of the human body. It not only supports the body and all its organs, it also protects the sensitive and delicate spinal cord and spinal nerves exiting it. It is composed of 24 freely movable segments and is taxed by activities of daily living. Every activity, even breathing, demands a movement of the spine, ribs, and all attachments. The spine gives the human structure both strength and agility. A humans "biped" position gives the advantage of agility, leverage and mobility, while also creating certain structural stresses. The human body must adapt to the continual stress of gravity in order to maintain its balance.

Posture affects and moderates every physiologic function from efficient breathing to hormonal production. It allows musculo-skeletal system to hold the body parts in place, provides space for vital organs to function at optimal efficiency and promotes efficient functioning of the nervous system. Spinal pain, headache, mood, blood pressure, pulse and lung capacity are among the functions most easily influenced by posture. The most obvious benefits of good posture are efficiency and comfort.

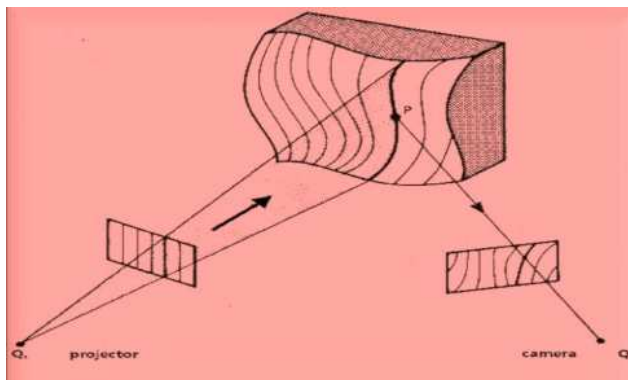
Yet, because of the interrelationship of the structural (bone) and functional (organ) systems of the body, posture is also a factor that can impact health. For example, poor posture compromises the movements of the rib cage and does not allow the lungs to function at maximum capacity in order to bring much needed oxygen to the tissue and eliminate carbon dioxide wastes. Other vital organs of the body are also restricted when body posture is improper, creating structural stress. By reducing these postural imbalances we can start to improve all functions of the body and improve our health as well as quality of life.

3. 3D measurement techniques for human body surface scanning

3.1 Photogrammetry

Photogrammetry is one of the many fields of three dimensional measurement associated with surveying. The theoretical basis of the measurements was Moire contourography, described in 1880s in optics. (Takasaki H., 1970)

A ray of white light hitting an uneven surface leads to this light reflecting at various degrees. Photogrammetry has been used for medical applications since midway through the nineteenth century, and is now beginning to regain its past popularity due to recent developments in real time instrumentation. Medical photogrammetry is now part of the broader field known as biostereometrics. The major shift in the analytical approach to photogrammetry came about by considering each image as representing a bundle of rays from the center of the lens system through points on the image to the object photographed. These individual rays could be corrected for distortion in the lens system, the focal length of the lens and the geometry of the film or digital chip. With several images from different stand-points, the bundles of rays would then intersect in space where they would have struck the real object. (Meadows DM et al., 1970) The reflected image was registered by a camera, digitally configured and analysed by a special computer program.



Picture 1. The principle of photogrammetry

Structured light projection and laser scanning represent the optical measurement technologies mostly employed for the three-dimensional digitalisation of the surface of the human body. They are both based on the same rule, namely triangulation, in the way that light structures are projected onto the human body, whereas light sensors acquire the scene; by known geometry of the set-up, 3D information can then be drawn from the imaged data. Digital imaging has greatly improved and changed photogrammetry because the “metric” parameters that were originally engineered into the cameras are now solved, and compensated for, by software. It is a great advantage to use such systems in combination with analysis and measurement performed by computer software for the comparison between pre- and post-operative shape of human body. These systems allowed for real-time registration and comparison of the resultant changes in body posture of the examined women. Two positive aspects of Moire contourgraphy are the non invasive nature of the test and the possibility to perform repeated examinations over time. (Wong HK et al., 1997)

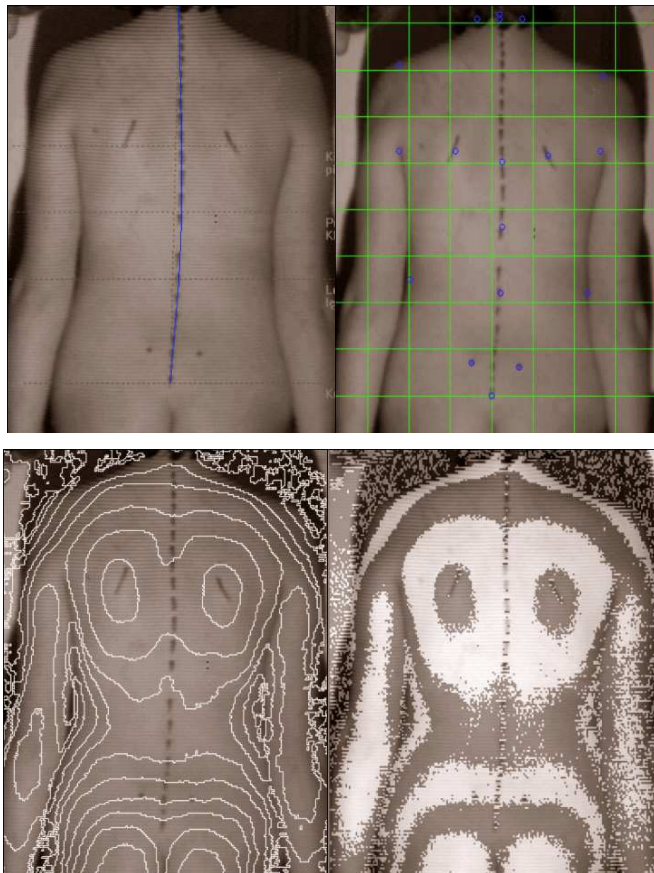
3.2 Use of moire contourgraphy

The first results of investigations that compared the changes in proper body posture in two groups of women (after radical mastectomy (RM) and women who underwent immediate breast reconstruction (IBR)) were published in 2004 and then 2006 and 2010 (Cieśla & Bąk, 2004, 2006; Cieśla & Połom, 2010).

All women before and after surgery were examined to determine their body posture using three-dimensional (3D) analysis of the body surface with photogrammetry. This method involves objective anthropometric measurements based on the computer analysis of the 3D image constructed of the spine of each examined woman. This non-invasive and non-burdening manner of obtaining measurements allowed for multiple measurements in each woman pre and post-operatively. Before taking a measurement, characteristic bony structures were marked on the patient’s back: the C7 to S1 spinous processes, the lower borders of the scapulae, and the superior posterior iliac spines.

The measurements were taken in specific, reproducible conditions, accounting for the same parameters of the visual apparatus, at a constant distance between the camera and the patient. This examination allowed for the measurement of 54 parameters in the coronal,

sagittal, and transverse planes, which made it possible to evaluate the body posture of the patients objectively.

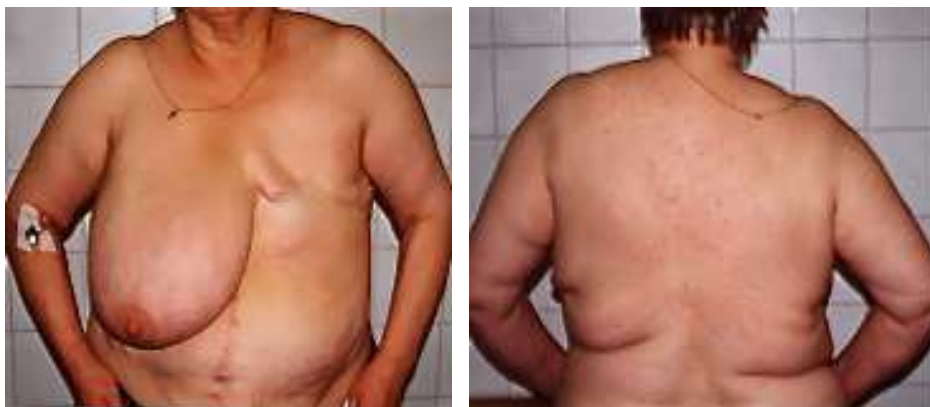

Picture 2. Patients' images obtained from studies using computerised photogrammetry

3.3 Asymmetry of body posture after mastectomy

Every human body is unique and from the moment we are born various factors (gravity and the activities we engage in) alter our posture therefore muscle imbalance and misalignment will affect all of us to a greater or lesser extent. It also has to be taken into account that the posture and health change during our lifetime under the influence of internal (degree of overall fitness, training, illness) and external factors (trauma). Radical surgical treatment of patients with breast cancer may contribute to a locomotor dysfunction. Damaged muscle weakness, pain associated with extensive postoperative wound, reflexive attempt to compensate for the absence of the breast - "a complex of half woman" as well as soft tissue fibrosis as a result of radiotherapy are the direct causes of adverse changes in the posture of women after mastectomy (Al Ghazar et al., 2000; Janni et al., 2001). Research conducted on a large group of patients showed the presence of posture defects in 82.3% of women after

breast amputation compared with only 35.1% in healthy group women. (Bąk & Cieśla 2009) The research confirmed clearly abnormal posture in women after radical mastectomy that appeared in all three planes: sagittal, coronal and transverse. Women after mastectomy have an increased tendency to exhibit kyphotic posture, tilt the trunk forward and extend kyphosis in the thoracic spine. Even with properly conducted intensive postoperative rehabilitation, it is observed that patients demonstrate a constant tendency to tilt forward while the shoulder on the operated side is lifted, ejected forward and medially. In the frontal plane, the symmetry disturbances of bony points are clearly visible especially of the shoulder heights on both sides, the position of the blades, twist of the pelvis and the deviation of vertebrae spinous from the vertical line.



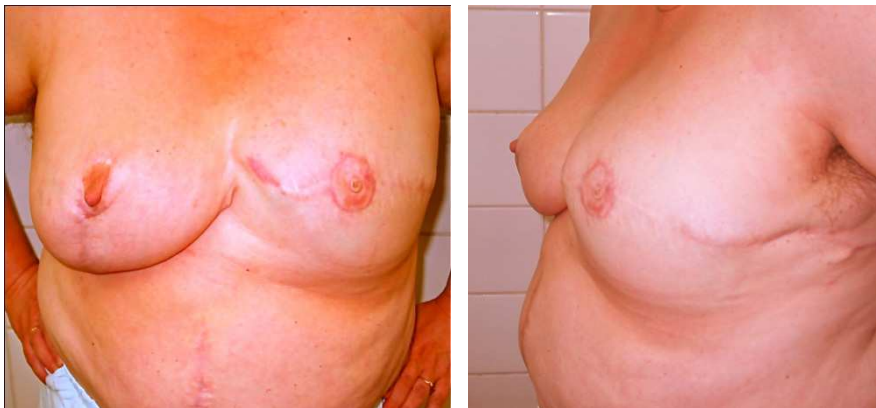Picture 3-4. Photographs showing the typical abnormalities of posture in women after radical breast amputation. Fifty two years old woman shown two years after radical mastectomy for cancer.

The asymmetry of the buttocks in women after RM was studied before. The results of these studies indicated that the asymmetry was related to the position of the shoulders and scapulae. In cases of radical mastectomy (RM) without breast reconstruction, external prosthesis worn as a special bra was a significant factor in the degree of buttock asymmetry. Women who wore such prosthesis regularly, both during day and night, demonstrated a lesser degree of body posture disturbances. It is also necessary for the patient to undergo rehabilitation to minimise the changes in body posture (Kopanski et al., 2003, Rostkowska et al., 2006).

In our study it was shown that body posture disturbances significantly affect the vertebral column in patients after RM. The scapula on the operated side was higher than the scapula on the un-operated side. Women who were older at the time of surgery more frequently have a right rotation to their buttocks and their pelvis was located more posterior on the right side. The spinous process with the greatest deviation from a vertical line perpendicular to the ground was expressed to a greater degree in women after mastectomy. This deviation was most significant in the lower thoracic spine (Th 7-12) of older women, while in younger women it was at a higher part of the thoracic spine (Th 1-6). Another interesting clinical observation is the change in body posture depending on time passed after the surgery. In the early postoperative time, there is a tendency to thrust the buttocks forward, and as more

time passes after the surgery the buttocks are thrust posteriorly. This is due to the fact that thrusting the buttocks forward in the early postoperative period has an aesthetic and psychological effect, which passes over time (Bąk & Rostkowska, 2000).

The recent studies have shown a statistically significant disturbance of proper body posture in women after mastectomy. These disturbances have even been demonstrated in women who underwent intensive rehabilitation. It has also been noted that these disturbances in body posture are decreased in women who used an external prosthesis not only during the day but also at night, while sleeping (Bąk & Rostkowska, 2000).



Picture 5-6. Photographs showing women from picture 1-2 four years after radical mastectomy for cancer and two years after delayed left breast reconstruction with Becker-25 (800cc) expander-prosthesis and Mc Kisson reduction of the right breast.

This leads to the assumption that breast reconstruction may have a positive effect in maintaining the proper body posture in women after mastectomy.

4. The influence of breast reconstruction on correct body posture

4.1 Reconstruction with prosthesis and expander-mammary prosthesis

A common method of breast reconstruction after breast surgery is the use of silicon prostheses, expanders or expander-prostheses. They are placed under pectoralis major muscle in a special muscle pocket including a part of serratus anterior muscle and even the upper part of rectus abdominis muscle. A great advantage of this kind of reconstruction is the use of the breast's shape, its weight and a high flexibility of silicone prosthesis. This solution limits the surgery to the wall of the chest of the breast after mastectomy. The most important elements of implant breast reconstruction are the inframammary fold, the inferior pole, the superior slope, and the projection (Cordeiro & McCarthy, 2006). However, in this type of breast reconstruction it is necessary to incorporate the above mentioned chest muscles in the process of shaping the new breast.

4.1.1 Pectoralis major muscle

Pectoralis major muscle (musculus thoracic major) is a large, wide and triangular muscle that belongs to a group of superficial muscles of the chest. It is innervated by the medial

pectoral nerve and lateral pectoral nerve. A superficial lamina of thoracic fascia covers its front surface and separates the muscle from the subcutaneous layer of adipose tissue and, in women, from the mammary gland. The rear surface of the pectoralis major muscle is covered through chest deep fascia. Medial part of pectoralis major has three trayers. The upper part - clavicles (pars clavicularis) is attached to the medial portion of clavicle. It is separated from the sterno-rib part by inter-rib furrow (sulcus interpectoralis). The central part - sterno-rib (pars sternocostalis) attaches on the front surface of the sternum and to rib cartilage from I to VI. Lower part - abdominal (pars abdominalis) attaches to the blade anterior abdominal rectus sheath. Part of the lateral muscle tendon passes into a common tendon attached to the greater tubercle crest of the humerus. The lower part of the pectoralis major forms axillary folds forward (plica axillaris anterior). The contraction of the whole muscle moves the shoulder blade forward, drops and draws an arm moving it slightly forward and making its rotation inside. Pectoralis major muscle is also an auxiliary respiratory muscle.

4.1.2 Serratus anterior muscle

Serratus anterior muscle (musculus serratus anterior) is located on the lateral chest wall. This flat, quadrangular muscle innervated by long thoracic nerve C₅₋₈ is one of the largest muscles in humans and belongs to the group of superficial muscles of the chest. From the front it has wide trayers in the shape of ten saw blades originating on the outer surface of the upper nine ribs. It is placed to the rear surface of the chest, and inserts along the entire anterior length of the medial border of the scapula. Anatomically, there are three parts of the serratus anterior muscles. The thickest and shortest superior part spans between the first and second rib and rib side of the superior angle of scapula. The thinnest intermediate part spreads out between the second and third rib and the medial border of the scapula. The inferior part stretches between the fourth and the ninth rib and the rib side of the inferior angle. The superior part is an antagonist of the middle trapezius muscle pulling the shoulder joint forward. The inferior part pulls scapula downward and the lower angle of the shoulder forward and laterally toward the armpit while setting the acetabulum articular shoulder upwards, which allows raising the upper limb above the level. In addition, serratus muscle pushes the shoulder blade against the chest wall. It is an auxiliary inspiratory muscle.

4.1.3 Abdominal rectus muscle

Abdominal rectus muscle (musculus rectus abdominis) is a muscle interoperating with a flat abdominal muscles, diaphragm and perineal muscles in the formation of the abdominal prelum. His initial trayers are the rib cartilage V-VII, appendix of the sternum and rib-gladioli ligament, and the end - pubic symphysis and pubic crest of the pelvic bone. It is prolonged in men in the suspensory ligament of penis (ligamentum suspensorium penis) and the suspensory ligament of clitoridis in women. It is covered by a sheath of the rectus abdominis muscle (vagina musculi recti abdominis). It has so called tendinous *intersections* (intersectiones tendineae). The blood supply is from inferior epigastric artery a terminal branch of the internal thoracic artery. It is innervated by intercostal nerves (Th6-Th12) and is often the first lumbar nerve (L1). Lower and upper abdominal arteries are responsible for vascularisation. Abdominal rectus muscle participates in bending the body, strengthens the abdominal prelum, raises pelvis and lowers the chest and ribs which supports the exhaust function.

BREAST RECONSTRUCTION	Musculus pectoralis major	Musculus serratus anterior	Musculus rectus abdominis	Musculus latissimus dorsi
Implant	+++	+	+	-
Implant+AlloDerm	++	-	-	-
TRAM	-	-	+++	-
Free TRAM	-	-	++	-
DIEP	-	-	+	-
LD	-	-	-	+++
Ms-LD	-	-	-	+
SIEA	-	-	-	-
SGAP	-	-	-	-
IGAP	-	-	-	-

+++ large
 ++ average
 + small

- no importance

TRAM – transverse abdominis muscle flap , Free TRAM - free transverse abdominis muscle flap,

DIEP- deepinferior epigastric perforator flap,

LD - latissimus dorsi flap,

Ms-LD - muscle sparing latissimus dorsi flap,

SIEA- superficial inferior epigastric artery flap,

SGAP - superior gluteal artery perforator flap,

IGAP - inferior gluteal artery perforator flap.

Table 1. The degree of trunk and abdominis wall muscle exploitation in different type of breast reconstruction.

4.1.4 Implantable biomaterials supporting implant coverage

Recent methods of using implantable biomaterials, or patient’s own abdominal rectus fascia or skin flap during simultaneous breast reduction preclude the need for using of the serratus anterior muscle and the rectus abdominis. In this way, not only there is a much greater opportunity to create a natural ptosis even with larger breasts, the possibility of obtaining the symmetry with the natural breast of the opposite side, but also the damage to the muscles of the chest to completely cover the implant is limited to the minimum.

4.1.4.1 Acellular dermal matrix (ADM)

Acellular dermal matrix (ADM) has been used in surgery as soft tissue replacement since 1994. The first report about the use of human acellular dermis in prosthetic breast

reconstruction was in 2005 (Breuing & Warren, 2005). AlloDerm, Neoform or Flex HD are dermal grafts obtained from deceased human donors, which can be used for immediate breast reconstruction as a "sling" to cover the lower outer quadrant of the reconstructed breast, thereby redefining the base and outer limits of the breast. It fuses with the mastectomy flap and serves to put the chest wall muscle on stretch, so that the entire expander or implant is more fully covered. This technique creates a subpectoral and sub-AlloDerm pocket only that completely encloses the breast implant. By tailoring the width of the AlloDerm, it is possible to precisely control the degree of lower-pole fullness. This technique shortens or eliminates the need for tissue expansion.

4.1.4.2 Inframammary fold reconstruction (IFR)

A new approach for inframammary fold reconstruction (IFR) that focuses on the breast and muscles fascial system establishes next very important point in implant breast reconstruction. The inframammary fold is an important landmark that frequently is disrupted or destroyed by modified radical mastectomy.

4.1.4.3 Skin-reducing mastectomy (SRM)

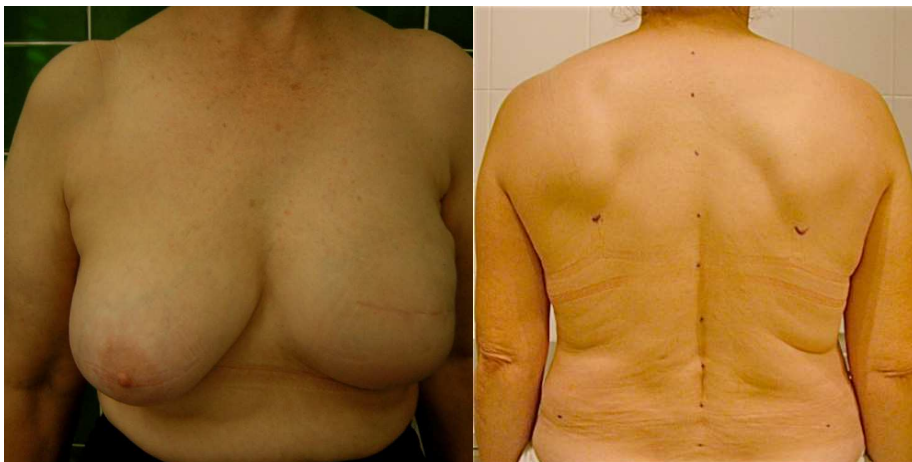Skin-reducing mastectomy (SRM) is a technique that creates a dermomuscular pouch with adequate volume in the lower-medial quadrant and, at the same time, provides satisfactory coverage of the silicone implant. Much of the surgical scarring lies in relatively concealed areas of the breast. (Nava et al., 2011)

It also has a beneficial influence on keeping the right body posture among women after surgery.

4.1.5 The results of the photogrammetric measurements in women after breast reconstruction with Becker prosthesis

The photogrammetric results obtained from women after surgery for breast cancer demonstrate a significant difference in body posture between the patients who underwent immediate breast reconstruction (IBR) and those with radical mastectomy (RM) who never had reconstruction. Prospective studies were performed in a group of women with stage I and II breast cancer operated in 2000-2005 at the Oncoplastic Division General Surgery of the State Regional Hospital Leszno. There were three groups of examined women: A (n=38) – women underwent radical Madden mastectomy, B (n=38) – women underwent skin sparing mastectomy with single stage immediate breast reconstruction (ssm+IBR), C (n=38) healthy women who have not had any surgery before (control group). Groups A and B were comparable in terms of age, body mass index, height, the degree of cancer advancement and comorbidities. All the women qualified for ssm+IBR agreed to this kind of surgery and declared their intention to actively participate in postoperative breast modeling and rehabilitation. This examination allowed for the measurement of 54 parameters in the coronal, sagittal and transverse planes, which made it possible to objectively evaluate the body posture of the patients.

The measurements taken preoperatively, but after clinical diagnosis and qualification to surgical treatment, did not differ significantly in group A (ssm+IBR) and B (RM), either between each other or in comparison to the control group. (Cieśła & Bąk, 2004, 2006; Bąk & Cieśła, 2009)



Picture 7. Photographs showing a fifty six years old woman with breast cancer 2 years after amputation with sparing the skin and simultaneous breast reconstruction using prosthesis ekspander-Becker-35 (565 cc). Visible correct positioning of the shoulders, shoulder blades, pelvis and no deviation from the vertical of vertebral processes of the spine.

Examination of those patients 6 months postoperatively demonstrated a considerable increase in body posture divergence in the patients who had RM without breast reconstruction. Twelve months postoperatively, this body posture divergence was even more obvious and was significantly different from the results obtained from the ssm+IBR and control (healthy women) groups. In the eighteenth postoperative month, the difference between the RM and ssm+IBR groups reached its peak, with the RM group showing even more divergence in body posture. Two years after surgery, there was no further increase in divergence demonstrated by the parameters of body posture in the coronal, sagittal and transverse planes in the patients with RM. It can be therefore assumed that adaptation of the body stabilises approximately 18 months after surgery and does not progress any further. There were no statistical differences between ssm+IBR patients and healthy controls in all five terms of measurements before and after surgery. (Cieśla & Połom, 2010)

There are visible, statistically significant, abnormal postures in the RM group appearing after 6 months with the upward trend until 18 months after surgery. In the group ssm + IBR the abnormal body postures after the surgery were small and did not differ statistically from the control group.

4.2 Autologous breast reconstruction

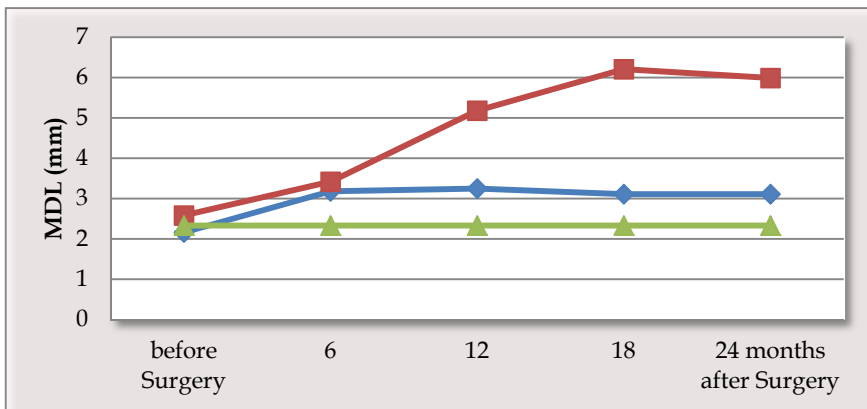
4.2.1 Pedicle flaps

4.2.1.1 Transverse rectus abdominis musculocutaneous flap reconstruction

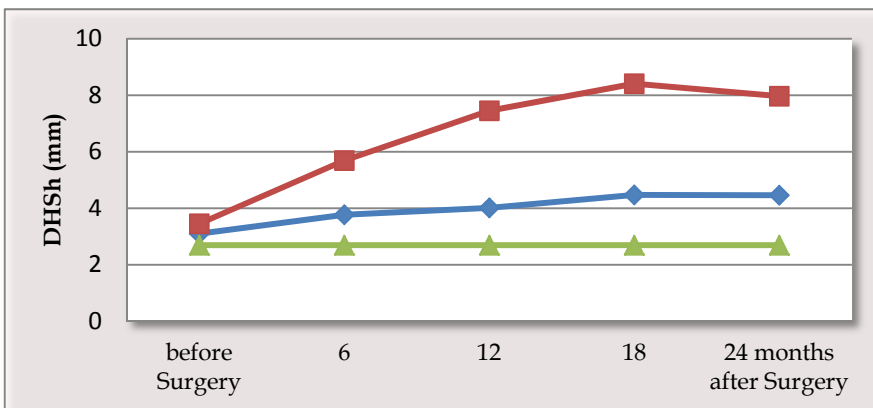
TRAM is still a standard procedure in autologous reconstruction with the use of soft tissues from abdomen in the form of rectus abdominis muscle pedicle skin-muscle flap. As a result, the reconstructed breast is flexible, soft and its shape is similar to the healthy one. However, the use of one or both rectus abdominis muscles for transferring tissues weakens the

abdomen muscle wall and may influence the incorrect static position and therefore body posture. Preliminary unpublished photometric studies seem to confirm this. It will be interesting to find out what is the influence of the TRAM reconstruction on the changes in body posture. A good solution to this problem seems to be the free transfer of own tissues with deep inferior epigastric perforator (DIEP) flap.

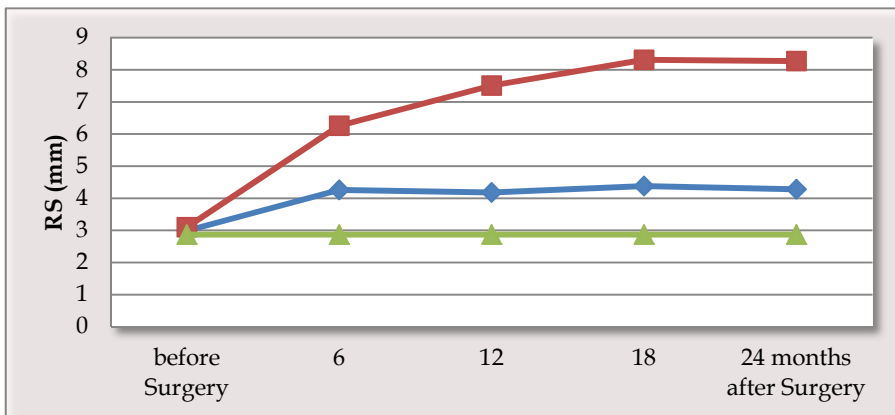
Michigan Breast Reconstruction Outcome Study made some interesting findings analysing the impact of TRAM reconstruction on the abdominal wall function. Two-year prospective study was conducted in 12 surgical centers. A feedback from 460 patients treated by 23 surgeons was analysed. Studies using isometric dynamometer showed the deficit of the abdominal wall functions both in methods of free and pedicle TRAM flap over two years. This deficit ranged with different authors between 6 to 19% while in women with pedicle TRAM was always larger (Alderman AK et al. 2006).



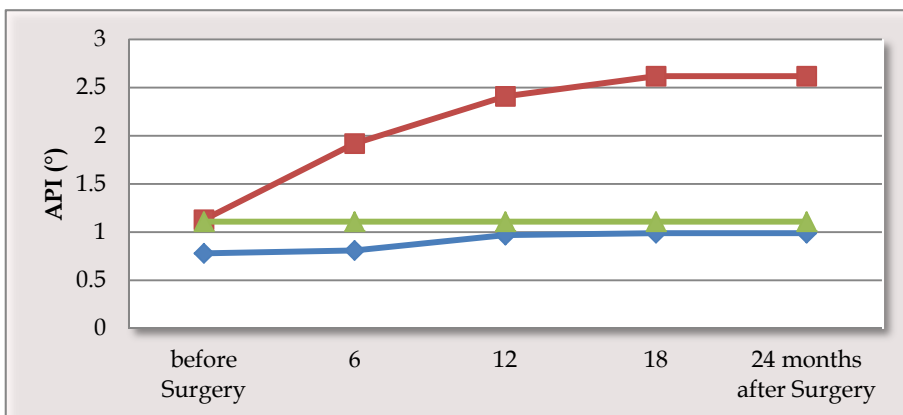
MDL - the maximal deviation of the line of the superior-posterior iliac spines from C7-S1.



DHSh -the difference in height of the shoulders



RS - the difference in depth of the lower border of the scapulae (rotation)



API - the angle of pelvis inclination (°)

Picture 8. Graphs showing the results of measurements of various parameters of body posture in planes: frontal, sagittal and transverse in three groups of women: after radical breast amputation (RM), after amputation of the sparing of skin and simultaneous breast reconstruction (IBR ssm +) and a group of healthy women, not operated (Control).

It was also found that up to 53% of the reconstructions using pedicle TRAM flap showed deficits in both rectus abdominal muscle and the oblique muscles.

In women with bilateral breast reconstruction using pedicle TRAM, the trunk flexion deficit reaches 40% and trunk extension deficit is 9%. This group of patients also experienced a subjective muscle dysfunction of the abdominal wall.

In varying degrees, this influenced the overall assessment of quality of life of patients after breast reconstruction with abdominal flaps.

4.2.1.2 Latissimus dorsi flap reconstruction

Another problem is a breast reconstruction with the use of latissimus dorsi (LD) flap. It is still a very common and useful method of breast reconstruction especially in difficult conditions or corrective surgeries.

Latissimus dorsi muscle (*musculus latissimus dorsi*) has the largest area of all the muscles in the human body. It is innervated by the thoracodorsal nerve. The initial points of attachment of this muscle are: vertebral processes of lower six thoracic vertebrae, lumbal vertebral processes, median sacral crest, the outer lip of the iliac crest (in the back of the third part) and the outer surface of the 9th and 10-12 ribs. The final trailer is a crest of lesser tubercle of the humerus (*crista tuberculi minoris humeri*). In addition to adduction, inward rotation and straightening the arm, it is also an auxiliary exhaust muscle (for example, it gets stretched during the cough). (Daltrey et al. 2006) Using the part of latissimus dorsi muscle and transferring it as pedicle flap with soft tissues to the anterior wall of the chest may significantly influence torso symmetry, which has been confirmed in photogrammetric studies. However, the extent of torso statics disturbances after LD reconstruction is still unknown. To some extent, the operational movement and function change of the latissimus dorsi muscles also affects the chest expiratory action and compromises the shoulder morbidity.

An interesting solution was proposed based on detailed studies of the anatomy of latissimus dorsi muscle vascularization - the muscle latissimus dorsi flap sparing (MS-LD) breast reconstruction (Mojallal et al. 2010). A tiny lateral part of muscle containing the descending branch of the thoracodorsal artery with its perforators (TDAPs) can be used as a pedicle to carry a large skin-fascial flap. This way, the donor site morbidity in this manner is much less than classical or extended adipomuscular technique and latissimus dorsi muscle function is spared (Brackley PT et al. 2010). It results in no or minimal functional deficit of donor site, low rate of flap complications, absence of seroma and acceptable scarring.

4.2.2 Free flaps

Perforator flaps represent the state of the art in breast reconstruction replacing the skin and soft tissue removed at mastectomy with soft, warm, living tissue is accomplished by borrowing skin and fatty tissue from the abdomen or hip. This is made without sacrificing muscles and strength as compared to less sophisticated techniques.

The most important reason to use free flaps for breast reconstruction is the improved blood supply and reduced donor site morbidity. Moreover the use of free flaps with vascular microanastomosis transferred from remote regions of the body may offer a favourable solution in terms of maintaining a proper posture, minimising muscle morbidity. Accurate isolation of the vascular pedicle while sparing the muscle prevents the damage.

4.2.2.1 The free transverse rectus abdominis musculocutaneous flap reconstruction (free TRAM)

The free transverse rectus abdominis musculocutaneous flap reconstruction (free TRAM) is vascularised from the inferior epigastric artery. With this method a small amount of the rectus abdominis muscle containing blood vessels supplying the skin and fat are used. The inevitable weakness in the abdominal wall does increase the risk of a bulge or hernia. In the free TRAM reconstruction group only a slight deficit of rectus abdominal muscle was

identified. Of course, even more abnormalities of the correct abdominal wall function were noticed in the bipedicle TRAM flap reconstruction and bilateral breast reconstruction using both pedicle and free TRAM.

4.2.2.2 The deep inferior epigastric perforator flap reconstruction (DIEP)

The deep inferior epigastric perforator flap reconstruction (DIEP) is an evolution of the free TRAM flap, developed in Germany in the early 1990s. The flap - fat and overlying skin survives on a blood supply via one or two perforators or side branches from the inferior epigastric artery. Perforators are generally smaller in diameter than the main vessel, and vary in size between different people. If the perforators are too small, this type of reconstruction cannot proceed as there is the risk of flap failure due to inadequate blood supply. An interesting comparison of the results of dysfunction of the abdominal wall in two groups of patients after breast reconstruction: using free TRAM and DIEP reconstruction was conducted. The DIEP flap group had significantly higher trunk flexion torque compared with free TRAM flap group. This could suggest a better function of the abdominal wall reconstruction in patients with DIEP (Blondeel et al. 1997).

A publication of a systematic review of reports of dysfunction of the abdominal wall function after different abdominal flaps breast reconstructions appeared in 2009 (Atisha D & Alderman AK, 2009). Conclusions are based on the analysis of 20 documented reports. It confirmed the largest deficit of trunk flexion in patients with pedicle TRAM flap reconstruction (up to a 23%), lower in patients with free TRAM flap reconstruction (up to a 18%) and lowest in the DIEP flap reconstruction group. There was no statistically significant difference between the pedicle and free TRAM groups. However, a statistically significant difference between the free TRAM and DIEP methods was confirmed, in favour of the latter method of reconstruction. The analysis of the ability of trunk extension showed 14% deficit in the group of pedicle TRAM, and only a slight deficit in the free TRAM flaps and DIEP groups.

4.2.2.3 The superficial inferior epigastric artery flap (SIEA)

This flap is vascularised from the superficial epigastric artery arises from the front of the femoral artery about 1 cm below the inguinal ligament. This vessel supplies the skin and the fat of the lower abdomen. In this case there is no need to make incisions within the abdominal wall, thus hypothetically the problem of hernias and functional disorders of the abdominal wall muscle is eliminated. Unfortunately, only about 50% of patients have this vessel present.

4.2.2.4 The superior gluteal artery perforator flap (SGAP)

This flap is vascularised from the superior gluteal artery. Because of very short vascular pedicle it is difficult to perform this technic without additional vein graft. It is mainly used as second-line treatment option for patients ineligible for TRAM, and having breasts without or with minimal ptosis.

4.2.2.5 The inferior gluteal artery perforator flap (IGAP)

This flap is vascularised from the inferior gluteal artery. Due to the improved donor site contour and scar, the IGAP can be a flap of choice when a tissue from the buttock is required. There are several advantages to use this flap: a predictable consistent vascular pedicle, an adequate cutaneous paddle and well concealed donor site.

4.2.2.6 The Rubens fat pad free flap

This flap consist of redundant fatty tissue vascularised by the deep circumflex iliac vessels. The main benefit of this method is the aesthetics of the donorsite contour and scar.

The use of SGAP and IGAP as well as the Rubens flaps in a well-planned bilateral breast reconstruction may be important in maintaining normal body symmetry.

However all above mentioned metods of breast reconstruction with the use of free flaps are very promising, the wide feasibility for breast surgeons can be difficult to perform because of need of hight quality microvascular expertise and financial constrains.

4.3 Immediate or delayed breast reconstruction?

Breast reconstruction carried out during one surgery as a second stage after the oncological treatment is finished has many advantages. The woman wakes up with a new breast after surgery. In this way many negative consequences resulting from not undertaking immediate reconstruction or delaying it are avoided. Immediate reconstruction is the only way to save own skin of the operated breast and significantly improve aesthetical results (SSM- skin sparing mastectomy or ASM - areola sparing mastectomy). The benefits of choosing immediate breast reshaping during mastectomy allow for the best aesthetic results according to many plastic surgeons. The breast tissue, skin and nipple are more easily preserved. The breast cancer patient also benefits from the close collaboration of both oncologic and plastic surgeon at the same theatre to obtain satisfactory results. Photometric studies of body posture explicitly indicate correct body posture parameters among this group of women. Moreover, it has been shown that adverse changes in correct body posture among women after mastectomy without reconstruction occur after 6 months after surgery and they get worse in time reaching a peak after 18 months (Cieśla & Bąk 2006; Cieśla & Połom 2010). Therefore, delaying reconstruction may have a negative effect on body posture among women after mastectomy. Still, the extent of the negative effects of delaying breast reconstruction needs to be looked into.

4.4 The role of rehabilitation

It is very important for women after radical mastectomy and mastectomy with immediate or delayed breast reconstruction to attend regularly physical rehabilitation in a gym. The programme of essential therapeutic rehabilitation included:

- increasing or maintaining mobility of shoulder joint on the operated side,
- increasing or maintaining muscle strength of the upper limb on the operated side,
- correcting the faulty posture which arose as a result of amputation,
- balancing the strength of postural muscles and developing postural endurance,
- increasing the efficiency of respiratory system,
- preventing the lymph stasis in the limb and in the area of operation,
- improving the physical efficiency and body fitness,
- changing the mindset in order to adapt to new living conditions

In the rehabilitation of women after mastectomy the exercises are based on isotonic contraction and short isometric tension. Apart from active exercises proper also active exercises without pressure (in suspension) were applied, as long as functional abilities of the

women allowed it. In individual cases (with weakened muscles, significant limitations of mobility, soreness in the shoulder girdle or other complications) passive exercises were introduced. Low exercise positions were mainly used, since physical exercises in high position (standing) are the greatest burden to the circulatory system, in particular its venous part. Low isolated positions force the subjects to perform proper movements, and do not allow compensating for a limited mobility of shoulder girdle with movement of neighbouring joints (for example using the spine).

Since in women after mastectomy the static and body symmetry are disturbed, scoliosis arises, kypholordosis is changed it is important to locate the place where effects on the spine are exerted according to the steering rule. Control from above (of upper limbs) and from below (lower limbs) is used. In breathing exercises special attention is paid to breathing route - upper-costal (diaphragmatic and mixed) and to teaching correct breathing rhythm. The aim of breathing exercises is to improve pulmonary ventilation after the operation, gradual stretching of the scar and pressure on the cistern of chyle and abdominal part of thoracic duct (squeezing the lymph out of them towards the head).

During therapeutic rehabilitation educational effects were considered relating to the patient's behaviour at home, using anti-oedematous prophylaxis and making women realise the significance of physical activity in the prevention of secondary malignant disease. Future research on the motional rehabilitation of women after mastectomy should head in two directions. First, the alterations in body posture should be monitored during regular physical exercises. There is an urgent need to work out an exact program of those exercises that improve particularly difficult features in the body posture. Patients should also be protected against compensatory changes. Another research topic is based on observation of alterations in body posture and their prevention in women after different kind of breast reconstruction.

5. Conclusions

It should be strongly noted that breast reconstruction surgery has a significant effect on the patient's postoperative body posture. Although the changes in body posture are not completely eliminated, breast reconstruction considerably decreases the amount of divergence from normal body posture, as compared to patients who do not have reconstruction after mastectomy. This may be the basis for justifying immediate breast reconstruction not only from multiple psychological and physical perspectives - self-image, ease of dressing, interpersonal relationships, quality of life, but also improved posture as a positive outcome of breast reconstruction.

Future studies should aim at determining the effects of breast surgery on the body posture, as such procedures can also impact the patient's quality of life. It seems that the immediate, one or two-stage breast reconstruction using tissue expanders, implants or expander-prostheses should be a very important and integral part of treatment of patients with breast cancer who need mastectomy.

The advantage of the immediate breast reconstruction is that it protects a woman from traumatic loss of breast(s), make it possible to perform a radical oncological amputation while preserving natural own breast skin (ssm) or even nipple-areola complex (asm). The

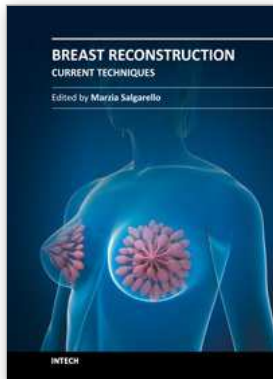
wider use of this procedure is possible in breast surgery centers and does not require complicated methods for own tissue transfer from other parts of the patient's body. However, this does not relieve the surgeon from mastering other techniques of breast reconstruction. The need for reconstruction using patient's own tissue is particularly useful in case of a failure of primary reconstruction with the use of implants or in case of severe postoperative complications. Freedom and skills of using techniques for reduction, mastopexy or augmentation of a healthy breast is necessary to achieve the proper symmetry of both breasts.

6. References

- Alderman AK, Kuzon WM, Wilkins EG. A two-year prospective analysis of trunk function in TRAM breast reconstructions. *Plast Reconstr Surg* 2006; 117(7):2131-2138.
- Al-Ghazal SK, Fallowfield L, Blamey RW. Comparison of psychological aspects and patient satisfaction following breast conserving surgery, simple mastectomy and breast reconstruction. *Eur J Cancer* 2000;36:1938-43.
- Atisha D, Alderman AK. A systematic review of abdominal wall function following abdominal flaps for postmastectomy breast reconstruction. *Ann Plast Surg* 2009 Aug;63(2):222-30
- Bak M, Rostkowska E. The influence of using breast prosthesis during the night on the changes of body posture among woman after mastectomy. *Physioth* 2000;8(4):11-5.
- Bak M, Cieřla S. Assessment of postural disorders in women after radical mastectomy followed by immediate breast Reconstruction. *Physioth* 2009;17(1)30-37.
- Blondeel PN, Vanderstraeten GG, Monstrey SJ, et al. The donor site morbidity of free DIEP flaps and free TRAM flaps for breast reconstruction. *Br J Plast Surg* 1997; 50:322.
- Brackley PT, Mishra A, Sigaroudina M, Iqbal A. Modified muscle sparing latissimus dorsi with implant for total breast reconstruction - extending the boundaries. *J Plast Reconstr Aesthet Surg* 2010 Sep;63(9):1495-502.
- Breuing KH, Warren SM. Immediate bilateral breast reconstruction with implants and AlloDerm slings. *Ann Plast Surg*. 2005;55:232-239.
- Cieřla S, Bak M : Disorders of body posture on women after mastectomy in photogrammetric estimation. *Eur J Cancer* 2004; 2(3): S167 - 4th European Breast Cancer Conference. Hamburg 2004
- Cieřla S, Bak M. (2004) The influence of immediate breast reconstruction with the use of the Becker prosthesis on body posture estimation at women after mastectomy for cancer. *Eur J Cancer* 2004; 2(3): S168 -4th European Breast Cancer Conference Hamburg 2004.
- Cieřla S, Immediate breast reconstruction after skin sparing mastectomy-102 cases. *Eur J Surg Oncol*, 2006;(32), Suppl 1,91
- Cieřla S, Bak M. The influence of immediate breast reconstruction on proper body posture on women after mastectomy for cancer. *Eur J Surg Oncol* 2006; 32(1): S99
- Cieřla S., Połom K. The effect of immediate breast reconstruction with Becker-25 prosthesis on the preservation of proper body posture in patients after mastectomy. *Eur J Surg Oncol* 2010; (36), 7:625-631.

- Cordeiro PG. Breast reconstruction after surgery for breast cancer. *N Engl J Med* 2008;359:1590–601.
- Cordeiro PG, McCarthy CM. A single surgeon's 12-year experience with tissue expander/implant breast reconstruction: II. A prospective analysis of long-term complications, aesthetic outcomes and patients satisfaction. *Plast Reconstr Surg* 2006;118:832–9.
- Daltrey I, Thomson H, Hussien M, Krishna K, Rayter Z, Winters ZE. Randomized clinical trial of the effect of quilting latissimus dorsi flap donor site on seroma formation. *B J Surg* 2006 Jul;93(7):825–30.
- Elder EE, Brandberg Y, Bjorklund T, et al. Quality of life and patient satisfaction in breast cancer patients after immediate breast reconstruction: a prospective study. *Breast* 2005;14:201–18.
- Ferlay J, Autier P, Boniol M, Heanue M, Colombet M, Boyle P (2007) Estimates of the cancer incidence and mortality in Europe in 2006. *Ann Oncol* 18(3): 581–592
- Findikcioglu K, Ozmen S, Guclu T. The impact of breast size on the vertebral column: a radiologic study. *Aesthetic Plast Surg* 2007;31: 23–7.
- Janni W, Rjosk D, Dimpfl TH, et al. Quality of life influenced by primary surgical treatment for stage I-III breast cancer. Long term follow up of a matched pair analysis. *Ann Surg Oncol* 2001;8: 542–8.
- Kopanski Z, Wojewoda T, Wojewoda A, et al. Influence of some anthropometric parameters on the risk of development of distal complications after mastectomy carried out because of breast carcinoma. *Am J Human Biol* 2003;15(3):433–9.
- Meadows DM, Johnson WO, Allen JB. Generation of surface contours by Moire' patterns. *Appl Opt* 1970;9:942–7.
- Mojallal A, Saint-Cyr M, Wong C, Veber M, Braye F, Rohrich R. Muscle-sparing latissimus dorsi flap. Vascular anatomy and indications in breast reconstruction. *Ann Chir Plast Esthet* 2010 Apr; 55(2):87–96.
- Morrow M, Scott SK, Menck HR, Mustoe TA, Winchester DP. Factors influencing the use of breast reconstruction postmastectomy: a National Cancer Database Study. *J Am Coll Surg* 2001;192:1–8.
- Nava MB, Ottolenghi J, Pennati A, Spano A, Bruno N, Catanuto G, Boliglowa D, Visintini V, Santoro S, Folli S. Skin/nipple sparing mastectomies and implant-based breast reconstruction in patients with large and ptotic breast: Oncological and reconstructive results. *Breast*. 2011 Mar 22.
- Parker PA, Youssef A, Walker S, et al. Short-term and long-term psychosocial adjustment and quality of life in women undergoing different surgical procedures for breast cancer. *Ann Surg Oncol* 2007;14:3078–89.
- Rietman JS, Dijkstra PU, Hoekstra HJ, et al. Late morbidity after treatment of breast cancer in relation to daily activities and quality of life: a systemic review. *EJSO* 2003;29:229–38.
- Rostkowska E, Bak M, Samborski W. Body posture in women after mastectomy and its changes as a result of rehabilitation. *Adv Med Sci* 2006;51:287–97.
- Takasaki H. Moire' topography. *Appl Opt* 1970;9(1457):1472.

Wong H-K, Balasubramaniam P, Rajan U, Chng S-Y. Direct spinal curvature digitization in scoliosis screening e a comparative study with Moire conturography. *J Spinal Disord* 1997;10(3):185-92.



Breast Reconstruction - Current Techniques

Edited by Prof. Marzia Salgarello

ISBN 978-953-307-982-0

Hard cover, 276 pages

Publisher InTech

Published online 03, February, 2012

Published in print edition February, 2012

Breast reconstruction is a fascinating and complex field which combines reconstructive and aesthetic principles in the search for the best results possible. The goal of breast reconstruction is to restore the appearance of the breast and to improve a woman's psychological health after cancer treatment. Successful breast reconstruction requires a clear understanding of reconstructive operative techniques and a thorough knowledge of breast aesthetic principles. Edited by Marzia Salgarello, and including contributions from respected reconstructive breast plastic surgeons from around the world, this book focuses on the main current techniques in breast reconstruction and also gives some insight into specific topics. The text consists of five sections, of which the first focuses on the oncologic aspect of breast reconstruction. Section two covers prosthetic breast reconstruction, section three is dedicated to autogenous breast reconstruction, and section four analyzes breast reconstruction with a fat graft. Finally, section five covers the current approaches to breast reshaping after conservative treatment.

How to reference

In order to correctly reference this scholarly work, feel free to copy and paste the following:

Sławomir Cieśla and Małgorzata Bąk (2012). The Effect of Breast Reconstruction on Maintaining a Proper Body Posture in Patients After Mastectomy, *Breast Reconstruction - Current Techniques*, Prof. Marzia Salgarello (Ed.), ISBN: 978-953-307-982-0, InTech, Available from: <http://www.intechopen.com/books/breast-reconstruction-current-techniques/the-influence-of-immediate-breast-reconstruction-on-proper-body-posture-in-women-after-mastectomy-fo>

INTECH
open science | open minds

InTech Europe

University Campus STeP Ri
Slavka Krautzeka 83/A
51000 Rijeka, Croatia
Phone: +385 (51) 770 447
Fax: +385 (51) 686 166
www.intechopen.com

InTech China

Unit 405, Office Block, Hotel Equatorial Shanghai
No.65, Yan An Road (West), Shanghai, 200040, China
中国上海市延安西路65号上海国际贵都大饭店办公楼405单元
Phone: +86-21-62489820
Fax: +86-21-62489821

© 2012 The Author(s). Licensee IntechOpen. This is an open access article distributed under the terms of the [Creative Commons Attribution 3.0 License](#), which permits unrestricted use, distribution, and reproduction in any medium, provided the original work is properly cited.