

One-Stage Immediate Breast Reconstruction with Implants in Conservative Mastectomies

Marzia Salgarello, Giuseppe Visconti and Liliana Barone-Adesi
*University Hospital "Agostino Gemelli",
 Catholic University of "Sacro Cuore", Rome,
 Italy*

1. Introduction

The evolution of breast cancer surgery is focused on optimization of the balance between the oncologic radicality and the maximization the cosmetic outcomes. The final goal of reconstructive breast surgery is to achieve a pleasant and attractive breast that matches as much as possible what is considered a "normal breast." To do that, it is important first to understand which features define the normal female breast identity. Following the works of Blondeel et al., the breast identity can be defined by a balanced combination of all the followings four elements:

- *Breast Footprint*: the foundation of the overlying breast, including the inframammary fold (IMF).
- *Breast Conus*: shape along with ptosis, volume and projection. These mean the "contents" of the breast.
- *Breast Skin Envelope*: the "container", what hold the breast "contents" on the footprint.
- *Nipple-Areola Complex*: unique structure, normally located on the point of maximal antero-posterior projection.

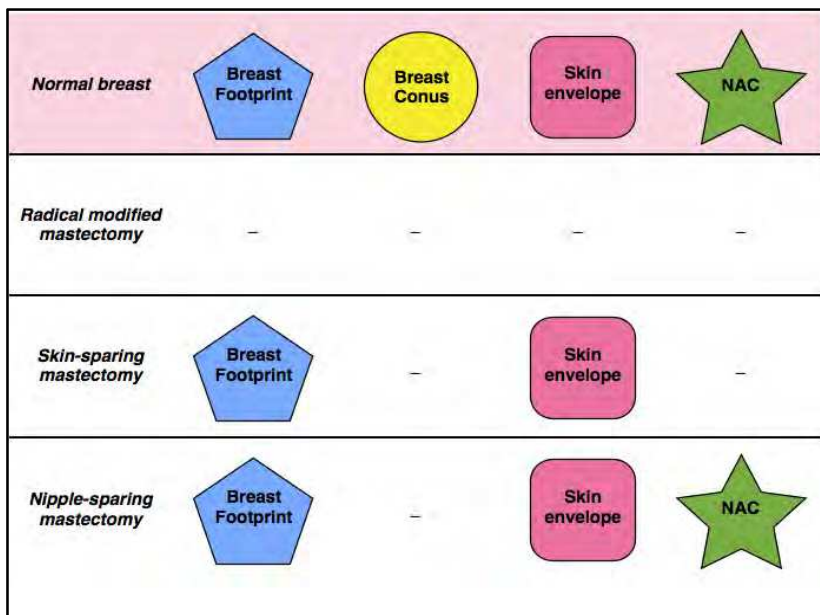
The absence of even only one of these elements prejudices the breast identity.

It is on these concepts that we can better understand and explain the advances of breast cancer surgery from radical modified mastectomy to conservative mastectomies such as skin-sparing mastectomies and nipple-sparing mastectomy.

So far, what is and what is not "conserved" by mastectomies? The breast conus is the only element that is always removed, being the parenchymal tissue its main component. The radical modified mastectomy violates all the other three elements. The skin-sparing mastectomies violate the conus and nipple-areola complex while preserve the skin envelope and an important breast structure such as the IMF (part of the breast footprint). The nipple-sparing mastectomy preserves everything except the conus.

More is violated, more has to be replaced, more demanding is the reconstruction, more difficult is the achievement of an an "attractive" breast. Since we are talking about the aesthetic appearance of the breast, it is also quite intuitive that more the "missed" element is visible more the mastectomy is recognized as "mutilative" and more the aesthetic outcome

is less favorable. So far, the absence of breast conus only that can be replaced by an implant or autologous tissue (being both not readily noticeable) is less of concern if compared to a replaced skin envelope or reconstructed NAC.



Since it was introduced by Toth and Lappert, skin-sparing mastectomy (SSM) has gained wide popularity over the last twenty-years. It is now considered a safe oncologic procedure, being its indications limited to the treatment of early breast cancer.

As for the concepts outlined above, the absence of the NAC leads patients to still identify SSM as a “mutilative procedure”, even if the breast mound is immediately reconstructed with implant or autologous tissues.

NAC reconstruction is usually performed 2-3 months later in outpatient setting. The aesthetic outcomes of different NAC reconstruction techniques are variable and no-one really matches the original features of the removed NAC.

For these reason and because of the successful application of skin-sparing mastectomy in breast surgery, surgeons worldwide have started to reconsider the feasibility of preserving the NAC during the mastectomy to maximize the cosmetic outcome in breast cancer surgery. Nipple-sparing mastectomy (NSM) represents, in fact, a further evolution of the “conservative” mastectomy concept, because by also preserving the NAC, reduces the mutilation consciousness to the breast conus only.

2. Indications

In this section we broadly summarize the oncologic indications for conservative mastectomies as this argument goes beyond the goal of this chapter.

- *Risk reduction/prophylactic mastectomy.*
- *Therapeutic mastectomy.*

In high-risk patients, risk reduction/prophylactic NSM is widely accepted because it has been demonstrated that it dramatically reduces the incidence of breast cancer, allowing at the same time a very satisfying reconstruction.

In breast cancer patients, SSMs has been demonstrated by large series to have no significant increase in local recurrence rates when compared to conventional mastectomies in patients with early breast cancer, except the ones with the skin tethering by tumour. In our centre, SSM is indicated in extensive ductal carcinomas in situ (DCIS), in multicentric tumors, in tumors that do not infiltrate the skin, with T1 and T2 tumors and an unfavorable breast-to-tumor ratio, and in patients who did not respond to chemotherapy. SSM is not indicated in inflammatory tumors or in locally advanced tumors.

NSM is indicated in carefully selected patients as the main concerns are related to both the risk of local recurrence of the cancer and development of a de-novo tumor in the NAC. This is justified by studies from 70s and 80s that have demonstrated an incidence of NAC tumor involvement ranging from 12 to 58%. However, these findings date from an era of later diagnosis and more advanced diseases. In fact, more recent reports have shown that NSM could carry an acceptable level of risk in selected patients with small (< 3cm), peripheral breast cancer with a negative axillary node. Nevertheless, there is no uniform consensus worldwide on the strict inclusion criteria of NSM as different technique are being used worldwide in NSM. In fact, some Authors use to excise the nipple core, others leave a thin button of tissue beneath the NAC with the aim to improve its viability, whereas others use the intraoperative radiotherapy with electrons (ELIOT) to further diminish the oncologic risk of the procedure. However, all these approaches, even with different inclusion criteria, are promising in the treatment of of some type of early breast cancer. In our centre, Nipple-sparing mastectomy is restricted to oncologic patients within the following inclusion criteria: tumor size of less than 5 cm, tumor at least 2 cm from the nipple-areola complex, no skin involvement or inflammatory breast cancer, clinically negative axillae or negative frozen-section of the sentinel node, negative intraoperative frozen section of the tissue immediately beneath the nipple, and patients' choice between breast conservative surgery and nipple-sparing mastectomy.

In addition to the oncologic considerations, the reconstructive concerns are equally determinant in NSM as this procedure is being performed to maximize the cosmetic outcomes after mastectomy. An unsatisfying reconstructive result would not justify the NSM to SSMs.

In this chapter we will analyze the one-stage immediate implant breast reconstruction using the submuscular-subfascial pocket following conservative mastectomies, focusing on the aesthetic outcomes and reconstructive issues.

3. Relevant applied anatomy

The comprehension of anatomy of the musculo-fascial structures of the thorax is essential for understanding and performing the submusculo-subfascial pocket dissection in breast reconstruction.

The Thorax muscles are anatomically divided by their depth in three layers:

- the first (more superficial) layer is defined by Pectoralis Major muscle (PM);
- the second (intermediate) layer is defined by Pectoralis Minor and Subclavian muscle;
- the third (deeper) layer is defined by the Serratus Anterior muscle (SA).

The submuscular-subfascial pocket is mainly defined by structure belonging to the first layer, as follow:

- superiorly by the released pectoralis major muscle (PM) with its fascias - deep pectoralis major fascia (DPF) and superficial pectoralis fascia (SPF).
- Inferiorly by the SPF.
- Laterally by the lateral pectoralis fascia (LPF) and axillary fascia (AF) with or without the serratus anterior muscle (SA).

3.1 Pectoralis major muscle

PM is a large, fan-shaped muscle. It originates from the medial clavicle, the sternum, the anterior second to sixth/seventh ribs and inserts onto the upper humerus about 10 cm from the humeral head on the anterior margin of the bicipital sulcus. On the median line of the sternum, it approaches the contralateral PM. It borders on rectus abdominis muscle inferiorly, the external oblique muscle infero-laterally, the serratus anterior muscle laterally and the deltoid muscle superiorly. The PM is superficial to rectus abdominis, serratus anterior and external oblique muscles.

The lateral margin of the PM forms the anterior axillary fold.

The main function of the PM is adduction and medial rotation of the arm.

3.2 Deep pectoralis fascia (DPF) and superficial pectoralis fascia (SPF)

The PM is wrapped by the pectoralis major fascia that anatomically represents a downward continuation of the superficial cervical fascia.

From anatomy books, the relationship of this fascia with the surrounding anatomical structures is usually not described in depth. That's why, we believe it is important to focus on some key-point of the anatomical relationship of these structures as they play a fundamental role in defining the submuscular-subfascial pocket.

The pectoralis major fascia wraps the PM by splitting itself in the deep pectoralis fascia and the superficial pectoralis fascia.

The DPF is located on the inner side of PM. Inferiorly it ends where PM ends and laterally it fuses itself with the SPF to define the pectoralis fascia laterally, or lateral pectoralis fascia (LPF).

The SPF is located on the outer side of PM, just below the deep layer of the superficial fascia (i.e breast capsule). Many fibrous connections exist between the SPF and the deep layer of the superficial fascia, making a bluntly dissection very difficult. These are:

- numerous thin, fibrous bundles in the upper third of PM;
- the presence of the Wuringer septum at the level of the fourth and fifth intercostal spaces;

- a tight connective tissue connecting the inframammary fold (IMF) with SPF.

The SPF thickness varies with different site of fascia. According to Jindle et al., SPF average thickness is 0.49, 0.60, 0.52 and 0.68 mm in the upper, lower, medial and lateral side. In our cadaver dissection experience, we found the SPF a thin and fragile but well defined fascia with strict anatomical relationship with PM epimysium (Fig. 1), confirming Jindle findings.

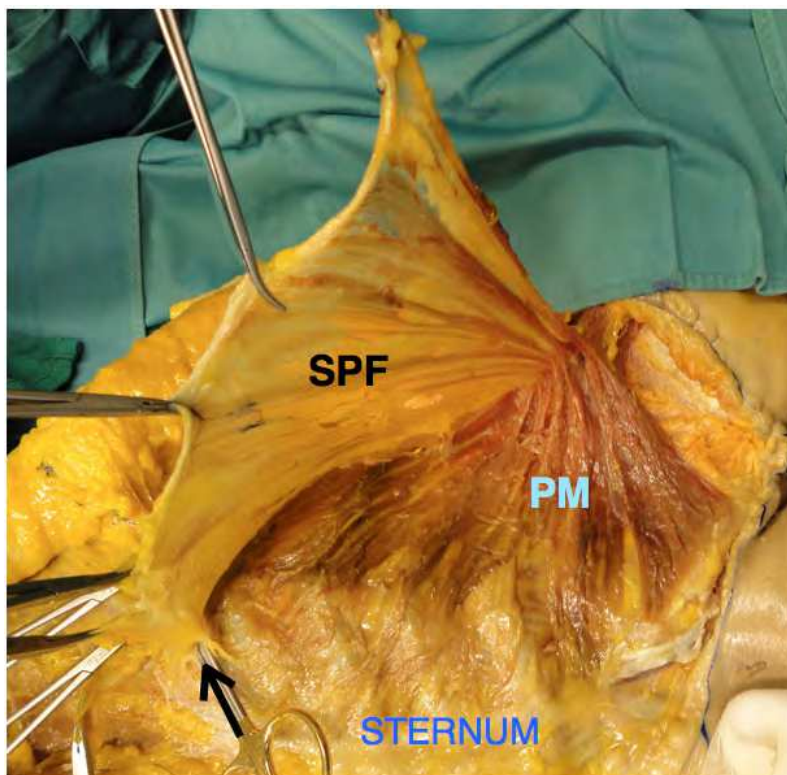


Fig. 1. SPF, cadaver dissection.

Cadaver dissection of right superficial pectoralis fascia. The deep layer of superficial breast fascia (breast capsule) has been dissected from SPF and PM. SPF has been dissected from the underlying PM starting from the superomedial to the inferolateral direction. The SPF continuation upward in the superficial cervical fascia as well as its adhesions to the sternum have been interrupted at the clavicle and at the sternum to allow the dissection. The cleavage between SPF and PM is anatomically not well distinct because of the strict relationship between SPF and PM epimysium. For this reason, few PM fibers have to be included in the fascia dissection. The black arrow points where the SPF anatomically have a fan shape behaviour. (see also figure 2, right)

The SPF cover the outer side of the PM. Laterally, it fuses with the DPF (figure 2, left) defining the pectoralis fascia laterally or lateral pectoralis fascia. Inferiorly, it pass over the inferior border on PM for few centimeters to end on the rectus sheath.

We found a peculiar behaviour of the SPF at the level of the IMF. At this point the SPF has a fan-shaped structure with two main divergent directions: one, that goes superficially ending on the skin at the level of the IMF and the other one goes inferiorly, vanishing on the rectus sheath. This structure plays a fundamental role in defining the IMF as, through this aproneurotic structure, the IMF is firmly attached to the chest wall. (figure 2, right)

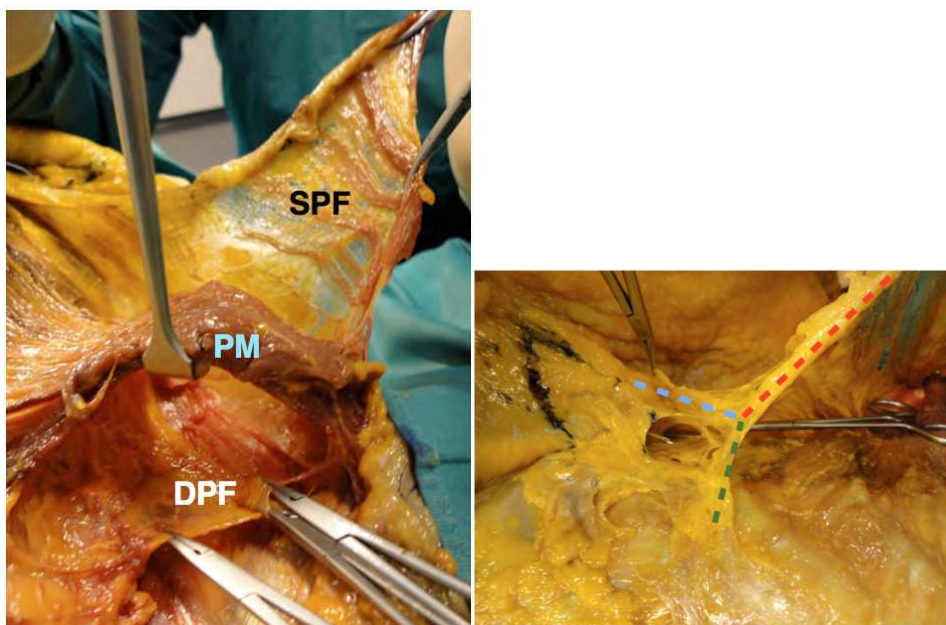


Fig. 2. (Left). SPF and DPF, cadaver dissection of right SPF. Close up at the lateral part of the PM defining the anterior axillary pillar. The SPF and DPF has been dissected off the muscle. Both fascias fuses themselves laterally defining an unique fascial layer, the lateral pectoralis fascia that continues laterally over the serratus anterior muscle as axillary fascia. (Right) Close up of SPF cadaver dissection at the IMF. At the IMF level, a needle has been inserted percutaneously. The SPF is a flat and thin structure over the PM (red dotted line). SPF shows a fan-shaped structure once at the IMF level with fibers showing two main directions: superficial fibers insert themselves at the level of the IMF (blue dotted line) while deep fibers point the abdominal wall by vanishing on the rectus sheath (green dotted line). The fan-shaped structure has been entered (where the needle emerges) to clarify the behaviour of the SPF at the IMF.

The structural features of the SPF makes it not useful in breast implant surgery if the SPF is completely dissected by the surrounding structures. In fact, it is a very fragile and thin fascia that can be easily smashed, thus having any supportive role alone. However, if used in combination with the surrounding structures, it can add valuable benefits in breast implant surgery.

In sub-fascial breast augmentation, the implant is placed beneath the SPF and above the PM. However, the SPF is only dissected by the PM being firmly attached to the breast capsule and breast itself.

In our submuscular-subfascial breast placement, the implant is placed beneath the PM being the fascia attached to the PM itself. The SPF relationships with PM epymisium are not violated, thus not weakening the fascia itself. In the submuscular-subfascial pocket, the SPF is only dissected beyond PM border, where the SPF is thicker. Inferiorly it is dissected by the rectus sheath and laterally by the SA.

3.3 Lateral pectoralis fascia (LPF) and axillary fascia (AF)

The LPF is defined by the fusion of the SPF and DPF lateral to PM border. The LPF continues with AF.

The AF extends between the lateral border of the PM anteriorly and the lateral border of Latissimus Dorsi muscle posteriorly, forming the floor of the axilla. It is suspended from the clavi-coraco-pectoral fascia, a triangular shaped aponeurotic system that envelopes the second layer of the thoracic muscles (i.e. Pectoralis minor, subclavian), being the downward continuation of the deep cervical fascia.

Lateral to PM, the AF is superficial to the SA and its fascia (third layer).

In the submuscular-subfascial pocket dissection, the AF is dissected in continuity with the LPF over the SA almost reaching the median axillary line. When this fascial layer is disrupted during the mastectomy or it is found very thin, we prefer to continue the plane of dissection beneath SA muscle and its fascia to assure lateral coverage.

3.4 Serratus anterior muscle (SA)

The SA is a large, fan-shaped muscle and the deepest extrinsic thoracic muscle. It origins with digitations from the upper eight ribs, interdigitating with origins of the external oblique muscle. The function of the SA is to stabilize the scapula against the chest wall. The SA is covered by its fascia, deeper to the AF and clavi-coraco-pectoral fascia.

In the submuscular-subfascial pocket dissection, the SA with its fascia is sometimes raised in continuity with the AF. This, when the LPF has been disrupted during the mastectomy or it is very thin.

4. Clinical decision-making in SSMs and NSM - How to maximize the results

4.1 SSMs and breast reconstruction: Why, when and how

We routinely offer SSMs in early stage breast cancer patients within our oncologic inclusion criteria. SSMs differ from radical modified mastectomy as the native breast skin is being preserved, allowing a more pleasant breast reconstruction. The type of skin incisions and the amount of skin removed define the type of SSM according to Carlson et al. Type I to III are reserved to patients with small to medium size breasts and the mastectomy carried out through a periareolar approach. A challenge arises in patients with macromastia. Whether reconstructed with implant or with the autologous tissues, a discrepancy between the spared skin envelope and the reconstructed breast mound tend to be. Because a contralateral reduction is usually required for symmetry, the Type IV and V SSM are offered to these patients, also known as skin-reducing mastectomies (SRM) as the oncologic procedure is carried out using a reduction pattern.

4.2 NSM and breast reconstruction: Why, when and how

Nipple-sparing mastectomy is offered to selected patients with the aim of maximizing the cosmetic outcome in high-risk and breast-cancer patients. Hence, the teamwork between plastic and breast surgeons is paramount. In our series of risk-reduction and oncologic nipple-sparing mastectomies, we did not register any subsequent nipple-areola complex cancer involvement. The final pathology of the retro-areolar tissue confirmed the negative intraoperative frozen section. Our nipple-areola complex cancer involvement rate is found to be within the range reported in the literature. Patients whose tumors are within 5 cm, at least 2 cm from the nipple-areola complex, without skin involvement or inflammatory breast cancer may be candidates when the intraoperative frozen section of the tissue immediately beneath the nipple-areola complex is negative.

4.3 The patient selection process in SSMs and NSM

4.3.1 SSMs

Patients with breast cup from A to C are better served with a type I to III SSM. The SRM patterns have been designed for patients with macromastia undergoing SSM as these patients would typically present a mismatch between skin redundancy and implant volume if type I to III SSM are performed. The SRM allows excess skin envelope removal and at the same time a pleasant shape and symmetry with the contralateral breast that usually needs a reduction, using the same reduction pattern as the SRM breast. The resulting final scars are similar to those from cosmetic surgery. The type IV SSM identifies a SSM with a reduction pattern embracing both the inverted-T reduction as well as the vertical reduction patterns. If the vertical reduction pattern is feasible in patients with medium to large breast, the inverted T approach is best suited for patients with very large and ptotic breasts. The type V SSM has been described to overcome the limitations of the type IV SSM in patients with superficial tumors located above the proposed reduction pattern.

Compared to SSMs, inverted-T SRM are characterized by a higher rate of skin ischemic complications as the mastectomy flaps are more devascularized by the pattern itself. For this reason, the selection criteria for SRM patients should be more strict than SSM patients. Risk factors such as smoking, diabetes and neoadjuvant chemotherapy has to be considered prior surgery.

4.3.2 NSM

Patients with breast cup A/B/C with a Regnault ptosis grade within 2 and hemiperiareolar scars/lateral scars with nipple-areola complex lateralization/ scars in the medial quadrants and from breast reduction/mastopexy should be informed that a higher rate of nipple-areola complex-related minor complications could occur. We discourage nipple-sparing mastectomy with implant reconstruction in very large and ptotic (cup D and over with Regnault ptosis grade 3) breasts, large breasts with scars, and in patients radiated or planned for radiation therapy.

Besides the type of incision and the NSM technique used, other factors may concur to the development of nipple-areola complex ischemic complications. Among these, heavy smoking, diabetes, and large-size and very ptotic breasts have been generally recognized as risk factors.

Evaluation of candidates for Implant-based Reconstruction in SSMs

Excellent candidates

- Thin patients undergoing bilateral SSM.
- Monolateral SSM with normal, small-medium size, no/minimally ptotic contralateral breast.

Good candidates

- Monolateral SSM with medium-big size, ptotic contralateral breast.

Poor candidates

- Radiated patients.
- Obese and smoking patients.
- Some neo-adjuvant chemotherapy protocol in SRM (still under investigation)

Evaluation of candidates for Implant-based Reconstruction in NSM

Excellent candidates

- Thin patients with breast cup A to B and ptosis grade 1 without breast scars.
- Bilateral NSM.
- Monolateral NSM with normal, small-medium size, no/minimally ptotic contralateral breast.

Good candidates

- Thin patients with breast cup C and ptosis grade 1 without breast scars.
- Thin patients with breast cup A to C and ptosis grade 1 to 3 with previous scars: external radial without NAC lateralisation and supero-lateral quadrant.
- Monolateral NSM with normal, small-medium size, ptotic contralateral breast.

Poor candidates

- Patients with breast cup D or major.
- Previous breast scars: lateral scars with NAC lateralization, medial quadrant scars, scars in the mammary fold and from previous breast reduction/mastopexy.
- Radiated patients.
- Obese and smoking patients.

4.4 Planning the skin incision

Besides the well-defined type I to III SSMs, planning the incision plays a key role in both SRM and NSM.

4.4.1 SSMs (type I to III)

Following Toth and Lappert paper on skin-sparing mastectomy, Carlson GW et al. classified the procedure in four types based on the type of incision made and the amount of skin removed.

- *Type I.* In SSM type I, the skin incision is periareolar only with, sometimes, a lateral radial extension to enhance the exposure. (i.e patients with small nipple-areola complex). SSM type I is normally offered to patients with breast cancer diagnosis made by needle biopsy, thus without other breast scars. Only the NAC is removed. (figure 3, left)
- *Type II.* The skin incision is periareolar in continuity with previous breast scars or skin overlying superficial tumors. It is intuitive that SSM type II is normally offered to patients with previous breast scar or superficial tumour tethering the skin in proximity to the NAC itself. When these are distant from the NAC, the SSM type III is applied to these patients. The NAC along with the previous scars/tumours are removed including the intervening skin.(figure 3, center)
- *Type III.* The mastectomy is developed through a periareolar incision. Distant excision of a previous breast scar or skin overlying superficial tumours is added. In this case, the intervening skin can be preserved. (figure 3, right)

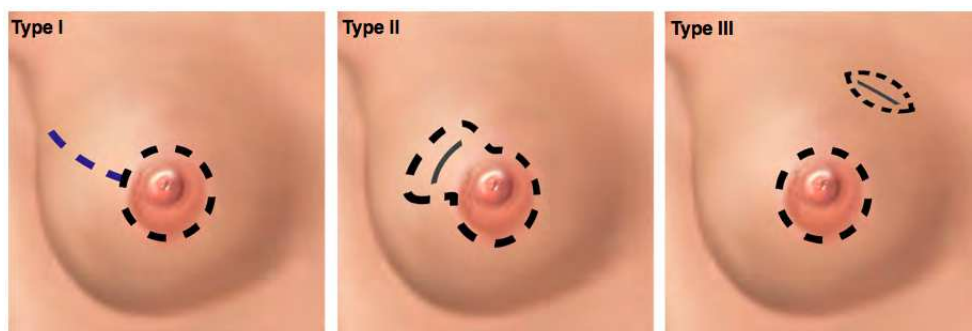


Fig. 3. (Left) Type I SSM. The lateral radial incision is made only for better exposure (dotted violet line). (center) Type II SSM. The intervening skin between the breast scar and the periareolar incision is included in the pattern. (right) Type III SSM. The intervening skin between the breast scar and periareolar incision is not included in the pattern.

4.4.2 SSM type IV or SRM

The SSM type IV or SRM are normally offered to patient with macromastia and/or ptotic breasts. The skin incisions resemble the inverted-T or the vertical reduction pattern, even if an important concept should be underlined for the incision planning. When a inverted-T SRM is planned, the mastectomy is developed through the inverted-T pattern, thus removing en-bloc the breast cancer with the skin pattern. In our series, when a vertical skin excess is present, the mastectomy is performed through a circumareolar approach (type I SSM) and a vertical dog-ear is removed at the end of the reconstruction to better shape the skin envelope on the implant. So far, the ending scar is vertical along with a central purse-string suture.

The SRM pattern follows the contralateral breast reduction pattern being the latter defined as follows. IMF and breast meridian are marked. The location of the IMF is transposed onto the anterior surface of the breast, using the Pitanguy maneuver and marked on the breast meridian. One cm above this point, point A is marked on the breast meridian. This will be the new nipple site. With the aid of a compass set on 7-8 cm, with one tip held on point A, a line with an upward concavity is drawn. (figure 4 - black dotted line) Seven-eight

centimeter is the sum of one-half the diameter of the areola and the length of the vertical limbs of the inverted T. Along the IMF, three points are marked: the medial (E) and lateral (F) extremities, and the place where the breast meridian crosses the IMF (D). Using point E as pivot, a compass set on the length as long as segment DE is rotated upward until it reaches the curved line drawn before. (figure 4 – red dotted line) Point B is marked there. In the same way, using point F as pivot and a compass set on the length as long as the segment DF (figure 4- green dotted line), point C is marked laterally on the same curved line. The inverted-T breast reduction pattern can now be easily completed connecting F to C, E to B and B and C to A. The drawing is checked twice by the surgeon. By using the fingers, point B and point C are pinched and transposed to point D to check the tension.

Once the breast reduction markings are completed, the SRM pattern is then drawn. The SRM pattern is marked similarly to the breast reduction one with few main differences. With the aid of a compass pointing the sternal notch and point A, point A' is marked on the SRM side one centimetre below than the contralateral side. The vertical limbs of the inverted-T on the SRM side are marked with a length 1-2 cm longer than the reduction side. The key-hole width is kept about 2cm narrower than that on the breast reduction side. All in order to reduce the skin tension on the scars and to foresee the extensive skin retraction after mastectomy.

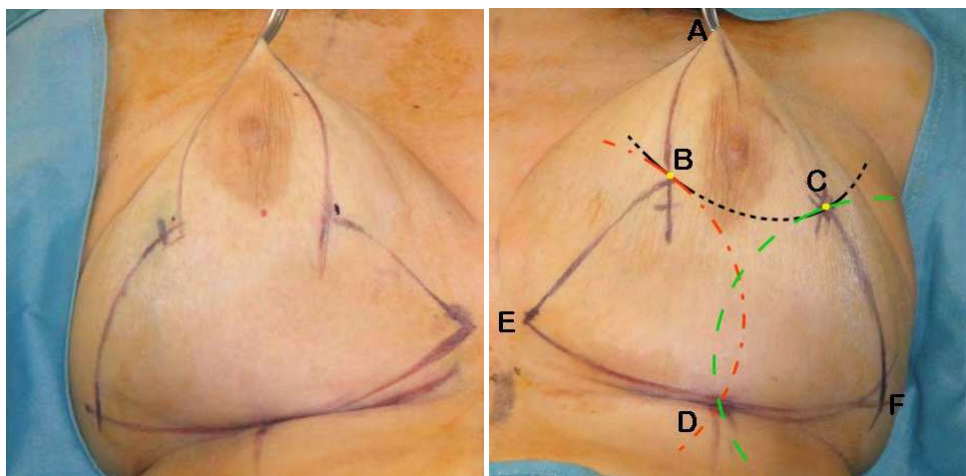


Fig. 4. The left inverted-T breast reduction pattern is showed along with the right SRM pattern. Note that the reduction pattern is wider than the SRM pattern.

The SRM pattern is checked twice. Point B' and point C' are pinched and transposed to point D' to be sure that the vertical limbs are tension-free. Otherwise, the SRM pattern is corrected to gain the target of a tension-free skin closure. In every case the skin area encircled by the markings is wider on the breast reduction side compared with the SRM one.

When a bilateral SRM has to be performed, the SRM pattern is transposed on the contralateral breast for symmetry. If breast asymmetry is present, the skin areas encircled by the markings will be different, wider on the bigger breast.

When using the inverted-T SRM pattern, the major concerns are related to the viability of the skin flaps, especially at the T-junction where the breakdown rate has been reported to be up to 30 percent because of the skin flaps ischemia due to their length and thinness. To reduce the incidence of skin flap necrosis, the reduction skin pattern needs to be more “conservative” than the conventional one used for cosmetic reason, as also showed in our series. This results in longer vertical skin flaps with a more acute angle. The target is to close the skin flaps over the reconstructed breast in a tension-free fashion.

4.4.3 NSM

The incision must be suitable for an appropriate mastectomy, for easy access to the retro-areolar tissue without impairing the nipple-areola complex viability, and for reconstructive pocket dissection.

Initially, we used the inferior hemiperiareolar incision in the breast with a normal to large areola diameter to better hide the scar. When the areola diameter was small, we extended the inferior periareolar incision in a short lateral radial fashion. After experiencing major and minor nipple-areola complex complications with the periareolar approaches, we opted for radial incisions.

The radial approaches consisted of lateral radial and vertical radial incisions. The lateral radial incision (3 and 9 hours for left and right breast, respectively) began from just outside the areola and extended laterally for a variable distance, depending on the breast size/ptosis and the needs of the breast surgeon. The vertical radial 6 hours approach is preferred for big and ptotic breasts (ptotic C cup and D and DD cups) when a slight skin excision is required. In young patients that exhibits a good skin quality, the skin redraping over the implant makes this excision useless. The vertical radial 6 hour approach consists of a vertical lozenge along the breast meridian, starting from 1 to 2 cm above the inframammary fold and ending at the nipple, inferiorly. The lozenge may include a little triangle of the areola. The incision is then extended lateral periareolarly for a maximum of one-half of the nipple-areola complex circumference. The vertical approach allows some shaping of the skin after the insertion of the implant, as some redundant skin is removed along the vertical incision to match the implant size. This explains the need of smaller implants in these patients when compared with C cup- sized ones.

Breasts with scars from reduction mammoplasty/mastopexy have been accessed using a part of the existing scars. In the presence of other scars, the breasts were accessed using the existing scars.

Radial approaches and incisions using existing scars located in the superolateral quadrant are related to lower rate of minor complications, no major complications, and high patients’ and surgeons’ satisfaction.

The periareolar incisions have been found to be related to the higher rate of nipple-areola complex complications. Our findings are in agreement with those observed by other authors. In our opinion, radial lateral incisions allow the best exposure of breast parenchyma and nipple-areola complex tissue, and easy access to perform reconstruction.

4.4 The selection of the reconstructive option.

The reconstructive options after SSM and NSM are one-stage or two-stage alloplastic reconstruction and an autologous one, alone or combined with the implant. In a study comparing the cosmetic outcome of three different reconstruction techniques following nipple-sparing mastectomy (implant only, pedicled latissimus dorsi flap with implant, and deep inferior epigastric perforator flap), Mosahebi et al. reported no significant differences in those who did not undergo postoperative radiotherapy.

In our series, we found good to excellent results in 83 % of cases of NSM and in 90 % of cases of SSMs and SRM. Thus, we favor one-stage immediate implant reconstruction for many reasons. When compared with the autologous one, the one-stage implant reconstruction presents less morbidity, more technical simplicity, and absence of the need for donor-side recovery. We routinely perform autologous reconstruction in case of implant reconstruction failure and in patients previously irradiated or planned for radiation therapy.

In high selected radiated patient, nowadays, we can offer an alternative reconstructive procedure called “Lipobed”, consisting of 1 to 3 sessions of breast fat grafting followed by implant-placement.

When compared with the two-stage implant reconstruction, the one-stage approach allows immediate definitive reconstruction and contralateral symmetrization procedures when needed. We found that by using the submuscular-subfascial pocket technique, a gentle expansion of lower-pole tissue coverage can be obtained. This, combined with the skin redundancy, leads us to consider tissue expansion as unnecessary in most of the case. Moreover, in SSM and SRM, the placement of a tissue expander would allow undesirable skin retraction of the mastectomy flaps. This phenomenon, in NSM cases, would promote nipple-areola complex lateralization. Some authors have expressed their concern in using definitive prostheses in the immediate set, because the skin stretching owing to the definitive implant could increase the risk of nipple-areola complex ischemia and skin-flap sufferance. This never happened in our cases.

Regarding inverted-T SRM, the implant-based reconstruction is often preferred as these patients are often obese making the autologous tissue reconstruction more challenging. In these patients, the major concerns are related to the viability of the skin flaps, especially at the T-junction where the breakdown rate has been reported to be up to 30 percent because of the skin flaps ischemia due to their length and thinness. To overcome this drawback, complete implant coverage with viable tissues beneath the skin flaps has been advocated. This allows to minimize complications over implants by giving a lifeboat for the skin healing process. This can be easily managed in an outpatient setting. The submuscular-subfascial pocket, being made only of autologous tissue, will favor the healing process by second intention in case of breakdown.

Thus, the technical advantages of the immediate implant reconstruction are as follows:

1. One-stage immediate reconstruction and contralateral symmetrization procedure when needed.
2. A natural breast shape for the significant lower-pole projection and no need of further coverage at the lower pole (i.e., acellular human dermis).
3. Reduction of the rate of implant reconstruction failure in SRM patients which experience T-junction breakdown as complete autologous tissue coverage is gained.

4. Preservation of the quantity and quality of the breast skin envelope, reducing the rate of skin retraction experienced with tissue expander placement.
5. Control of the nipple-areola complex tendency to migrate laterally. (NSM cases)
6. Reduction in the patient's physical and psychological impact from breast mutilation.
7. Reduction in healthcare costs.

On the other hand, this surgery is discouraged when the adipofascial layer is impaired during nipple-sparing mastectomy.

By ending this paragraph, we have to underline that there are some cases where the one-stage immediate implant reconstruction is not feasible because it would lead to unpleasant results. This normally happens for brachitype patients with short PM and little extensible SPF for whom it is not possible to obtain a good pocket space at the lower pole. It is in these cases, where the implant does not fulfill correctly the lower pole and is displaced in the upper pole, that we place a tissue-expander to better expand the lower pole thus creating the condition for a pleasant implant reconstruction.

4.5 The choice of the breast implant

Nowadays, both gel- and saline-filled implants with smooth, textured and polyurethane-foam covered are available on the market.

Currently, we found that anatomical cohesive silicone-gel textured implants with high projection were the most suitable for breast reconstruction; in fact, with the slightly filled upper pole as well as the full roundness and overprojected lower pole, they resembled the contour of a natural breast.

The determination of implant size depends on many factors. In literature, there are many mathematical-based algorithm for the choice of breast implant that can be helpful moreover for the young surgeons. However, we think that experience cannot be replaced by any mathematical algorithm, even the more dynamic and complete one.

Preoperatively, we estimated a range of implant sizes based on the following factors:

- contralateral breast mound, base and height.
- the actual breast mound, base and height of the mastectomy side as well as the expected breast volume to be replaced.
- Clinical evaluation of any chest-wall asymmetry.
- Patients' request. There are patients that are asking for bigger breast and other ones that prefers the same or even smaller volume.

It is mandatory for us that the range of implant sizes estimated preoperatively are available in the OR along with implant sizers. Nowadays, the advances in breast implant surgery offers the surgeons a large available choice on breast implant sizes, even within the same brand, that an almost "customized" reconstruction can be performed.

This advantages cannot be under-estimated if an excellent result is searched.

Intraoperatively, the final decision on the breast implant size and type is determined by evaluating the volume of the mastectomy specimen and either with the help of transverse width and vertical height of the contralateral breast and implant sizers.

In our experience on more than 350 patients, we did use Silimed Nuance silicon-gel filled implants with textured surfaces in 75 % of the cases and in the remainder Allergan Natrelle Style 410 silicon-gel filled implant with textured surfaces. Both the implant types share the anatomic shape and a high to extra projection in the lower pole.

4.6 The contralateral breast

When the conservative mastectomy is not bilateral, the final result in breast reconstruction cannot be limited to the reconstructed breast because it is a matter of symmetry between the reconstructed and contralateral breast. During preoperative patient consult, the plastic surgeon must assess also the contralateral breast along with patient desire, to correctly plan the reconstruction as well as the need of contralateral breast surgery. Patient has to be informed at the same time about the reconstruction along with the timing and plan, if any, for contralateral breast.

The contralateral breast can be left untouched only when facing with a normal, small-medium size breast with no ptosis when a conservative mastectomy with immediate one-stage implant reconstruction is performed.

Patient with breast hypoplasia are better managed with a breast augmentation. Patient with small-medium and ptotic breasts, from pseudo to real ptosis, are better managed with mastopexy with or without implant.

Patients with medium to big and ptotic breast that underwent a SSM type I to III or a NSM can be managed with breast reduction with vertical or J-scar with or without implant.

Patient undergoing SRM are normally planned for immediate contralateral inverted-T breast reduction.

5. Surgical technique

Conservative mastectomies were carried out by the breast surgeon using different incisions, as explained above. These were planned preoperatively by the plastic surgeon in consultation with the breast surgeon.

The breast parenchyma was removed by sparing the superficial layer of the superficial fascia, leaving standard-thickness skin flaps and by deeply sparing the pectoralis major fascia. (Fig. 5,left) Following the mastectomy, the definitive implant was placed in a submuscular-subfascial pocket. The lateral pectoralis fascia is opened by blunt dissection in its upper part (at the level of the 1st and 2nd rib) and the subpectoral plane (beneath PM) entered at this level. (Fig. 5,right)

A fiber-optic retractor with incorporated suction is then inserted. Under direct vision, the subpectoral plane is dissected as the muscular fibres to the chest wall are divided with the cautery till the lower part of the pectoralis major. (fig. 6)

The PM has been detached from its costal insertion. Two fingers are introduced in the submuscular-subfascial pocket to show the dissection. Note that the musculo-fascial integrity are completely preserved inferiorly and laterally.

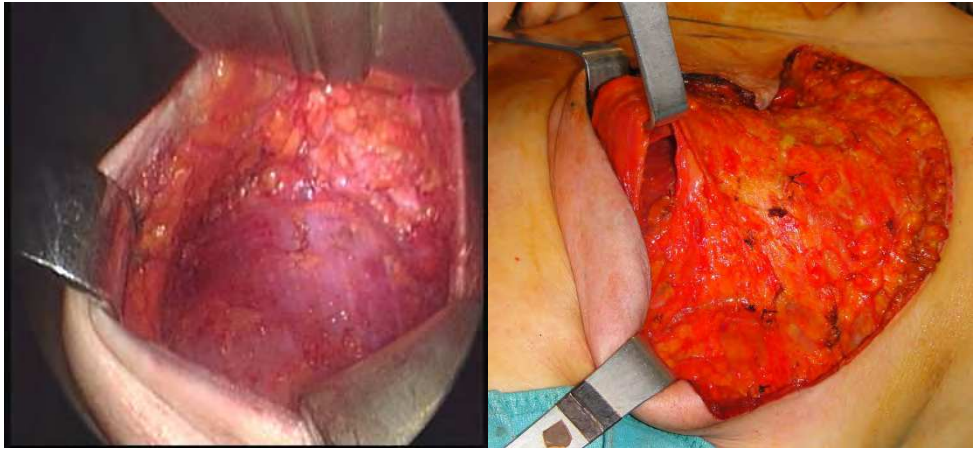


Fig. 5. (Left) SSM, picture made with endoscopic camera. Three retractors are lifting the mastectomy skin flaps. On the bottom, the PM with its overlying fascia. (right) Intraoperative picture of right SRM. Beginning of submuscular-subfascial pocket dissection. The submuscular space is bluntly entered laterally to PM at the level of the second rib. A retractor is lifting the PM at its upper part.

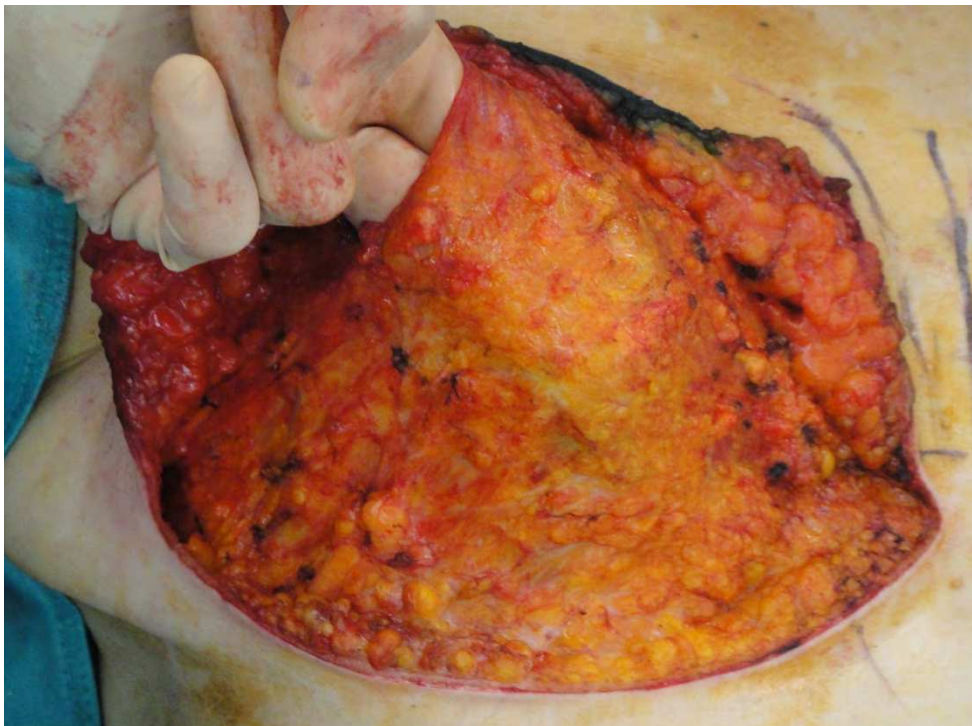


Fig. 6. SRM, sumuscular-subfascial pocket dissection.

At this level, the dissection is continued downward with cautery under the adipofascial layer (i.e. superficial pectoralis fascia (SPF) and overlying subcutis)(16,17), up to the inframammary fold (IMF). Then, the SPF is incised at the level of the IMF, exposing the overlying subcutaneous tissue. (Fig. 7)

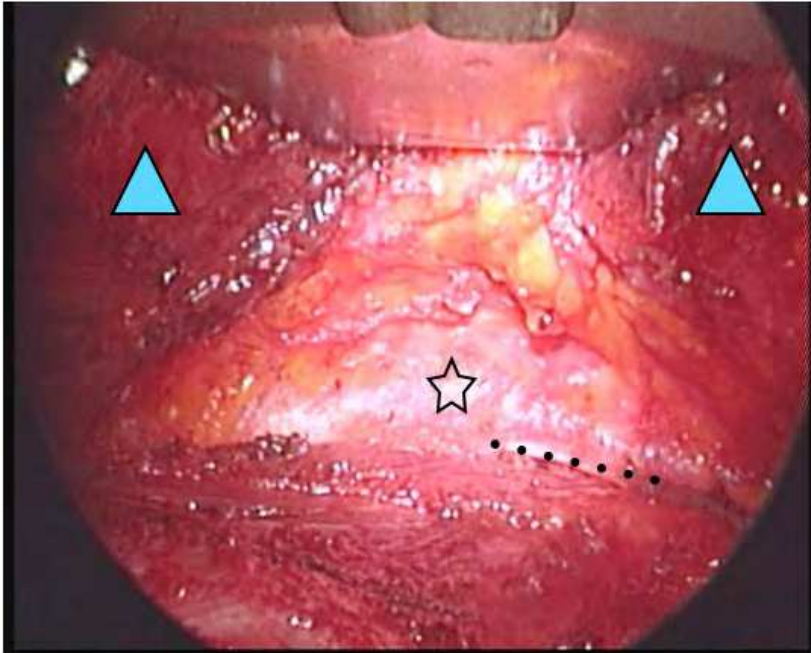


Fig. 7. SPF the PM, picture made with endoscopic camera. From *Salgarello M, Visconti G, Barone-Adesi L. (2010) Nipple-sparing mastectomy with immediate implant reconstruction: cosmetic outcomes and technical refinements. Plast Reconstr Surg. 2010 Nov;126(5):1460-71.*

PM costal insertion has been completely detached and PM freed (blue triangles). The retractor is pointing the inferior border of PM. SPF came into view as opalescent white structure with overlying subcutaneous tissue (star). The beginning of the rectus sheath is seen as a white, thick structure (dotted line).

This manoeuvre allows a re-definition of the IMF and a slight expansion of the lower pocket that may host even an implant with bigger volume than the excised gland.

Size choice of the implant was made with the help of implant sizer for Silimed prostheses and with the help of transverse breast width and vertical breast height for Mentor and McGhan implants. Nowadays, for the latter we use Allergan Natrelle 410 series ® FX and MX restrilizable implant sizer. After implant insertion, the upper part of the lateral pectoralis fascia was closed with absorbable stitches. Then the patient was semi-sitting positioned to check out the result.

The mobility of skin flaps, the larger quantity of tissue on the breast lateral pole and skin retraction would tend to attract the NAC laterally. The definitive implant filled the skin

envelope (i.e. the mastectomy flaps) thus allowing the repositioning of the breast skin and preventing the NAC lateralisation. However, when needed, the NAC position was assured with 1 or 2 absorbable stitches from the retroareolar tissue to the pectoralis fascia.

Thence, the implant was covered by the pectoralis major superiorly and by SPF and the overlying subcutis inferiorly. The submusculo-subfascial pocket was closed over the implant as this was completely separated from the subcutaneous tissue of the mastectomy flap. (Fig.8)

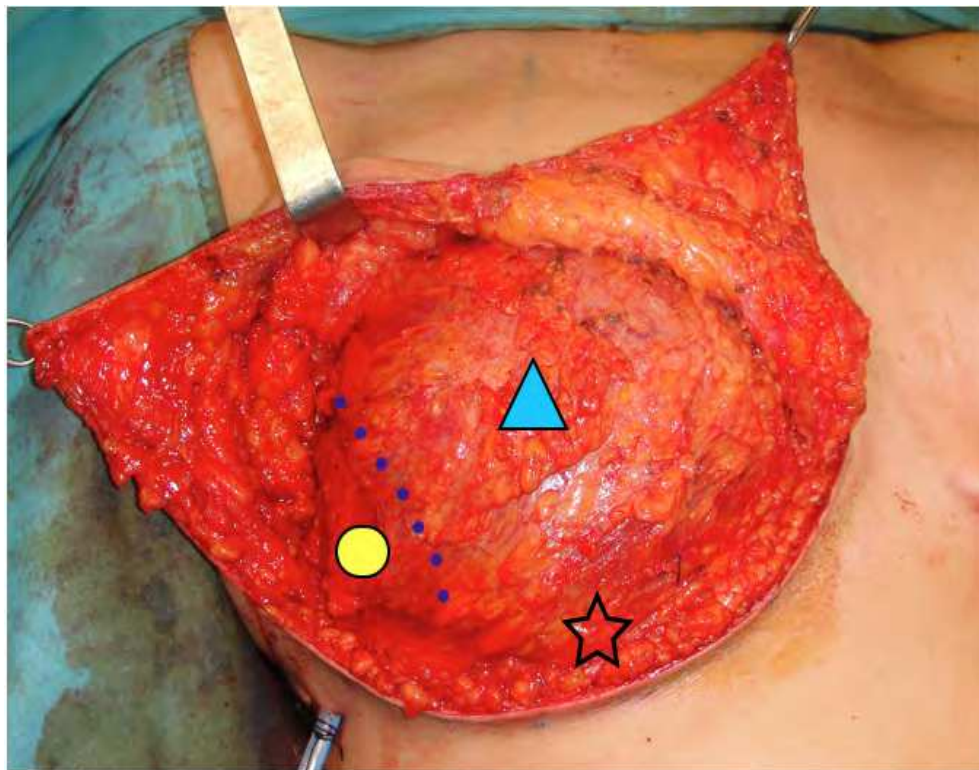


Fig. 8. SRM with definitive implant in the submuscular-subfascial pocket.

The submuscular-subfascial pocket seen from the mastectomy space in a SRM reconstruction. The dotted line shows the lateral margin of PM (blue triangle). The SPF has been lifted from rectus sheath inferiorly (star) and from serratus anterior laterally (yellow circle). The biomechanical features of these freed musculo-fascial structure allow the placement of big implant (in this case a 400 cc definitive implant) with good compliance of the musculo-fascial structure to the implant shape. Note the lower pole fullness along with a pleasant shape.

6. Results

6.1 SSM

We did perform more than 350 SSM with immediate one-stage breast reconstruction in our centre, being bilateral in 15% of the cases. Almost all monolateral cases (95%) had contralateral breast surgery to achieve simmetry. All these patients had not received radiotherapy and were not planned to undergo postoperative radiotherapy.

Nevertheless, 3% of the patients underwent postoperative radiotherapy because of the following reasons after the final histology: extended multicentric tumour; peritumoral lymphatic invasion; more than 4 positive nodes. The final aesthetic outcome was judged as excellent to good in 78.6% (figure 9), fair in 14%, and poor in 7.3%.

Patients' satisfaction was from high to very high in 90% of the results.

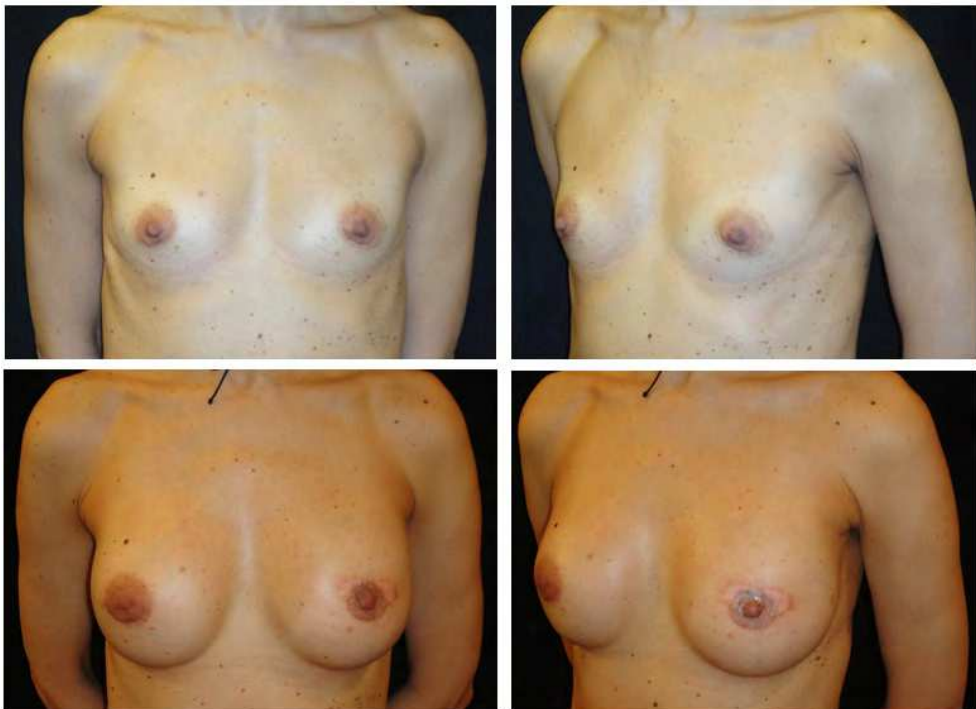


Fig. 9. (Above; left, right). Preoperative picture. The patient underwent left SSM type I with immediate implant reconstruction (McGhan 410 FX 280cc) plus right breast augmentation using McGhan 410 FM 205 cc. (Below; left, right) Thirteen month postoperative picture. NAC reconstruction has been performed 2 months later.

6.2 SRM

The average implant volume used was 416.5cc (range 300 to 500cc). The reconstructive outcomes were graded as excellent in 45 % of the patients (figure 10), very good in 40%, good 7%, fair and bad in 8 % of the cases which experienced full thickness necrosis of the vertical mastectomy limbs and at the T-junction. Patients' satisfaction was high to very high, except the case with "major" skin flap necrosis.

Major complications (i.e. extensive mastectomy skin flap necrosis) were noticed in 1 breasts that underwent debridement, implant removal and tissue-expander placement 2 days postoperatively. The only one minor skin necrosis have been experienced and managed by debridement and STSG in local anaesthesia 20 days postoperatively.

We did not experience any pathologic capsule contracture as well as any other early/late complications. Contour deformities have been found in 12.5%, which were all successfully treated with fat graft. (table 1)

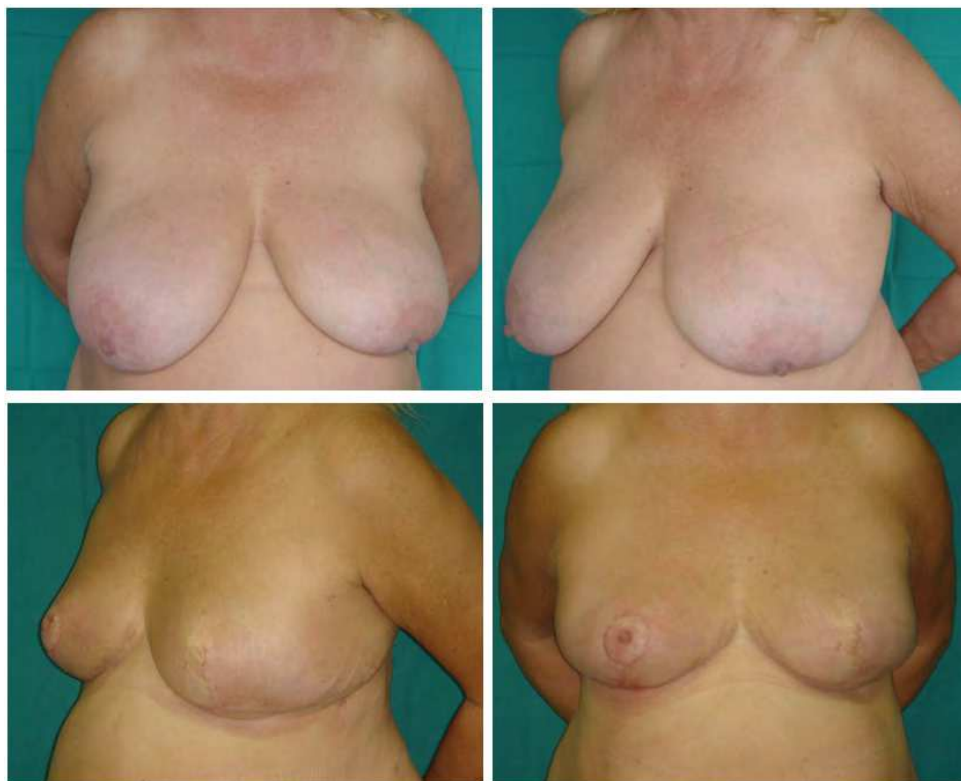

Fig. 10. (Above; left, right). Preoperative picture. The patient underwent left inverted-T SRM (mastectomy specimen weight:800gr) with immediate implant reconstruction (Silimed Nuance 300cc) plus right inverted-T breast reduction (reduction specimen weight 550gr). (Below; left, right) Eleven month postoperative picture. The patients refused the NAC reconstruction.

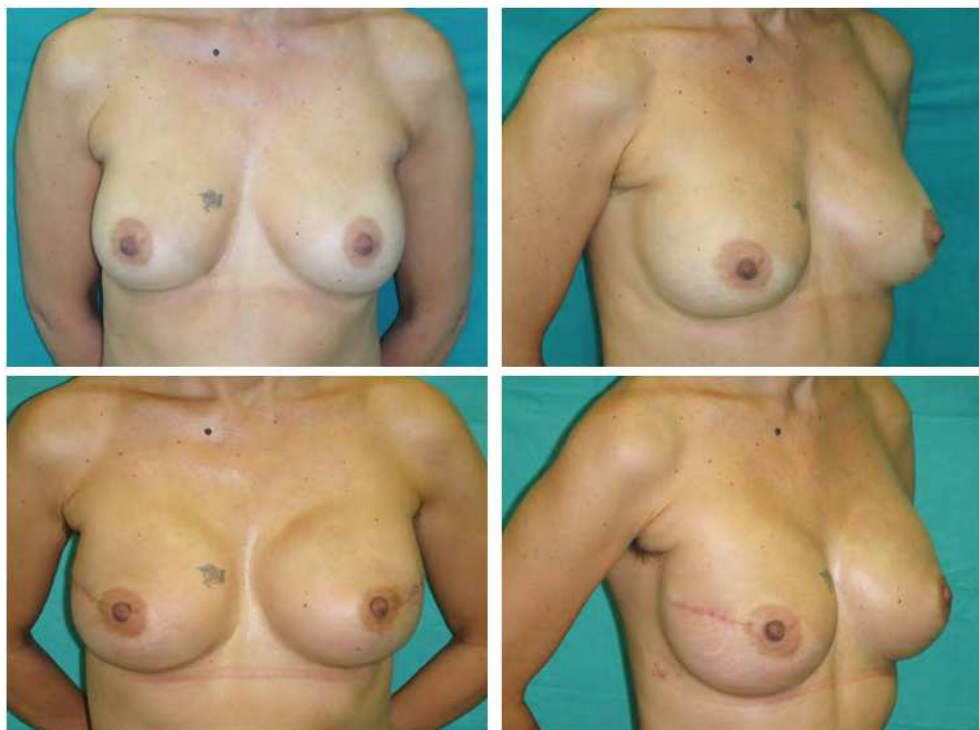

Fig. 11. (Above; left, right). Preoperative picture. The patient underwent bilateral NSM through radial lateral incisions plus immediate implant reconstruction (McGhan 410 MX 455cc). (Below; left, right) Three month postoperative picture.

6.3 NSM

On more than 60 cases with NSM, 40% were bilateral and 60% monolateral. All the monolateral cases underwent contralateral breast surgery simultaneously with nipple-sparing mastectomy for cancer (skin-sparing mastectomies and immediate implant reconstruction) and symmetry. The average implant volume use was 340 (range 200 to 485 cc).

The reconstructive outcomes were graded as excellent in 37.8% of the cases (figure 11), very good in 16%, good in 29.5%, fair in 10%, poor in 5% and bad in 1.7% in which total nipple-areola complex loss was experienced. Patients' satisfaction was high to very high, except the case with total nipple-areola complex loss.

6.4 Complications peculiar to each type of conservative mastectomy

6.4.1 SSM and SRM

Complications that may be experienced after SRM mastectomy and immediate implant reconstruction can be grouped in "early" and "late" complications. Among "early" complication, we identify mastectomy skin flap necrosis requiring revision surgery as

“major skin necrosis”. Skin flap necrosis susceptible to conservative treatment/minor surgery has been named “minor skin necrosis”. Hematoma, seroma, infections represent other “early complications”.

Thinning of skin with visible implant, implant rupture and capsule contracture represent the “late complications”.

6.4.1.1 Major skin necrosis

The risk of mastectomy skin flap necrosis can be dramatically reduced if an appropriate patient selection is made preoperatively.

As outlined before, smoking, obesity, hypertension, diabetes, microvascular disease must be ruled out during preoperative patient consult as they have been recognized as risk factors. Even if literature evidence is lacking on the matter, some chemotherapy protocols seems to interfere with mastectomy skin flap viability.

Intraoperatively, it is never overstressed that mastectomy skin flap must be gentle manipulated during the oncologic surgery and a meticulous mastectomy with preservation of the subdermal plexus is mandatory.

Large mastectomy skin flap necrosis that extends over the T-junction means the failure of the conservative approach as a surgical revision consisting of debridement is needed. The debridement further reduces the skin envelope usually meaning removal of the breast implant. We did experience major skin flap necrosis in the only one case which underwent neo-adjuvant chemotherapy. (fig. 12)

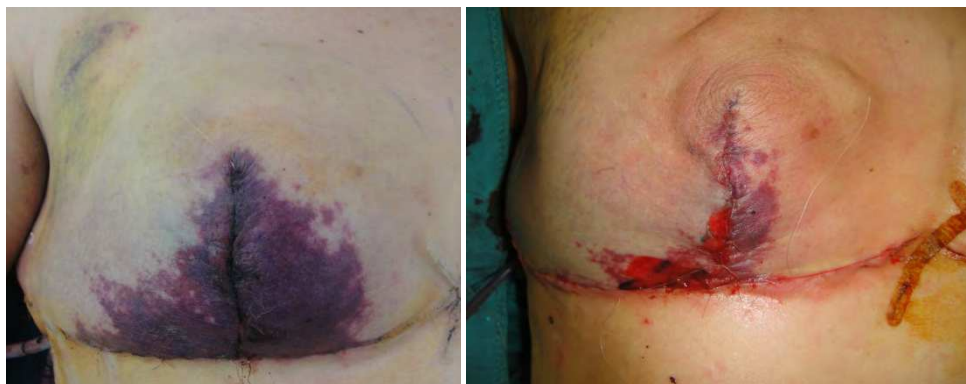

Fig. 12. Major skin necrosis after SRM. (Left) Postoperative day 2 of right SRM and immediate implant reconstruction with a Silimed Nuance 350 XH. Ischemic suffering is visible at the T junction and at both the vertical mastectomy flaps. This patient underwent neoadjuvant chemotherapy and showed a preoperative chemotherapy-related anemia. (right) Patient in the OR after debridement, implant removal and tissue-expander insertion.

6.4.1.2 Minor skin necrosis

The most experienced drawback in inverted-T SRM is the breakdown at the T-junction, reported up to 30 % in literature.(figure 13) When an implant reconstruction is performed,

complete implant coverage with viable tissues is desirable to protect the areas at risk of breakdown. In case of skin necrosis, the presence of a viable tissue beneath the skin flaps would allow wound healing by second intention or by STSG. This would minimize implant reconstruction failure due to implant extrusion/infection, being this complication reported close to 15 percent in literature.

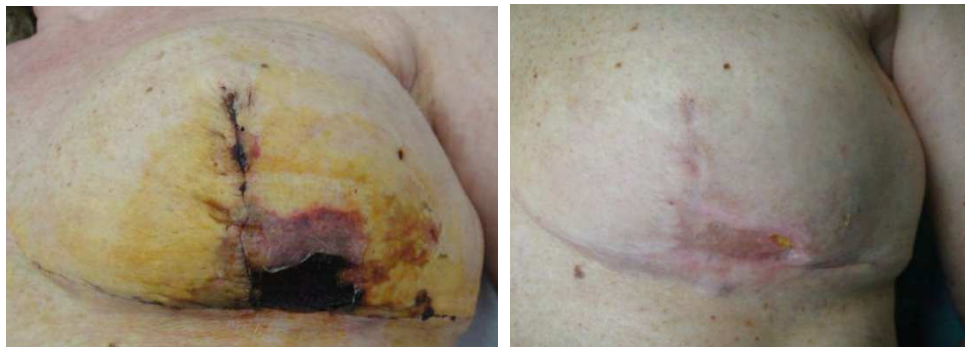

Fig. 13. Mastectomy skin necrosis at the T-junction after left SRM. (Left) Postoperative day 15 picture with a 3x2 cm frank eschar at the T junction. (right) Ten days after debridement and STSG taken from the bottom. There is a residual millimetric area in healing process.

6.4.2 NSM

Peculiar complication in NSM and immediate implant reconstruction can be divided in “early” and “late” complications. We grouped total nipple-areola complex loss and nipple-areola complex cancer involvement as “major complications.” In fact, these cases represent a total failure of the NAC preservation both from an oncologic and cosmetic point of view.

Partial nipple-areola complex loss, skin flap-edge necrosis, impaired wound healing, were termed “early minor complications.” Nipple-areola complex distortion and/or lateralization were termed “late minor complications.” (table 1)

6.4.2.1 NAC cancer involvement

No nipple-areola complex cancer involvement was registered in our series.

The risk of NAC cancer involvement represents the main concern in breast cancer surgery when performing NSM. Inconsistent data from studies of 70s and 80s reported a risk of NAC cancer involvement from 12 to 58 %. However, these data came from an era of later diagnosis and more advanced disease. To reduce the likelihood of NAC cancer involvement, breast cancer patients have to be within stricts inclusion criteria. Even if there is still no general consensus on the inclusion criteria for NSM and on the predictor factors of NAC cancer involvement, the results from different centers outlined that NSM represents a safe oncological procedure in patients with tumour inferior to 3cm in size, at least 2cm from the NAC and with negative nodes. In fact, recent NSM series reports a NAC cancer involvement being from 0 to 16%.

We will not focus on the oncological aspect of NSM because it goes beyond the goal of this chapter, but it is important to underline that it is still a matter of debate, especially regarding the inclusion criteria and the predictor factors of NAC cancer involvement.













Complications*	Major			Early minor**			Late minor		
	MAC total loss	MAC cancer involvement	MAC partial loss	Skin flap necrosis	MAC lateralisation	MAC distortion	MAC lateralisation and distortion	Capsule contracture	Contour deformities
PERIAREOLAR APPROACHES									
Hemiperiareolar									
									
									
									
Periareolar with lateral or vertical radial extensions									
									
									
									
Radial									
									
									
									
Other									
									
									
									
TOTAL									

Table 1. Overview of our experience in NSM and immediate implant reconstruction. The complications experienced are related to the skin incisions. From Salgarello M, Visconti G, Barone-Adesi L. (2010) Nipple-sparing mastectomy with immediate implant reconstruction: cosmetic outcomes and technical refinements. *Plast Reconstr Surg.* 2010 Nov;126(5):1460-71.

* under each complication it is showed the breast cup size/poissis grade according to Reganall.
 ** : other "early minor complications" such as infection, hematoma, seroma, skin flap ulcerance has not been reported in the table because not experienced (0%).
 BCS : breast-conserving surgery, Xrt : radiation therapy.

6.4.2.2 NAC total loss

After excluding the risk of NAC cancer involvement, all the surgical efforts should be spent in preserving the NAC viability when performing a NSM. This mainly means a gentle manipulation of the NAC during the mastectomy and the reconstruction time and preservation of subdermal plexus. These facts have to be always emphasized by the plastic surgeon, moreover when not working with the same breast surgeon. In our opinion, this complication itself would not justify NSM .

The risk of total NAC loss should be better assessed preoperatively or at most intraoperatively. When the surgeon is high suspicious about NAC viability he can opt to harvest the NAC in order to graft it at the end of the surgery. Alternatively, the NSM can be converted in SSM by removing the entire NAC.

In our series total nipple-areola complex loss was found in one breast. This patient was managed with early nipple-areola complex excision and purse-string closure, and did not require implant removal. (figure 14)

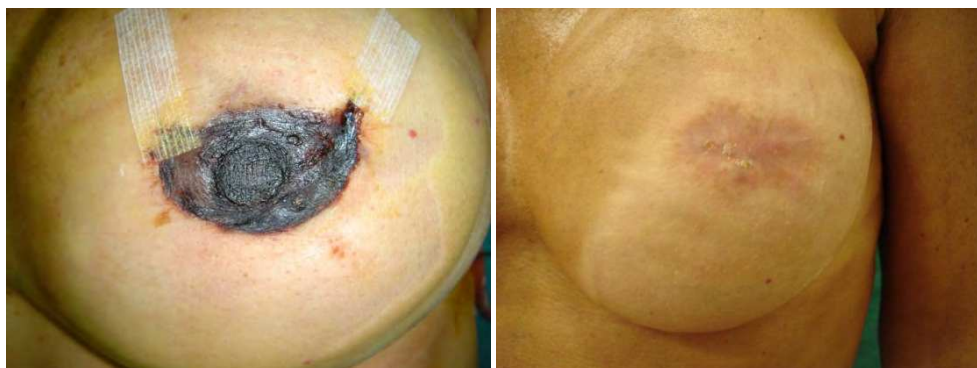

Fig. 14. NAC total loss (Left) Postoperative day 15 after left NSM and right SSM type II with immediate implant reconstruction. (Right) NAC total loss has been managed by debridement and purse-string closure in local anaesthesia; three-month later, it looks the patient underwent SSM.

6.4.2.3 NAC partial loss

Among early minor complications, partial loss involving less than 50 percent of the nipple-areola complex was found in 8% (Fig. 15). These were treated with dressing changes and healed uneventfully within 8 weeks.

6.4.2.4 NAC hypopigmentation

NAC hypopigmentation has been recognized as a sequelae of tissue ischemic sufferance without developing necrosis.

In our series, we did find one case of NAC hypopigmentation. (fig.16)

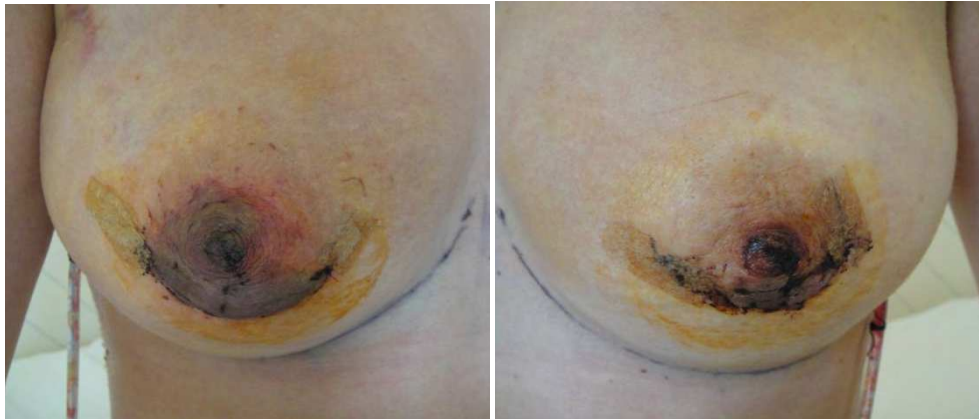


Fig. 15. Bilateral Partial NAC loss. Postoperative day 7 after bilateral NSM using inferior hemiperiareolar skin incision. (left, right)

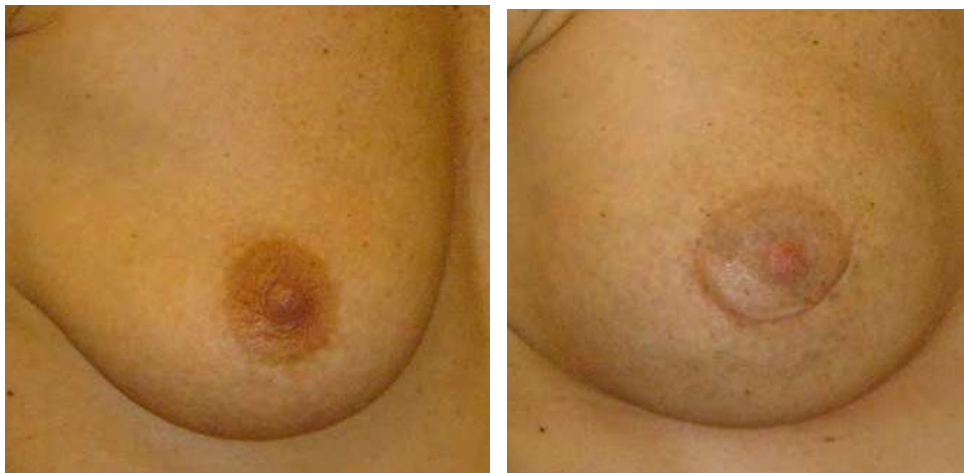

Fig. 16. NAC hypopigmentation. (left) Preoperative picture of NSM planned with inferior hemiperiareolar skin incision. (right) Two-month postoperative appearance. The NAC hypopigmentation in the inferolateral NAC quadrant is evident.

6.4.2.5 NAC lateralization / asymmetry / distortion

NAC lateralization defines a lateral malposition of the NAC when compared to preoperative location. For the breast aesthetic principles, the NAC should be located on the breast meridian. Some authors advocate that nipple-areola complex lateralization is related to either implant reconstruction or breast size/ptosis because of the likely dissociation between nipple-sparing mastectomy skin envelope, pectoralis nipple-areola complex major muscle, and implant. A recent 8-year survey on patient satisfaction after nipple-sparing mastectomy reconstruction (mainly with skin expander or autologous methods) by Mosahebi et al. demonstrates that nipple-areola complex malposition is a common complication and

represents the most frequent aspect that patients would change, after lack of sensation. If sensation loss is not avoidable, our series demonstrates that nipple-areola complex malposition can be prevented. In our opinion, we did not experience nipple-areola complex lateralization because we directly inserted a definitive implant that completely filled the skin envelope and opposed skin retraction that would lateralize the nipple-areola complex position. In our series, we did not find any case of NAC lateralization even when using a radial lateral incision, except the cases which already showed this condition preoperatively, as sequela of previous breast-conserving surgery through radial lateral scars. (fig. 17)

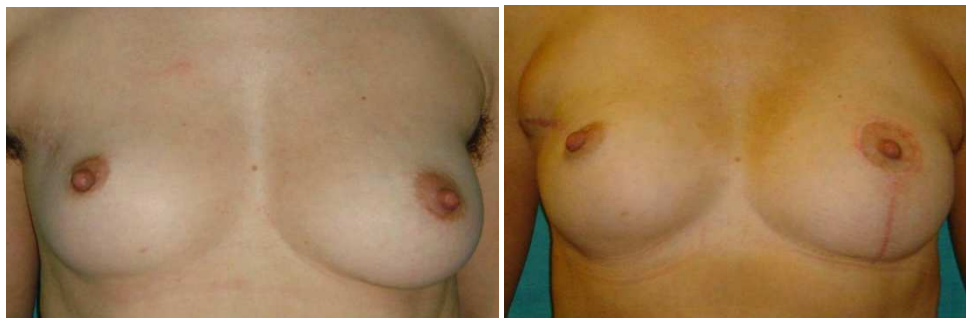

Fig. 17. NAC lateralization (Left) Preoperative picture of right NSM and left mastopexy. Patient underwent superolateral lumpectomy 1 year before on the right breast. The lumpectomy scar on the right breast is evident. It goes from the anterior axillary pillar to the areola and it brings to NAC lateralization. (right) One month postoperative after right NSM and immediate implant reconstruction and left vertical mastopexy. The NAC lateralization persists and it is more pronounced as right breast volume is increased after NSM and immediate implant reconstruction.

NAC asymmetry is experienced when NAC position is not symmetric with the contralateral one. This can be a consequence of monolateral NAC lateralization.

However, a symmetric bilateral lateralization is a sign of symmetry. The likelihood of NAC asymmetry is expected to be higher in monolateral NSM than bilateral procedures.

NAC distortion is defined by an altered NAC shape. This minor complication can be due to a pull-effect of the NSM scar on the NAC or a impaired wound healing.

We did experienced this complication in 5% of the cases. (fig. 18)

6.5 Complications common to all conservative mastectomies

6.5.1 Hematoma, seroma, infection

None of these complications has been experienced in any case of NSM and SRM.

However, we did experience infection in 6% of SSMs, seroma in 1,5% and haematoma in 3%.

90 % of implant infection were solved with e.v. antibiotics. One patient developed a seroma that became infected, and subsequently, it required the explantation of the implant. Furthermore, one patient experienced an infection 50 days after the surgery during the first

cycle of adjuvant chemotherapy and required implant explantation. Regarding the patients who developed an infection and retained their implant, 15% showed severe capsular contractures at 6 month follow-up.

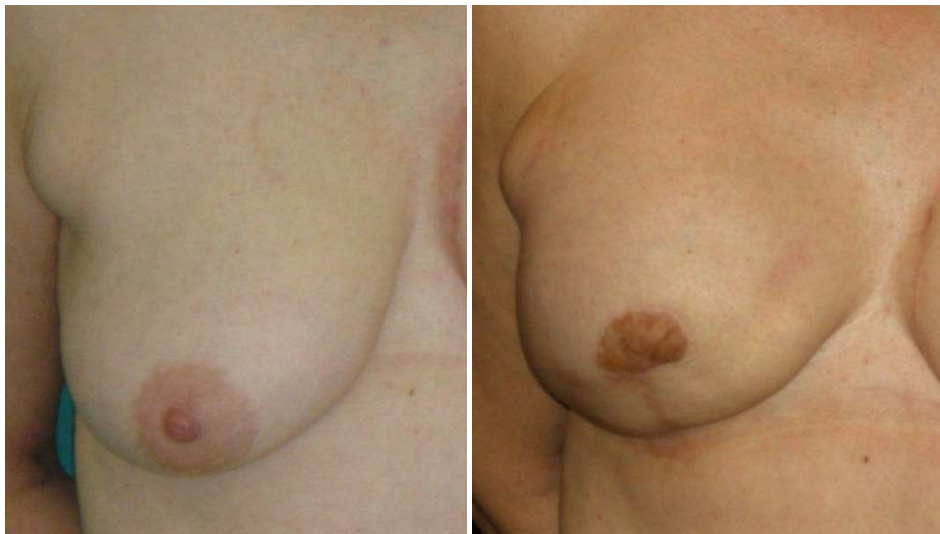

Fig. 18. NAC distortion along with nipple loss. (Left) Preoperative view of right NSM using a complete periareolar incision with vertical radial h 6 estension. Nine-month postoperative view. Note the NAC distortion and nipple loss after ischemic sufferance.

6.5.2 Rippling, implant rupture, implant malposition/rotation

We experienced 2% of rippling. We did not experience any case of implant rupture. Implant rotation has been experienced in only 2 SSM cases which underwent revision surgery.

6.5.3 Contour deformities

With the advances in modern breast reconstruction, the expectations from surgeons and patients for a great aesthetic result of a reconstructed breast are very high. The main goals are to recreate a harmonic breast mound in terms of size, projection, ptosis, providing natural contour in both the superior and inferior poles, so far matching the contralateral breast. According to Kanchwala et al., the contour deformities of the reconstructed breast and chest wall can be categorized in three groups:

- *Type 1.* The so-called “step-off” deformity occurring at the interface between the native chest wall and the reconstructed mound. It can be related to an “out-of-border” mastectomy that usually interests the superior pole, to an inappropriate implant or both. (fig. 19)
- *Type 2.* Intrinsic defect, secondary to irregularities from autologous tissue, fat necrosis or implant rippling.
- *Type 3.* Resulting from extrinsic factors, such as radiation therapy, scarring and post-lumpectomy defects. (fig 20)

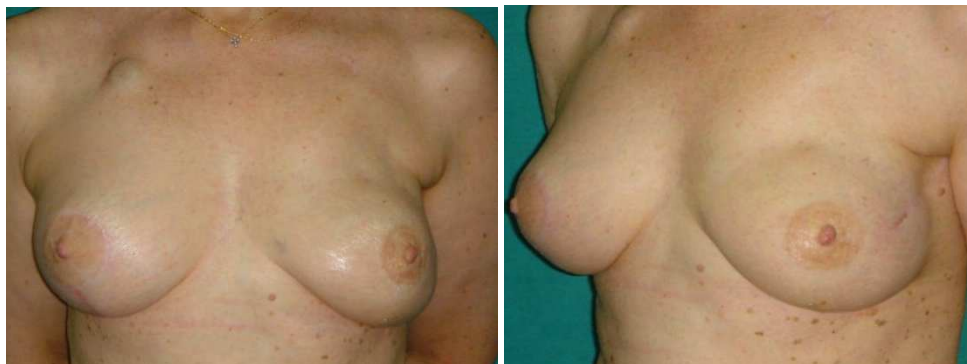


Fig. 19. (left, right) One-year postoperative view of left NSM through previous lateral biopsy with immediate implant reconstruction using an Allergan Natrelle 410 LF 205cc scar and right J-scar mastopexy. The step-off deformity on the left breast is evident.

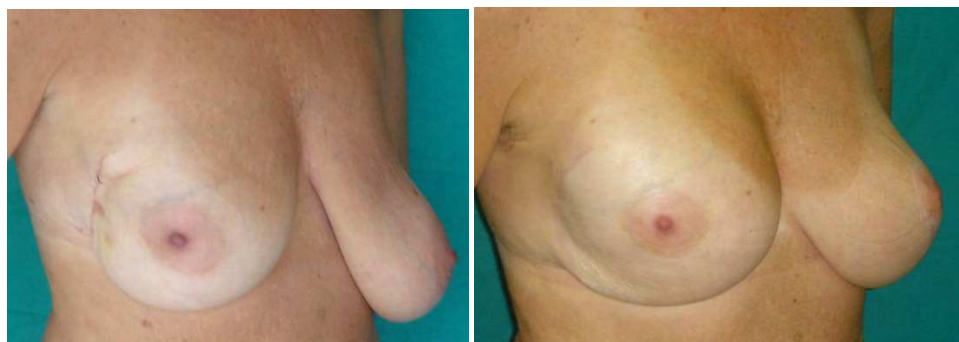

Fig. 20. (Left) Preoperative picture of right NSM and left J-scar mastopexy. Note the breast scar in the lateral mammary fold as sequelae of previous full lateral quadrantectomies. (right) Ten-month postoperative view of NSM through previous lateral mammary fold scar and immediate reconstruction with Silimed Nuance 370cc. The lateral contour deformity due to previous extensive lumpectomy and scarring is evident.

The most experienced contour deformity in SSM patients is the type 1 deformity, where in NSM is the type 3. All these patients underwent from 1 to 3 sessions of fat grafting, experiencing different degrees of improvement. (fig. 21).

Autologous fat graft represents, nowadays, the best filler to correct soft tissue contour deformities as well as the ones experienced in the reconstructed breast. In fact it replaces “like-to-like”, adipose tissue missed with the same tissue, providing excellent results in terms of contour, softness and camouflage. Depending on the extent of the defects, more than 1 session may be needed to achieve a satisfactory result. It is a low-invasive operation, with few scarring and well-tolerated by patients.

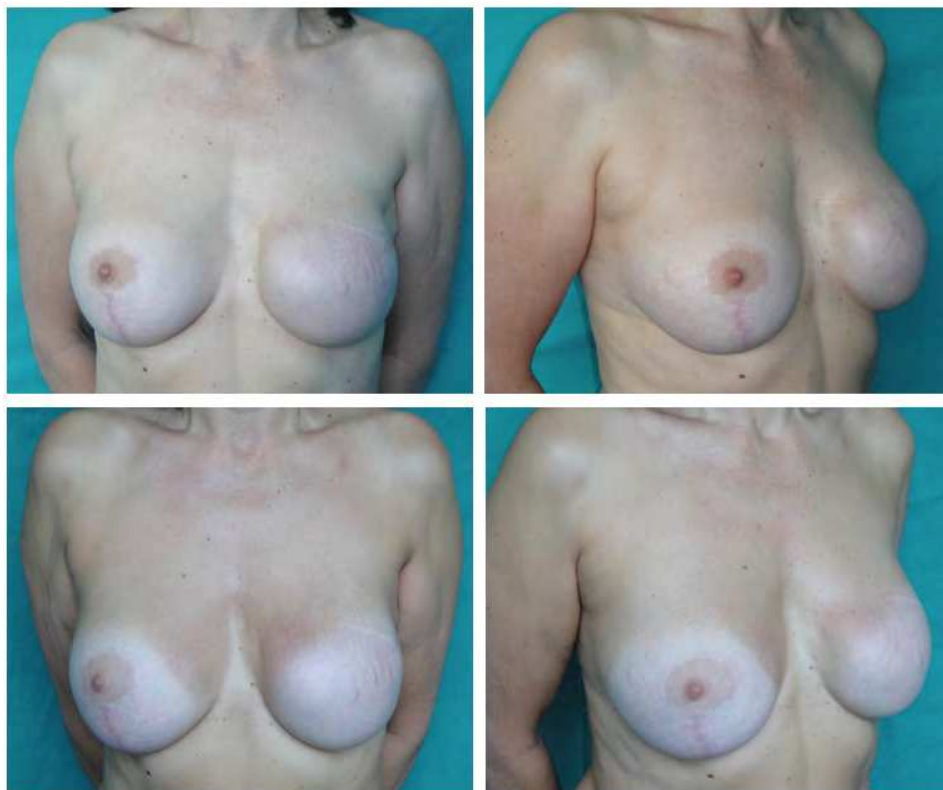


Fig. 21. (above; left, right) Fifteen month postoperative result after left SSM and immediate reconstruction with Silimed Nuance 480 cc and right breast mastopexy with implant (Silimed Natural 120cc). The “step-off” deformity in the upper quadrant of the left breast is evident as well as the implant contour in evident in the medial quadrant. (Below; left, right) Three month postoperative picture after 1 session of fat graft (32cc of grafted fat in the upper quadrant and 30cc grafted in the medial quadrant). The patient is waiting for the NAC reconstruction.

6.5.4 Capsule contracture

In breast implant surgery, capsule contracture represents an important issue. The human body response to the presence of a foreign body is the development of fibrous capsules, as it normally happens around breast implant. However, when this response leads to change of breast shape, induration and even pain it is recognized as capsule contracture. It represents one of the most significant complication in breast implant surgery.

Even if four decades has passed since the introduction of breast implants, the exact pathogenesis of capsular contracture remains unknown. From more recent trends, capsular contracture is attributed to subclinical infection in breast pocket, presence of foreign bodies (i.e. Surgical gloves talc), suture line fibers, silicone particles coming from breast implant surface and last but not the least, especially in breast cancer patients, radiation therapy.

In our SSM series, we did experience 5% of capsular contracture of which 80% developed a Baker IV grade all sharing postoperative radiation therapy and 20% a Baker IV capsular contracture sharing history of infection and retained implants. No capsular contracture has been experienced in SRM cases. In our NSM series, we experience capsular contracture in the only one patient with a history of breast radiation therapy.

In case of capsular contracture in a radiated field, we normally postpone indication to implant removal and autologous tissue reconstruction with DIEAP flap. If the patient has contraindication to the autologous tissue reconstruction or refused it, we perform 3 sessions of lipofilling all around the implant capsule followed by total capsulectomy and implant changing.

7. Conclusion

The immediate one-stage submuscular-subfascial implant reconstruction with hyperprojected silicone-gel filled anatomical implant represents a versatile and valid option in patients undergoing conservative mastectomies if not radiated or planned for radiation therapy. By using this surgical technique, very good aesthetic results, low complication rates, and high patient satisfaction are experienced. The clinical-decision making process in these patients is paramount to maximize the results.

8. Acknowledgment

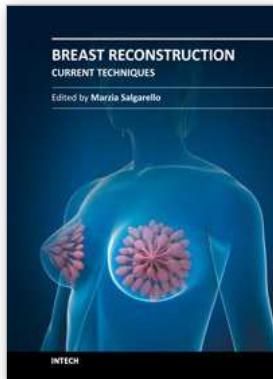
Thanks to Prof. Dr. P.M.N. Werker, Mr. Hepke Gjaltema and Mr. Sip Zwerver for the opportunity, kindness and hospitality for the cadaver dissections at Weckenbach Institute - Skillslab, Universitair Medisch Centrum Groningen, Groningen, The Netherlands.

9. References

- Blondeel PN, Hijjawi J, Depypere H, Roche N, Van Landuyt K. (2009) Shaping the breast in aesthetic and reconstructive breast surgery: an easy three-step principle. *Plast Reconstr Surg.* 2009 Feb;123(2):455-62.
- Carlson GW, Bostwick J 3rd, Styblo TM, Moore B, Bried JT, Murray DR, Wood WC. (1997) Skin-sparing mastectomy. Oncologic and reconstructive considerations. *Ann Surg* 1997 May;225(5):570-5.
- Caruso F, Ferrara M, Castiglione G, Trombetta G, De Meo L, Catanuto G, Carillio G. (2006) Nipple sparing subcutaneous mastectomy: sixty-six months follow-up. *Eur J Surg Oncol.* 2006 Nov;32(9):937-40.
- Chen CM, Disa JJ, Sacchini V, Pusic AL, Mehrara BJ, Garcia-Etienne CA, Cordeiro PG. (2009) Nipple-sparing mastectomy and immediate tissue expander/implant breast reconstruction. *Plast Reconstr Surg.* 2009 Dec;124(6):1772-80.
- Crowe JP, Patrick RJ, Yetman RJ, Djohan R. (2008) Nipple-sparing mastectomy update: one hundred forty-nine procedures and clinical outcomes. *Arch Surg.* 2008 Nov;143(11):1106-10.
- Garcia-Etienne CA, Cody Iii HS 3rd, Disa JJ, Cordeiro P, Sacchini V. (2009) Nipple-sparing mastectomy: initial experience at the Memorial Sloan-Kettering Cancer Center and a comprehensive review of literature. *Breast J.* 2009 Jul-Aug;15(4):440-9. Epub 2009 May 22.

- Gasperoni C, Salgarello M. Preoperative breast marking in reduction mammoplasty. (1987) *Ann Plast Surg.* 1987 Oct;19(4):306-11.
- Gerber B, Krause A, Reimer T, Müller H, Küchenmeister I, Makovitzky J, Kundt G, Friese K. (2003) Skin-sparing mastectomy with conservation of the nipple-areola complex and autologous reconstruction is an oncologically safe procedure. *Ann Surg.* 2003 Jul;238(1):120-7.
- Hartmann LC, Schaid DJ, Woods JE, Crotty TP, Myers JL, Arnold PG, Petty PM, Sellers TA, Johnson JL, McDonnell SK, Frost MH, Jenkins RB. (1999) Efficacy of bilateral prophylactic mastectomy in women with a family history of breast cancer. *N Engl J Med.* 1999 Jan 14;340(2):77-84.
- Hartmann LC, Sellers TA, Schaid DJ, Frank TS, Soderberg CL, Sitta DL, Frost MH, Grant CS, Donohue JH, Woods JE, McDonnell SK, Vockley CW, Deffenbaugh A, Couch FJ, Jenkins RB. (2001) Efficacy of bilateral prophylactic mastectomy in BRCA1 and BRCA2 gene mutation carriers. *J Natl Cancer Inst.* 2001 Nov 7;93(21):1633-7.
- Hunter JE, Malata CM. (2007) Refinements of the LeJour vertical mammoplasty skin pattern for skin-sparing mastectomy and immediate breast reconstruction. *J Plast Reconstr Aesthet Surg* 2007;60(5):471-81.
- Hwang K, Kim DJ. (2005) Anatomy of pectoral fascia in relation to subfascial mammary augmentation. *Ann Plast Surg.* 2005 Dec;55(6):576-9.
- Jinde L, Jianliang S, Xiaoping C, Xiaoyan T, Jiaqing L, Qun M, Bo L. (2006) Anatomy and clinical significance of pectoral fascia. *Plast Reconstr Surg.* 2006 Dec;118(7):1557-60.
- Kanchwala SK, Glatt BS, Conant EF, Bucky LP. (2009) Autologous fat grafting to the reconstructed breast: the management of acquired contour deformities. *Plast Reconstr Surg.* 2009 Aug;124(2):409-18. Review.
- Kroll, S. S., Khoo, A., Singletary, S. E., et al. Local recurrence risk after skin-sparing and conventional mastectomy: A 6-year follow-up. *Plast. Reconstr. Surg.* 104: 421, 1999.
- Laronga C, Kemp B, Johnston D, Robb GL, Singletary SE. The incidence of occult nipple-areola complex involvement in breast cancer patients receiving a skin-sparing mastectomy. *Ann Surg Oncol.* 1999 Sep;6(6):609-13.
- McDonnell SK, Schaid DJ, Myers JL, Grant CS, Donohue JH, Woods JE, Frost MH, Johnson JL, Sitta DL, Slezak JM, Crotty TB, Jenkins RB, Sellers TA, Hartmann LC. Efficacy of contralateral prophylactic mastectomy in women with a personal and family history of breast cancer. *J Clin Oncol.* 2001 Oct 1;19(19):3938-43.
- Menon RS, van Geel AN. Cancer of the breast with nipple involvement. *Br J Cancer.* 1989 Jan;59(1):81-4.
- Mosahebi A, Ramakrishnan V, Gittos M, Collier J. (2007) Aesthetic outcome of different techniques of reconstruction following nipple-areola-preserving envelope mastectomy with immediate reconstruction. *Plast Reconstr Surg.* 2007 Mar;119(3):796-803.
- Nahabedian MY, Tsangaris TN. (2006) Breast reconstruction following subcutaneous mastectomy for cancer: a critical appraisal of the nipple-areola complex. *Plast Reconstr Surg.* 2006 Apr;117(4):1083-90.
- Nava MB, Catanuto G, Pennati A, Garganese G, Spano A. Conservative mastectomies. (2009) *Aesthetic Plast Surg.* 2009 Sep;33(5):681-6.
- Nava MB, Cortinovis U, Ottolenghi J, Riggio E, Pennati A, Catanuto G, Greco M, Rovere GQ. (2006) Skin-reducing mastectomy. *Plast Reconstr Surg* 2006 Sep;118(3):603-10.

- NCCN, National Comprehensive Cancer Network. (2011) Clinical practice guidelines in oncology: breast cancer – version V.2.2011. NCCN, 2011. (last access 30th of August, 2011)
- Petit JY, Veronesi U, Orecchia R, Rey P, Martella S, Didier F, Viale G, Veronesi P, Luini A, Galimberti V, Bedolis R, Rietjens M, Garusi C, De Lorenzi F, Bosco R, Manconi A, Ivaldi GB, Youssef O. (2009) Nipple sparing mastectomy with nipple areola intraoperative radiotherapy: one thousand and one cases of a five years experience at the European institute of oncology of Milan (EIO). *Breast Cancer Res Treat.* 2009 Sep;117(2):333-8.
- Regolo L, Ballardini B, Gallarotti E, Scoccia E, Zanini V. (2008) Nipple sparing mastectomy: an innovative skin incision for an alternative approach. *Breast.* 2008 Feb;17(1):8-11.
- Rivadeneira, D. E., Simmons, R. M., Osborne, M. P., et al. Skin-sparing mastectomy with immediate breast reconstruction: A critical analysis of local recurrence. *Cancer J.* 6: 331, 2000.
- Sacchini V, Pinotti JA, Barros AC, Luini A, Pluchinotta A, Pinotti M, Boratto MG, Ricci MD, Ruiz CA, Nisida AC, Veronesi P, Petit J, Arnone P, Bassi F, Disa JJ, Garcia-Etienne CA, Borgen PI. Nipple-sparing mastectomy for breast cancer and risk reduction: oncologic or technical problem? *J Am Coll Surg.* 2006 Nov;203(5):704-14.
- Salgarello M, Farallo E.(2005) Immediate breast reconstruction with definitive anatomical implants after skin sparing mastectomy. *Br J Plast Surg* 2005; 58: 216-222
- Salgarello M, Visconti G, Barone-Adesi L. (2010) Nipple-sparing mastectomy with immediate implant reconstruction: cosmetic outcomes and technical refinements. *Plast Reconstr Surg.* 2010 Nov;126(5):1460-71.
- Salgarello M, Visconti G, Barone-Adesi L.(2011) Fat grafting and breast reconstruction with implant: another option for the irradiated breast cancer patients. *Plast Reconstr Surg.* 2011 Oct 18. [Epub ahead of print]
- Santanelli F, Paolini G, Campanale A, Longo B, Amanti C. (2010) The "Type V" skin-sparing mastectomy for upper quadrant skin resections. *Ann Plast Surg* 2010 Aug;65(2):135-9.
- Santini D, Taffurelli M, Gelli MC, Grassigli A, Giosa F, Marrano D, Martinelli G. (1989) Neoplastic involvement of nipple-areolar complex in invasive breast cancer. *Am J Surg.* 1989 Nov;158(5):399-403.
- Spears SL., Willey SC, Feldman ED, Cocilovo C, Sidawy M, Al-Attar A, Hannan C, Seiboth L, Nahabedian MY. Nipple-sparing mastectomy for prophylactic and therapeutic indications. *Plastic & Reconstructive Surgery.*, POST ACCEPTANCE, 5 July 2011
- Stolier AJ, Sullivan SK, Dellacroce FJ. (2008) Technical considerations in nipple-sparing mastectomy: 82 consecutive cases without necrosis. *Ann Surg Oncol.* 2008 May;15(5):1341-7. Epub 2008 Feb 7.
- Toth BA, Lappert P. (1991) Modified skin incisions for mastectomy: the need for plastic surgical input in preoperative planning. *Plast Reconst Surg* 1991 Jun;87(6):1048-53.
- Vlajcic Z, Zic R, Stanec S. (2005) Nipple-areola complex preservation: predictive factors of neoplastic nipple areola complex invasion. *Ann Plast Surg* 2005; Vol 55(3): 240-244.
- Warren Peled A, Itakura K, Foster RD, Hamolsky D, Tanaka J, Ewing C, Alvarado M, Esserman LJ, Hwang ES. (2010) Impact of chemotherapy on postoperative complications after mastectomy and immediate breast reconstruction. *Arch Surg.* 2010 Sep;145(9):880-5.



Breast Reconstruction - Current Techniques

Edited by Prof. Marzia Salgarello

ISBN 978-953-307-982-0

Hard cover, 276 pages

Publisher InTech

Published online 03, February, 2012

Published in print edition February, 2012

Breast reconstruction is a fascinating and complex field which combines reconstructive and aesthetic principles in the search for the best results possible. The goal of breast reconstruction is to restore the appearance of the breast and to improve a woman's psychological health after cancer treatment. Successful breast reconstruction requires a clear understanding of reconstructive operative techniques and a thorough knowledge of breast aesthetic principles. Edited by Marzia Salgarello, and including contributions from respected reconstructive breast plastic surgeons from around the world, this book focuses on the main current techniques in breast reconstruction and also gives some insight into specific topics. The text consists of five sections, of which the first focuses on the oncologic aspect of breast reconstruction. Section two covers prosthetic breast reconstruction, section three is dedicated to autogenous breast reconstruction, and section four analyzes breast reconstruction with a fat graft. Finally, section five covers the current approaches to breast reshaping after conservative treatment.

How to reference

In order to correctly reference this scholarly work, feel free to copy and paste the following:

Marzia Salgarello, Giuseppe Visconti and Liliana Barone-Adesi (2012). One-Stage Immediate Breast Reconstruction with Implants in Conservative Mastectomies, *Breast Reconstruction - Current Techniques*, Prof. Marzia Salgarello (Ed.), ISBN: 978-953-307-982-0, InTech, Available from:

<http://www.intechopen.com/books/breast-reconstruction-current-techniques/one-stage-immediate-breast-reconstruction-with-implants-in-conservative-mastectomies>

INTECH
open science | open minds

InTech Europe

University Campus STeP Ri
Slavka Krautzeka 83/A
51000 Rijeka, Croatia
Phone: +385 (51) 770 447
Fax: +385 (51) 686 166
www.intechopen.com

InTech China

Unit 405, Office Block, Hotel Equatorial Shanghai
No.65, Yan An Road (West), Shanghai, 200040, China
中国上海市延安西路65号上海国际贵都大饭店办公楼405单元
Phone: +86-21-62489820
Fax: +86-21-62489821

© 2012 The Author(s). Licensee IntechOpen. This is an open access article distributed under the terms of the [Creative Commons Attribution 3.0 License](#), which permits unrestricted use, distribution, and reproduction in any medium, provided the original work is properly cited.