

Laparoscopic Ureteroureterostomy

Oner Sanli, Tzevat Tefik and Selcuk Erdem

Department of Urology, Istanbul Faculty of Medicine, Istanbul University,
Turkey

1. Introduction

Ureter is the conduit carrying urine from renal pelvis to bladder. Since it has long course; many extrinsic pathologies, intrinsic mural anomalies and luminal defects may affect continuity of the ureter. Ureteric reconstruction aims to achieve integrity of the urinary tract in pathological conditions while preserving renal function. However, ureteric reconstruction is one of the challenging procedures in urology since the length and location of the problematic ureter or underlying pathology does not allow performing one kind of surgery in all situations.

The level of ureteral disease is indicative to make a decision on appropriate reconstructive procedure. The repair of 2/3 proximal ureter located above the pelvic brim is generally more demanding. Ureteroureteral anastomosis (ureteroureterostomy) is a suitable procedure for short pathologies located in the mid- and proximal ureter; meanwhile transureteroureterostomy, ureteral substitution and renal autotransplantation techniques are useful for large affected ureteral disease. (Png & Chapple, 2000) On the other hand, ureteroneocystostomy, Boari's flap or psoas hitch procedures are well-accepted treatment alternatives for the 1/3 distal part of ureter below the pelvic brim. All techniques may be performed with open, laparoscopic and robot-assisted laparoscopic approaches.

In the last 20 years, urological community witnessed a revolution that; traditional open surgery has been largely replaced by endoscopic and laparoscopic techniques. This radical leap has gained widespread acceptance due to well-documented advantages of minimally invasive surgery. Since the introduction of laparoscopy in the field of urology, the number of centers performing this approach has been increasing steadily. It is acknowledged that laparoscopy provides surgical outcomes with efficacy equal to that of open surgery. (Guillonnet al., 2001) For this reason, more clinics are adapting the trend of laparoscopy. Due to the clear advantages of laparoscopic surgery, the indications of this approach have expanded dramatically over the years. (Dunn et al., 2000) Similarly, the renowned benefits of minimal invasive surgery such as less pain, quicker convalescence and improved cosmesis are also well perceived by the patients. Moreover, decreased intra-operative blood loss, lesser need of transfusions and shortened hospital stay makes this approach as a "*sine qua non*" of the current and future urologic surgery.

Even though, laparoscopic ureteroureterostomy (LUU) has been performed in major tertiary centers, where the surgeons facile with laparoscopic techniques and perfect surgery; the wide application of laparoscopy in many centers throughout the world encourages experienced surgical teams to perform challenging procedures such as LUU. Accordingly,

this chapter will focus on LUU performed for relatively small pathologies that affect proximal 2/3 part of ureter.

2. Laparoscopic anatomy of ureter

The ureter when measured from the ureteropelvic junction (UPJ) to the bladder is about 28 to 34 cm long. Anatomically, the ureter is divided in three segments. The proximal ureter extends from the UPJ to the area where the ureter crosses sacroiliac joint, the middle ureter courses over the bony pelvis and the distal ureter extends from the iliac vessels to the bladder. (Pereira et al., 2010) Each ureter passes over the medial part of the psoas major in the line with the ends of the transverse processes of the lumbar vertebrae. Then they cross the genitofemoral nerve and pass under the gonadal vessels into the pelvis near the bifurcation of the common iliac vessels (CIVs). After crossing the CIVs, the ureters follow the course of internal iliac artery and run along the anterior border of the greater sciatic notch. Thereupon, they turn medially at the ischial spine and lie along the levator ani just before entering the bladder. (Hinman, 1993) The vas deferens crosses in front of the ureters while the ureters; pass in front of the end of the seminal vesicle in the male. Whereas, in the female, they lie behind the ovary and at the ischial spine are in close proximity with the suspensory ligament of the ovary. The ovarian vessels make an oblique crossing over the ureters as a potential vulnerable site for injury in gynecological operations. After entering the parametrium of the broad ligaments, they run through the uterosacral, cardinal and vesicouterine ligaments. Then, they cross the lateral and posterior parts of the uterine arteries. The left ureter crossing the uterine artery runs anteromedially about 1 cm above the lateral vaginal fornix and from 1 to 4 cm lateral to the cervix passes through the anterior aspect of the vagina before entering the bladder. Thus, ureter is mostly injured as it crosses inferior to the uterine artery. (Elliot & McAninch, 2006)

The blood supply of the ureter is so remarkable with multiple arteries anastomosing along its length. Thus, the division of any of the ureteral arteries does not usually produce ischemia. (Anderson et al., 2007) The proximal ureteral arteries most often are supplied by the renal arteries (30%). The aorta provides 15% and the gonadal arteries 8% of its blood supply. Distally, the superior (12%) and inferior (12%) vesical arteries and internal iliac arteries (9%) provide the arterial supply to the lower portion of the ureter. (Hinman, 1993) The uretero-subperitoneal arteries lie outside the ureteral sheath. At the ureteral wall the arteries divide into "ureteral" arteries supplying the periureteral arterial plexus and the "subperitoneal" arteries supplying the periureteral tissue. (Landman & Pattaras, 2005) It is important to know that; the blood supply of the ureter in the abdomen is medial, while in the pelvis the blood supply is lateral. The ureteral arteries divide on the entering the loose ureteral sheath into long ascending and descending branches. Whereas; the subperitoneal arteries supply the periureteral tissue and provide a distribution to the peritoneum. Venules are distributed as a delicate network throughout the ureteral adventitia. The proximal ureter is drained via small veins into the renal or gonadal veins whereas; the distal end drain into those of broad ligament (in females), pelvic plexus and adjacent veins.

3. Patient selection and diagnostic work-up

Iatrogenic or traumatic injuries of the proximal 2/3 of the ureter, proximal ureteral stricture (e.g. due to stone, radiation, inflammation), retrocaval ureter (RCU) presenting

with reduced ipsilateral kidney function or symptomatic, ureteral endometriosis, proximal ureteral obstruction (e.g: crossing vessels, neoplasia, aberrant ureteral position, valves), ureteral ectopia and some duplication anomalies of the urinary tract (e.g. functioning upper pole hydronephrosis without ureterocele) are the main indications of LUU. In most cases, a kind of imaging modality such as intravenous urography (IVP) or computerized tomography (CT) urography is needed to demonstrate the site of ureteric problem or intrinsic or extrinsic pathology leading to hydronephrosis. If these imaging modalities are inconclusive, a cystoscopy and retrograde or antegrade pyelography are useful for identifying pathological processes. For some cases having problems such as diminished vascular supply or concomitant infection that may impair wound healing leading to urinary extravasation after surgery, placement of nephrostomy tube is advocated. In those cases, the nephrostomy tube should be kept in place until ensuring the patency of the anastomosis.

Before surgery, the patient should undergo routine preoperative laboratory investigations, including total blood count, kidney function tests, and coagulation tests [such as, prothrombin time, partial thromboplastin time, and international normalized ratio (INR)]. Meanwhile, preoperative preparation of the patient should also include early withdrawal of drugs, such as acetylsalicylic acid or anticoagulants that affect platelet function. It is worth mentioning that, chronic renal failure or receiving hemodialysis treatment is not contraindications for laparoscopic ureteric reconstruction. (Sanli et al., 2010)

4. Preoperative auxiliary instrumentation

Laparoscopic ureteroureterostomy can be performed with transperitoneal (TP) or retroperitoneal (RP) approaches. Whether TP or RP approach is being used, it may be time saving to insert preoperatively a double-J (DJ) stent in low dorsal lithotomy position. In case of strictures or obstruction in the ureteral segment where the DJ stent cannot be inserted, it is advised to leave a ureteral stent as much as closed to the obstruction with its tether secured to the glans penis in males or the ipsilateral groin in females. This method will probably ease finding of pathological ureteral segment especially in cases of severe fibrosis. In addition, it is generally advocated to receive a clear liquid diet for 24 hours and a rectal suppository a night before the procedure.

5. Laparoscopic ureteroureterostomy - Surgical technique

The principles of laparoscopic ureteric reconstruction are not different from those established for open surgery. These are ensuring good vascular supply in both ureteric ends with care to preserve the adventitia, complete excision of pathological lesions or nonviable tissue to a bleeding edge, good drainage with stenting and a wide spatulated and adequate ureteric end for tension-free anastomosis of mucosa to mucosa. (Elliot & McAninch, 2006; Png & Chapple, 2000)

5.1 Transperitoneal (TP) approach

After insertion of a Foley urethral catheter the patient is secured in a modified flank position over the kidney break at a 45-60° angle. A Veress needle is used to create a pneumoperitoneum and a 10-mm camera port is inserted at the level of umbilicus just

lateral to the rectus abdominis muscle. On the occasion that the patient is slim; umbilicus may be used for this purpose. In right sided LUU, a 5-mm and a 10-mm port is inserted at the 1/3 caudal and 1/3 cranial points along a virtual line between xiphoid process and anterior superior iliac spine), respectively. Whereas, in case of left sided LUU, 5 and 10-mm port are inserted vice versa.

After proper port placement, the line of Toldt is incised and the colon is deflected medially to provide exposure of the RP (retroperitoneal) structures including inferior vena cava, ureter, gonadal vein, duodenum and renal pelvis in right side; ureter and gonadal vein in the left side. Subsequently, the ureter is found with proper RP dissection and problematic segment is visualized. This problematic ureter is then resected, making sure to reach healthy, well vascularized ureteral ends. If the situation is an injury due to thermal injury, wide debridement may be required because microvascular damage can extend for 2 cm beyond the evidence of visible injury. (Amato et al., 1970)

5.2 Retroperitoneal approach

For RP approach, the patient is placed in full lateral decubitus position with overextension in order to increase the distance between the ports. For port position, an incision is made below the 12th rib in the posterior axillary line for 10-mm camera port and after division of muscular layer and lumbodorsal fascia RP space is entered and dilated with a balloon dissector. A 5-mm trocar is inserted below the costal margin in the anterior axillary line and another 10-mm trocar is inserted 2 cm above the superior border of iliac crest in the midaxillary line in right sided cases. Ten and 5-mm trocars are inserted vice versa in left sided cases.

5.3 Ureteroureterostomy technique

Spatulated ureteroureterostomy (UU) is the gold standard technique in patients with good vascular supply in both ureteric ends and adequate ureteric length for tension-free anastomosis. If the lengths of proximal or distal ureter do not allow tension free anastomosis, kidney may be mobilized for gaining some extra length. Generally the following basic approach is applied: After adequate exposure, both upper and lower ureter is transected sharply and spatulated laterally and medially as needed. Spatulation helps the meticulous watertight suturing while preventing the rotation of the ureter. One of the essential roles of the spatulation process is the preservation of the longitudinal ascending and descending branches of the ureteral arteries as well as allows wider luminal diameter. It is accepted that the placement of stay sutures can improve one's ability to properly direct the incisions while minimizing trauma to the tissues. (Lucas & Sundaram, 2011) However, it should be noted that placing stay sutures may need extra trochars for making them functional. Instead of this 12 o'clock and 6 o'clock sutures may be used for this purpose (Figure 1 and 2). Thereupon, a tension-free watertight UU is fashioned (over a DJ stent) using posterior and anterior wall closures of interrupted or running stitches with absorbable suture materials such as 4-0 or 5-0 polyglactin/polydioxanone sutures. The authors of the present chapter prefer to use interrupted sutures which are not too close together (2-3 mm apart) to prevent ischemia of the suture line.

Before completion of the reconstruction, if not inserted before, a DJ stent is placed to secure the anastomosis (Figure 3 and 4). However, one should be ensured that proximal end of the stent is in the renal pelvis; while distal end in the bladder. The proximal end of the stent may be visualized in the proximal ureter or renal pelvis but sometimes it may be difficult to observe the distal end if it is in the bladder. For confirming this issue, the bladder may be filled with methylene blue via the urethral catheter and observe reflux of blue urine through the stent. At the last occasion, cystoscopy may be performed to see the stent within the bladder. For securing the anastomosis and facilitate wound healing, repaired ureteral segment may be wrapped with an omental flap in transperitoneal approach. Subsequently, if placed stay sutures are released and haemostasis is checked with lowering the pressure of pneumo- or pneumoretroperitoneum to 4 mmHg. Eventually, a drain is positioned over the renal fossa and left overnight with a Foley urethral catheter. For injuries at or below the pelvic brim, ureteroneocystostomy should be the treatment of choice which is beyond the scope of this chapter.

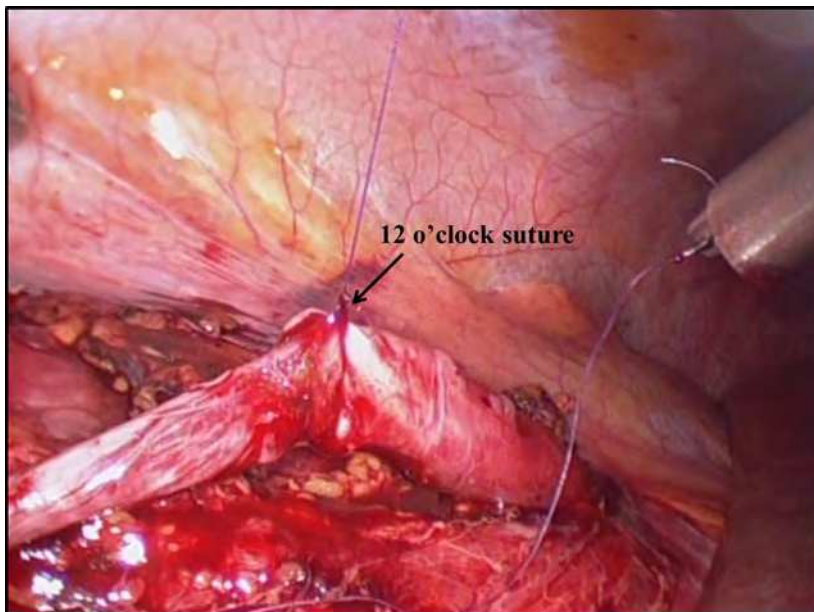


Fig. 1. "12 o'clock suture" is used as stay suture that helps direct visualization and minimizing trauma to surrounding tissues

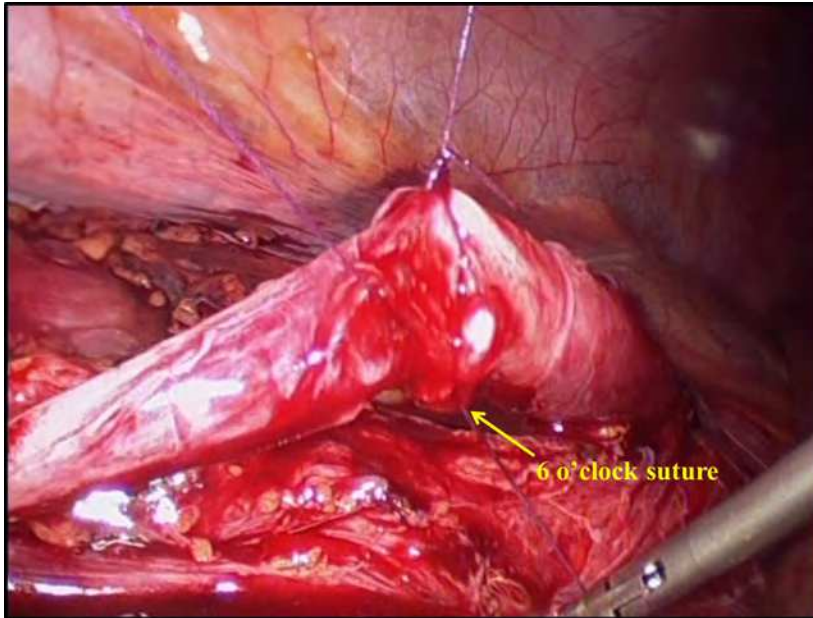


Fig. 2. "6 o'clock suture" helps completion of anterior and posterior closure of anastomosis separately

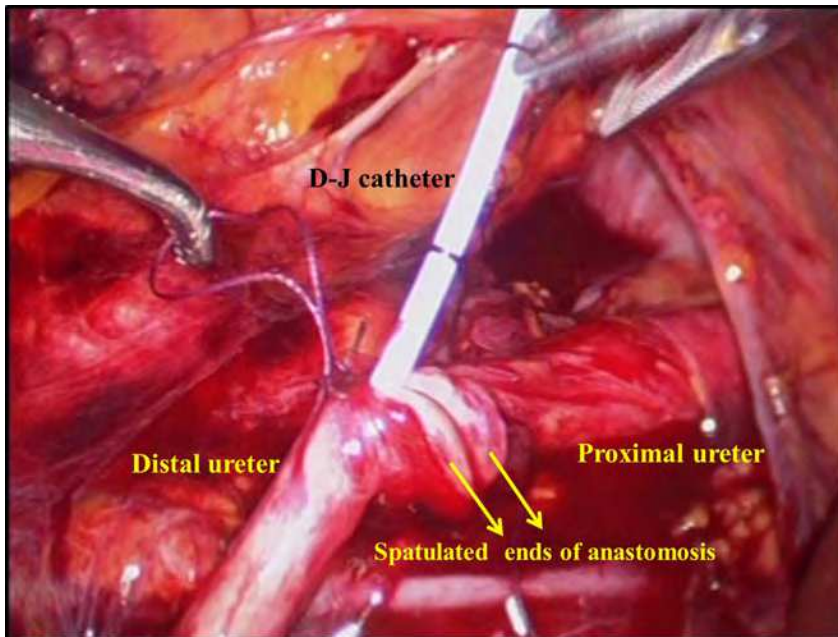


Fig. 3. Double J catheter insertion through anterior wall of anastomosis

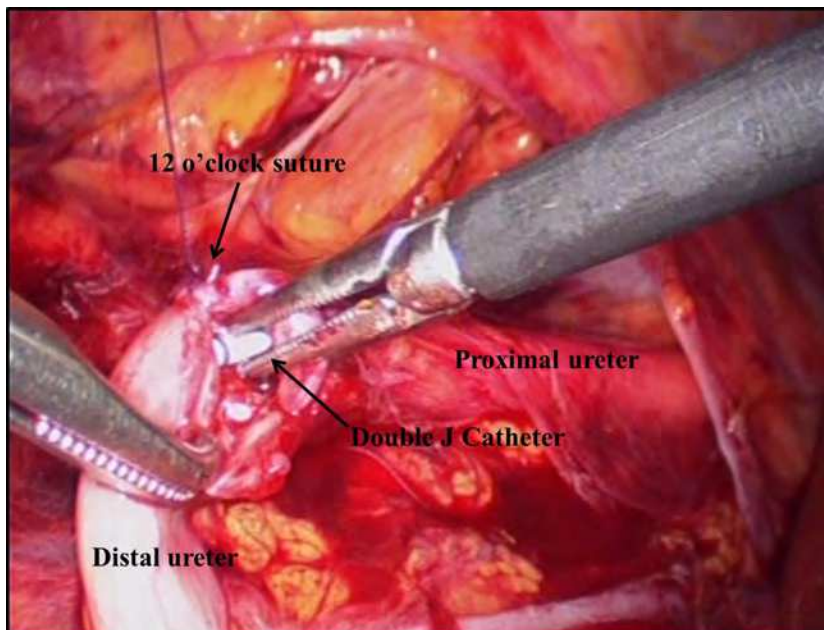


Fig. 4. Double J catheter inserted into renal pelvis

6. Transuretero-ureterostomy technique

Before Hendren popularized transuretero-ureterostomy (TUU) for use in undiversion, the technique has been restricted to patients who had suffered trauma or disease to the distal ureter, the excision of which left a defect that was too long to be bridged by mobilizing the bladder upwards by any means. (Hendren, 1973; Hodges et al., 1963) Other indications of TUU are cystectomy and substitution cystoplasty, Mitrofanoff-type urinary diversion and failed urinary diversion. (Kaiho et al., 2011; Noble et al., 1997) In 1999, Dechet et al. demonstrated the feasibility of laparoscopic TUU in a porcine model. (Dechet et al., 1999) Piaggio and Gonzalez first reported successful laparoscopic TUU in 3 children with ureteral obstruction, refluxing megaureter and ureteral injury after bladder diverticulectomy. (Piaggio & Gonzalez, 2007) The basic principles in open TUU are valid for the laparoscopic surgery, as well. These are mobilizing the ureter to be transposed across the posterior abdominal wall above the point of origin of the inferior mesenteric artery (to avoid kinking), to mobilize the recipient ureter to reduce the tension and to use an appropriate caliber stent across anastomosis. (Noble et al., 1997) For anastomosis, a small elliptic portion is excised from the medial wall of the recipient ureter and after spatulation of the donor ureter, an end to side anastomosis is performed. (Pesce et al, 2001) Although transuretero-ureterostomy has been proved to be safe and effective procedure, its place should certainly be restricted to ureteric defects above the pelvic brim, where a ureteroneocystostomy is not possible. (Png & Chapple, 2000) Transuretero-ureterostomy is a challenging approach used in selective cases; laparoscopic TUU is even more arduous because of the difficulty of passing donor ureter under mesocolon to the recipient ureter and currently should be reserved for very experienced referral centers. It is worth mentioning that inadequate surgical technique

leading to urine leakage and subsequent stricture may compromise the drainage of the patent system. This is also valid for donor ureters with compromised vasculature due to radiation treatment or periureteral infection. Meanwhile TUU is discouraged if the renal unit on the side of injured ureter has minimal function.

7. Post-operative care and follow-up

In case of doubt, a plain abdominal film may be obtained to confirm the stent position. Since ureteral reconstruction generally leads to clean-contaminated wound, prophylaxis with 2nd generation cephalosporins is suggested. (Grabe et al, 2011) However, in case of positive urine culture before surgery, suitable antibiotics according to urine culture should be continued at least 7-10 days. The DJ stent should be removed in 2-6 weeks postoperatively. Retrograde pyelography (RGP) is not necessary while removing DJ catheter. We do not advocate DJ stents with an externalized tether since they may be a source of urinary tract infection (UTI). An IVP obtained 3 months after the operation can demonstrate the patency of anastomosis and is an excellent follow-up modality to discover any problems in continuity of urinary tract. The IVP can also demonstrate strictures and irregularities of reconstructed ureter. In case of any patency suspicion a 3-dimension reconstruction of a CT or magnetic resonance (MR) urography can facilitate the diagnosis. Six, 12 month and thereafter yearly follow up with IVP and yearly renal ultrasonography is recommended for 3 years.

8. Associated complications

Urinary tract infection, bleeding, haematoma formation, prolonged urine leakage from the drain and concomitant ileus (in TP approach) are the early complications that can be encountered with LUU. Meanwhile urinoma formation, retroperitoneal abscess and peritonitis may occur. The rate of early complications was found to be 3.8% (n= 4) in 109 renal units with the evaluation of the current literature (Table 1-4)

Urinary tract infection can be managed with administration of antibiotics; the bleeding may require re-exploration, whereas haematoma can be followed with serial haematocrit counts and ultrasonography. Prolonged leakage from the drain and ileus due to urinary leakage may require replacement of DJ stent under fluoroscopic control or nephrostomy tube placement.

Ureteral stricture, fistulae formation, undrained urinoma formation and periureteral abscess are the late complications that may require re-exploration and anastomosis revision. The rate of late complications was found to be 2.8% (n= 3, Table 1-4) in 109 renal units mentioned in the literature.

9. Outcomes analysis

In 1949 Anderson and Hynes published the first case of UU for retrocaval ureter. (Anderson & Hynes, 1949) Currently, open ureteric reconstruction is the standard of care. LUU has been successfully used for surgical correction of reterocaval ureters (RCU) since 1994. (Baba et al., 1994)

Retrocaval ureter is a rare congenital abnormality (incidence of 1 in 1000) that results in external ureteral compression by the inferior vena cava (IVC) and becomes symptomatic in the 3rd or 4th decade of life. Its etiology is presumed to be abnormal embryologic

Author	Baba 1994	Polasek 1998	Solomon 1999	Mugiya 1999	Amada 2001	Gupta 2001	Ramalingam 2001	T-Machado 2005a	Xu 2008	Singh 2010	Li 2010	Autorcio 2010	Santli 2010
Indication	RCU	RCU	RCU	RCU	RCU	RCU	RCU	RCU	RCU	RCU	RCU	RCU	RCU
Approach	Trans.	Trans.	Retro	Retro	Trans/Retro	Retro	Trans	Retro	Retro	Trans	Retro	Trans	Trans
Method	Traditional	Traditional	Traditional	Traditional	Traditional	Traditional	Traditional	Traditional	Traditional	Traditional	Traditional	Single site	Traditional
No of cases	1	1	1	1	1/1	1	2	1	7	1	10	1	3
Mean Operative Time (min.)	570	225	270	300	450-400	210	225	130	128.6	120	82	180	118
Anastomosis Time (min.)	150	45	NA	NA	NA	NA	NA	40	36	NA	NA	NA	38.3
Anastomosis Technique	Interrupted	Interrupted	Interrupted	Running	Interrupted	Interrupted	Interrupted	Running	Interrupted	NA	Interrupted+running	Running	Interrupted
No of Ports	5	3	4	4	4/4	3	4	3	3	4	3	Single port	3
Estimated Blood Loss (ml)	NA	NA	<20	50	<20	NA	Insignificant	50	20 (15-50)	NA	< 10	NA	76
Ureteral stent placement	NA	Preop.	NA	Preop.	Preop.	NA	NA	NA	NA	NA	NA	NA	Preop./none
Double J Placement	Intraop.	Intraop.	Preop.	Intraop.	Intraop.	Preop.	Preop	Intraop.	Intraop.	Intraop.	Intraop.	Preop.	Preop./Intraop
Foley removal (days)	NA	2	NA	NA	NA	NA	NA	NA	5-7	NA	2	1	2.6
Drain removal (days)	NA	NA	2	5	1/1	2	3	NA	NA	2	NA	2	2.6
Hospital Stay (days)	9	4	7	NA	NA	3	4.5	2	6.5 (5-9)	3	6.5	2	3.3
DJ removal (weeks)	NA	4	4	12	4/4	6	8	6	4-6	4	4-6	4	4
Follow up (months)	NA	4	6	6	NA	3	7	3	16	4	52	3	4.3
Recovery	uneventful	uneventful	Uneventful	Uneventful	uneventful	uneventful	uneventful	uneventful	uneventful	uneventful	uneventful	uneventful	Uneventful
Complications	none	none	none	None	None	None	1 (leak)	none	None	none	none	none	None
Postoperative complications	none	None	none	none	None	None	none	none	none	none	None	none	none
Late on-set complications	none	None	none	none	None	None	none	none	none	none	None	none	none

Author suggested extracorporeal anastomosis to reach shorter operative time
 *This report includes two case; ureteroureterostomy and pyeloplasty, only informations about ureteroureterostomy listed in this table.
 NA: Not available

Table 1. Studies evaluating LUU for RCU.

Author	Nezhat 1992	Nezhat 1996	Sinforoso 2005	Ou 2005	Chakraborty-Singh 2007	Simmons 2007	Carvalho 2008	Mereu 2008
Indication	Endometriosis	Endometriosis	Transitional Cell Carcinoma	Stricture	Transsected	Stricture	Stricture	Endometriosis
Approach	NA	NA	Trans.	Trans.	Trans.	Trans.	Trans.	Trans.
Method	Traditional	Traditional	Traditional	Traditional	Traditional	Traditional	Traditional	Traditional
No of patients	1	8	1	4	2	5	1	17
Mean Operative Time (min.)	187	NA	NA	100-240	NA	NA	NA	NA
Anastomosis Time (min.)	35	NA	NA	NA	NA	NA	NA	NA
Anastomosis Technique	Interrupted	NA	Running	Interrupted	Interrupted	NA	NA	Interrupted
No of Ports	NA	NA	3	5	3	4	4	4
Estimated Blood Loss (ml)	NA	<100	NA	NA	NA	86	NA	NA
Ureteral stent placement	NA	NA	NA	Preop.	Preop.	NA	Preop.	NA
Double J Placement	Preop.	NA	Intraop.	Preop.	Intraop.	Intraop.	Intraop.	Intraop.
Foley removal (days)	1	NA	NA	NA	6	NA	8	NA
Drain removal (days)	1	NA	NA	NA	4.5	5-7	12	NA
Hospital Stay (days)	2	NA	3	1.5	3	3	NA	NA
DJ removal (weeks)	6	NA	NA	6	6	4-6	6	NA
Follow up (months)	3	24	9	12	5	24	6	NA
Recovery	Uneventful	Uneventful	Uneventful	Uneventful	Uneventful	Uneventful	Uneventful	Uneventful
Complications								
Postoperative complications	None	None	None	None	None	None	None	none
Late on-set complications	None	1 (stricture)	None	none	none	None	none	2 (stricture)

NA: Not available

Table 2. Studies evaluating LUU for different indications.

Author	Bhandarkar 2012	Nagrui 2012	Gonzalez 2012	Kurthoy 2012 [§]	Pitagallo 2012 [§]	Stewart 2012	Strom 2011
Indication	Congenital midureteral stricture	Retrocaval Ureter	Duplicated ureter	Duplicated ureter	Different etiologies [§]	Duplicated ureter	Duplicated ureter
Approach	Trans.	Trans.	Trans.	Trans.	Trans.	Trans.	Trans.
Method	Traditional	Traditional	Traditional	Traditional	Traditional	Traditional	Traditional
No of patients	4	1	6 (8 operation)	3	3	2	7
Mean Operative Time (min.)	NA	100	257	186	263,6	120	187
Anaestomosis Time (min.)	NA	NA	NA	NA	NA	NA	NA
Anastomosis Technique	Interrupted	NA	Interrupted+running	Running	Running	Running	Interrupted+Running
No of Ports	3	3	3-4*	3	4	4	3
Estimated Blood Loss (ml)	NA	NA	2.7	NA	47	NA	Minimal
Ureteral stent placement	Preop.	NA	Preop.	Preop.	Preop.	Preop.	Preop.
Double J Placement	Preop.	Intraop.	Intraop.	Intraop.	Preop.	NA	Preop.
Foley removal (days)	2	NA	1.5	NA	1-2	2.5	2
Drain removal (days)	2	2	2	NA	1-2	2	No drain
Hospital Stay (days)	4	3	3	2.25	3.33	5.5	2
DJ removal (weeks)	6	2	3	6	2-4	1	4-6
Follow up (months)	18	2	10.7	3	6	6	8
Recovery	Uneventful	Uneventful	Uneventful	Uneventful	uneventful	Uneventful	Uneventful
Complications	None	None	2 (febril UTI)	none	1 (urine leakage) [§]	None	None
Postoperative complications	none	none	none	None	none	None	none
Late on-set complications	none	none	none	None	none	None	none

* Three ports for unilateral, four ports for bilateral duplication
[§]This report includes three laparoscopic ureteroureterostomies, two robot-assisted laparoscopic ureteroureterostomy and one laparoscopic Scardino-Princee flap. Table only lists three laparoscopic ureteroureterostomies
[§]Consists of laparoscopic transureteroureterostomies
[§]Unilateral ureteral obstruction after cross-trigonal reimplantation for vesicoureteral reflux, unilateral refluxing megaureter and ureteral injury after bladder diverticulectomy
[§]Spontaneously resolved in less than 24 hours
 NA: Not available

Table 3. Studies evaluating LUU performed for diffent indications in pediatric urology.

Author	Yeze 2006	Mafarriji 2007	Hemal 2008	Passerotti 2008	Lee 2009	Smith 2009
Indication	Obstructed upper pole with renal ectopia	Stricture	Retrocaval ureter	Midureteral stricture*	Stricture-Transsection	Pediatric; RCU crossing vessels
Approach	Trans.	Trans.	Trans.	Trans.	Trans.	Trans.
Method	Robo-assisted	Robo-assisted	Robo-assisted	Robo-assisted	Robo-assisted	Robo-assisted
No of patients	1	2	1	3	3	2
Mean Operative Time (min.)	485	218.5	NA	244	136.6	283.5
Anastomosis Time (min.)	NA	NA	NA	NA	NA	NA
Anastomosis Technique	Running	Running	Interrupted	Interrupted	Running	Running
No of Ports	4	4	4	4	4	4
Estimated Blood Loss (ml)	15	55	NA	21.7	NA	12.5
Ureteral stent placement	Preop.	Preop.	NA	NA	Preop.	NA
Double J Placement	Intraop.	Intraop.	Intraop.	Preop.	Intraop.	Preop.
Foley removal (days)	2	NA	1	NA	NA	1
Drain removal (days)	2	NA	1	NA	NA	1
Hospital Stay (days)	3	2.5	3	3.5	3	1
DJ removal (weeks)	4	NA	6	NA	6	½
Follow up (months)	3	12.5	3	11.6	24	1
Recovery	Uneventful	Uneventful	Uneventful	Uneventful	Uneventful	Uneventful
Complications						
Postoperative complications	None	None	None	None	None	None
Late on-set complications	none	None	none	None	None	none

*ureteral valve, an inflammatory response with polyanteritis nodosa, an ureteral stone associated stricture

NA: Not available

Table 4. LUU'ies performed with robotic technology.

development of the IVC, which results from the major portion of the infrarenal IVC being formed from the subcardinal vein that lies ventral to the ureter. (Considine, 1966) For the first time, Baba et al performed a TP approach in a case of RCU with mean operative time (OT) of 570 min. and an interrupted anastomosis in 150 min. (Baba et al., 1994) A decade was needed to shorten the OT to 82 min. reported by Li et al. (Li et al., 2010) Ten cases in the literature were performed through the TP approach with a mean OT of 235 min., whereas 22 cases with a RP approach having mean OT of 138 min do exist (Table 1). Even though the OT in RP approach is shorter, retroperitoneoscopy has its own disadvantage of limited working space for laparoscopic manipulation. On the contrary, the advantage of RP approach is the rapid and direct access to renal pelvis and ureter without violating the peritoneal cavity. (Li et al., 2010) Even if a decent number of authors claim that the RP-LUU is less time-consuming (Ameda et al., 2001; Gupta et al, 2001; Li et al., 2010; Mugiya et al., 1999; Salomon et al., 1999; Tobias-Machado et al., 2005; Xu et al., 2009); some prefer the TP access and affirm that it is easier than the RP approach. (Ameda et al., 2001; Autorino et al., 2010; Baba et al., 1994; Polascik & Chen, 1998; Ramalingam & Selvarajan, 2003; Sanli et al., 2010; Singh et al., 2010) Given the small number of cases reported in the literature, and bias from case selection; the OT favors the RP approach, nonetheless the surgeon should prefer the method that is most familiar with.

There is a general impression that performing an anastomosis with interrupted sutures is safer while performing UU. Most of the authors reporting LUU for RCU used interrupted suturing technique. (Ameda et al., 2001; Baba et al., 1994; Elliot & McAninch, 2006; Mugiya et al., 1999; Polascik & Chen, 1998; Ramalingam & Selvarajan, 2003; Salomon et al., 1999; Sanli et al., 2010; Xu et al., 2009) However, none of the authors using running sutures have reported any complication regarding urine anastomotic stricture. (Autorino et al., 2010; Li et al., 2010; Mugiya et al., 1999; Tobias-Machado et al., 2005) Li et al., has used posterior ureteroureteral anastomosis with running suture which every 2 sutures were coupled with a lock-stitch suture and anterior interrupted suture anastomosis. This technique reduced their OT to a mean of 82 min without compromising the anastomosis. Meanwhile, some authors advocate performing pyelopyelostomy instead of UU; because it is less likely to produce stricture formation due to the larger caliber structures as well as better blood supply in the level of renal pelvis. (Bhandarkar et al., 2003; Dogan et al., 2010; Simforoosh et al., 2005) We believe that this technique is a rational option especially for patients with Type I retrocaval ureter which is characterized by S or fish-hook deformity of the ureter and is usually associated with moderate to severe hydronephrosis (Type II RCU is sickle-cell shaped and is associated with mild hydronephrosis). In addition, pyelopyelostomy with the preservation of retrocaval segment was suggested by Simforoosh et al. (Simforoosh et al., 2005) The authors' rationale for leaving the retrocaval segment was the dysplastic and narrow nature of this segment which may not be suitable for UU. Meanwhile, leaving this segment may also prevent some complications such as venous bleeding during dissection of vena cava.

Meanwhile, some authors placed a ureteral stent preoperatively and insert a DJ catheter during the operation (Ameda et al., 2001; Baba et al., 1994; Li et al., 2010; Mugiya et al., 1999; Polascik & Chen, 1998; Sanli et al., 2010; Singh et al., 2010; Tobias-Machado et al., 2005; Xu et al., 2009) Others, insert preoperatively a DJ stent and postulate that lessens OT. (Autorino et al., 2010; Gupta et al., 2001; Ramalingam & Selvarajan, 2003; Salomon et al., 1999; Sanli et al.,

2010) As mentioned before, we believe that placement of a DJ catheter before the operation is time saving.

In order to decrease the OT different approaches have been utilized. Tobias-Machado et al performed the anastomosis extracorporeally. (Tobias-Machado, 2005) The ureteral ends were exteriorized through the incision of the 12-mm port after enlarging the skin incision to 20-mm. Despite decreasing the OT, we believe that exteriorizing the ureteral ends require additional dissection of the ureters which may impair the ureteral blood supply. Meanwhile, a half open (extracorporeal) technique does not address and fit the rationale laparoscopy. Nevertheless, it may be rational to suggest the use of this technique to novice laparoscopists with limited dexterity for intracorporeal suturing.

Ureteral strictures (US) due to ureteral trauma, inflammation, stones or radiation are the leading indications for UU. Although, trauma to the ureter is relatively rare and accounts for only %1 of all urinary tract trauma, 75% of ureteric trauma is iatrogenic and of these 73%, 14% and %14 are in gynecological, urological and general surgical in origin, respectively. (Dobrowolski et al., 2002; Lynch et al., 2005) There is a trend of increase in incidence of iatrogenic urological trauma from 1990's due to development of new techniques such as ureteroscopy and laparoscopy. Ureteroscopy results in ureteral perforation in 2-6% of cases which is a significant risk factor for ureteral stricture. (Elliot & McAninch, 2006) LUU should be considered in patients with unsuccessful attempts by using standard minimal invasive therapies such as balloon dilatation and endoureterotomy with laser or electrocautery. While repairing the stricture, the length of the stricture has always been a subject of debate achieving tension-free anastomosis. Ou et al. published 3 cases of LUU performed on patients with US having operated for laparoscopic hysterectomy. (Ou et al., 2005) They have trimmed the necrotic tissue on ureteral ends, performed tension free LUU over DJ catheter and wrapped the repair with omentum. The authors suggested using LUU; when the injury is not close to the bladder and involves less than 1.5 cm of the ureter. They probably mentioned the use of this technique in strictures less than 1.5cm based on their clinical experience; but we believe that depending on the tortuosity of the ureter, more lengthy strictures may be repaired with LUU. Since for open surgery, it is known that defects up to 3 cm can be repaired at once without tension. (Mayor & Zingg, 1976) Meanwhile, if the defect is larger, this tension may be reduced by mobilizing and straightening its pelvic part. Cholkeri-Singh et al. have published 2 cases of laparoscopic ureteral repair after ureteral injury during laparoscopic procedures. (Cholkeri-Singh et al., 2007; Table 2) Similarly, Carvalho et al have reported successful repair of ureteral injury after hernia repair by LUU. (Carvalho et al., 2008) Furthermore, Simmons et al published 5 cases of LUU after stricture. (Simmons et al., 2007) All these authors acknowledge that favorable laparoscopic approach is possible if performed with the assistance of experienced surgeons.

Despite very limited evidence in the literature, laparoscopic segmental ureterectomy was suggested as alternative to open segmental ureterectomy for low grade transitional cell carcinoma (TCC) of the proximal and mid ureter. (Simforoosh et al., 2005) However, while performing this operation, one should leave a 1 cm safety margin proximally and distally and frozen section analysis for the both ureteral ends is highly recommended. Meanwhile, it is worth mentioning that TCC is very prone to port site metastasis and every attempt should be made to prevent this undesirable and life-threatening complication.

Urologic endometriosis is another disease that may require UU. Despite of the fact that urinary tract involvement is uncommon (1-5%), it may cause obstruction of the ureter leading to hydronephrosis. (Jimenez et al., 2000) In this circumstance, surgical resection of the involved ureteral segment is a viable option because it removes the disease and surrounding fibrosis. The first case of LUU in the literature is reported by Nezhat et al. (Nezhat et al, 1992) In a recent study, Antonelli et al., reported the outcomes of 11 patients with ureteral endometriosis treated with surgical excision. (Antonelli et al., 2006) Among these patients, endometriosis was found to be deeply infiltrating the muscle layer in 4 (intrinsic endometriosis), whereas only adventitia or periureteral tissues were affected in 7 (extrinsic endometriosis) patients. The authors reported no complications regarding UU technique in 2 patients and mentioned that laparoscopic ureterolysis is a more suitable approach for minimal, extrinsic and non-obstructive ureteral involvement; whereas LUU is favorable for intrinsic disease. Meanwhile, Mereu et al reported 17 cases of ureteral endometriosis managed with LUU. (Mereu et al., 2010) Of this cohort, 2 patients had complications with strictures postoperatively. Thus, the authors advocate the complete ureteral excision of the tissue involved since the left endometriosis tissue may lead to recurrences. Similar convincing outcomes were also reported by Nezhat et al (Table 2; Nezhat et al., 1998)

Laparoscopic ureteroureterostomy may have place in some pediatric urological diseases mentioned in Table 3. Briefly, the OT and hospital stay ranges between 100 and 263 min. and 2 and 5.5 days, respectively. After a mean follow-up of 7.7 months, 3 complications were encountered for the operation of 23 renal units. These were febrile UTIs in 2 patients and urine leakage that was spontaneously resolved within 24 hours in 1 patient. (Bhandarkar et al., 2005; González & Piaggio, 2007; Nagraj et al., 2006; Piaggio & González, 2007; Steyaert et al., 2009; Storm et al., 2010)

10. Novel techniques

Tissue engineering has been applied experimentally for the reconstitution of several urologic tissues and organs, including ureter. (Atala, 2004) In one of these studies, Osman et al. have reported the replacement of 3cm segment ureteral defect by acellular tube matrix from canine decellularized ureters. However, ureteral replacement with this naïve bioscaffold was unsuccessful due to fibrosis. (Osman et al., 2004) Smith et al reported a small intestinal submucosa (SIS) allograft to bridge a 2 cm ureteral defect and noted that SIS graft was replaced with ureteral growth in 9 weeks. (Smith et al., 2002) Meanwhile Matsunuma et al. used decellularized matrix with cultured uroepithelial cells for tissue engineered ureter and showed that angiogenesis of this bioscaffold may be increased by seeded bone marrow derived mononuclear cells. (Matsunuma et al., 2006) Recently, a model of "omental bioreactor" for differentiation of engineered neoureter was recently introduced by Baumert et al. (Baumert et al., 2007) In this model bladder biopsies were taken and smooth muscle and urothelial cells were cultured. Then the cultured cells were seeded to small intestinal submucosa (SIS) matrix. Afterwards the cultured cells were wrapped by the omentum around a silicone drain to obtain neoureters. Thus, the authors obtained mature well differentiated multilayered urothelium. Consequently, although animal studies express promising results, the actual ureteral replacement with viable grafts has to wait the studies to mature further (Baumert et al., 2008)

Fibrin sealants are being used more and more in urology. It has been used for laparoscopic pyeloplasty, partial nephrectomy, ureteral injuries, closure of ureterotomies in stone surgery and occlusion of the distal ureter while performing distal ureterectomy with "pluck" technique for the treatment of upper urinary tract TCC. (Eden et al., 1997; Kouba et al., 2004; Mueller et al., 2005; Schultz & Christiansen, 1985) Moreover, a large volume urine leakage after renal cyst decortication was stopped with endoscopic retrograde fibrin glue injection and ureteral stent placement. (Chen et al., 2011) Meanwhile, there is some evidence in the literature that fibrin sealants promote wound healing and reinforce ureteral anastomosis. (Kumar et al., 2001) In animal model, it was shown that LUU made by fibrin glue without stay sutures produced better radiographic findings, flow characteristics and histology. (Wolf et al., 1997) Consequently, fibrin sealants may be used for further water-tightness of the anastomosis. In addition, the use of tissue sealants may reduce the number of sutures placed for anastomosis which may theoretically decrease suture line ischemia. (Detweiler et al., 1999)

Robotic technology has been increasingly used in urological procedures. It tends to replace conventional laparoscopic techniques in complex urologic surgeries and especially in reconstructive procedures. Some series of robotic UU has been published recently. (Hemal et al., 2008; Lee et al., 2010) Apart from the ergonomic advantages for the surgeon and technical benefits such as meticulous sharp dissection and precise spatulation of the ureter with the aid of wristed instruments and magnified 3D vision; this technology did not yet contribute significantly over laparoscopy. (Hemal et al., 2008) However, it is worth mentioning that intracorporeal suturing is much easier with robot which is probably the most important factor on OT. The cost and the lack of haptic feedback are the major disadvantages of robotic technology. Recently, Lee et al. reported 3 successful re-anastomosis of the ureter robotically (Lee et al., 2010). The mean operation time was 136.6 minutes and none of the patients developed recurrent stricture after a 24 months of follow-up. Meanwhile, Smith et al. reported successful robotic UU in 2 children with the length of hospital stay roughly 30 hours. (Smith et al., 2009) The authors reported resolution of hydronephrosis at 1 month follow-up imaging. To our knowledge, 10 renal units were operated with the robot for different indications. The OT is ranging from 136.6 min to 485 min and no complication were encountered after mean follow-up ranging 1 to 24 months (Table 4).

Laparoendoscopic single-site (LESS) surgery for UU is promising and the feasibility of the technique has been reported by Autorino et al. in a patient diagnosed with RCU. (Autorino et al., 2010)

11. Conclusions

Ureteroureterostomy has always been a challenging procedure in the history of urology. Surgical approaches for UU have steadily evolved over the last 50 years paralleling the introduction of new technologies.

In the past decade, laparoscopy has been increasingly utilized for a variety of complex urological procedures. The recent technological advancements in laparoscopy had significant impacts on urologic surgery. The technical refinement and development of laparoscopic devices have enabled laparoscopic surgeons perform challenging urinary tract reconstructions. Due to the small number of cases, LUU cannot be stated that it is superior to open surgery. But the benefit of magnification with improved visualization and minimal

invasiveness provide meticulous dissection and precise approximation which renders the laparoscopic approach beneficial to open.


12. References

- Amato JJ, Billy LJ, Gruber RP, et al. Vascular injuries. An experimental study of high and low velocity missile wounds. *Arch surg* 1970; 101: 167-174.
- Ameda K, Kakizaki H, Harabayashi T, Watarai Y, Nonomura K, Koyanagi T. Laparoscopic ureteroureterostomy for retrocaval. *Int J Urol*. 2001; 8: 71-4.
- Anderson JC, Hynes W. Retrocaval ureter; a case diagnosed pre-operatively and treated successfully by a plastic operation. *Br J Urol*. 1949;21:209-14.
- Anderson JK, Kabalin JN, Cadeddu JA. (2007) Surgical anatomy of the Retroperitoneum, Adrenals, Kidneys, and Ureters. In: Campbell-Walsh Urology, Wein AJ, Kavoussi LR, Novick AC, Partin AW, Peters CA, editors, p. 32-7. Philadelphia: Saunders;
- Antonelli A, Simeone C, Zani D, Sacconi T, Minini G, Canossi E, Cucino SC. Clinical aspects and surgical treatment of urinary tract endometriosis: Our experience with 31 cases. *Eur Urol* 2006; 49: 1093-1098.
- Atala A. Tissue engineering for the replacement of organ function in the genitourinary system. *Am J Transplant*. 2004;4 Suppl 6:58-73.
- Autorino R, Khanna R, White MA, Haber GP, Shah G, Kaouk JH, Stein RJ. Laparoendoscopic single-site repair of retrocaval ureter: first case report. *Urology*. 2010;76:1501-5.
- Baba S, Oya M, Miyahara M, Deguchi N, Tazaki H. Laparoscopic surgical correction of circumcaval ureter. *Urology*. 1994; 44: 122-6.
- Baumert H, Mansouri D, Fromont G, et al. Terminal urothelium differentiation of engineered neoureter after in vivo maturation in the "omental bioreactor". *Eur Urol* 2007;52:1492-8.
- Baumert H, Hekmati M, Dunia I, Mansouri D, Massoud W, Molinié V, Benedetti EL, Malavaud B. Laparoscopy in ureteral engineering: a feasibility study. *Eur Urol*. 2008;54:1154-63.
- Bhandarkar DS, Lalmalani JG, Shivde S. Laparoscopic ureterolysis and reconstruction of a retrocaval ureter. *Surg Endosc*. 2003 17: 1851-1852.
- Bhandarkar DS, Lalmalani JG, Shah VJ. Laparoscopic resection and ureteroureterostomy for congenital midureteral stricture. *J Endourol*. 2005;19:140-2.
- Carvalho GL, Santos FG, Santana EF, Foinquinos RA, Passos GO Jr, Brandt CT, Lacerda CM. Laparoscopic repair of a ureter damaged during inguinal herniorrhaphy. *Surg Laparosc Endosc Percutan Tech*. 2008;18:526-9.
- Chen ML, Tomaszewski JJ, Matoka DJ, Ost MC. Management of urine leak after laparoscopic cyst decortication with retrograde endoscopic fibrin glue application and ureteral stent placement. *J Endourol*. 2011;25:71-4.
- Cholkeri-Singh A, Narepalem N, Miller CE. Laparoscopic ureteral injury and repair: case reviews and clinical update. *J Minim Invasive Gynecol*. 2007;14:356-61.
- Considine J. Retrocaval ureter. A review of the literature with a report on two new cases followed for fifteen years and two years respectively. *Br J Urol*. 1966; 38: 412-2
- Dechet CB, Young MM, Segura JW. Laparoscopic transureteroureterostomy: demonstration of its feasibility in swine. *J Endourol* 1999;13:487-93
- Detweiler MB, Detweiler JG, Fenton J. Sutureless and reduced suture anastomosis of hollow vessels with fibrin glue: a review. *J Invest Surg*. 1999;12:245-62.

- Dobrowolski Z, Kusionowicz J, Drewniak T, Habrat W, Lipczynski W, Jakubik P, Weglarz W. Renal and ureteric trauma: diagnosis and management in Poland. *BJU Int* 2002; 89: 748-751.
- Dogan HS, Oktay B, Vuruskan H, Yavascaoglu I. Treatment of retrocaval ureter by pure laparoscopic pyelopyelostomy: experience on 4 patients. *Urology* 2010; 75: 1343-1347
- Dunn MD, Portis AJ, Shalhav AL, et al. Laparoscopic versus open radical nephrectomy: a 9-year experience. *J Urol*. 2000;164: 1153-115.
- Eden CG, Sultana SR, Murray KH, Carruthers RK. Extraperitoneal laparoscopic dismembered fibrin-glued pyeloplasty: medium-term results. *Br J Urol*. 1997;80:382-9.
- Elliot SP, McAninch JW. Ureteral injuries: external and iatrogenic. *Urol clin North am* 2006; 33: 55-66
- González R, Piaggio L. Initial experience with laparoscopic ipsilateral ureteroureterostomy in infants and children for duplication anomalies of the urinary tract. *J Urol*. 2007;177:2315-8.
- Guillonneau B, Abbou C, Doublet JD, Gaston R, Janetckek G, Mandressi A, et al. A proposal for a 'European Scoring System for laparoscopic operations in Urology' *Eur Urol* 2001;40:2-6.
- Gupta NP, Hemal AK, Singh I, Khaitan A. Retroperitoneoscopic ureterolysis and reconstruction of retrocaval ureter. *J Endourol*. 2001;15:291-3.
- Hemal AK, Rao R, Sharma S, Clement RG. Pure robotic retrocaval ureter repair. *Int Braz J Urol*. 2008;34:734-8.
- Hendren WH. Some alternatives to urinary diversion in children. *J Urol*. 1978;119:652-60.
- Hinman F. Kidney, Ureter, and Adrenal Glands, In: *Atlas of Urosurgical Anatomy*. Philadelphia: W.B. Saunders; 1993. p. 284-9.
- Hodges CV, Moore RJ, Lehman TH, Behnam AM. Clinical experiences with transureteroureterostomy. *J Urol*. 1963;90:552-62.
- Jimenez RE, Tiguert R, Hurley P, An T, Grignon DJ, Lawrence D, Triest J. Unilateral hydronephrosis resulting from intraluminal obstruction of the ureter by adenosquamous endometrioid carcinoma arising from disseminated endometriosis. *Urology* 2000; 1; 56: 331.
- Kaiho Y, Ito A, Numahata K, Ishidoya S, Arai Y. Retroperitoneoscopic transureteroureterostomy with cutaneous ureterostomy to salvage failed ileal conduit urinary diversion. *Eur Urol* 2011; 59: 875-8
- Kouba E, Tornehl C, Lavelle J, Wallen E, Pruthi RS. Partial nephrectomy with fibrin glue repair: measurement of vascular and pelviciceal hydrodynamic bond integrity in a live and abattoir porcine model. *J Urol*. 2004;172:326-30.
- Kumar U, Dickerson A, Sakamoto K, Albala DM, Turk TM. Effects of fibrin glue on injured rabbit ureter. *J Endourol*. 2001 Mar;15(2):205-7.
- Kutikov A, Nguyen M, Guzzo T, Canter D, Casale P. Laparoscopic and robotic complex upper-tract reconstruction in children with a duplex collecting system. *J Endourol*. 2007;21:621-4.
- Landman J, Pattaras JG. Urologic laparoscopic anatomy. In: Moore RG, Bishoff JT, Loening S, Docimo SG, editors. *Minimally Invasive Surgery*, London and New York: Taylor & Francis, 2005. P. 11-28.
- Lee DI, Schwab CW, Harris A. Robot-assisted ureteroureterostomy in the adult: initial clinical series. *Urology*. 2010; 75: 570-573.

- Li HZ, Ma X, Qi L, Shi TP, Wang BJ, Zhang X. Retroperitoneal laparoscopic ureteroureterostomy for retrocaval ureter: report of 10 cases and literature review. *Urology*. 2010; 76: 873-6
- Lucas SM, Sundaram CP. Transperitoneal robot-assisted laparoscopic pyeloplasty. *J Endourol*. 2011;25:167-72.
- Lynch TH, Lynch TH, Martínez-Piñeiro L, Plas E, Serafetinides E, Türkeri L, Santucci RA, Hohenfellner M; European Association of Urology, EAU Guidelines on urological trauma. *Eur Uro* 2005; 47,1-15.
- Matsunuma H, Kagami H, Narita Y et al. Constructing a tissue-engineered ureter using a decellularized matrix with cultured uroepithelial cells and bone marrow-derived mononuclear cells. *Tissue Eng*. 2006; 12: 509-18.
- Mayor G, Zingg EJ. Ureteroureteral anastomosis: In *Urologic Surgery Diagnosis, Techniques and Postoperative Treatment*. Stuttgart: Georg Thieme Publishers; 1976. p 284-289
- Mereu L, Gagliardi ML, Clarizia R, Mainardi P, Landi S, Minelli L. Laparoscopic management of ureteral endometriosis in case of moderate-severe hydroureteronephrosis. *Fertile Steril* 2010; 93: 46-51.
- M. Grabe, T.E. Bjerklund-Johansen, H. Botto, B. Wullt, M. Çek, K.G. Naber, R.S. Pickard, P. Tenke, F. Wagenlehner. *Urological Infections EAU Guidelines 2011*; DOI: 978-90-79754-96-0
- Mueller TJ, DaJusta DG, Cha DY, Kim IY, Ankem MK. Ureteral fibrin sealant injection of the distal ureter during laparoscopic nephroureterectomy--a novel and simple modification of the pluck technique. *Urology*. 2010;75:187-92.
- Mugiya S, Suzuki K, Ohhira T, Un-No T, Takayama T, Fujita K. Retroperitoneoscopic treatment of a retrocaval ureter. *Int J Urol*. 1999;6:419-22.
- Nagraj HK, Kishore TA, Nagalakshmi S. Transperitoneal laparoscopic approach for retrocaval ureter. *J Minim Access Surg*. 2006;2:81-2.
- Nezhat C, Nezhat F, Green B. Laparoscopic treatment of obstructed ureter due to endometriosis by resection and ureteroureterostomy: a case report. *J Urol* 1992 148: 865-868.
- Nezhat CH, Nezhat F, Seidman D, Nezhat C. Laparoscopic ureteroureterostomy: a prospective follow-up of 9 patients. *Prim Care Update Ob Gyns* 1998; 5, 200.
- Noble IG, Lee KT, Mundy AR. Transuretero-ureterostomy: a review of 253 cases. *Br J Urol*. 1997; 79 :20-3.
- Osman Y, Shokeir A, Gabr M, El-Tabey N, Mohsen T, El-Baz M. Canine ureteral replacement with long acellular matrix tube: is it clinically applicable? *J. Urol*. 2004; 172: 1151-4.
- Ou CS, Huang IA, Rowbotham R. Laparoscopic ureteroureteral anastomosis for repair of ureteral injury involving stricture. *Int Urogynecol J Pelvic Floor Dysfunct*. 2005; 16: 155-157
- Piaggio LA, Gonzalez R. Laparoscopic transureteroureterostomy: a novel approach. *J Urol* 2007; 177: 2311-4.
- Pesce C, Costa L, Campobasso P, Fabbro MA, Musi L. Successful use of transureteroureterostomy in children: a clinical study. *Eur J Pediatr Surg*. 2001; 11: 395-8.
- Pereira BMT, Ogilvie MP, Gomez-Rodriguez JC, Ryan ML, Pena D, Marttos AC, Pizano LR, McKenney MG. A review of ureteral injuries after external trauma. *Scand J Trauma Resusc Emerg Med* 2010;18: 6
- Piaggio LA, González R. Laparoscopic transureteroureterostomy: a novel approach. *J Urol*. 2007;177:2311-4.

- Png JC, Chapple CR. Principles of ureteric reconstruction. *Curr Opin Urol.* 2000 May;10(3):207-12.
- Polascik TJ, Chen RN. Laparoscopic ureteroureterostomy for retrocaval ureter. *J Urol.* 1998;160:121-2.
- Ramalingam M, Selvarajan K. Laparoscopic transperitoneal repair of retrocaval ureter: report of two cases. *J Endourol.* 2003;17:85-7.
- Salomon L, Hoznek A, Balian C, Gasman D, Chopin DK, Abbou CC. Retroperitoneal laparoscopy of a retrocaval ureter. *BJU Int.* 1999; 84: 181-2.
- Sanli O, Onol FF, Tefik T, Simsek A, Naghiyev A, Onol SY. Transperitoneal laparoscopic ureteroureterostomy for the treatment of retrocaval ureter: analysis of 3 consecutive cases *Turkish Journal of Urology* 2010; 36: 309-313.
- Sanli O, Tefik T, Ortac M, Karadeniz M, Oktar T, Nane I, Tunc M. Laparoscopic nephrectomy in patients undergoing hemodialysis treatment. *JLS.* 2010;14:534-40
- Schultz A, Christiansen LA. Fibrin adhesive sealing of ureter after ureteral stone surgery. A controlled clinical trial. *Eur Urol.* 1985;11:267-8.
- Simforoosh N, Mosapour E, Maghsudi R. Laparoscopic ureteral resection and anastomosis for management of low-grade transitional-cell carcinoma. *J Endourol.* 2005;19:287-9.
- Simforoosh N, Nouri-Mahdavi K, Tabibi A. Laparoscopic pyelopyelostomy for retrocaval segment: first report of 6 cases. *J Urol* 2006; 175: 2166-2169.
- Simmons MN, Gill IS, Fergany AF, Kaouk JH, Desai MM. Laparoscopic ureteral reconstruction for benign stricture disease. *Urology* 2007;69:280-4.
- Singh O, Gupta SS, Hastir A, Arvind NK. Laparoscopic transperitoneal pyelopyelostomy and ureteroureterostomy of retrocaval ureter: Report of two cases and review of the literature. *J Minim Access Surg.* 2010;6:53-5.
- Smith TG III, Gettman M, Lindberg G, Napper C, Pearle MS, Cadeddu JA. Ureteral replacement using porcine small intestine submucosa in a porcine model. *Urology* 2002; 60: 931-4.
- Smith KM, Shrivastava D, Ravish IR, Nerli RB, Shukla AR. Robot-assisted laparoscopic ureteroureterostomy for proximal ureteral obstructions in children. *J Pediatr Urol* 2009; 5: 475-479.
- Steyaert H, Lauron J, Merrot T, Leculee R, Valla JS. Functional ectopic ureter in case of ureteric duplication in children: initial experience with laparoscopic low transperitoneal ureteroureterostomy. *J Laparoendosc Adv Surg Tech A.* 2009;19 Suppl 1:S245-7.
- Storm DW, Modi A, Jayanthi VR. Laparoscopic ipsilateral ureteroureterostomy in the management of ureteral ectopia in infants and children. *J Pediatr Urol.* 2010 doi:10.1016/j.jpuro.2010.08.004
- Tobias-Machado M, Lasmar MT, Wroclawski ER. Retroperitoneoscopic surgery with extracorporeal uretero-ureteral anastomosis for treating retrocaval ureter. *Int Braz J Urol.* 2005;31:147-50.
- Wolf JS Jr, Soble JJ, Nakada SY, Rayala HJ, Humphrey PA, Clayman RV, Poppas DP. Comparison of fibrin glue, laser weld, and mechanical suturing device for the laparoscopic closure of ureterotomy in a porcine model. *J Urol.* 1997;157:1487-92.
- Xu DF, Yao YC, Ren JZ, Liu YS, Gao Y, Che JP, Cui XG, Chen M. Retroperitoneal laparoscopic ureteroureterostomy for retrocaval ureter: report of 7 cases. *Urology.* 2009;74:1242-5.



Advances in Laparoscopic Surgery

Edited by Dr Arshad Malik

ISBN 978-953-307-933-2

Hard cover, 148 pages

Publisher InTech

Published online 01, February, 2012

Published in print edition February, 2012

Laparoscopic surgery, also called minimal access surgery, has revolutionized the field of surgery over the past few years. It has gained worldwide popularity and acceptance by surgeons and patients alike. Minimal scarring, less pain, and shorter hospital stay are the main reasons behind the global appeal of this novel technique. There has been a tremendous improvement in the technique, as well as in the instruments. The technique has passed through the stages of simple laparoscopic surgery to advanced levels, where more complicated procedures are being successfully attempted. The recent introduction of robotic surgery is also gaining popularity, in addition to single port laparoscopic surgery (SILS), which can be scarless surgery. Most of the surgical procedures, which were considered contraindication for the laparoscopic approach, have eventually become the most common and acceptable indications today. This book is intended to provide an overview of the most common procedures performed laparoscopically, as well as some recent advancements in the field.

How to reference

In order to correctly reference this scholarly work, feel free to copy and paste the following:

Oner Sanli, Tzevat Tefik and Selcuk Erdem (2012). Laparoscopic Ureteroureterostomy, *Advances in Laparoscopic Surgery*, Dr Arshad Malik (Ed.), ISBN: 978-953-307-933-2, InTech, Available from: <http://www.intechopen.com/books/advances-in-laparoscopic-surgery/laparoscopic-ureteroureterostomy>

INTECH

open science | open minds

InTech Europe

University Campus STeP Ri
Slavka Krautzeka 83/A
51000 Rijeka, Croatia
Phone: +385 (51) 770 447
Fax: +385 (51) 686 166
www.intechopen.com

InTech China

Unit 405, Office Block, Hotel Equatorial Shanghai
No.65, Yan An Road (West), Shanghai, 200040, China
中国上海市延安西路65号上海国际贵都大饭店办公楼405单元
Phone: +86-21-62489820
Fax: +86-21-62489821

© 2012 The Author(s). Licensee IntechOpen. This is an open access article distributed under the terms of the [Creative Commons Attribution 3.0 License](#), which permits unrestricted use, distribution, and reproduction in any medium, provided the original work is properly cited.