

# Percutaneous Muscle Biopsy: History, Methods and Acceptability

Harnish P. Patel, Cyrus Cooper and Avan Aihie Sayer  
*MRC Lifecourse Epidemiology Unit, University of Southampton, Southampton  
UK*

## 1. Introduction

Advances in histological, biochemical, physiological and molecular biological assays, as well as in microscopy and image analysis have allowed multiple analyses in muscle tissue (1-5). Muscle biopsy is invaluable in providing a definitive diagnosis of a wide range of myopathies (muscular dystrophies, glycogen storage diseases, inflammatory myopathies and congenital myopathies) and denervating disorders and gives important information on the course of the disease, informs treatment, disease stage as well as prognosis. Results of histopathological analyses should then be interpreted in context of the clinical history, examination and laboratory serum markers (1;6). Furthermore, access to muscle tissue provides the opportunity to assess morphological characteristics such as fibre composition, fibre cross sectional area and capillarisation (e.g. in ageing muscle) (7-9) as well as mRNA, protein abundance and muscle enzyme activity (10). Ultrastructural analyses to gauge response to intervention can be performed (11) as can studies of physiological characteristics of muscle such as single fibre contraction properties (2;8).

## 2. History of muscle biopsy

Methodologies enabling the study of muscle tissue have relied on obtaining tissue through post mortem or open muscle biopsy techniques that require general anaesthesia. Although open muscle biopsy provides large specimens that enables direct visualization of disease distribution and can include a peripheral nerve, the technique involves co-ordination between surgical and anaesthetic colleagues, requires an inpatient bed stay and is therefore time and resource demanding. Moreover, this technique can result in significant scarring.

Microscopic analysis of muscle obtained through percutaneous biopsy can be credited to the French Neurologist Guillaume-Benjamin-Amand Duchenne (1806-1875), lauded for describing muscular dystrophy amongst his many other accolades. Fuelled by his passionate interest in muscular diseases and electrophysiology, he constructed a needle possessing a trocar that made it possible to obtain muscle tissue and was the first clinician to perform percutaneous or 'semi-open' muscle biopsy in living subjects without anaesthesia (12).

Numerous muscle biopsy needles have since been described (13;14). However, the percutaneous needle introduced by Bergstrom in 1962 (15), similar in characteristic to the

needle described by Duchenne, gained popularity through widespread use in diagnostic as well as research (study of normal muscle in relation to physiological change) purposes in both children and adults (3;4;16). Although continuously being refined (17;18), each iteration of the needle is true to its origins i.e. possess a sharp trocar, a cutting cannula that needs sharpening perhaps every 10 uses and a pushing rod to expel the tissue post biopsy (Figure 1). Muscle yields obtained from the needle biopsy have been reported to vary from 25-75 mg (2) 70 - 140mg (4) and up to 143-293 mg after repeated sampling (19).

An alternative instrument to the Bergstrom biopsy needle is the Weil-Blakesley conchotome (Figure 2) (20-22). This instrument, designed like a forcep was described by Henriksson in 1979 (21) and consists of a sharp biting tip encompassing a hollow that can vary from 4-6 mm in width. In similar fashion to the Bergstrom needle, it is inserted through a skin incision 5-10mm in length but does not require a sharp trocar to aid muscle penetration. In addition, its design allows controlled tissue penetration and offers a degree of manoeuvrability (22). These features allow biopsy on a wider range of muscles and permits sampling of muscle groups where the pressure required for the needle procedure to penetrate muscle may not be advisable because of overlying neurovascular or underlying bony structures e.g. at the tibialis anterior (22;23). An additional benefit is that, unlike the Bergstrom needle, the conchotome biting tip does not need regular sharpening and has been reported to maintain sharpness for up to 4 years (17). Muscle yields from the conchotome technique in the earliest report by Henriksson (21) ranged from 26 to 296mg. In our practice, muscle weights ranged at a comparable 20-290mg (24).

### 3. Micro-biopsy

The 'semi-open' techniques described above requiring an incision may be considered too painful and the potential for scarring may be off putting for some. Furthermore, semi-open techniques may be impractical to study time course responses to intervention e.g. exercise or drug administration. As a consequence, minimally invasive techniques such as micro-biopsy have been explored (19;25;26). The device used for skeletal muscle micro-biopsy is a version of the popular spring loaded one-handed automated biopsy systems used to perform biopsies of the breast, prostate, kidney or liver. The assembly consists of a disposable core biopsy needle e.g. 16G Magnum ® (Bard Ltd, UK) and an insertion cannula that will allow multiple biopsies to be performed via a single insertion site (Figure 3). The needle penetration depth can be pre-set by the operator after which release of a trigger unloads the spring and fires the needle into the muscle, excising a small piece of tissue. The validity of this method compared with the Bergstrom needle in histomorphometric analyses has been tested (19).

The semi-open muscle biopsy and micro-biopsy techniques are common, simple and easily learned procedures that have superseded open muscle biopsy in clinical as well as research practice (4;6;17). Any potential risks are reduced if performed correctly and with strict attention to asepsis. Muscles that can be subject to biopsy include the deltoid, biceps, triceps, tibialis anterior, gastrocnemius, soleus and the sacrospinal muscles (3;22;23;27;28). However, the most common site for biopsy both in clinical and research practice is the outermost portion of the *vastus lateralis*. This site, approximately two-thirds down a line from the

anterior superior iliac spine to the patella is readily accessible and does not contain an overlying neurovascular bundle. Furthermore, extensive normative fibre histomorphometric data obtained from vastus lateralis biopsy exists in the literature that allows the recognition of normal and abnormal and facilitates comparison between studies (2;6).

#### 4. Vastus lateralis muscle biopsy (Figure 4)

The biopsy technique using the Weil-Blakesley conchotome and the Bergstrom needle is described below. The technique for micro-biopsy is reviewed by Hayot et al (19); apart from the fact that a skin incision is not required, the procedure shares the same principle as for the conchotome and needle methods and is illustrated in Figure 5.

Equipment needed for percutaneous muscle biopsy

1. Weil-Blakesley conchotome with either 4mm or 6mm biting tip (*Gebrüder Zepf Medizintechnik, Dürbheim, Germany*) (Figure 2) or Bergstrom needle with either 4mm or 6mm cutting trocar (*Dixons surgical instruments Ltd, UK*) (Figure 1)
2. 10ml and 20ml syringes
3. Scalpel size 11
4. Sterile gauze squares and sterile saline-soaked gauze squares
5. Sterile drape with adhesive aperture (*Steri-Drape™, 3M Health Care, USA*)
6. Chlorhexidine or iodine based skin disinfectant
7. 5-10ml 2% Lidocaine without epinephrine
8. Sterile 10ml Universal Container
9. Quarter inch steri-strips
10. Stretchable bandage and elastic tape for compression
11. Ice

Optional (dependent on planned analyses)

1. Liquid nitrogen and suitable cryovials
2. Isopentane cooled in liquid nitrogen
3. Cork disc
4. OTC mount
5. Fixative e.g. formalin, 3% Glutaraldehyde/4% formaldehyde
6. Dissecting microscope to orientate tissue sample so that sections with fibres in true cross-section can be obtained
7. Suitable blunt edged forceps for post procedure tissue handling

In the clinical setting, muscle biopsies are conducted based on patient symptoms and the distribution of muscular weakness and generally do not require standardised conditions but do require the biopsy site to be free of previous muscle injury, contractures or prior instrumentation/therapy e.g. injection sites (1;6). In research or in quantitative studies, standard conditions should apply to all procedures. For example, studies may require participants to be fasted pre biopsy or the exclusion of diabetic subjects (24).

There is little guidance on the use of aspirin or other anti-platelet agents pre biopsy. Whereas warfarin and related anticoagulants would need to be stopped for at least one to two weeks prior to the procedure, aspirin was stopped 4-7 days prior to uneventful muscle

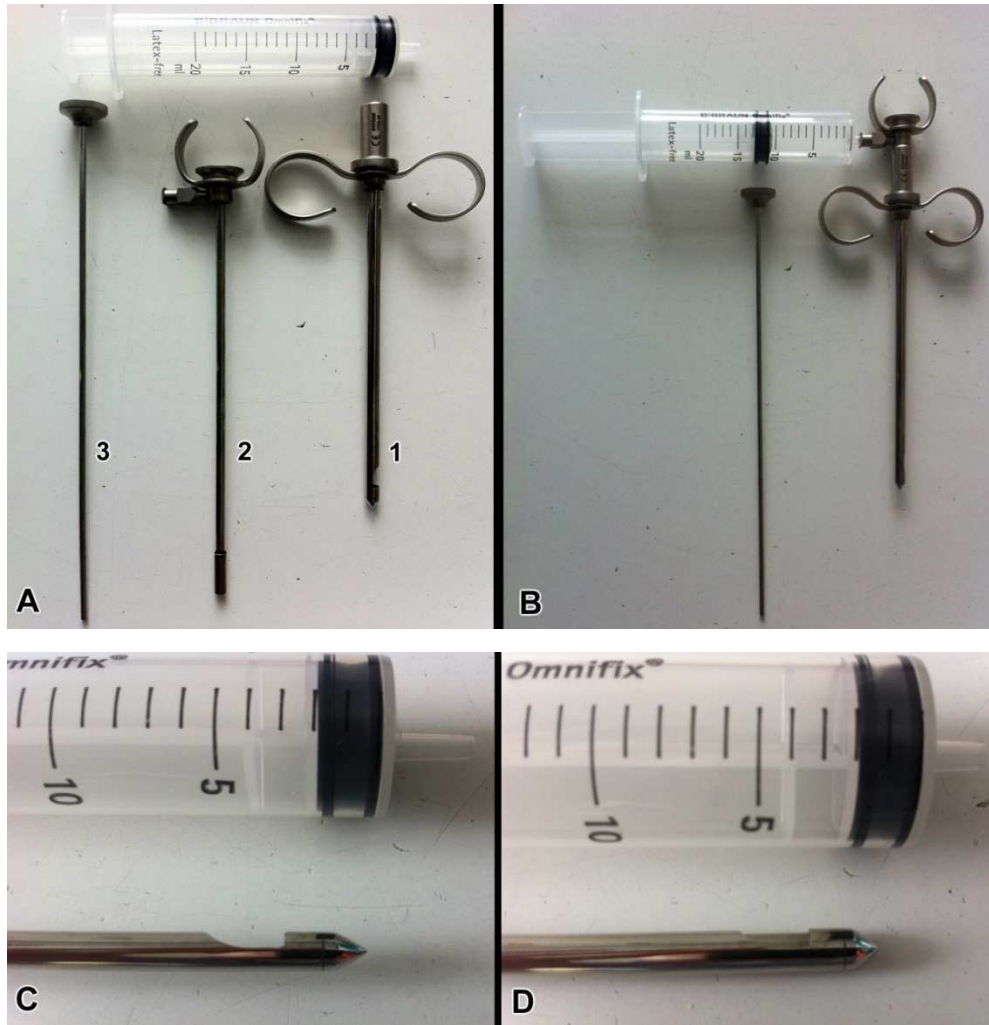


Fig. 1. A. Components of the biopsy needle include 1. Trocar, 2. Cutting cannula, 3. Clearing probe/rod. B. Assembled for biopsy, with cutting cannula inserted within the trocar. A 20 ml syringe can be connected to the cutting cannula to increase the yield of tissue by suction. C. Cutting window visible. D. Window with cutting cannula fully depressed.

biopsy in our research study (24). It is likely that the drug free duration would need to be longer for ADP receptor blockers e.g. clopidogrel. Obviously, risks of stopping such secondary prevention drugs must be considered case-by-case.

Participants are asked to lay supine, comfortably on a bed with the preferred thigh exposed from the groin crease. The operator should be positioned adjacent to the thigh however, a position adjacent to the contra-lateral thigh with the operator reaching over can also be assumed according to individual preference. The leg should remain straight and relaxed

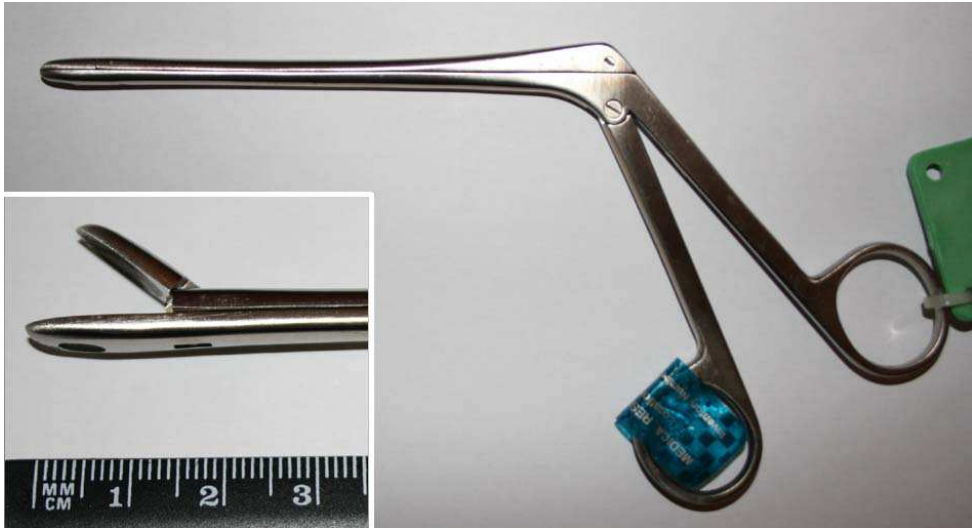
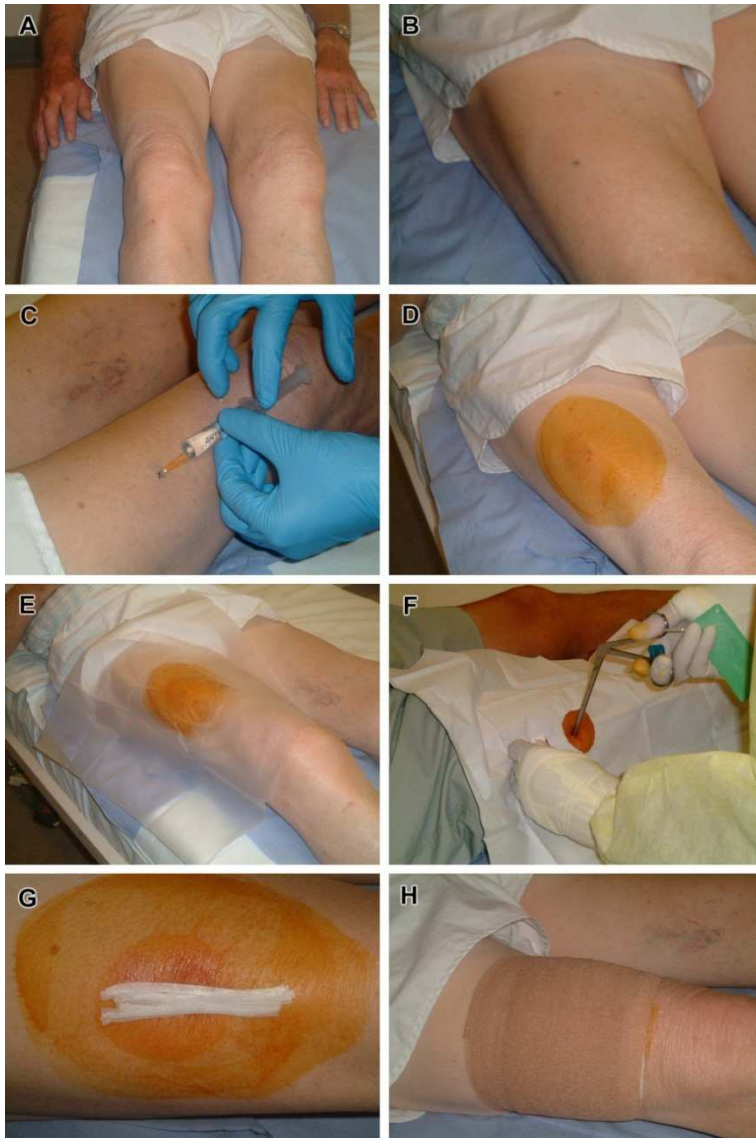
Fig. 2. The Weil-Blakelsley Cochotome with a 6mm biting tip (From Patel HP et al [24])


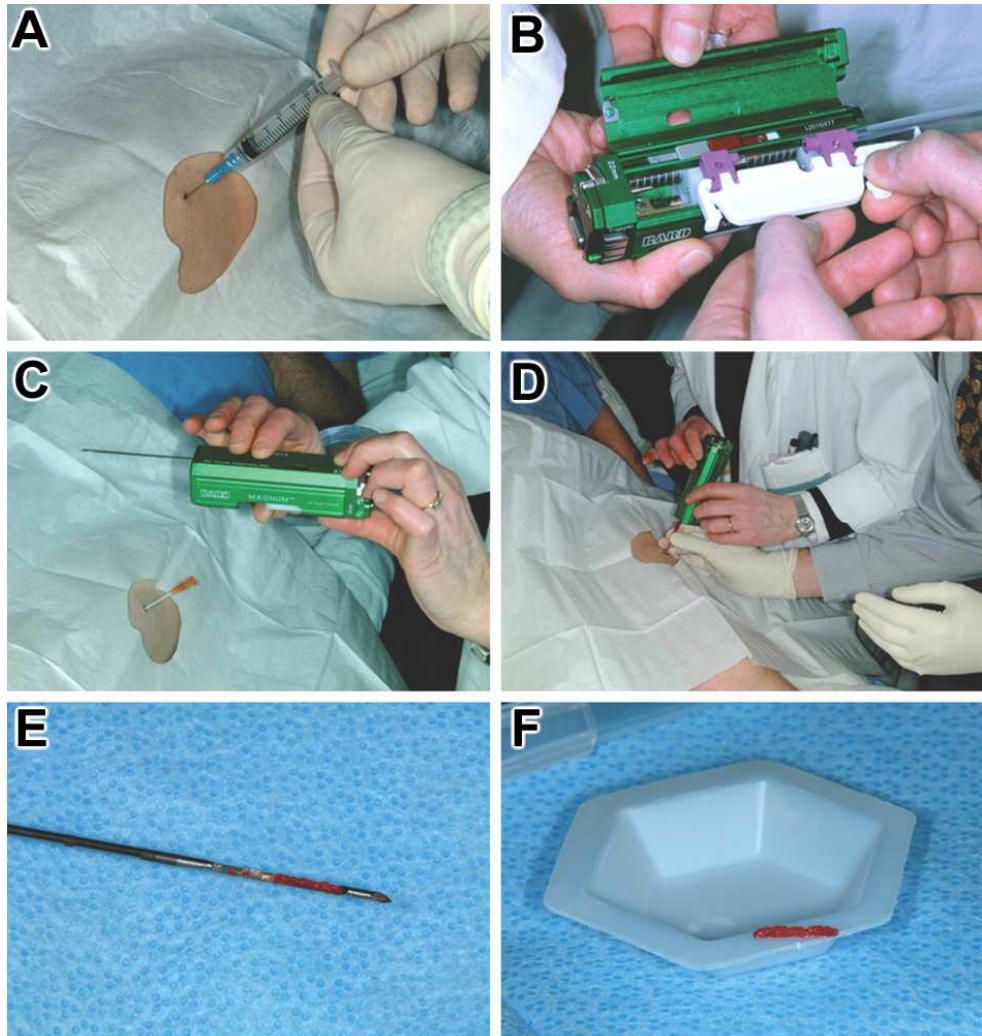


Fig. 3. Spring loaded micro-biopsy system consisting of trigger housing, biopsy needle and the insertion cannula (not shown). (Illustration kindly provided by M Hayot, Service Central de Physiologie Clinique, Montpellier, France)



A. The leg is exposed from the groin crease down to the ankle. B The biopsy area, approximately 2/3 down a line from the anterior superior iliac spine to the patella is marked. C&D The biopsy site over the vastus lateralis is shaved of hair, infiltrated with local anaesthetic and cleaned with antiseptic. E. The biopsy site is isolated with a sterile drape that has a 10 cm adhesive aperture. F. The skin and overlying fascia is then punctured with a size 11 scalpel. The conchotome tip is inserted into the track made by the scalpel, opened, closed and rotated through 90° to excise tissue. G&H. The 5-10mm wound is closed with steri-strips after which a dry dressing and compression bandage are applied.

Fig. 4. The muscle biopsy procedure using the Weil-Blakesley conchotome



A. Infiltration with local anaesthesia. B. Placement of biopsy needle into the trigger housing. C. Skin puncture with the insertion cannula. D. Insertion of the biopsy needle through the insertion cannula and trigger release. E. Removal of the muscle specimen aided by a sterile scalpel (insertion cannula can remain in situ to permit repeated sampling). F. Weighing of the sample. (Reproduced with permission of the European Respiratory Society ©)

Fig. 5. Micro-biopsy procedure with the Magnum® biopsy system (Bard Ltd, UK)<sup>19</sup>

throughout the procedure but the thigh can be tensed momentarily to accentuate the outline of the vastus lateralis to mark the biopsy site. Thereafter the skin surrounding the mark is shaved and cleaned with an alcohol swab.

The skin and overlying fascia is then infiltrated with 5mls of 2% lidocaine local anaesthetic. The subcutaneous bleb is allowed to dissipate during which time the operator should don a sterile gown, gloves and create a sterile field on a suitable trolley. After opening the pack containing the Conchotome or biopsy needle, the skin should be sterilized with povidone iodine (*Betadine*) or a 2% Chlorhexidine gluconate/isopropyl alcohol solution according to local infection control protocols. A sterile drape with an adhesive aperture is then used to maintain a sterile field. With a size 11 scalpel, a 5-10mm incision is made on the skin and down to the fascia through which the closed biting tip of the conchotome is inserted. The conchotome is inserted at right angles to the long axis of the femur, facing away from the femur and to a depth averaging 2-5cm. The free hand of the operator can hold the thigh surrounding the biopsy site while the tip of the conchotome is opened and closed (scissor action) to interpose muscle tissue. The conchotome is then rotated through 90-180° to cut the muscle. Sampling takes a few seconds and can be repeated within the single site, where necessary, to obtain sufficient muscle tissue given the high probability of sampling adipose tissue initially (Figure 4 A-H). The biopsies should be placed on sterile saline-dampened gauze and then transferred into a universal container or petri dish and placed on ice for the remainder of the procedure.

Operator and skin preparation prior to using the using the needle biopsy or the micro-biopsy gun is exactly the same as described for the conchotome (17;29). Constituents of the needle include include the trocar/needle, the cutting cannula and the clearing probe/rod (Figure 1A 1,2,3 respectively). The instrument should be assembled by inserting the cutting cannula into the trocar and checked to ensure alignment and sliding action. The width of a size 11 scalpel to make a skin incision and a track down to the fascia should suffice. The trocar is inserted through the incision, past the fascia where the operator should get a sensation of overcoming resistance; at this point the window of the trocar (Figure 1C) should be fully in the muscle. The cutting cannula is withdrawn a few centimetres and the needle angled to allow tissue to enter the instrument. Alternatively, an assistant can apply suction via a syringe applied to the cutting cannula (Figure 1B) to draw muscle into the cutting chamber before fully advancing the cannula to guillotine a section of muscle (18;30) (Figure 1D) The free hand of the operator can be used to steady the thigh. The yield of muscle can be increased by rotating the instrument by 90° and repeating the procedure (18).

Post procedure, direct pressure should be applied to the wound for 5-10 minutes prior to closure with steri-strips (*Leukostrip, Smith and Nephew, UK*). Sterile absorbent gauze is placed on the steri-strips and a clear adhesive film (*Bioclusive™, Johnson and Johnson, UK*) placed on the gauze. A two-layer compression bandage is then tied for up to 6 hours. The subject is asked to lay down for up to half an hour post procedure and is observed. The procedure, using the conchotome or the Bergstrom needle can take between 15 and 20 minutes; the majority of said time spent in preparation.

#### **4.1 Post muscle biopsy patient/participant advice**

Following the procedure it is common to experience some thigh stiffness that can be alleviated by gentle exercise e.g. walking. There are no real restrictions to mobility but in



our practice we ask participants to avoid 1. vigorous activity for 72 hours (hill climbing, running, heavy lifting) and 2. Immersion in water for 48-72 hours (24). Participants can shower if the biopsy site was protected from water for example, wrapping polythene plastic/cling film around the thigh. Written instructions for post biopsy care, spare dressings and emergency contact details should be given to each participant or patient. To ensure full wound healing, that can take up to two weeks, the dressing should be changed after 4 days and steri-strips removed at day 7 post procedure. All those having the procedure should be warned about transient numbness around the biopsy site that may persist for up to two weeks as well as the remote possibility of wound infection that would necessitate a medical consult.

### 5. Acceptability and adverse events

When performed correctly and according to protocol, the semi-open and micro-biopsy techniques result only in minor discomfort for the subject that is qualitatively described as a "pushing sensation" or a "deep pressure" (29) with very low pain scores (Table 1) (24). Post biopsy, there may be local soreness, stiffness or cramp that do not seem to limit normal activity including recreational sports e.g. golf, bowls (18;24) (Table 1). One participant in our research study reported running a Marathon two weeks after a conchotome vastus lateralis biopsy (24).

Where authors have reported complications, they have commonly been wound haematomas (4;20;22;26). For example, a subject had been taking aspirin at the time of the

VAS pain score (mm)	Median (IQR)
During the procedure	7(1-34)
1 day post procedure	4(0-16)
7 days post procedure	1(0-4)
Daily activity resumed	N (%)
After one day	60(65%)
After 2 days	26(28%)
>2 days	7 (7%)

Table 1. Pain visual analogue scale (VAS) score and resumption of daily activity in 93 research participants subject to the conchotome muscle biopsy. Pain scale was marked at 0mm - 'no pain' and at 100mm - 'pain as bad as it can be'. Typically pain scores were low during and post procedure. The majority of the participants resumed daily activity one-day post procedure (*Adapted from Patel HP et al [24]*)

biopsy (20) or did not follow post biopsy recommendations and put an undue amount of strain onto the thigh shortly after the procedure (22). Pain only occurs if the fascia is caught in the needle or a nerve is sampled inadvertently and may persist for one to two weeks (6). There have been no reports in the literature of serious wound infections or disability post procedure.


Minimally invasive muscle biopsy techniques described above are both feasible and acceptable in clinical and research practice with good safety profiles. The choice of instrument depends on experience and preference, tissue requirement, location of muscle as well as clinical assessment of disease involvement. When performed correctly, all yield muscle tissue satisfactory for most histochemical and histological analyses. In addition, the semi-open techniques allow detailed morphological, biochemical and molecular biological analyses to be conducted on muscle tissue.

## 6. References

- [1] Anderson JR. Recommendations for the biopsy procedure and assessment of skeletal muscle biopsies. *Virchows Arch* 1997 Oct;431(4):227-33.
- [2] Coggan AR. Muscle biopsy as a tool in the study of aging. *J Gerontol A Biol Sci Med Sci* 1995 Nov;50 Spec No:30-4.
- [3] Edwards R, Young A, Wiles M. Needle biopsy of skeletal muscle in the diagnosis of myopathy and the clinical study of muscle function and repair. *N Engl J Med* 1980 Jan 31;302(5):261-71.
- [4] Edwards RH, Round JM, Jones DA. Needle biopsy of skeletal muscle: a review of 10 years experience. *Muscle Nerve* 1983 Nov;6(9):676-83.
- [5] Giresi PG, Stevenson EJ, Theilhaber J, Koncarevic A, Parkington J, Fielding RA, et al. Identification of a molecular signature of sarcopenia. *Physiol Genomics* 2005 Apr 14;21(2):253-63.
- [6] Dubowitz V, Sewry C A. *Muscle Biopsy: A Practical Approach*. 3rd ed ed. China: Saunders Elsevier; 2007.
- [7] Charifi N, Kadi F, Feasson L, Costes F, Geysant A, Denis C. Enhancement of microvessel tortuosity in the vastus lateralis muscle of old men in response to endurance training. *J Physiol* 2004 Jan 15;554(Pt 2):559-69.
- [8] Frontera WR, Suh D, Krivickas LS, Hughes VA, Goldstein R, Roubenoff R. Skeletal muscle fiber quality in older men and women. *Am J Physiol Cell Physiol* 2000 Sep;279(3):C611-C618.
- [9] Patel H, Jameson K, Syddall H, Martin H, Stewart C, Cooper C, et al. Developmental Influences, Muscle Morphology, and Sarcopenia in Community-Dwelling Older Men. *J Gerontol A Biol Sci Med Sci* 2011 Feb 28.
- [10] Costill DL, Daniels J, Evans W, Fink W, Krahenbuhl G, Saltin B. Skeletal muscle enzymes and fiber composition in male and female track athletes. *J Appl Physiol* 1976 Feb;40(2):149-54.
- [11] Sinha-Hikim I, Cornford M, Gaytan H, Lee ML, Bhasin S. Effects of testosterone supplementation on skeletal muscle fiber hypertrophy and satellite cells in community-dwelling older men. *J Clin Endocrinol Metab* 2006 Aug;91(8):3024-33.

- [12] Charriere M, Duchenne GB. Emporte piece histologique. *Bull Acad Med* 1865;30:1050-1.
- [13] O'Rourke KS, Blaivas M, Ike RW. Utility of needle muscle biopsy in a university rheumatology practice. *J Rheumatol* 1994 Mar;21(3):413-24.
- [14] O'Rourke KS, Ike RW. Muscle biopsy. *Curr Opin Rheumatol* 1995 Nov;7(6):462-8.
- [15] Bergstrom J. Muscle electrolytes in man. *Scand J Clin Lab Invest* 1962;14(suppl. 68).
- [16] Edwards RH. Percutaneous needle-biopsy of skeletal muscle in diagnosis and research. *Lancet* 1971 Sep 11;2(7724):593-5.
- [17] Dietrichson P, Coakley J, Smith PE, Griffiths RD, Helliwell TR, Edwards RH. Conchotome and needle percutaneous biopsy of skeletal muscle. *J Neurol Neurosurg Psychiatry* 1987 Nov;50(11):1461-7.
- [18] Hennessey JV, Chromiak JA, Della VS, Guertin J, MacLean DB. Increase in percutaneous muscle biopsy yield with a suction-enhancement technique. *J Appl Physiol* 1997 Jun;82(6):1739-42.
- [19] Hayot M, Michaud A, Koechlin C, Caron MA, Leblanc P, Prefaut C, et al. Skeletal muscle microbiopsy: a validation study of a minimally invasive technique. *Eur Respir J* 2005 Mar;25(3):431-40.
- [20] Dorph C, Nennesmo I, Lundberg IE. Percutaneous conchotome muscle biopsy. A useful diagnostic and assessment tool. *J Rheumatol* 2001 Jul;28(7):1591-9.
- [21] Henriksson KG. "Semi-open" muscle biopsy technique. A simple outpatient procedure. *Acta Neurol Scand* 1979 Jun;59(6):317-23.
- [22] Poulsen MB, Bojsen-Moller M, Jakobsen J, Andersen H. Percutaneous conchotome biopsy of the deltoid and quadriceps muscles in the diagnosis of neuromuscular disorders. *J Clin Neuromuscul Dis* 2005 Sep;7(1):36-41.
- [23] Dietrichson P, Mellgren SI, Skre H. Muscle biopsy with the percutaneous conchotome technique. *J Oslo City Hosp* 1980 May;30(5):73-9.
- [24] Patel H, Syddall HE, Martin HJ, Cooper C, Stewart C, Sayer AA. The feasibility and acceptability of muscle biopsy in epidemiological studies: findings from the Hertfordshire Sarcopenia Study (HSS). *J Nutr Health Aging* 2011;15(1):10-5.
- [25] Lacomis D. The use of percutaneous needle muscle biopsy in the diagnosis of myopathy. *Curr Rheumatol Rep* 2000 Jun;2(3):225-9.
- [26] Magistris MR, Kohler A, Pizzolato G, Morris MA, Baroffio A, Bernheim L, et al. Needle muscle biopsy in the investigation of neuromuscular disorders. *Muscle Nerve* 1998 Feb;21(2):194-200.
- [27] Andonopoulos AP, Papadimitriou C, Melachrinou M, Meimaris N, Vlahanastasi C, Bounas A, et al. Asymptomatic gastrocnemius muscle biopsy: an extremely sensitive and specific test in the pathologic confirmation of sarcoidosis presenting with hilar adenopathy. *Clin Exp Rheumatol* 2001 Sep;19(5):569-72.
- [28] Helliwell TR, Coakley J, Smith PE, Edwards RH. The morphology and morphometry of the normal human tibialis anterior muscle. *Neuropathol Appl Neurobiol* 1987 Jul;13(4):297-307.
- [29] Derry KL, Nicolle MN, Keith-Rokosh JA, Hammond RR. Percutaneous muscle biopsies: review of 900 consecutive cases at London Health Sciences Centre. *Can J Neurol Sci* 2009 Mar;36(2):201-6.

- [30] Evans WJ, Phinney SD, Young VR. Suction applied to a muscle biopsy maximizes sample size. *Med Sci Sports Exerc* 1982;14(1):101-2.



## **Muscle Biopsy**

Edited by Dr. Challa Sundaram

ISBN 978-953-307-778-9

Hard cover, 154 pages

**Publisher** InTech

**Published online** 05, January, 2012

**Published in print edition** January, 2012

Investigation of muscle diseases has changed dramatically with the understanding of genetic basis of a wide range of muscle diseases. Muscle biopsy has become a powerful tool not only to provide diagnosis but to make tissue available for genetic studies and to basic scientists for biomedical research. Accurate interpretation of muscle biopsy to detect cell dysfunction/ damage/death or absence / abnormality of a protein or genetic defect by the sophisticated technologies is important to guide treatment of various muscle diseases. In this book on muscle biopsy various chapters deal with the procedure and interpretation of muscle biopsy, its use in the culture of myotubes and membrane transport studies. Muscle biopsy is an important technique to investigate mitochondrial dysfunction and the mitochondrial DNA integrity in oxidation. Phosphorylation in various metabolic diseases like obesity, type 2 diabetes mellitus and peripheral vascular disease is explored in the other chapters with detailed descriptions on methodology. This book provides the advances in the basic techniques of muscle biopsy for a neuroscientist.

### **How to reference**

In order to correctly reference this scholarly work, feel free to copy and paste the following:

Harnish P. Patel, Cyrus Cooper and Avan Aihie Sayer (2012). Percutaneous Muscle Biopsy: History, Methods and Acceptability, Muscle Biopsy, Dr. Challa Sundaram (Ed.), ISBN: 978-953-307-778-9, InTech, Available from: <http://www.intechopen.com/books/muscle-biopsy/percutaneous-muscle-biopsy-history-methods-and-acceptability>

**INTECH**  
open science | open minds

### **InTech Europe**

University Campus STeP Ri  
Slavka Krautzeka 83/A  
51000 Rijeka, Croatia  
Phone: +385 (51) 770 447  
Fax: +385 (51) 686 166  
[www.intechopen.com](http://www.intechopen.com)

### **InTech China**

Unit 405, Office Block, Hotel Equatorial Shanghai  
No.65, Yan An Road (West), Shanghai, 200040, China  
中国上海市延安西路65号上海国际贵都大饭店办公楼405单元  
Phone: +86-21-62489820  
Fax: +86-21-62489821

© 2012 The Author(s). Licensee IntechOpen. This is an open access article distributed under the terms of the [Creative Commons Attribution 3.0 License](#), which permits unrestricted use, distribution, and reproduction in any medium, provided the original work is properly cited.