

Venous Thrombosis and the Eye

Bob Z. Wang and Celia S. Chen
Flinders Medical Centre and Flinders University
Australia

1. Introduction

Venous thrombosis is associated with Virchow's triad. This involves the combination of hypercoagulability, damage to the vessel endothelium and haemodynamic changes in the form of stasis or turbulence. These features ultimately contribute to thrombosis formation (Heit 2008).

Venous thrombosis can affect the eyes, resulting in serious ocular symptoms and is a significant cause of vision loss worldwide (Rogers, McIntosh et al. 2010). In the eye, venous thrombosis can result in a branch or a central retinal vein occlusion. The eye can also be affected by systemic venous thrombosis such as that which occurs in cerebral venous sinus thrombosis presenting with papilloedema, or in anti-phospholipid syndrome resulting in retinal arteriole occlusion, ischemic optic or cranial neuropathies.

In this chapter, we will discuss the ocular features of venous thrombosis, the presentation of retinal vein occlusion, and its ocular and systemic management. We will then examine the ophthalmic manifestations of systemic venous thrombosis.

2. Retinal vein occlusion

2.1 Pathogenesis

Retinal venous obstruction occurs as a result of Virchow's triad in the retinal vessels with stasis, hypercoagulability and endothelial change. In the retina, disruption of venous return results in elevated intravascular pressure and culminates in retinal haemorrhage and oedema. Retinal ischaemia then follows, leading to non-perfusion of the capillary beds.

Retinal vein occlusion RVO can be classified as either a branch retinal vein occlusion (BRVO) (Figure 1) or a central retinal vein occlusion (CRVO) (Figure 2) depending upon the location of the obstruction (Hayreh 2005). Each of BRVO and CRVO can be further sub-classified into ischaemic and non-ischaemic categories.

Ischaemic RVO is characterised by retinal capillary non-perfusion and results in more severe signs and symptoms including significant decrease in visual acuity, cotton wool spots (indicating retinal ischaemia) and a relative afferent pupil defect. An ischemic RVO is usually associated with ocular complications such as intraocular neovascularisation.

In non-ischaemic RVO stasis of the retinal veins occurs. There is leakage from the capillary bed but capillary perfusion is still present. A non-ischaemic RVO is associated with decreased visual acuity as a result of leaking retinal capillaries that cause macular oedema.

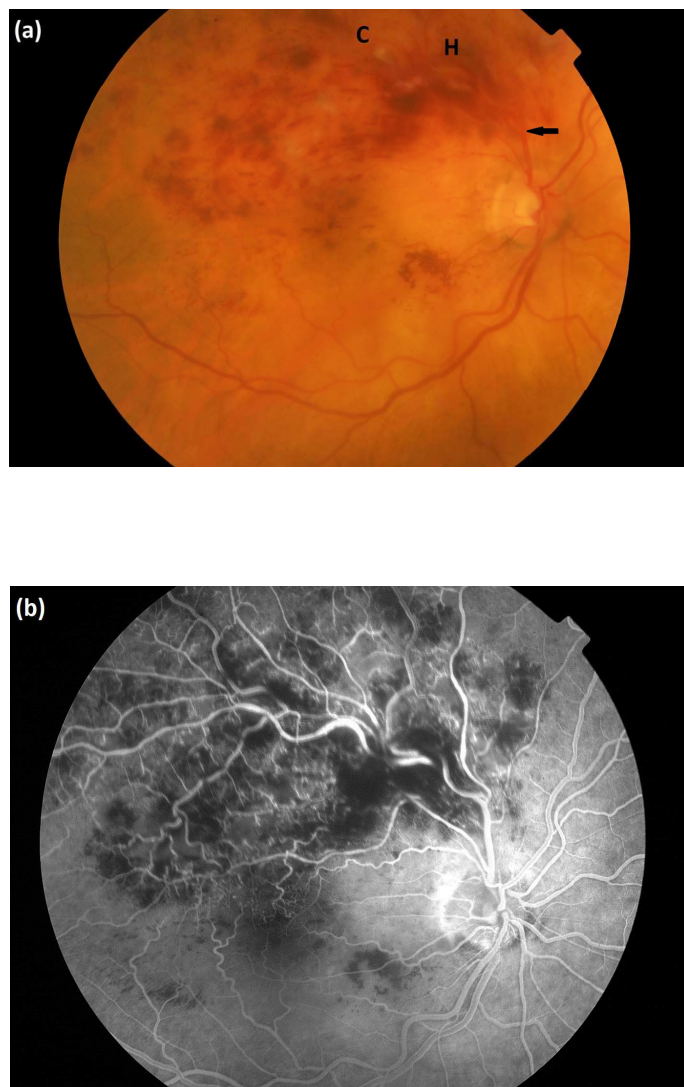


Fig. 1. Fundus photograph of a superior-temporal branch retinal vein occlusion in the right eye (a) with the corresponding fluorescein angiogram (b). The retina shows a sectoral area of retinal haemorrhages (H) and cotton wool spots (C) in the area distal to the vein occlusion (black arrow).

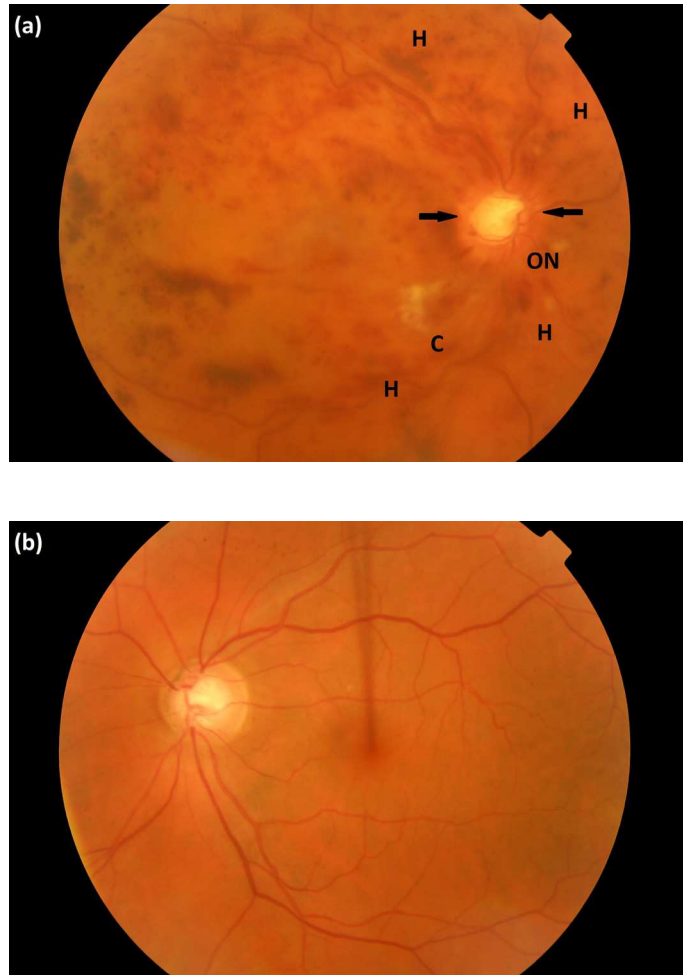


Fig. 2. Fundus photograph of a central retinal vein occlusion in the right eye (a) with normal left eye (b) of the same patient. In central retinal vein occlusion, there are scattered haemorrhages (H) in all four quadrants of the retina, cotton wool spots (C), and optic nerve swelling (ON), which is characterised by indistinct disc margins (black arrows).

2.2 Prevalence

The prevalence of RVO is approximately 1 in 200 people, with an estimated 16.4 million people being affected worldwide (Rogers, McIntosh et al. 2010). Prevalence appears to increase with age (Rogers, McIntosh et al. 2010), whereas gender or ethnicity does not appear to affect prevalence (Rogers, McIntosh et al. 2010). Retinal vein occlusion is usually unilateral and very rarely bilateral. A BRVO is four times more common than a CRVO (Rogers, McIntosh et al. 2010), with its prevalence ranging from 0.3% (Wong, Larsen et al. 2005) to 1.1% (Mitchell, Smith et al. 1996).

2.3 Risk factors

The risk factors for RVO include systemic or local conditions which result in vascular stasis or endothelial damage. Systemic risk factors for RVO are often associated with atherosclerotic vessel changes, and these risk factors include age (Hayreh, Zimmerman et al. 1994), hypertension (Mitchell, Smith et al. 1996; Hayreh, Zimmerman et al. 2001) and hyperlipidaemia (1993; 1996). Diabetes mellitus (Dodson, Kritzing et al. 1992; Hayreh, Zimmerman et al. 2001), peripheral vascular disease and cerebrovascular disease also contribute to a higher likelihood of developing RVO.

Less common systemic risk factors for RVO include those associated with hypercoagulability. These include myeloproliferative disorders (Fegan 2002) such as polycythaemia, myeloma and Waldenstrom macroglobulinaemia. These account for 1% of RVO cases. Acquired and inherited hypercoagulable states (Fegan 2002) may also predispose a patient to RVO. Acquired diseases that have been shown to contribute to RVO include hyperhomocysteinaemia (Chua, Kifley et al. 2005; Janssen, den Heijer et al. 2005), anti-cardiolipin antibodies (Janssen, den Heijer et al. 2005), lupus anticoagulant and anti-phospholipid antibodies. Inherited hypercoagulable diseases that have been associated with RVO include factor V Leiden mutation, protein C or S deficiency (Greiner, Hafner et al. 1999), anti-thrombin deficiency, prothrombin gene mutation (Incorvaia, Lamberti et al. 1999) and factor XII deficiency (Incorvaia, Lamberti et al. 1999). Inflammatory diseases such as Behçet's disease, sarcoidosis, Wegener's granulomatosis and Goodpasture syndrome and chronic renal failure have also been proven to be risk factors for RVO. Oestrogen therapy may be a cause of RVO, although the evidence is inconclusive (Kirwan, Tsaloumas et al. 1997). Hormone replacement therapy has not been shown to be a major risk factor for RVO, whereas the contraceptive pill does increase the risk of RVO and is contraindicated in those with RVO.

A local risk factor for the development of a CRVO is primary open angle glaucoma (1996; Mitchell, Smith et al. 1996). This is due to stasis caused by the elevated intraocular pressure in glaucoma reducing arterial perfusion. The mean arterial perfusion pressure is the difference between the mean arterial pressure and the intraocular pressure.

2.4 Investigations

All investigations should be directed towards examining the systemic risk factors of RVO and assessing the ocular complications of neovascularization.

Systemic investigations include screening for atherosclerotic disease and hypercoagulability. This involves measuring blood pressure, electrocardiogram, a full blood count, measuring erythrocyte sedimentation rate, fasting glucose and lipids, a vasculitic screen and a thrombophilia screen. A vasculitic screen involves measuring antinuclear antibodies, rheumatoid factor, anti-neutrophil cytoplasmic antibody, serum protein electrophoresis, complement 3 and 4. Whereas a thrombophilia screen would include measuring serum homocysteine, protein C and S, Factor V Leiden, antithrombin, anticardiolipin antibodies and lupus anticoagulant.

It is important to remember that in patients with BRVO, cardiovascular risk factors are the predominant cause. In contrast, in patients with CRVO, especially when the patient's age is less than 65, there should be a more extensive search for other risk factors such as oral contraceptive use, thrombophilia or inflammatory diseases.

Ocular investigation with a fundus fluorescein angiography allows for visualisation of large retinal vessels and retinal capillary beds. This helps to differentiate between the ischemic

and non-ischaemic types of RVO (Figure 3). Optical coherence tomography (OCT) is another investigation that is becoming increasingly important in assessing the changes in retinal architecture and measuring the thickness of the retinal layers. OCT can assist in detecting and quantifying intraretinal cysts and the associated macular oedema (Figure 4).

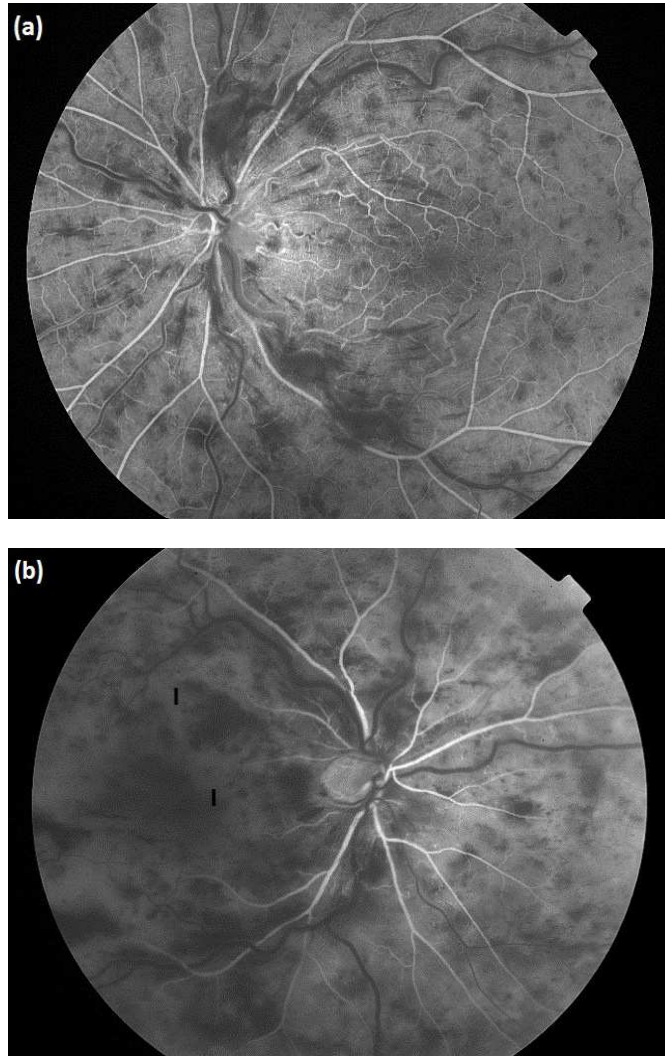


Fig. 3. Fluorescein angiogram of a non-ischaemic central retinal vein occlusion (a) compared to an ischaemic central retinal vein occlusion (b). In non-ischaemic central retinal vein occlusion, there is effective capillary perfusion and this is seen as white due to the fluorescein filling the vessels. In ischaemic central retinal vein occlusion, there are areas of capillary non-perfusion (I) and seen as black due to the absence of fluorescein filling the vessels.

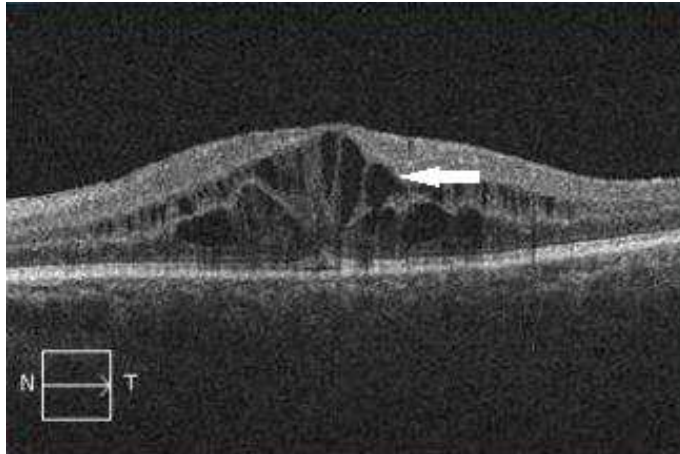


Fig. 4. Optical coherence tomography scan of the macula in an eye with retinal vein occlusion. Nasal to temporal (N→T) cross-sectional image of the macula demonstrates the presence of significant macula oedema and associated intra-retinal cysts (white arrow).

2.5 Clinical presentations

2.5.1 Branch retinal artery occlusion

In BRVO, only a branch of the retinal venous system is affected. Risk factors for BRVO are listed above. The occlusion in BRVO occurs most commonly at an arteriovenous junction, where the artery and vein share a common adventitial sheath. Venous thrombosis results from arterial wall thickening, which compresses the adjacent vein.

Vision loss is the most common presentation in patients with BRVO. The vision loss is usually sudden, unilateral and painless. This loss can be variable and is dependent upon the amount of macular and retinal involvement. If there is macular involvement, vision is usually affected. Alternatively, if the BRVO is small or located in the peripheral retina, the patient may still have 6/6 vision. Metamorphopsia or distorted vision and a visual field defect may also occur.

Ocular fundus examination often reveals a wedge shaped area of retinal abnormality. The superior temporal retinal arcade is affected in 60% of all cases of BRVO due to the higher number of arteriovenous crossings in this area. The veins distal to the occlusion may demonstrate dilatation and tortuosity, while there may be some venous attenuation proximal to the occlusion. Retinal haemorrhages are a notable feature of BRVO. Superficial retinal haemorrhages appear flame shaped, while deep haemorrhages are characteristically referred to as dot-blot haemorrhages (Figure 5). Very rarely, there may be subhyaloid or vitreous haemorrhages. Other ocular fundus features of BRVO include retinal oedema and cotton-wool spots, which is also a sign of retinal ischaemia.

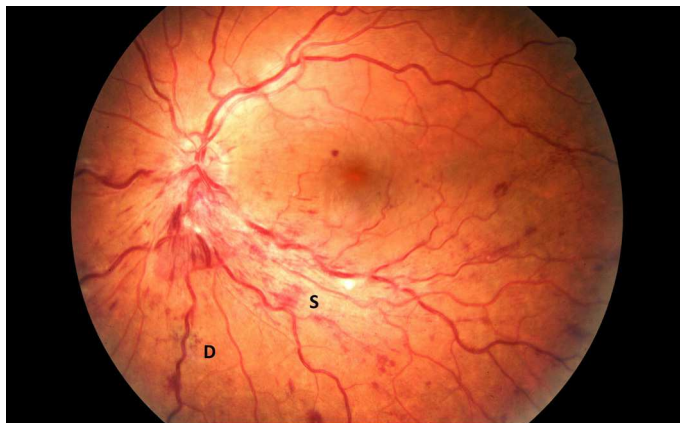


Fig. 5. Fundus photograph of an inferior branch retinal vein occlusion in the left eye showing different types of retinal haemorrhages. Superficial retinal haemorrhages (S) are flame shaped; deep retinal haemorrhages (D) are dot-blot.

2.5.2 Central retinal vein occlusion

Similar to BRVO, the most common presentation in patients with CRVO is vision loss. The vision loss is sudden, unilateral, painless and usually profound, in the range of counting fingers.

Examination reveals a relative afferent Pupillary defect. While fundus examination demonstrates tortuosity and dilatation of all the branches of the central retinal vein as well as superficial (flame-shaped) and deep (dot-blot) intraretinal haemorrhages. Cotton wool spots and oedema of the optic disc or macula may be present.

Fluorescein angiography is the ocular investigation of choice in patients with suspected CRVO. The general features of CRVO using fluorescein angiography include delayed arteriovenous transit time and blockage by retinal haemorrhages. Fluorescein angiography is vital in distinguishing between non-ischaemic and ischaemic CRVO (Figure 3). There is effective capillary perfusion in non-ischaemic CRVO and capillary non-perfusion in ischaemic CRVO.

2.6 Treatment

Treatment involves management of the systemic risk factors and local treatment for complications of RVO, such as macular oedema and neovascularisation.

With regard to systemic treatment of RVO, there is no strong evidence in current literature for the use of anticoagulant, fibrinolytic agents or antiplatelet agents. Best practice management involves treating the atherosclerotic risk factors, such as hypertension and hyperlipidaemia.

Local treatment for BRVO differs from the treatment of CRVO. For BRVO, the Branch Vein Occlusion Study (BVOS) suggested that retinal haemorrhages and any macular oedema should be observed for 3 months to allow for spontaneous resolution. After 3 months, if the macular oedema is still present, treatment may be warranted. The BVOS recommends grid laser photocoagulation for the treatment of macular oedema (1984). Use of intravitreal anti-VEGF agents, such as ranibizumab, has been shown to be beneficial (Campochiaro, Heier et

al. 2010). There has been some conflicting evidence regarding the use of triamcinolone acetonide in the treatment of macular oedema in BRVO. Jonas et al. found it to be beneficial in the treatment of macular oedema (Jonas, Akkoyun et al. 2005), however Scott et al found intravitreal triamcinolone to be no more effective than grid laser photocoagulation and was even associated with a higher risk of adverse events (Scott, Ip et al. 2009). Dexamethasone has been shown to be beneficial, but there is also a risk that dexamethasone can increase intraocular pressure (Haller, Bandello et al. 2010). Optic disc or retinal neovascularisation requires treatment with pan-retinal (scatter) laser photocoagulation in the distribution of occluded vein (1986; Hayreh, Rubenstein et al. 1993). Prophylactic PRP is not indicated to prevent neovascularisation, as the harmful effects of PRP outweigh the benefits in prophylaxis (1984).

Treatment of CRVO should initially involve determining the type of CRVO present. In patients with non-ischaemic CRVO, the macular oedema can be treated with intravitreal steroids such as triamcinolone acetonide (Ip, Scott et al. 2009) or dexamethasone (Haller, Bandello et al. 2010). Treatment with intravitreal anti-VEGF agents, such as Ranibizumab has been shown to be useful in a double-blinded randomized controlled trial (Brown, Campochiaro et al. 2010). Laser photocoagulation for the treatment of macular oedema in CRVO has not been found to be beneficial (1995). In ischaemic CRVO, the presence of anterior chamber angle neovascularisation or rubeosis iridis should immediately be treated with laser pan-retinal photocoagulation (1995). Prophylactic PRP is not warranted and PRP is only indicated once anterior segment neovascularisation becomes apparent. Unproven treatments include the use of Ticlopidine, Troxerutin and Epoprostenol.

2.7 Prognosis

Prognosis is dependent upon the type of RVO.

BRVO tends to have a better prognosis, but it may take 6 to 12 months to resolve. The affected area is commonly replaced by hard exudates and venous sheathing. Collateral vessels can form between the affected and unaffected retina. If there are improvements in visual acuity and the development of efficient collaterals, the prognosis is often good. The prognosis is poor if there are complications associated with the BRVO such as the development of chronic macular oedema, which occurs in 57% of temporal branch occlusions. Another serious complication is neovascularisation, which can lead to recurrent vitreous and pre-retinal haemorrhages as well as retinal detachments and ultimately adversely affects the visual outcome.

Similarly, the acute stage of CRVO takes approximately 6 to 12 months to resolve. Disc collaterals between the retinal and choroidal vascular network usually form during this time. The final visual acuity is dependent upon the initial visual acuity following RVO (1997), with better visual outcomes in those with good initial visual acuity. The complications and prognoses are different for the different types of CRVO. The complications of non-ischaemic CRVO include chronic macular oedema and conversion to ischaemic CRVO. The prognosis of non-ischaemic CRVO is often good, unless a conversion to ischaemic CRVO occurs. One-third of non-ischaemic CRVO convert to become ischemic by 3 years, with half of these conversions occurring within the first 4 months following the CRVO (1997). Ischaemic CRVO may be complicated by neovascularization, which occurs in 5% of eyes. When rubeosis iridis develops, it results in neovascular glaucoma, due to the neovascular membrane occluding the trabecular meshwork where the aqueous fluid drains out of the eye. Neovascular glaucoma commonly occurs within 3 months of the onset of the

CRVO and is characterised by a sudden increase in pain due to a rise in intraocular pressure. The risk factors for its development include poor visual acuity, extensive retinal haemorrhage and significant retinal non-perfusion on fluorescein angiography (1997). In patients with less than 10 optic disc areas of retinal non-perfusion, less than 10% of eyes will develop rubeosis iridis. However, if there are more than 30 optic disc areas of retinal non-perfusion, the risk of rubeosis iridis increases significantly. The prognosis of ischaemic CRVO is usually poor due to the development of macular ischaemia or neovascularization. RVO in one eye increases the risk for the development of a RVO in the contralateral eye. This occurs in 9-15% of patients within 5 years of the initial diagnosis of RVO (Hayreh, Zimmerman et al. 1994). Unfortunately, at present there is no treatment available to prevent the development of RVO in the contralateral eye or a recurrence of RVO in the same eye. RVO is also associated with an increased likelihood of death from cerebral vascular and cardiovascular causes (Tsaloumas, Kirwan et al. 2000; Cugati, Wang et al. 2007).

3. Ophthalmic manifestations of systemic thrombosis

Systemic venous thrombosis can cause significant ocular symptoms and signs. Evidence suggests that ocular manifestation in systemic thrombosis increases the risk of cerebral events (Asherson, Khamashta et al. 1989) and ultimately, this impacts the prognosis of the patient.

It is, therefore, important to consider ocular features of systemic venous thrombosis, but, it is also equally important that clinicians are aware of the ophthalmic features of systemic conditions that predispose to a venous thrombosis, such as thrombophilias.

It is clearly impossible to consider all systemic conditions that cause a predisposition to venous thrombosis in this chapter. Therefore, here we will consider two systemic conditions that have important ocular manifestations. Firstly, we will discuss cerebral venous sinus thrombosis and to highlight the ocular features of systemic thrombosis. Then we will examine anti-phospholipid syndrome to review the ocular features of a condition that is a risk factor for venous thrombosis.

3.1 Ophthalmic manifestations of cerebral venous sinus thrombosis

Cerebral venous sinus thrombosis (CVT) is a condition that results from thrombosis and occlusion of the cerebral veins or dural sinus. This thrombosis causes increased venous pressure and subsequently results in impairment of cerebrospinal fluid (CSF) absorption and increased intracranial pressure (ICP). Regardless of the site, all CVT can cause raised ICP. The common sites for CVT include the cavernous sinus, sigmoid sinus, transverse sinus and sagittal sinus. Rarer sites of thrombosis include the lateral sinus, jugular vein, posterior fossa vein and the deep cerebral venous system (straight sinus).

Impaired CSF absorption is associated with increased intracranial pressure, while increased capillary pressure disrupts the blood-brain barrier, decreases capillary perfusion and results in capillary damage. This increased capillary pressure ultimately causes vasogenic and cytotoxic oedema as well as cerebral parenchyma lesions (Gotoh, Ohmoto et al. 1993; Yoshikawa, Abe et al. 2002).

3.1.1 Prevalence

CVT is a rare thrombotic occurrence with an incidence of 3-4 per million (Stam 2005). It is more common in females compared to males with a ratio of 3:1 (Ferro, Canhao et al. 2004), and is also more common in children compared to adults (Agnelli and Verso 2008).

3.1.2 Clinical presentation

The ophthalmic presentation of CVT can be quite variable and it may have an acute or chronic onset. The most common ocular feature is papilloedema due to raised intracranial pressure. Acute papilloedema appears as flame shaped haemorrhages and cotton wool spots, which are an indication of nerve fibre layer infarction (Figure 6); whereas chronic papilloedema may have a 'champagne cork' like appearance (Figure 7). Despite the presence of papilloedema, visual acuity is often initially unaffected and the first ocular symptom to occur is usually visual field constriction (Figure 7). Patients can also present with visual obscuration with bending or coughing; and there may be diplopia due to cranial nerve VI palsy (Figure 8).

In cases of cavernous sinus thrombosis, ocular features are the predominant feature and can include ocular pain, chemosis, proptosis and cranial nerve palsies affecting the extraocular muscles. This is due to the close association between the oculomotor (cranial nerve III), trochlear (cranial nerve IV) and abducens (cranial nerve VI) nerve and the cavernous sinus.

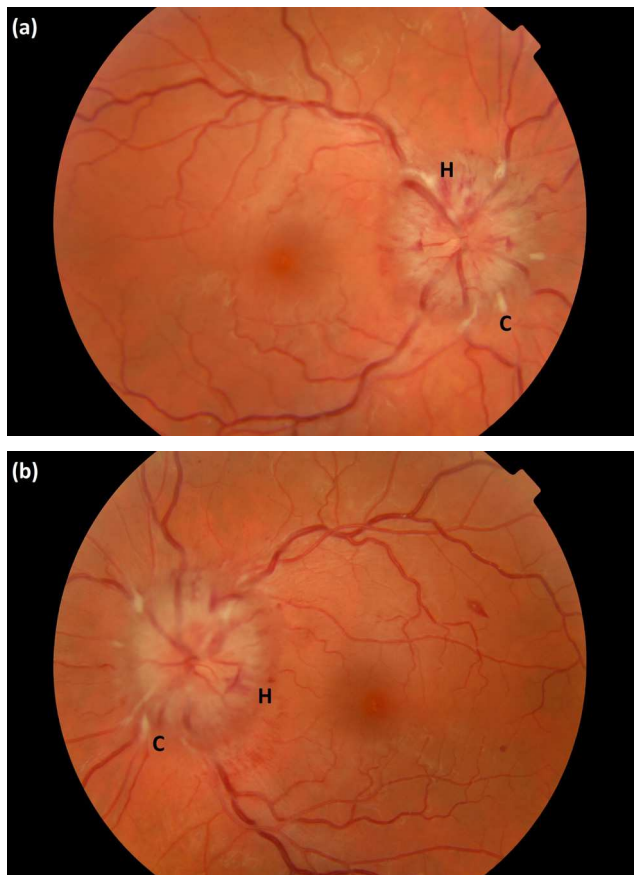


Fig. 6. Fundus photograph showing acute papilloedema with haemorrhages (H) and cotton wool spots (C) in the right eye (a) and the left eye (b) of the same patient.

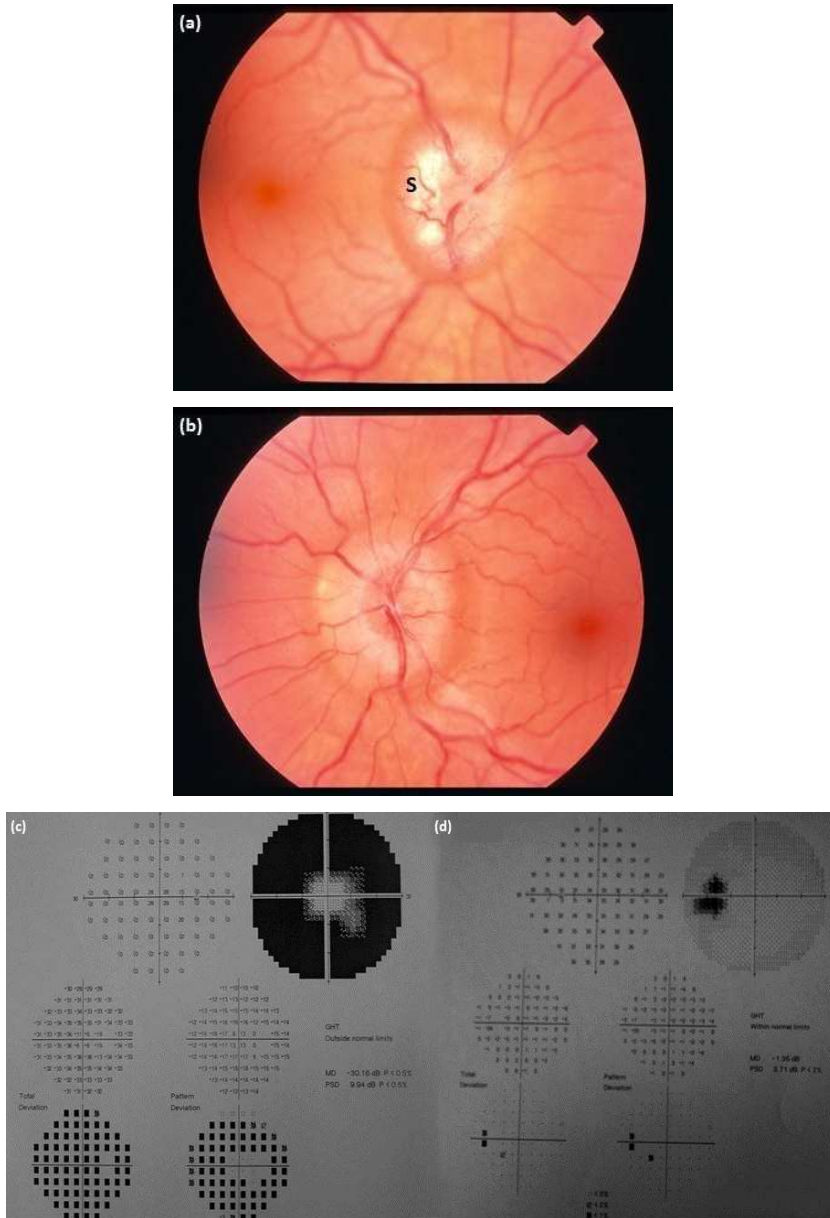


Fig. 7. Fundus photograph showing a 'champagne cork' like appearance in chronic papilloedema in the right eye (a) and left eye (b) of the same patient. In the right eye, there is a Y shaped retinochoroidal shunt (S) due to the retinal vessels diverting towards the choroidal vessels and is another fundus feature of chronic papilloedema. Corresponding visual fields images shows significant field constriction in the right eye (c) and an enlarged blind spot in the left eye (d).

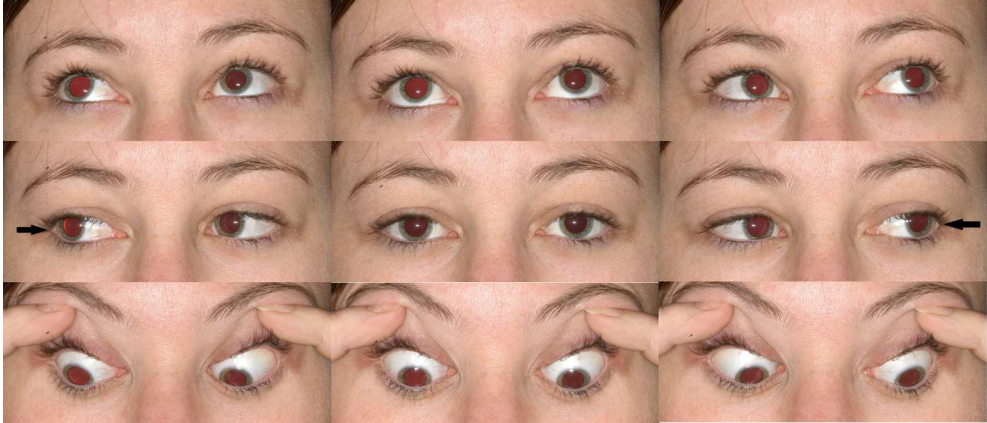

Fig. 8. Clinical photograph of all nine positions of gaze in a patient with a cranial nerve VI palsy associated with raised intracranial pressure. The patient complains of diplopia and there is weakness in the lateral rectus as indicated by the visibility of the sclera on lateral gaze (arrows).

3.1.3 Investigations

Magnetic resonance imaging (MRI) with magnetic resonance venography is the most sensitive method for diagnosing CVT and visualising brain parenchymal lesions. However, this sensitivity depends upon the location of the thrombosis (Ferro, Morgado et al. 2007).

Given its wide availability, computed tomography (CT) is often used for investigation of CVT. The radiological findings of CVT on CT are often non-specific and the scan may be normal in 30% of cases with CVT. Signs that assist in the diagnosis of CVT include the dense triangle sign on non-contrast CT (hyperdensity in the posterior part of the superior sagittal sinus caused by venous thrombosis), the cord sign on contrast CT (linear hyperdensity over cerebral cortex caused by venous thrombosis) and the empty delta sign on contrast CT (area where there is absence of contrast enhancement in the posterior part of the superior sagittal sinus) (Boukobza, Crassard et al. 2007). These signs occur in one-third of patients with CVT. Ocular assessment in patients with CVT should involve serial visual acuity, visual field measurements and imaging of the optic nerve head with stereophotographs or other imaging modalities such as OCT in order to monitor progression.

Once diagnosed, an investigation for the possible causes of CVT may be warranted. This involves blood tests to screen for thrombophilias, as well as a search for a malignancy.

3.1.4 Treatment

Treatment aims to recanalise the occlusion, prevent thrombus propagation, address the underlying cause, and then control the symptoms of the condition such as vision loss.

The most important principle of treatment of CVT is anticoagulation (Coutinho and Stam 2010) in patients who have no contraindications to anticoagulation. Treatment with either unfractionated heparin or low molecular weight heparin has been shown to reduce the risk of death and dependency (Stam, De Bruijn et al. 2002). Anticoagulation appears to be safe in CVT patients with intracranial haemorrhages (Einhaupl, Stam et al. 2010), as the haemorrhages in CVT are the result of venous occlusion.

Although controversial, failure in improvement with anticoagulation may require the use of direct endovascular thrombolysis (Einhaupl, Stam et al. 2010) which involves either mechanically (Scarrow, Williams et al. 1999) or chemically (Wasay, Bakshi et al. 2001) dissolving the clot. This is generally reserved for patients with poorer prognoses (Stam 2005), as there is the potential that thrombolysis may cause death or dependency in up to 40% of patients with CVT (Stam, Majoie et al. 2008). However, in critically ill patients, thrombolysis may reduce death compared to other treatments or no treatment at all (Canhao, Falcao et al. 2003).

Aside from treatment of the CVT, it is important to manage any associated symptoms. In particular, control of elevated intracranial pressure is vital in patients with headaches, as well as preserving visual function. In cases of decreasing visual acuity associated with CVT, optic nerve sheath fenestrations may help to reduce pressure, thereby preventing optic nerve atrophy. Equally important in CVT treatment is the control of seizures.

3.1.5 Prognosis

The prognosis of CVT is generally good. At 16 months, approximately 57% of patients with CVT have no signs or symptoms, and a further 22% of patients with CVT have only minor residual symptoms (Ferro, Canhao et al. 2004). Characteristics that are associated with a poorer prognosis include age over 37, male, previously having a coma or mental status abnormality; haemorrhage noted on imaging; deep venous system thrombosis; central nervous system infection and CVT associated with malignancy (Ferro, Canhao et al. 2004).

Approximately 3% of patients die in the acute phase of CVT and 8% of patients die within the first 30 days following initial symptoms of CVT (Canhao, Ferro et al. 2005). Death is often due to transtentorial herniation or due to diffuse oedema and multiple parenchymal lesions (Canhao, Ferro et al. 2005).

Significant visual loss in CVT is rare (Purvin, Trobe et al. 1995), and if present, is often associated with prolonged elevated intracranial pressure. Visual prognosis depends upon the duration and severity of elevation in pressure.

There is often recanalisation after CVT and this commonly occurs within the first four months. The likelihood of recanalisation occurring depends on the location of the CVT (Baumgartner, Studer et al. 2003). Following a CVT, approximately 3% develop a recurrent CVT and 6% develop another form of venous thromboembolism at 6 years (Martinelli, Bucciarelli et al. 2010).

3.2 Ophthalmic manifestations of antiphospholipid syndrome

Antiphospholipid syndrome (APS) is an autoimmune disease associated with both arterial and venous thrombosis. It is characterised by lupus anticoagulant, anticardiolipin antibody and anti- β_2 glycoprotein-I antibody (Miyakis, Lockshin et al. 2006).

3.2.1 Prevalence

The prevalence of ocular involvement in APS is variable, with studies suggesting that ocular features can occur in 8% to 88% of patients with APS (Utz and Tang 2011).

3.2.2 Clinical presentation

Ocular manifestations of APS include occlusive vascular disease (Miserocchi, Baltatzis et al. 2001; Suvajac, Stojanovich et al. 2007), vasculitis (Miserocchi, Baltatzis et al. 2001) and neuro-

ophthalmic manifestations. Occlusive vascular disease may occur in the form of central and branch retinal artery or vein occlusion, and choroidal infarction (Ang, Yap et al. 2000) (Figure 9). Vasculitis may manifest as anterior uveitis, episcleritis (Figure 10), scleritis (Figure 11) or retinal vasculitis causing retinal artery occlusion (Figure 12). APS may also be associated with cranial nerve III (Genevay, Hayem et al. 2002) (Figure 13), cranial nerve IV (Shin and Lee 2006) and cranial nerve VI (Shin and Lee 2006) palsies, in addition to ischaemic optic neuropathy (Giorgi and Balacco Gabrieli 1999), and optic neuritis (Giorgi and Balacco Gabrieli 1999).

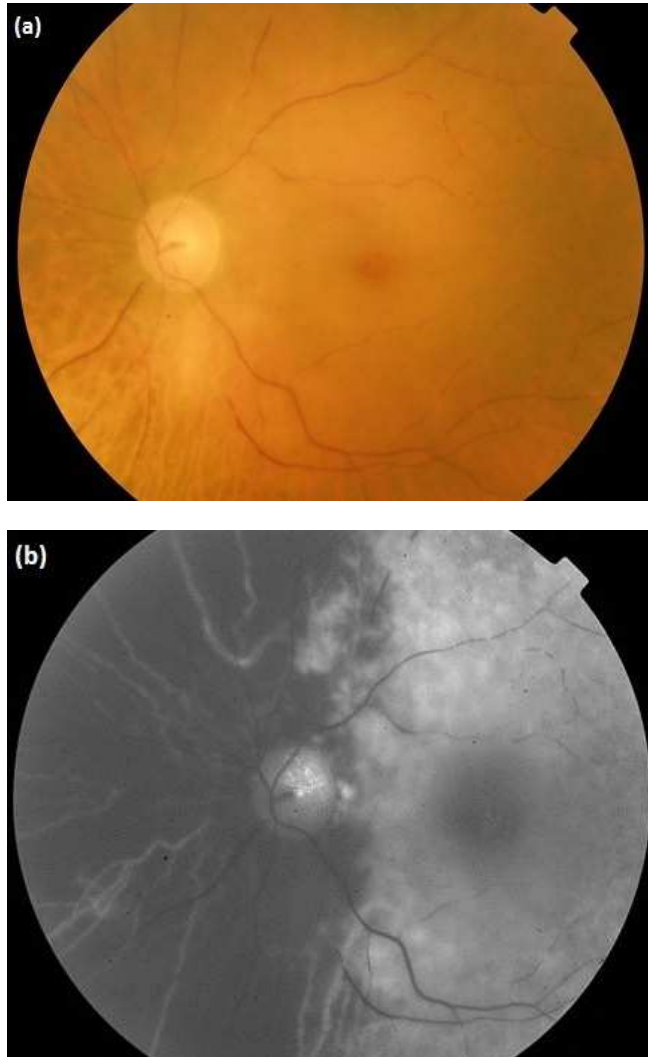


Fig. 9. Fundus photograph showing central retinal artery occlusion with associated choroidal infarction in the left eye (a) and the corresponding fluorescein angiogram (b).

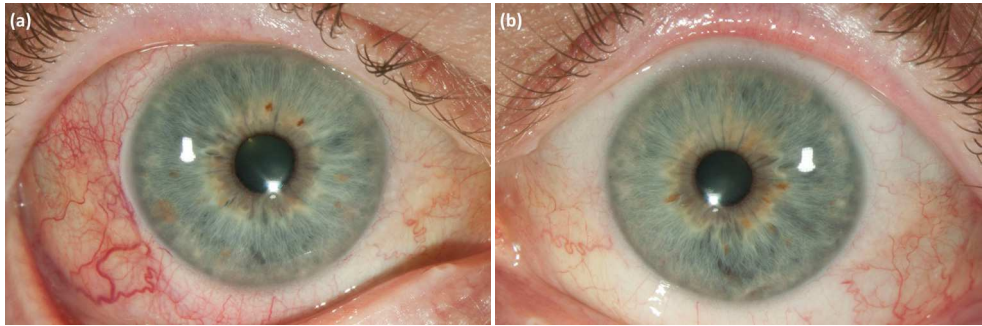


Fig. 10. External photograph showing episcleritis of both eyes of the same patient with antiphospholipid syndrome. The right eye (a) is clinically more severe than the left eye (b).

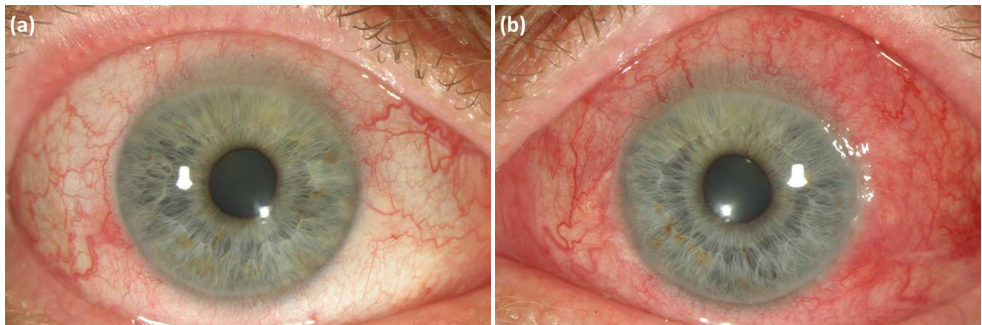


Fig. 11. External photograph showing scleritis of both eyes with the right eye (a) less severe than the left eye (b). The scleritis associated with antiphospholipid syndrome is often a necrotising scleritis.

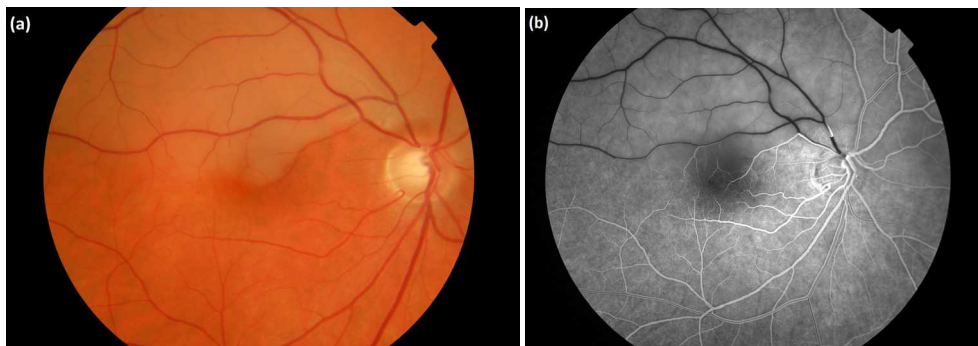


Fig. 12. Fundus photograph of a branch retinal artery occlusion in the right eye due to vasculitis (a). The superior retina is pale due to infarction and the occluded artery is clearly visible on the corresponding fluorescein angiogram (b).

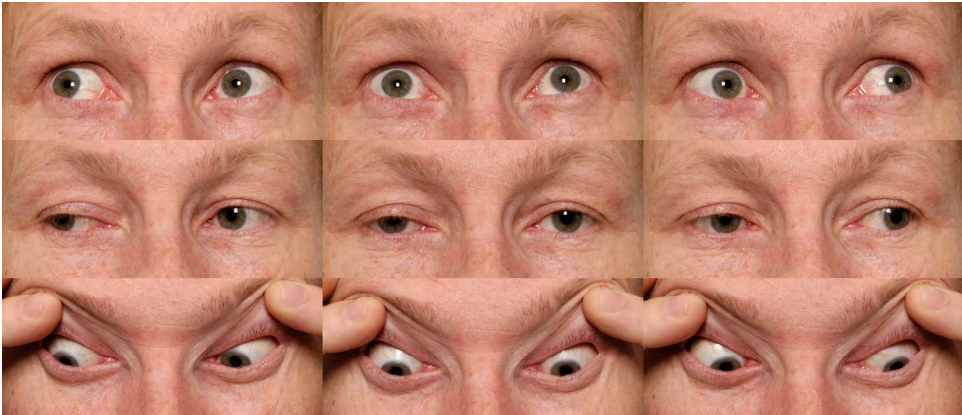


Fig. 13. Clinical photograph of all nine positions of gaze in a patient with a right pupil involving cranial nerve III palsy with right ptosis and exotropia on primary gaze.

Patients with retinal vaso-occlusion usually present with pain, unilateral or bilateral decreased visual acuity, visual field defect or amaurosis fugax. Bilateral amaurosis fugax is a very serious condition, and may indicate the presence of central nervous system ischaemia. Those with cranial neuropathy present with acute binocular diplopia.

On examination, patients with APS may have dry eyes, conjunctival telangiectasia (Miserocchi, Baltatzis et al. 2001) and corneal infiltrates or keratitis. Ocular fundus examination may reveal tortuous and dilated retinal veins, intra-retinal haemorrhages, cotton-wool spots, optic disc and macular oedema or neovascularisation.

3.2.3 Investigations

Ocular imaging with fluorescein angiography directly visualizes the retinal vessels and occlusion. An MRI scan may be important if there is visual loss without ocular fundus changes, as it is important to investigate the possibility of CNS ischaemia.

In addition to imaging, a full thrombophilia work-up may be necessary in the absence of traditional thrombophilia risk factors. This would include searching for antiphospholipid antibodies, including lupus anticoagulant, anticardiolipin antibody and anti- β_2 glycoprotein-I antibody. Other screening tests should include homocysteine, protein C and S, plasminogen, anti-thrombin levels, activated protein C resistance and factor V Leiden mutation.

3.2.4 Treatment

Early detection of ocular manifestations of APS is important as it allows treatment and prevention of further systemic disease. This first involves determining the patient's thrombotic risk.

The treatment of the systemic disease is vital as it may reverse the retinal ischaemia (Srinivasan, Fern et al. 2001). This should include reducing modifiable risk factors such as hypertension, hyperlipidaemia, diabetes mellitus, oral contraceptive use, hormone replacement therapy and smoking.

Treatment should also target the cause of the thrombosis. APS with venous thrombosis requires anticoagulation with warfarin while APS with arterial thrombosis requires anti-platelet agents (Ruiz-Irastorza, Hunt et al. 2007).

3.2.5 Prognosis

Ocular prognosis depends upon the presence of complications such as neovascularisation and therefore, regular ocular monitoring is required.

In patients with antiphospholipid syndrome, the risk of further thromboembolic complications ranges from 22% to 29% (Ruiz-Irastorza, Hunt et al. 2007)

4. Conclusion

Similar to systemic venous thrombosis, venous thrombosis in the eye is a manifestation of Virchow's triad. Ocular venous thrombosis presents as retinal vein occlusion. The eye can also be affected by systemic venous thrombosis. Accurate diagnosis of venous thrombosis is vital and early treatment should be implemented in order to preserve existing vision and to prevent serious visual, and life threatening complications.


5. References

- Agnelli, G. and M. Verso (2008). "Epidemiology of cerebral vein and sinus thrombosis." *Front Neurol Neurosci* 23: 16-22.
- Ang, L. P., E. Y. Yap, et al. (2000). "Bilateral choroidal infarction in a patient with antiphospholipid syndrome: a case report." *Clin Experiment Ophthalmol* 28(4): 326-328.
- Anonymous (1984). "Argon laser photocoagulation for macular edema in branch vein occlusion. The Branch Vein Occlusion Study Group." *Am J Ophthalmol* 98(3): 271-282.
- Anonymous (1986). "Argon laser scatter photocoagulation for prevention of neovascularization and vitreous hemorrhage in branch vein occlusion. A randomized clinical trial. Branch Vein Occlusion Study Group." *Arch Ophthalmol* 104(1): 34-41.
- Anonymous (1993). "Risk factors for branch retinal vein occlusion. The Eye Disease Case-control Study Group." *Am J Ophthalmol* 116(3): 286-296.
- Anonymous (1995). "Evaluation of grid pattern photocoagulation for macular edema in central vein occlusion. The Central Vein Occlusion Study Group M report." *Ophthalmology* 102(10): 1425-1433.
- Anonymous (1995). "A randomized clinical trial of early panretinal photocoagulation for ischemic central vein occlusion. The Central Vein Occlusion Study Group N report." *Ophthalmology* 102(10): 1434-1444.
- Anonymous (1996). "Risk factors for central retinal vein occlusion. The Eye Disease Case-Control Study Group." *Arch Ophthalmol* 114(5): 545-554.
- Anonymous (1997). "Natural history and clinical management of central retinal vein occlusion. The Central Vein Occlusion Study Group." *Arch Ophthalmol* 115(4): 486-491.
- Asherson, R. A., M. A. Khamashta, et al. (1989). "Cerebrovascular disease and antiphospholipid antibodies in systemic lupus erythematosus, lupus-like disease, and the primary antiphospholipid syndrome." *Am J Med* 86(4): 391-399.
- Baumgartner, R. W., A. Studer, et al. (2003). "Recanalisation of cerebral venous thrombosis." *J Neurol Neurosurg Psychiatry* 74(4): 459-461.

- Boukobza, M., I. Crassard, et al. (2007). "When the "dense triangle" in dural sinus thrombosis is round." *Neurology* 69(8): 808.
- Brown, D. M., P. A. Campochiaro, et al. (2010). "Ranibizumab for macular edema following central retinal vein occlusion: six-month primary end point results of a phase III study." *Ophthalmology* 117(6): 1124-1133 e1121.
- Campochiaro, P. A., J. S. Heier, et al. (2010). "Ranibizumab for macular edema following branch retinal vein occlusion: six-month primary end point results of a phase III study." *Ophthalmology* 117(6): 1102-1112 e1101.
- Canhao, P., F. Falcao, et al. (2003). "Thrombolytics for cerebral sinus thrombosis: a systematic review." *Cerebrovasc Dis* 15(3): 159-166.
- Canhao, P., J. M. Ferro, et al. (2005). "Causes and predictors of death in cerebral venous thrombosis." *Stroke* 36(8): 1720-1725.
- Chua, B., A. Kifley, et al. (2005). "Homocysteine and retinal vein occlusion: a population-based study." *Am J Ophthalmol* 139(1): 181-182.
- Coutinho, J. M. and J. Stam (2010). "How to treat cerebral venous and sinus thrombosis." *J Thromb Haemost* 8(5): 877-883.
- Cugati, S., J. J. Wang, et al. (2007). "Retinal vein occlusion and vascular mortality: pooled data analysis of 2 population-based cohorts." *Ophthalmology* 114(3): 520-524.
- Dodson, P. M., E. E. Kritzing, et al. (1992). "Diabetes mellitus and retinal vein occlusion in patients of Asian, west Indian and white European origin." *Eye (Lond)* 6 (Pt 1): 66-68.
- Einhaupl, K., J. Stam, et al. (2010). "EFNS guideline on the treatment of cerebral venous and sinus thrombosis in adult patients." *Eur J Neurol* 17(10): 1229-1235.
- Fegan, C. D. (2002). "Central retinal vein occlusion and thrombophilia." *Eye (Lond)* 16(1): 98-106.
- Ferro, J. M., P. Canhao, et al. (2004). "Prognosis of cerebral vein and dural sinus thrombosis: results of the International Study on Cerebral Vein and Dural Sinus Thrombosis (ISCVT)." *Stroke* 35(3): 664-670.
- Ferro, J. M., C. Morgado, et al. (2007). "Interobserver agreement in the magnetic resonance location of cerebral vein and dural sinus thrombosis." *Eur J Neurol* 14(3): 353-356.
- Genevay, S., G. Hayem, et al. (2002). "Oculomotor palsy in six patients with systemic lupus erythematosus. A possible role of antiphospholipid syndrome." *Lupus* 11(5): 313-316.
- Giorgi, D. and C. Balacco Gabrieli (1999). "Optic neuropathy in systemic lupus erythematosus and antiphospholipid syndrome (APS): clinical features, pathogenesis, review of the literature and proposed ophthalmological criteria for APS diagnosis." *Clin Rheumatol* 18(2): 124-131.
- Gotoh, M., T. Ohmoto, et al. (1993). "Experimental study of venous circulatory disturbance by dural sinus occlusion." *Acta Neurochir (Wien)* 124(2-4): 120-126.
- Greiner, K., G. Hafner, et al. (1999). "Retinal vascular occlusion and deficiencies in the protein C pathway." *Am J Ophthalmol* 128(1): 69-74.
- Haller, J. A., F. Bandello, et al. (2010). "Randomized, sham-controlled trial of dexamethasone intravitreal implant in patients with macular edema due to retinal vein occlusion." *Ophthalmology* 117(6): 1134-1146 e1133.
- Hayreh, S. S. (2005). "Prevalent misconceptions about acute retinal vascular occlusive disorders." *Prog Retin Eye Res* 24(4): 493-519.

- Hayreh, S. S., L. Rubenstein, et al. (1993). "Argon laser scatter photocoagulation in treatment of branch retinal vein occlusion. A prospective clinical trial." *Ophthalmologica* 206(1): 1-14.
- Hayreh, S. S., B. Zimmerman, et al. (2001). "Systemic diseases associated with various types of retinal vein occlusion." *Am J Ophthalmol* 131(1): 61-77.
- Hayreh, S. S., M. B. Zimmerman, et al. (1994). "Incidence of various types of retinal vein occlusion and their recurrence and demographic characteristics." *Am J Ophthalmol* 117(4): 429-441.
- Heit, J. A. (2008). "The epidemiology of venous thromboembolism in the community." *Arterioscler Thromb Vasc Biol* 28(3): 370-372.
- Incorvaia, C., G. Lamberti, et al. (1999). "Idiopathic central retinal vein occlusion in a thrombophilic patient with the heterozygous 20210 G/A prothrombin genotype." *Am J Ophthalmol* 128(2): 247-248.
- Ip, M. S., I. U. Scott, et al. (2009). "A randomized trial comparing the efficacy and safety of intravitreal triamcinolone with observation to treat vision loss associated with macular edema secondary to central retinal vein occlusion: the Standard Care vs Corticosteroid for Retinal Vein Occlusion (SCORE) study report 5." *Arch Ophthalmol* 127(9): 1101-1114.
- Janssen, M. C., M. den Heijer, et al. (2005). "Retinal vein occlusion: a form of venous thrombosis or a complication of atherosclerosis? A meta-analysis of thrombophilic factors." *Thromb Haemost* 93(6): 1021-1026.
- Kirwan, J. F., M. D. Tsaloumas, et al. (1997). "Sex hormone preparations and retinal vein occlusion." *Eye (Lond)* 11 (Pt 1): 53-56.
- Martinelli, I., P. Bucciarelli, et al. (2010). "Long-term evaluation of the risk of recurrence after cerebral sinus-venous thrombosis." *Circulation* 121(25): 2740-2746.
- Miserocchi, E., S. Baltatzis, et al. (2001). "Ocular features associated with anticardiolipin antibodies: a descriptive study." *Am J Ophthalmol* 131(4): 451-456.
- Mitchell, P., W. Smith, et al. (1996). "Prevalence and associations of retinal vein occlusion in Australia. The Blue Mountains Eye Study." *Arch Ophthalmol* 114(10): 1243-1247.
- Miyakis, S., M. D. Lockshin, et al. (2006). "International consensus statement on an update of the classification criteria for definite antiphospholipid syndrome (APS)." *J Thromb Haemost* 4(2): 295-306.
- Purvin, V. A., J. D. Trobe, et al. (1995). "Neuro-ophthalmic features of cerebral venous obstruction." *Arch Neurol* 52(9): 880-885.
- Rogers, S., R. L. McIntosh, et al. (2010). "The prevalence of retinal vein occlusion: pooled data from population studies from the United States, Europe, Asia, and Australia." *Ophthalmology* 117(2): 313-319 e311.
- Ruiz-Irastorza, G., B. J. Hunt, et al. (2007). "A systematic review of secondary thromboprophylaxis in patients with antiphospholipid antibodies." *Arthritis Rheum* 57(8): 1487-1495.
- Scarrow, A. M., R. L. Williams, et al. (1999). "Removal of a thrombus from the sigmoid and transverse sinuses with a rheolytic thrombectomy catheter." *AJNR Am J Neuroradiol* 20(8): 1467-1469.
- Scott, I. U., M. S. Ip, et al. (2009). "A randomized trial comparing the efficacy and safety of intravitreal triamcinolone with standard care to treat vision loss associated with macular Edema secondary to branch retinal vein occlusion: the Standard Care vs

- Corticosteroid for Retinal Vein Occlusion (SCORE) study report 6." *Arch Ophthalmol* 127(9): 1115-1128.
- Shin, S. Y. and J. M. Lee (2006). "A case of multiple cranial nerve palsies as the initial ophthalmic presentation of antiphospholipid syndrome." *Korean J Ophthalmol* 20(1): 76-78.
- Srinivasan, S., A. Fern, et al. (2001). "Reversal of nonarteritic anterior ischemic optic neuropathy associated with coexisting primary antiphospholipid syndrome and Factor V Leiden mutation." *Am J Ophthalmol* 131(5): 671-673.
- Stam, J. (2005). "Thrombosis of the cerebral veins and sinuses." *N Engl J Med* 352(17): 1791-1798.
- Stam, J., S. F. De Bruijn, et al. (2002). "Anticoagulation for cerebral sinus thrombosis." *Cochrane Database Syst Rev*(4): CD002005.
- Stam, J., C. B. Majoie, et al. (2008). "Endovascular thrombectomy and thrombolysis for severe cerebral sinus thrombosis: a prospective study." *Stroke* 39(5): 1487-1490.
- Suvajac, G., L. Stojanovich, et al. (2007). "Ocular manifestations in antiphospholipid syndrome." *Autoimmun Rev* 6(6): 409-414.
- Tsaloumas, M. D., J. Kirwan, et al. (2000). "Nine year follow-up study of morbidity and mortality in retinal vein occlusion." *Eye (Lond)* 14(Pt 6): 821-827.
- Utz, V. M. and J. Tang (2011). "Ocular manifestations of the antiphospholipid syndrome." *Br J Ophthalmol* 95(4): 454-459.
- Wasay, M., R. Bakshi, et al. (2001). "Nonrandomized comparison of local urokinase thrombolysis versus systemic heparin anticoagulation for superior sagittal sinus thrombosis." *Stroke* 32(10): 2310-2317.
- Wong, T. Y., E. K. Larsen, et al. (2005). "Cardiovascular risk factors for retinal vein occlusion and arteriolar emboli: the Atherosclerosis Risk in Communities & Cardiovascular Health studies." *Ophthalmology* 112(4): 540-547.
- Yoshikawa, T., O. Abe, et al. (2002). "Diffusion-weighted magnetic resonance imaging of dural sinus thrombosis." *Neuroradiology* 44(6): 481-488.



Venous Thrombosis - Principles and Practice

Edited by Dr. Ertugrul Okuyan

ISBN 978-953-307-885-4

Hard cover, 232 pages

Publisher InTech

Published online 05, January, 2012

Published in print edition January, 2012

According to Virchow's triad, venous thrombosis can occur as a result of one or more of three factors: changes in the dynamics of the blood flow, endothelial injury/dysfunction of the blood vessel and hypercoagulability. The blood in the veins is constantly forming microscopic thrombi that are routinely broken down by the body, and significant clotting can occur only when the balance of thrombus formation and resolution is altered. This book is a fresh synthesis of venous thromboembolism care and considers the opinions and studies from different fields of medicine. As venous thrombosis spectrum is wide and can affect many organ systems, from deep veins of the leg to the cerebral venous system, our intent is for this to be a comprehensive, up-to-date and readable book. We tried to present a synthesis of existing material infused with new ideas and perspectives and authors own clinical studies and even case-reports.

How to reference

In order to correctly reference this scholarly work, feel free to copy and paste the following:

Bob Z. Wang and Celia S. Chen (2012). Venous Thrombosis and the Eye, Venous Thrombosis - Principles and Practice, Dr. Ertugrul Okuyan (Ed.), ISBN: 978-953-307-885-4, InTech, Available from:

<http://www.intechopen.com/books/venous-thrombosis-principles-and-practice/venous-thrombosis-and-the-eye>

INTECH
open science | open minds

InTech Europe

University Campus STeP Ri
Slavka Krautzeka 83/A
51000 Rijeka, Croatia
Phone: +385 (51) 770 447
Fax: +385 (51) 686 166
www.intechopen.com

InTech China

Unit 405, Office Block, Hotel Equatorial Shanghai
No.65, Yan An Road (West), Shanghai, 200040, China
中国上海市延安西路65号上海国际贵都大饭店办公楼405单元
Phone: +86-21-62489820
Fax: +86-21-62489821

© 2012 The Author(s). Licensee IntechOpen. This is an open access article distributed under the terms of the [Creative Commons Attribution 3.0 License](#), which permits unrestricted use, distribution, and reproduction in any medium, provided the original work is properly cited.