6

Dental Metal Allergy

Maki Hosoki and Keisuke Nishigawa
The University of Tokushima Graduate School
Japan

1. Introduction

Dental metal allergy is the general term used to describe allergic diseases caused by reactions to dental metal materials. Recently, allergic symptoms involving other dental materials, such as organic compounds, have been reported, and these allergic diseases need to be referred to as either a dental allergy or dental material allergy. When safety evaluations involving biomaterials are performed, various kinds of risk factors, including the potential for cytotoxicity and/or allergization, need to be taken into consideration (Geurtsen, 2002, Wataha, 2000).

At the present time, even ordinal dental treatment requires the use of many kinds of metallic and organic materials, some of which are known to cause allergic symptoms. The first clinical cases of dental metal allergy involved a mercurial allergy to intraoral amalgam fillings that led to stomatitis and dermatitis around the anus (Fleischmann, 1928). Previous studies in many countries have reported a variety of symptoms to be associated with different metals (Hubler&Hubler, 1983, Lundstrom, 1984, Magnusson et al., 1982, Wiesenfeld et al., 1984). Nickel, chromium, mercury, palladium, and cobalt are typical of metals used in dentistry that have caused allergies, which have included reactions to these materials not only in the mucosa of the oral cavity, but also on the skin of the hands, feet, and/or entire body (Gawkrodger, 2005, Hamano et al., 1998, Yanagi et al., 2005).

Typical allergies reported to be associated with dental materials have included contact dermatitis, systemic contact dermatitis, and contact dermatitis syndrome. Since most of the intraoral dental materials cannot be removed from home environments, these allergic reactions tend to be intractable, with repetitions of symptomatic treatments, such as external medications, found in many of these cases. Sometimes general and local dermatitis is found in the skin apart from the intraoral dental material, and it exhibits pathognomonic symptoms of the allergy that are different from those noted in other contact dermatitis.

2. Epidemiology

The prevalence of dental metal allergy has gradually increased over the last decade (Fig. 1). The demography of the dental metal allergy patients who visited Tokushima University Hospital is seen in Table 1. During July 2000 to June 2005, a total of 148 out of 212 patients (69.8%) exhibited a positive allergic reaction to at least one kind of the patch-test reagents. Since more than 80% of these patients were referred from dentists and dermatologists at other medical institutions, we expected to find a higher positive reaction rate as compared

to that of the other studies. Over a five-year surveillance period, nickel, palladium, chromium, cobalt and stannum exhibited the highest positive reaction rates to the patch tests in these patients. During this time period, the increases in the positive reaction rates for nickel, palladium, chromium and molybdenum were greater than those seen in our previous study (Fig. 2). (Hosoki et al., 2009)

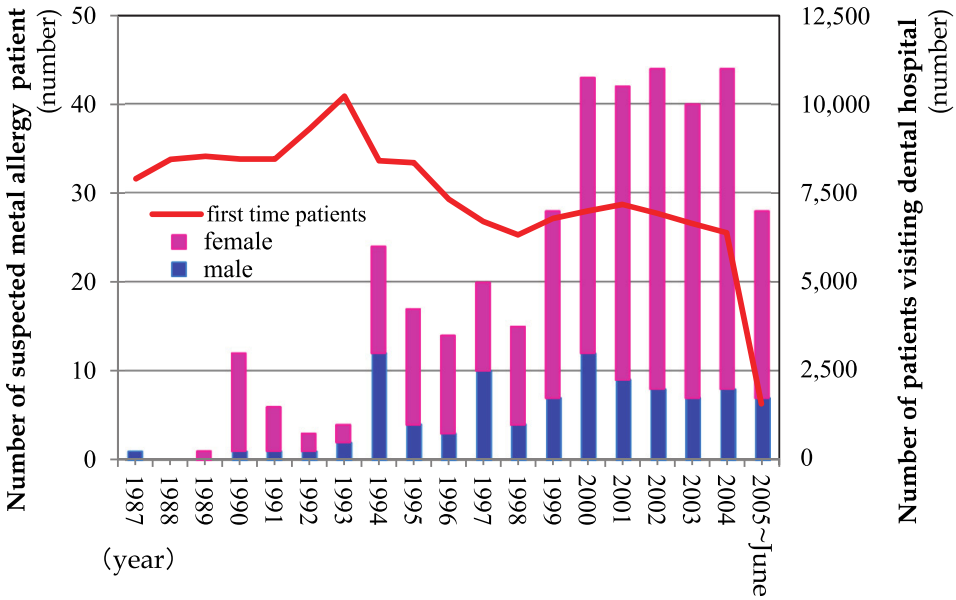

Fig. 1. Number of patients with dental metal allergy.

Period	July 2000 to June 2005	July 1995 to June 2000	July 1987 to June 1995
Patient number	212	114	60
Positive (adjusted residual)	148 (+2.4)	60 (–3.2)	41 (+0.7)
Negative (adjusted residual)	64 (–2.4)	54 (+3.2)	19 (–0.7)
Positive rate (%)	69.80	52.60	68.90

Table 1. Positive patch-test rates.

Akyol et al. have reported on the results of a European standard series of patch tests performed on 1038 contacts dermatitis patients. A total of 32.3% appeared to have a positive reaction with more than one reagent, and nickel exhibited the highest positive reaction rate (17.6%) (Akyol et al., 2005). Lam et al. investigated 2585 contact dermatitis patients and found that 54.7% exhibited a positive reaction rate, with the highest result seen for nickel (24.4%). In 2008, Lam et al. confirmed these results (Lam et al., 2008). On the other hand, Khamaysi et al. reported patch-test results for 121 patients and showed there was a higher positive reaction rate for gold-sodium-thiosulphate (14.0%), nickel sulfate (13.2%), mercury (9.9%), palladium chloride (7.4%), and cobalt chloride (5.0%) (Khamaysi et al., 2006).

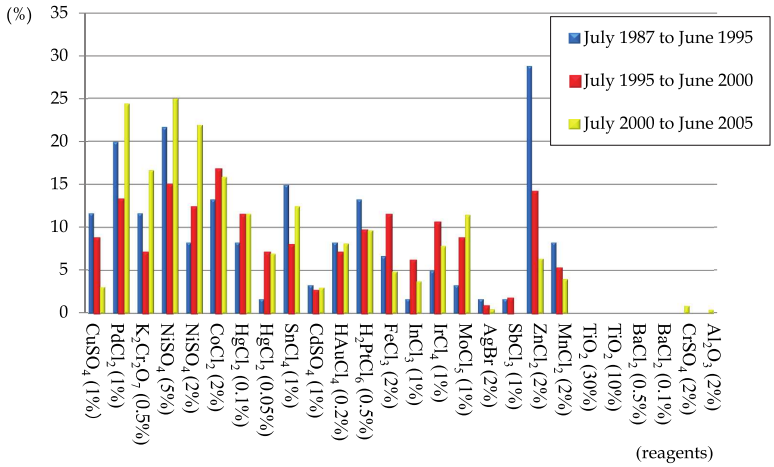

Fig. 2. Positive reaction rates for all patch-test reagents.

There have only been a few studies that examined healthy volunteers and the prevalence of metal allergies. Inoue used 18 types of metal reagents (Patch test allergens metal series, Tori Pharmaceutical Co., Ltd., Japan) to investigate allergic reactions in 1035 adult volunteers. Based on the International Contact Dermatitis Research Group (ICDRG) criteria, Inoue determined that 3.9% of the volunteers (male, 2.7%; female, 4.0%) exhibited positive reactions, regardless of the reagent used. Higher reaction rates were observed for metal reagents that contained $HgCl_2$ (11.1%), $SnCl_2$ (6.3%), $CoCl_2$ (5.4%), and $K_2Cr_2O_7$ (5.1%) (Inoue, 1993). However, since this study was reported in 1993, the estimation of the prevalence rate of metal allergy at present time would be expected to be higher.

3. Pathogenic mechanism

In general, the pathogenic mechanism for metal allergy has been classified as a type IV allergic reaction, which is the same as that for ordinal contact dermatitis (Fisher, 1973). In some cases it has been reported that removal of intraoral dental material containing allergy-positive metal elements relieves atopic dermatitis and asthma symptoms. Thus, this indicates that metal allergies may contain an aspect of the pathogenic mechanism for type I allergic reactions (Hosoki et al., 2002, Nakayama, 2002).

Under normal conditions, chemically stable metallic material rarely causes allergic symptoms. In the human body, the metallic ion itself cannot act as an allergen. However, if an electron from the external shell of a metallic item is removed, then the ionized metal element can be released within the human body. In such cases, these metal elements can bind to protein and form a hapten, which is then recognized by T-cells, and thus, ultimately leads to an allergic reaction (Davies et al., 1977, Ishii et al., 1990). Therefore, the tendency for ionization can be very influential with regard to the creation of an allergic reaction. If this potential ionization of a metal element can be prevented, the risk of metal allergy can be decreased. Unfortunately, intraoral circumstances, such as large amounts of electrolytic solutions, i.e. saliva, always surround metallic restorations and thus, the pH of a solution can rapidly fluctuate in line with the type of diet followed. Overall, this increases the difficulty in preventing changes of the dental metal material that can initiate allergies.

4. Pathology

4.1 Symptoms

Table 2 lists the symptoms and diagnosis of the metal allergy patients who visited the Clinic of Dental Metal Allergy at Tokushima University Hospital during the period ranging from 1987 to 2005. Symptom locations can vary from being on only a limited area of the body, such as on the oral mucosa, hands, palm, back or neck, to being found over the entire skin surface. However, each of these metal elements does not possess a distinct pathology and no correlation has been noted between the class of metal elements and the clinical symptoms. Explanations for the typical symptoms noted for dental metal allergy are presented in the following table.

	Number of patients					
	July 2000 to June 2005		July 1995 to June 2000		July 1987 to June 1995	
Symptoms	Number	%	Number	%	Number	%
Pustulosis palmaris et plantaris/dyshidrotic eczema	51	24.1	19	21.7	9	15.0
Lichen planus	24	11.3	15	17.1	4	6.7
Stomatitis/cheilitis/ gingivitis	21	9.9	13	14.8	8	13.3
Contact dermatitis	18	8.5	37	42.2	17	28.3
Allergic rhinitis	10	4.7			1	1.7
Anthema in hands and plantae	10	4.7	2	2.3		
Glossalgia	8	3.8			8	13.3
Asthma	8	3.8			1	1.7
Urticaria	8	3.8	1	1.1		
Atopic dermatitis	7	3.3	12	13.7		
Candidiasis	7	3.3				
Redness and eczema in one hand	7	3.3	2	2.3	3	5.0
Anthema	7	3.3				
Generalized eczema	7	3.3				
Contact dermatitis and redness with pierced earring, ring and necklaces	6	2.8				
Redness (hands and feet/ face)	5	2.4				
Intraoral white lesion	4	1.9				
Glossitis/lingual nervous feeling	4	1.9	2	2.3	4	6.7
Solar dermatitis	4	1.9			2	3.3
Other	40	18.9	11	12.5	3	5.0

Table 2. Typical symptoms and diagnoses.

4.2 Pustulosis palmaris et plantaris, and dyshidrotic eczema

In these patients, erythema, blisters with pustules, scale and crust typically appear on the palm and plantar (Fig. 3). In addition, sterile pustules are sometimes accompanied by itch, heat and painful sensations, and on occasion, osteoarthritis may also be found. Osteoarthritis symptoms involve the trunk, peripheral nerves, and the extra-articular region, and frequently there is local swelling, tenderness, heat sensation, and flare noted in these patients. During the early stages, histological findings show there is lymphocyte infiltration into the epidermis along with spongy degeneration. After formation of blisters and at the point where the blister reaches the horny cell layer, neutrophils appear and pustule development begins. At the present time, detailed pathoetiology of these symptoms has yet to be reported. Focal infection of the chronic inflammation from the palatine tonsil, marginal and periapical periodontitis, and metal allergy are all suspected as being predisposing factors.

(a) Pustulosis Palmaris (b) Pustulosis Palmaris

(c) Pustulosis Palmaris (crooked nails) (d) Pustulosis Plantaris

Fig. 3. Pustulosis palmaris et plantaris and dyshidrotic eczema.

4.3 Lichen planus

Chronic inflammatory disease can include dyskeratosis of the skin, oral and external genitalia mucosa. When it appears on the oral mucosa, lace or stitch pattern keratinizations

may be present and accompanied by erosion and ulceration (Fig. 4). On the skin, red or purple-red papules are seen at the internal area of the joint extremities and trunk. While some of these papules may be painless, others can cause itch, heat sensation or pain.

The buccal mucosa is the favorite site of lichen planus. In longstanding cases, this keratinization pattern can sometimes spread into the entire oral mucosa. In dental metal allergy cases, it appears at the oral mucosa attached to the metal restoration that contains the allergy-positive metal element.

Histological findings exhibit parakeratosis, liquefaction degeneration of the basal cell, and T lymphocyte infiltration under the epithelial tissue. At the present time, the pathoetiology of lichen planus is still not clear. Mechanical stimulation, metal allergy, and the hepatitis C virus (HCV) are all suspected as being predisposing factors. Since Jubert et al. reported that about 30% of these patients exhibit HCV antibody, inveterate cases of lichen planus should have both liver function and HCV antibody tests performed.

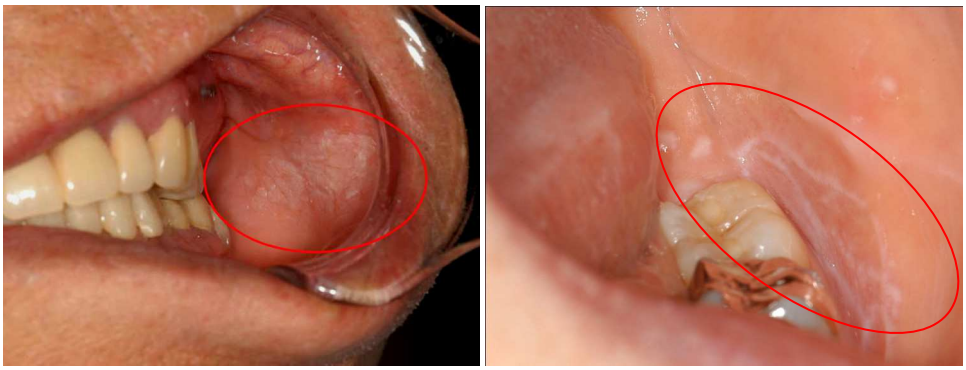

Fig. 4. Lichen planus.

4.4 Stomatitis, glossitis, cheilitis

The clinical and histological findings of these symptoms around the oral cavity do not differ from ordinal oral inflammations. Red halo glossitis and cheilitis sometimes can occur on the

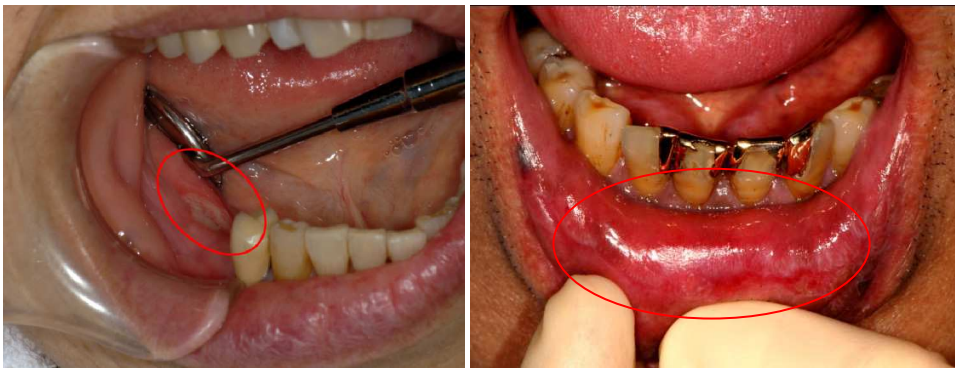

Fig. 5. Stomatitis and cheilitis.

oral mucosa close to the suspected dental prosthesis that contains the allergy-positive metal elements (Fig. 5). However, stomatitis and aphthous oral ulcers can sometimes occur on oral regions that are distant from the dental metal prosthesis. Regardless of the location, recurrent formations of the inflammation are frequently observed in these cases.

4.5 Glossodynia

In glossodynia, the main symptoms that patients encounter are pain, twitching and a burning sensation in the tongue. In some cases, no clear organic changes are ever found. Flare of the tongue, and an atrophy of the filiform papillae similar to that seen in geographical tongue can be found (Fig. 6). Possible predisposing factors include psychological factors, galvanic current, mechanical stimulation, allergy to metal elements eluted from a dental prosthesis, or a shortage of an essential nutrient.

Fig. 6. Glossodynia.

4.6 Generalized eczema and pseudoatopic dermatitis

In generalized eczema, an intractable itching dermatitis occurs on all of the skin (Fig. 7). In 1965, Shanon (Shanon, 1965) first reported pseudoatopic dermatitis to be a general eczematoid dermatitis caused by a chromic allergy due to shoe leather and cement. The clinical findings for this type of dermatitis are exactly the same as those seen for atopic

Fig. 7. Generalized eczema and pseudoatopic dermatitis.

dermatitis, with patients exhibiting no atopic diathesis and a low value for the immunoglobulin E (IgE) radioimmunosorbent test. Absorbed allergen is spread by blood flow and causes the eczema and urticaria on general skin, and in some cases is associated with itching, heat and painful sensations. Instead of referring to this as generalized eczema, the symptoms for this could be referred to as atopic dermatitis with metal allergy. The name of this disease is still being debated at the present time.

4.7 Atopic dermatitis

Typical symptoms of atopic dermatitis are chronic eczema with an itching sensation. Serum IgE is generally increased in these patients, and there is a repeated advancement to remission of the symptoms. Intractable cases sometimes exhibit a positive reaction to a metal reagent when using the patch test. In such cases, removing the intraoral metal restorations that contain the allergy-positive metal could lead to a remission of the symptoms. Since the skin barrier function of atopic dermatitis patients is compromised and not enough to prevent infection and sensitization, metal allergies tend to complicate these types of cases.

5. Diagnosis and treatment

The figure shows the flow chart for the diagnosis and treatment of dental metal allergy.

Fig. 8. Flow chart for diagnosis and treatment of dental metal allergic disease.

5.1 History taking

The primary goal of the questions for the metal allergy patients is to obtain a past history concerning their reaction to the metallic items that might be responsible for the allergic reaction. The following case highlights the information that leads to suspecting the patient of having a dental metal allergy.

1. Having incurable skin trouble with red spots, eczema, and vesicles, with ineffective dermatological treatment.
2. React to metals in ornaments and daily necessities, and is hard to cure.

3. After dental treatment with metal material, skin and intraoral symptoms developed or became incurable.

All of the patients were given recommendations to undergo a patch test for the purpose of diagnosing dental metal allergy. As an alternative in vitro examination, lymphocyte activation tests can also be used. However, since lymphocyte activation tests are not available for every metal element, the patch test should be considered as the first choice for confirmation of the diagnosis.

5.2 Patch test

Patch testing should be done according to criteria from the International Contact Dermatitis Research Group (ICDRG). Examination plasters containing the test reagent were attached to the back or the arm of the patient for 48 hours (Groot, 2008). After waiting for one hour after the plaster removal and the effect of the stimulation was gone, changes on the skin surface were evaluated according to the ICDRG criteria (Jean-Marie Lachapelle&Maibach, 2009). The same evaluations were repeated 72 hours and one week later. Since some of the metal reagents tended to exhibit a high reaction 7 days after plaster attachment, a minimum of a one-week test period is required for these tests (Davis et al., 2008). In addition, since aluminum in the Finn Chamber reacts with Hg^{2+} and produces hydrochloric acid, this chamber cannot be used for the $HgCl_2$ reagent.

5.2.1 Metal reagents

The following metal reagents are the primary reagents used for a patch test (Table. 3).

Product name	Test reagent
Trolab Patch Test Allergens	Metal Compounds
Brial Allergen GmbH	Epicutaneous contact allergens
	Dental materials
Chemotechnique Diagnostics	Patch Test Products, Dental Screening DS-1000
	Dental Materials Patients DMP-1000
Torii Patch Test Allergens	Metal series

Table 3. Test reagents

5.3 Treatment of dental metal allergy

If patients exhibited positive reactions to any of the metal reagents of the patch test, intraoral restorations that could potentially contain metal elements should be examined. Since most of the dental metal material is an alloy metal, simply inspecting the material is not adequate for distinguishing the metal elements. Thus, a non-invasive analysis technique that extracts micro dust from the intraoral restoration and examines it with an Electron Probe Micro-Analyzer (EPMA) or an X-Ray Fluorescence Spectroscopy (XRFS) needs to be performed (Minagi et al., 1999, Suzuki, 1995, Uo&Watari, 2004). For the extraction of metal dust, a tungsten-carbide bur is sometimes used to scrape the metal restoration (Minagi et al., 1999, Suzuki, 1995). However, to ensure there were minimal invasions of the site, we employed the following simple silicone point technique.

1. For each sample, prepare the following material set:

- A disposable polishing point (Super-Snap Mini Point, Shofu Corporation, Kyoto, Japan) (Fig. 9)
- Cellulose tape (Sellotape, Nichiban, Tokyo, Japan)
- Polypropylene film (3520 polypropylene, Spex Chemical Sample Press, Metuchen, NJ, USA)

Fig. 9. Disposable polishing point.

2. Clean the surface of the intraoral restoration with a dental cleaning brush in order to remove the plaque and other stains.
3. Attach the Super-Snap to the hand motor and scrub the surface of the metal restoration using a slow speed (1000-2000 rpm). If the antagonistic tooth was restored with a metal material, do not take any samples from the occlusal surface. This will prevent any effect of the metal on the antagonistic tooth.
4. Transfer the metal dust on the surface of the Super-Snap to a cellulose tape strip and cover the tape strip with polypropylene film.
5. The figure below shows pictures of a sample from an intraoral restoration. Micrometal dust on the cellulose tape strip has been covered with polypropylene film. The amount of the extracted sample was about 1 mg and no polishing of the tooth surface was required after the extraction.



Fig. 10. Polypropylene film, virgin metal sample and a Super-Snap Mini Point.

6. XRF spectroscopy analyzer (EDX900, Shimadzu Corporation, Tokyo, Japan) was used for evaluation of the metal element. Using this analyzer makes it possible for the

acquired sample can be sterilized using gaseous sterilization so that it can then be mailed to facilities that have a micro analyzer (Fig. 11). Since the analysis conditions of the XRFS are different for each device, we have not described the details for each of these devices.

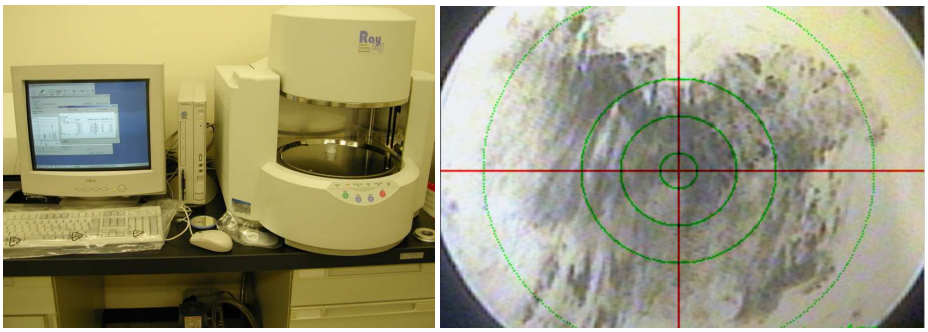

Fig. 11. XRF spectroscopy analyzer and the CCD camera view of the EDX900.

7. Results of the XRF analysis indicated whether or not the intraoral restoration involved an allergy-positive metal element. Since this technique was only available for restorations that were exposed on the surface of a tooth, materials used to build up a tooth, luting cements and root canal fillings could not be examined without having to remove the outer restorations. If the patients are able to identify the dental clinic where the original work was done, then the clinic can be contacted and the name of the metal products used determined before the materials are removed. If information on the actual metal element can be determined, then after informed consent is obtained from the patient, the intraoral metal materials previously utilized can be included in the planning of the subsequent dental treatment to remove the inadequate metal restorations.

5.4 Removal of metal restorations

When removing the restorations that contain allergy-positive metal elements, the removal priority should be as follows.

1. Oral restorations with high elutions, such as black-colored amalgam fillings.
2. Restorations located near the lesion site.
3. Restorations that contain a high rate of allergy-positive metal elements.
4. Two or more restorations with different metal materials that make contact with the occlusion or with the proximal teeth.

In principle, all restorations with allergy-positive metal elements need to be removed. The build-up material that was used for the inside of the full veneer crown is no exception, as it could be eluted. If the patient does not have an allergy to the acrylic material, composite resin filling and/or a temporary restoration with an acrylic resin can be performed to confirm the effect of removing the metallic materials. For patients with an acrylic allergy, glass ionomer cement can be used as a temporary treatment. After the metal material has been removed, sometimes an almost immediate aggravation of the allergic symptoms is observed. This could potentially be due to the effect of metal dust that was swallowed,

breathed in, or taken up by the oral mucosa during the removal procedure. In most cases, these symptoms are transient and the patient will recover within a couple of weeks. To avoid the possibility that a patient will develop such symptoms, all metal dust needs to be carefully excluded with oral evacuation equipment along with the adoption of the rubber dam dry field technique, whenever possible. In cases where allergy free metal materials are available, the final prosthesis using such metal material should be avoided until all allergy-positive metal materials have been removed. Additional metal restoration can increase the number of different metal elements in the oral cavity under certain circumstances, which may accelerate the elution of metallic ions from an allergy-positive metal element.

5.5 Reconstruction of dental restorations

Rebuilding of removed restorations should be started after complete elimination of all allergy-positive metal elements and the confirmation of no further relapse of symptoms. New restorations have to be made using allergy-negative materials for each of the individual patients. Since very small amounts of the element could cause an allergic symptom, all materials have to be tested to ensure that every micro component is allergy free. Since the reliability of the patch-test results have not been proven to be perfect, allergy-negative metal elements could still potentially cause allergy symptoms. Thus, during the reconstruction of dental prostheses, the initial restoration should be attached with temporary cement, and the patient prognosis followed for at least one month to ensure there are no allergy symptoms. In the case of a patient with a zinc allergy, careful selection of the luting cement is required. Zinc phosphate, zinc oxide eugenol, polycarboxylate cements along with most of the materials utilized for root canal fillings all have a zinc component and thus, cannot be used.

Lately, there have been many new products for dental restoration that have been developed and introduced in the market. Some of the new products that are listed below might potentially be useful for dental treatments of metal allergy patients.

5.5.1 Titanium

Since titanium possesses a fine biocompatibility property, this material has been used for pacemakers and dental implant biomaterials. Pure titanium can also be used for the material to fabricate a full veneer crown and fixed prostheses of the metal allergy patient. However, it should be noted that titanium wire used for orthodontic treatments contains a nickel-titanium alloy, and is not acceptable for nickel allergy patients.

5.5.2 Highly polymerized compounds

5.5.2.1 Hybrid ceramics

Recent progress of micro fillers and matrix components have greatly improved the physical property of light curing resin products. This newly developed product could potentially be applied in many clinical situations. The following table lists the official properties of the light curing resins currently on the market.

Name (Product)	Filler content (wt%)
Artglass (Heraeus Kulzer)	70
CERAMAGE (SHOFU)	73
GRADIA (GC)	75
ESTENIA C&B (Kuraray)	92
BelleGlass NG (Sybron Dental)	75
Targis (Ivoclar Vivadent)	77
Sculpture (Pentron)	78

Table 4. The official property of hybrid ceramics

5.5.2.2 Rebuilding materials for an abutment tooth

The combination of a composite resin for rebuilding and glass fiber has been used for an alternative to metal core rebuilding. Both a direct and indirect method can be used to fabricate the fibrous post using these materials.

The following are materials that can be used for fibrous posts.

5.5.2.2.1 FiberKor Post system (Pentron Clinical Technologies)

Type S glass fiber (10 μm in diameter) has a high physical property and is bundled up in matrix resin in order to make up the fibrous post used in the rebuilding. Components of the fibrous post are glass fiber (42%), filler (29%) and matrix resin (29%).

5.5.2.2.2 FIBER POST (GC Corp.)

Glass fibers that have a diameter of 14 μm are bundled lengthwise to create high density within the resin matrix. This material contains 58 vol% (77 wt%) of uniformed glass fiber.

5.5.2.2.3 CLEARFIL® FIBER POST (Kuraray)

Premier® Integra Fiber Post (Premier Products Co.)

This product contains 68% pre-silanated Zirconia-rich glass fibers within a composite matrix.

5.5.2.2.4 FRC Postec (Ivoclar Vivadent)

5.5.3 Ceramic materials

The progress in the field of ceramic materials has been quite remarkable as of late. Some of the all-ceramic restoration systems now on the market have a fine biostability and aesthetics that are suitable for use in treating metal allergy patients. With the development of computer-aided design and computer-aided manufacturing (CAD/CAM), all ceramics restorations with aluminous and zirconium coping have become the practical choice for esthetic prostheses (Fig. 12, 13). The zirconium ceramic systems in particular possess fine

physical properties with regard to toughness and strength, with some products able to be applied for use in a complete oral reconstruction. The following table lists all of the main ceramic system products that are currently on the market.

Classification by processing		Proprietary name	Product name	Chief ingredient
Slip Technique		In-Ceram Alumina	Vita	Al_2O_3,La_2O_3
		In-Ceram Zilconia	Vita	Al_2O_3, ZrO_2
Press molding		IPS Empress	Ivoclar Vivadent	Leucite
		IPS Empress2	Ivoclar Vivadent	Leucite
		OPC/OPC3G	Pentron	Leucit/Lithium disilicate
		Cergo	Degdent	Leucite
		Finesse All-Ceramic	Dentsply Ceramo	Leucite
Electrophoresis		Wol-Ceramn ELC System	Wol-Dent	Al_2O_3, ZrO_2
CAD/CAM		Cerec	Sirona	Glass ceramics, Llithium disilicate, Polymers
		GN-1	GC	Al_2O_3
		Decsy	Digital process	Leucite
		IPS e.max CAD	Ivoclar Vivadent	Lithium disilicate
CAD/CAM	Yttria	Procera	Nobel Biocare	ZrO_2
		Cercon	DeguDent	ZrO_2
		Lava	3M ESPE	ZrO_2
		Katana	Noritake	ZrO_2
		Everest ZS	KaVo	ZrO_2
		ZENO Zr Discs	WIELAND	ZrO_2
		Aadva Zr	GC	ZrO_2
	Cerium	Nano Zilconia	Panasonic Dental	ZrO_2

Table 5. Ceramic system products

(a) zirconium frame (Cercon, DeguDent)

(b) Forming of porcelain on zirconium frame

(c) Finished porcelain fused-to-zirconium crowns

Fig. 12. Example of zirconium blocks, zirconium frame before and after the sintering procedure, and the finished all ceramic crown.

Fig. 13. Example of zirconium crowns.

6. Clinical cases

6.1 Case 1: 51-year-old female with dyshidrotic eczema

The subject was an inpatient of the Dermatological Clinic of Tokushima University Hospital. Results of the patch test at the clinic revealed that the patient had a nickel, cobalt, iridium, zinc, manganese and platinum allergy. The figure 14 shows a picture of the patient's right palm at her initial visit to the Dental Metal Allergy Clinic. Anti-allergic medication and steroid ointment did not result in recovery from her allergic symptoms.

Prognosis

At the time she was seen in the clinic, the zirconium ceramic system for complete oral reconstruction was not on the market. Therefore, a semi-fixed prosthesis with four piece

units was designed for maxillary dentition, while a resin clasp denture was fabricated for her missing mandibular molar.

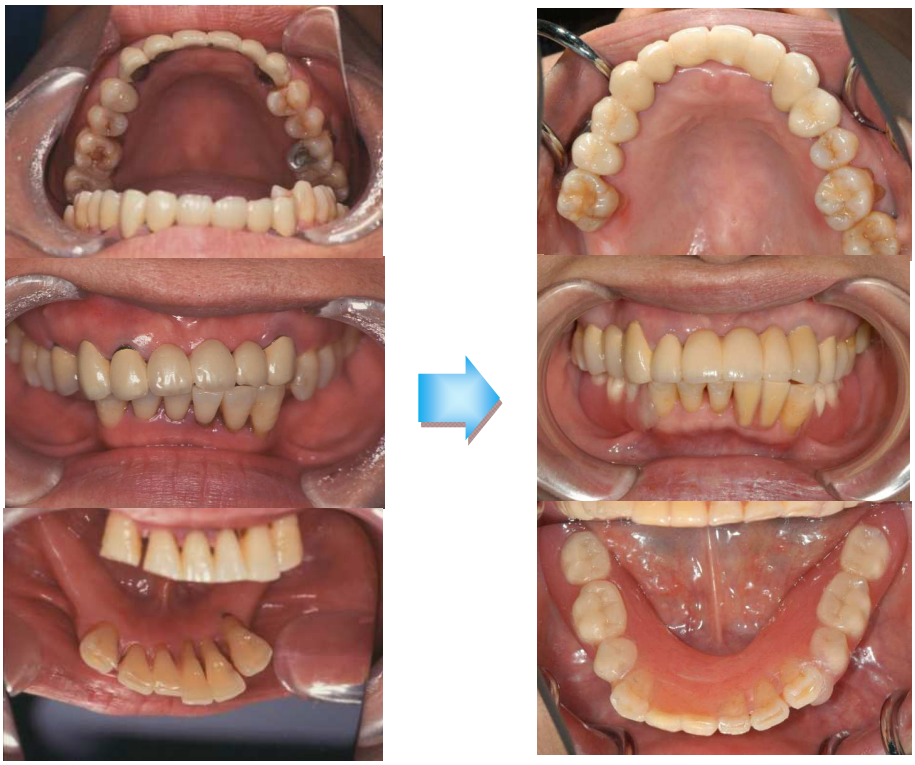

a) Intraoral pictures at first visit

(b) Intraoral pictures after dental treatment

(c) A picture of her hand at first visit

(d) A picture of her hands after dental treatment

Fig. 14. Intraoral pictures and hands before and after dental treatment.

6.2 Case 2: 62-year-old male who requested dental implant treatment

This patient had no past history of drug or food allergies and did not have allergic rhinitis. He became aware of his dermatitis symptoms on general skin in 1999 and was given external steroid medications at the dermatology clinic. Since he did not recover from his symptoms, he visited a general hospital in 2000 and was diagnosed with photodermatosis. At the hospital he was administered steroids, but exhibited no remarkable recovery. In 2002, he visited another dermatological clinic and was given external steroids and anti-allergic drugs, however, his symptoms remained. In 2005, he visited Tokushima University Hospital to ask for dental implant treatment. After examination by a dentist, the patient was referred to the Dental Metal Allergy Clinic.

Prognosis

Results of the patch test revealed that the patient had allergy-positive reactions to various kinds of metal reagents. An ultraviolet light test exhibited erythema with more than 5 minutes exposure to ultraviolet A (2.1 J/cm^2) and 50 seconds to ultraviolet B (35 J/cm^2). The

(a) Before dental treatment (b) After dental treatment

Fig. 15. Intraoral picture, and photos of the ear and back before and after the dental treatment.

minimal erythema dose was smaller with ultraviolet A. This patient was diagnosed as having complication dermatitis with photodermatosis, and dental metal allergy.

Subsequently, we then began to remove all metal restorations that contained allergy-positive metal elements. After removal of a fixed prosthesis and extraction of some of his teeth, a removable prosthesis with a non-metal clasp (Jeneric/Pentron, Wallingford, CT, USA) was fabricated. Porcelain fused to zirconium crowns were attached to the patient after complete removal of all of his metal restorations. In conjunction with the progress of the dental treatment, the previously exhibited erythema and swelling gradually reduced, and the prurigo in the local region recovered. The figure 15 shows an intraoral picture and the skin symptoms before and after the dental treatment. Clear recovery of the dermatitis was observed except the neck region that was exposed to sunlight. In this case, the exclusion of the intraoral metal restorations resulted in the healing of the patient's chronic and intractable dermatitis.

7. Discussion

Recently, the number of dental metal allergy patients along with the number of cases that practicing dentists have referred to our special outpatient section have increased. While the cause of this increase is not clear at the present time, suspicions have been raised about the effects of the popularization of pierced earrings as one of the potential causes. In Japan, ear/body piercings since the 1990s have been the cause of nickel allergies in female patients. It is possible that lifestyle choices could be one of the factors responsible for this high prevalence of dental metal allergy. Nickel hypersensitivity is one of the most common metal allergies, and we have documented a high positive reaction rate to nickel reagents. (Hosoki et al., 2009). Larsson-Stymne et al. reported finding a relationship between pierced earrings and nickel allergies (Larsson-Stymne&Widstrom, 1985). Sivertsen et al. also has reported finding the nickel allergy to be associated with pierced ears rather than either local pollution or atopic dermatitis (Smith-Sivertsen et al., 1999). Jensen et al. demonstrated there was a decrease in nickel sensitization in Danish schoolgirls whose ears had been pierced after implementation of the nickel-exposure regulations in 1992 (Jensen et al., 2002). These findings have led to other European countries to regulate exposure to nickel, and in the future, similar regulations may be enacted in Japan. One other study has reported that hypersensitivity reactions to nickel are likely to occur only when there is a prior sensitization from non-dental contacts, and even if this occurs, these sensitizations are still rare (Setcos et al., 2006, Spiechowicz et al., 1999). It is likely that nickel allergens from sources other than dental material will need to be considered in the future, as the use of the nickel alloy in dental materials in Japan is on the wane. Patients with inflammatory swelling due to several types of pierced earrings tend to show positive reactions to both gold and platinum, as well as nickel and palladium. The nickel allergy is known to be an important causative factor of atopic dermatitis (Klas et al., 1996). Therefore, care should be taken when using this material, as nickel allergies often cause serious allergic symptoms. In addition, one of the important results found in the current study was the positive reaction rate to palladium.

Due to the increase of patients with allergies noted over the last few years, practicing dentists need to have sufficient knowledge about dental metal allergies and be able to make these types of clinical diagnoses and then either treat these patients properly or refer them to

specialists who can take over these treatment regimens. Current data indicate that practicing dentists need obtain further specialized knowledge about dental metal allergy in order to ensure the correct treatment of patients in their clinics.

8. Conclusion

All treatments that employ dental metal materials have the potential to cause allergic symptoms, and thus, proper preventive measures and treatment plans are required for these allergy patients. The results of our current research demonstrate the necessity for educating all dental practitioners in the recognition and treatment of dental metal allergy.

9. References

Akyol, A.,A. Boyvat,Y. Peksari & E. Gurgey (2005). Contact sensitivity to standard series allergens in 1038 patients with contact dermatitis in Turkey, *Contact Dermatitis* (52): 333-7.

Davies, R. J.,B. T. Butcher & J. E. Salvaggio (1977). Occupational asthma caused by low molecular weight chemical agents, *J Allergy Clin Immunol* (60): 93-5.

Davis, M. D.,K. Bhate,A. L. Rohlinger,S. A. Farmer,D. M. Richardson & A. L. Weaver (2008). Delayed patch test reading after 5 days: the Mayo Clinic experience, *J Am Acad Dermatol* (59): 225-33.

Fisher, A. A. (1973). *Contact Dermatitis,Second Ed.*, NY.

Fleischmann, P. (1928). Zur Frage der Gefährlichkeit Kleinster Quecksilbermengen, *Dtsch Med Wochen scher* (54): 304

Gawkrodger, D. J. (2005). Investigation of reactions to dental materials, *Br J Dermatol* (153): 479-85.

Geurtsen, W. (2002). Biocompatibility of dental casting alloys, *Crit Rev Oral Biol Med* (13): 71-84.

Groot, A. C. d. 2008. Patch Testing. Amsterdam: ELSEVIER.

Hamano, H.,K. Uoshima,W. P. Miao,T. Masuda,M. Matsumura,H. Hani,H. Kitazaki & M. Inoue (1998). [Investigation of metal allergy to constituent elements of intraoral restoration materials], *Kokubyo Gakkai Zasshi* (65): 93-9.

Hosoki, M.,E. Bando,K. Asaoka,H. Takeuchi & K. Nishigawa (2009). Assessment of allergic hypersensitivity to dental materials, *Biomed Mater Eng* (19): 53-61.

Hosoki, M.,E. Bando,M. Nakano,K. Nishigawa,K. Okura & Y. Yamazaki (2002). A clinical investigation for the patients with dental metal allergy, *Journal of Dental Research* (81): 412.

Hubler, W. R., Jr. & W. R. Hubler, Sr. (1983). Dermatitis from a chromium dental plate, *Contact Dermatitis* (9): 377-83.

Inoue, M. (1993). The Status Quo of Metal Allergy and Measures Against it in Dentistry, *J.Jpn.Prosthodont.Soc* (37): 1127-1138.

Ishii, N.,H. Ishii,H. Ono,Y. Horiuchi,H. Nakajima & I. Aoki (1990). Genetic control of nickel sulfate delayed-type hypersensitivity, *J Invest Dermatol* (94): 673-6.

Jean-Marie Lachapelle & H. I. Maibach (2009). *Patch Testing and Prick Testing: A Practical Guide Official Publication of ICDRG*, Springer, Heidelberg.

Jensen, C. S.,S. Lisby,O. Baadsgaard,A. Volund & T. Menne (2002). Decrease in nickel sensitization in a Danish schoolgirl population with ears pierced after implementation of a nickel-exposure regulation, *Br J Dermatol* (146): 636-42.

Khamaysi, Z.,R. Bergman & S. Weltfriend (2006). Positive patch test reactions to allergens of the dental series and the relation to the clinical presentations, *Contact Dermatitis* (55): 216-8.

Klas, P. A.,G. Corey,F. J. Storrs,S. C. Chan & J. M. Hanifin (1996). Allergic and irritant patch test reactions and atopic disease, *Contact Dermatitis* (34): 121-4.

Lam, W. S.,L. Y. Chan,S. C. Ho,L. Y. Chong,W. H. So & T. W. Wong (2008). A retrospective study of 2585 patients patch tested with the European standard series in Hong Kong (1995-99), *Int J Dermatol* (47): 128-33.

Larsson-Stymne, B. & L. Widstrom (1985). Ear piercing--a cause of nickel allergy in schoolgirls? , *Contact Dermatitis* (13): 289-93.

Lundstrom, I. M. (1984). Allergy and corrosion of dental materials in patients with oral lichen planus, *Int J Oral Surg* (13): 16-24.

Magnusson, B.,M. Bergman,B. Bergman & R. Soremark (1982). Nickel allergy and nickel-containing dental alloys, *Scand J Dent Res* (90): 163-7.

Minagi, S.,T. Sato,K. Suzuki & G. Nishigawa (1999). In situ microsampling technique for identification of elements of a restoration with exposed metal to identify potential allergens, *J Prosthet Dent* (82): 221-5.

Nakayama, H. (2002). New aspects of metal allergy, *Acta Dermatovenerol Croat* (10): 207-19.

Setcos, J. C.,A. Babaei-Mahani,L. D. Silvio,I. A. Mjor & N. H. Wilson (2006). The safety of nickel containing dental alloys, *Dent Mater* (22): 1163-8.

Shanon, J. (1965). Pseudo-atopic dermatitis. Contact dermatitis due to chrome sensitivity simulating atopic dermatitis, *Dermatologica* (131): 176-90.

Smith-Sivertsen, T.,L. K. Dotterud & E. Lund (1999). Nickel allergy and its relationship with local nickel pollution, ear piercing, and atopic dermatitis: a population-based study from Norway, *J Am Acad Dermatol* (40): 726-35.

Spiechowicz, E.,P. O. Glantz,T. Axell & P. Grochowski (1999). A long-term follow-up of allergy to nickel among fixed prostheses wearers, *Eur J Prosthodont Restor Dent* (7): 41-4.

Suzuki, N. (1995). Metal allergy in dentistry: detection of allergen metals with X-ray fluorescence spectroscope and its application toward allergen elimination, *Int J Prosthodont* (8): 351-9.

Uo, M. & F. Watari (2004). Rapid analysis of metallic dental restorations using X-ray scanning analytical microscopy, *Dent Mater* (20): 611-5.

Wataha, J. C. (2000). Biocompatibility of dental casting alloys: a review, *J Prosthet Dent* (83): 223-34.

Wiesenfeld, D.,M. M. Ferguson,A. Forsyth & D. G. MacDonald (1984). Allergy to dental gold, *Oral Surg Oral Med Oral Pathol* (57): 158-60.

Yanagi, T.,T. Shimizu,R. Abe & H. Shimizu (2005). Zinc dental fillings and palmoplantar pustulosis, *Lancet* (366): 1050.



Contact Dermatitis

Edited by Dr. Young Suck Ro

ISBN 978-953-307-577-8

Hard cover, 180 pages

Publisher InTech

Published online 16, December, 2011

Published in print edition December, 2011

This book centralizes on the subject of contact dermatitis. It aims to provide the dermatologist with a sound base of clinical wisdom and key scientific findings to make an accurate diagnosis and management plan. SPECIAL FEATURES: - Describes numerous possible allergens that cause contact dermatitis. - Provides details of research in the basic sciences to help our readers understand more about contact dermatitis. - Provides a comprehensive description of recently developed methods that have evolved for the diagnosis of contact dermatitis. - Provides a concise, clinically focused, user-friendly format, which can rapidly improve your knowledge of the disease. The past decade has seen significant changes in contact dermatitis. Our understanding of the pathophysiology, our diagnostic approaches, and management of the disease has evolved. In this volume, some of the world's most highly regarded experts discuss areas that have seen significant improvement, as well as areas for future development.

How to reference

In order to correctly reference this scholarly work, feel free to copy and paste the following:

Maki Hosoki and Keisuke Nishigawa (2011). Dental Metal Allergy, Contact Dermatitis, Dr. Young Suck Ro (Ed.), ISBN: 978-953-307-577-8, InTech, Available from: http://www.intechopen.com/books/contact-dermatitis/dental-metal-allergy

INTECH
open science | open minds

InTech Europe
University Campus STeP Ri
Slavka Krautzeka 83/A
51000 Rijeka, Croatia
Phone: +385 (51) 770 447
Fax: +385 (51) 686 166
www.intechopen.com

InTech China
Unit 405, Office Block, Hotel Equatorial Shanghai
No.65, Yan An Road (West), Shanghai, 200040, China
中国上海市延安西路65号上海国际贵都大饭店办公楼405单元
Phone: +86-21-62489820
Fax: +86-21-62489821