

Diagnosis of Acute Leukemia in Under-Resourced Laboratories

Abbas H. Abdulsalam
*Al-Yarmouk Teaching Hospital, Baghdad
 Iraq*

1. Introduction

Laboratory diagnosis of acute leukemia in modern hematology practice is increasingly relying on guidelines that require the availability of relatively expensive machines with consistent need for continuous quality control, kits supply and maintenance.

In under-resourced hematology laboratories there is usually a missing step in the battery of required investigations. Moreover, when some of the advanced diagnostic instruments can be found then the problem of chronic inadequate and irregular supply of kits and services would supervene. Therefore, the laboratory diagnosis would mostly depend on the more basic, but consistently available and well controlled, laboratory techniques that should at least include complete blood count (CBC) and peripheral blood morphology, after which a bone marrow study with aspirate and sometimes a trephine biopsy will follow.

Moreover, in specialized hematology centers there may be a routine availability of few special stains, a very limited immunophenotyping CD markers panel, cytogenetics and PCR or FISH testing mostly for BCR-ABL1 oncogene.

The aim of diagnosis, lineage assignment and sub-classification of acute leukemia in these laboratories should immediately serve a clear therapeutic goal.

Sketching rational systematic schemes for optimum use of the locally available investigation options would usually permit the diagnosis of most varieties of acute leukemias with a very acceptable level of reliability. Also these schemes may provide invaluable information regarding the prospect of update and future plans for laboratory development as it can show clearly where the weak joints are (Abdulsalam, 2010).

2. Basis of diagnosis of myelodysplastic syndrome (MDS)

The WHO classification of this pre-AML disorder (Table 1) can be applied in most under-resourced laboratories as it only entails the use of peripheral blood morphology and bone marrow aspirate morphology with Perl's reaction (diagnosis of rare hypoplastic and myelofibrotic MDS would require also bone marrow trephine biopsy) with the sole addition of cytogenetics, preferably performed on marrow aspirate sample.

Even when cytogenetic testing is not available, still the WHO classification can be reliably applied for the diagnosis of most of the MDS subcategories, with the exceptions of the otherwise provisional diagnosis of MDS-5q⁻ syndrome (which is characteristically found in a middle age or an elderly female with peripheral blood macrocytic anemia and upper

Type	Peripheral blood	Bone marrow aspirate
Refractory cytopenia with unilineage dysplasia: - Refractory anemia (RA) - Refractory neutropenia - Refractory thrombocytopenia	Uni- or bi-cytopenia and <1% blasts	Unilineage dysplasia* with <5% blasts
Refractory anemia with ring sideroblasts (RARS)	Anemia and <1% blasts	Erythroid dysplasia only with <5% blasts and >15% ring sideroblasts
Refractory cytopenia with multilineage dysplasia	Bi- or pan-cytopenia and <1% blasts	Bi- or tri-dysplasia with <5% blasts and <15% ring sideroblasts
Refractory cytopenia with multilineage dysplasia and ring sideroblasts	Bi- or pan-cytopenia and <1% blasts	Bi- or tri-dysplasia with <5% blasts and >15% ring sideroblasts
Refractory anemia with excess blasts-1 (RAEB-1)	1-4% blasts	5-9% blasts and no Auer rods
Refractory anemia with excess blasts-2 (RAEB-2)	5-19% blasts	10-19% blasts, or <19% blasts plus Auer rods**
MDS-Unclassified	Uni-, bi- or pan-cytopenia and <1% blasts	Cytogenetic diagnosis of MDS with uni-, bi- or tri-lineage dysplasia in <10% of the cells and <5% blasts
Isolated 5q- syndrome	Anemia with upper normal or increase platelet count	Isolated del(5q) on cytogenetic study, prominent large megakaryocytes with hypolobated nuclei and <5% blasts***

* Dysplasia is considered significant only if it is present in >10% of the cells.

** If Auer rods or pseudo-Chediak Higashi inclusions are present then MDS RAEB-2 is diagnosed even when the peripheral blood and bone marrow blasts are <5% and <10% respectively.

*** If blasts > 5% then it is classified as RAEB, although still lenalidomide treatment should be tried.

Table 1. WHO classification of MDS, 2008 (Vardiman, et al, 2009)

normal platelet count or even thrombocytosis, bone marrow megakaryocytes of normal overall size but with a relatively small mono- or bi-lobed nucleus and a very good response to a therapeutic trial of lenalidomide) (Kelaidi et al, 2008) and MDS-Unclassified (which can be diagnosed on follow up when the disease persists or even progress). This classification, unlike the late FAB classification, would keep with the newest 20% blasts cut-off point to diagnose acute leukemia, coping with the worldwide standards of MDS literatures and provide much more relevant prognostic groups.

3. Diagnosis of acute leukemia in under-resourced laboratories

FAB classification (Table 2) of acute leukemia should be applied in under-resourced laboratories where the only available routine techniques for diagnosis are morphology and special stains (Abdulsalam, 2010). The scheme in (Figure 1) may be used as a general guideline for the diagnosis of acute leukemia in under-resourced laboratories; however, it should be modified to optimally fit into the locally available techniques.

The practical application of WHO classification for acute leukemia (Tables 3 and 4) requires both diagnosis and risk stratification. The diagnosis can be based on morphology, special

stains and immunophenotyping (preferably using flowcytometry, or if it is not available then one can rely on either immunocytochemistry with/without immunohistochemistry). Laboratory risk stratification relies on cytogenetics and multiplex conventional PCR.

Later on, a follow up for minimal residual disease can be performed using the same genetic abnormality found at diagnosis, i.e., cytogenetic remission, or more accurately, real time quantitative (RQ) PCR for quantization of the characteristic translocation that was found positive (but without quantization using conventional “qualitative” PCR) at diagnosis.

Acute leukemia	Subtype	Morphology	Additional tests
ALL	L1	Small, homogeneous with high N:C ratio blasts	TdT, CD3, CD79a, CD20, CD10
	L2	Larger, heterogeneous, nucleolated with low N:C ratio blasts	
	Leukemic phase of Burkitt's lymphoma (L3)	Large, homogeneous and nucleolated blasts with basophilic and vacuolated cytoplasm	Cytogenetics, ISH or PCR
AML	M0	Undifferentiated blasts	Anti-MPO, CD117, CD33, CD68 or Lysozyme
	M1	Undifferentiated blasts ± dysplastic myeloid differentiation	SBB stain
	M2	Myeloblasts with myeloid maturation	
	M3	Characteristic morphology, Faggot cells	
	M3 variant	Characteristic morphology, bilobed nuclei	
	M4	Peripheral blood monocytes $\geq 5.0 \times 10^9/l$ ± bone marrow monocytic lineage $\geq 20\%$	NSE confirmation of monocytic lineage
	M5a (Monoblastic), M5b (Monocytic) and M5c (Histiocytic)	Bone marrow monocytic lineage $\geq 80\%$	
	M6	Trilineage dysplasia and $>50\%$ erythroblasts	SBB, Glycophorin + anti-MPO, avoid CD34 as it would stain both myeloblasts and proerythroblasts
	M7	Blast with cytoplasmic blebs and bone marrow fibrosis	CD41

Table 2. Diagnosis of acute leukemia based on FAB groups

Follow up for minimal residual disease using a multi-color flowcytometry can be adequately performed (Thorn et al, 2011) but is usually more demanding than the genetic techniques, and therefore, it may not be the best choice in a resource-poor laboratory.

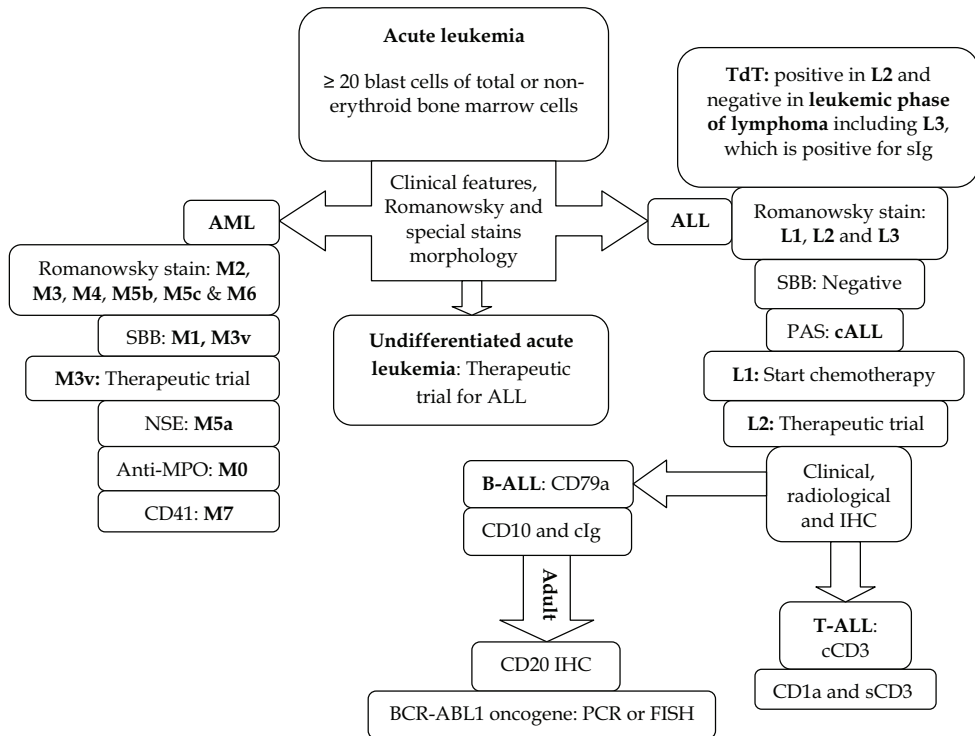


Fig. 1. Options for diagnosis of acute leukemia in resource-poor laboratories: FAB-based classification serving a clear therapeutic target.

3.1 Basis of diagnosis of acute leukemia

In the WHO classification of acute leukemia (Jaffe, et al, 2001) the diagnosis is based on an arbitrary cut-off point of 20% blasts as a percentage of bone marrow total or non-erythroid cells or as a percentage of peripheral blood cells. This exact percent is also applied nowadays in under-resourced laboratories where the FAB classification should be used (Bain, 2010a).

This 20% myeloblasts cut-off point seems to be universally accepted and for the time being it represents the best known tool for defining acute leukemia. However, the word “arbitrary” may still precede it and this may be attributed to (Abdulsalam, 2011):

1. This precise percent does not represent some specific biological event in the continuum of increasing blast count, but it is merely, to the best of our current knowledge, a cut-off point that permits a relatively clear classification and therapeutic aim. However, the fact that some high risk MDS patients are being treated actively with only 10% bone marrow blasts should be remembered.

--- Therapy- related myeloid neoplasms

--- De novo myeloid neoplasms

- AML with *recurrent genetic abnormalities* including
 - t(8;21)(q22;q22); RUNX1-RUNX1T1
 - inv(16)(p13.1q22) or t(16;16)(p13.1;q22); CBFβ-MYH11
 - t(15;17)(q22;q12); PML-RARA
 - t(9;11)(p22;q23); MLLT3-MLL
 - t(6;9)(p23;q34); DEK-NUP214
 - inv(3)(q21q26.2) or t(3;3)(q21;q26.2); RPN1-EVI1
 - t(1;22)(p13;q13); RBM15-MKL1
 - Provisional entity: AML with mutated NPM1
 - Provisional entity: AML with mutated CEBPA
- AML with myelodysplasia-related changes
- AML not otherwise categorized
- Myeloid sarcoma
- Myeloid proliferation related to Down syndrome
- Transient abnormal myelopoiesis
- Myeloid leukemia associated with Down syndrome
- Blastic plasmacytoid dendritic cell neoplasm

Table 3. WHO classification of AML, 2008 (Vardiman, et al, 2009)

--- B lymphoblastic leukemia/lymphoma

- B lymphoblastic leukemia/lymphoma, not otherwise specified
- B lymphoblastic leukemia/lymphoma with *recurrent genetic abnormalities* including

t(9;22)(q34;q11.2) and BCR-ABL1
translocation involving 11q23 and MLL rearrangement
t(12;21)(p13;q22) and ETV6-RUNX1
hyperdiploidy (> 50 chromosomes)
hypodiploidy (< 46 chromosomes)
t(5;14)(q31;q32) and IL3-IGH
t(1;19)(q23;p13.3) and TCF3-PBX1

--- T lymphoblastic leukemia/lymphoma

Table 4. WHO classification of ALL, 2008 (Vardiman, et al, 2009)

2. The significant difference in the cut-off point of blast percent between peripheral blood and bone marrow is well established in MDS as the two groups RAEB-1 (blast count less than 5% in peripheral blood and 5-9% in bone marrow) and RAEB-2 (blast count 5-9% in peripheral blood and 10-19% in bone marrow). In acute leukemia no such discrimination is available.
3. The morphological finding of pathological "clonal" blast, type II that contains Auer rods, Pseudo-Chédiak-Higashi (Abdulsalam & Sabeeh, 2011) (Image 1) or other specific inclusions that are not seen in reactive marrow, is referring to the diagnosis of RAEB-2 or AML, here again the arbitrary cut-off point of 20% blasts will decide the specific diagnosis.
4. The original FAB classification was based for many years on the arbitrary cut-off point of 30% bone marrow blasts and previously some patients with 20-29% blasts remained stable over months without chemotherapy. However, this major percent change was driven by the survival studies which revealed that patients with 20-29% myeloblasts have a similar survival pattern as those with 30% and more in the bone marrow (Jaffe et al, 2001).
5. Although myeloblasts recognition criteria as agranular and granular blasts achieved a reasonable consensus, there are minor discordances in their definitions and in practice it may be a matter of convention (subjective method) to discriminate it from the continuum of cells, as in deciding whether this cell is a blast type III or a promyelocyte.
6. The "blasts" refer to myeloblasts, lymphoblasts, monoblasts, promonocytes and megakaryoblasts.
7. Diagnosis of AML-M3 and its variant is not related to the blast percent.
8. Cases with blast cells less than 20% may still be diagnosed as acute leukemia if they present with certain recurrent cytogenetic abnormalities as in AML M4 with inv(16) or t(16;16)(p13;q22) and AML M2 with t(8;21) (Jaffe et al, 2001).
9. The utilization of 20% lower blast threshold is not really an issue in ALL because most patients at diagnosis already have more than 50% blasts. Moreover, a patient with normal or reduced peripheral blood count and bone marrow lymphoblasts about or slightly above 20% would usually be classified as lymphoblastic lymphoma rather than ALL. A 25% cut-off point has been suggested to arbitrarily differentiate between the two conditions.
10. In AML-M0 and M1 the 20% blasts cut-off point is also of no use in practice.

Laboratory diagnosis of acute leukemia in modern hematology practice is increasingly relying on objective techniques to detect a specific ultrastructural or genetic abnormality. Therefore, the era of 20% blasts to diagnose acute leukemia may not stand the time any longer than that of the old FAB group 30% blasts lower threshold. However, at least in the present and the near future the morphology will remain the initial diagnostic test of acute leukemia and the abovementioned blast threshold will still be useful as a tool for classification (Abdulsalam, 2011).

The presence or absence of myeloblasts has a central role in diagnosis of AML and suspicion of ALL respectively. The blasts are divided into agranular (type I) and granular (type II and III) blasts based on Romanowsky stain morphology. However, when using SBB stain many of the "apparently" agranular blasts turn to be granular. Pathognomonic signs of AML that can be seen with Romanowsky stain and more frequently with SBB stain include SBB-positive granules, Auer rods, atypical "thick" Auer rods, pseudo-Chédiak-Higashi inclusions (Abdulsalam et al, 2011a) (Image 1) and rectangular crystalline structures (Merino & Esteve, 2005).

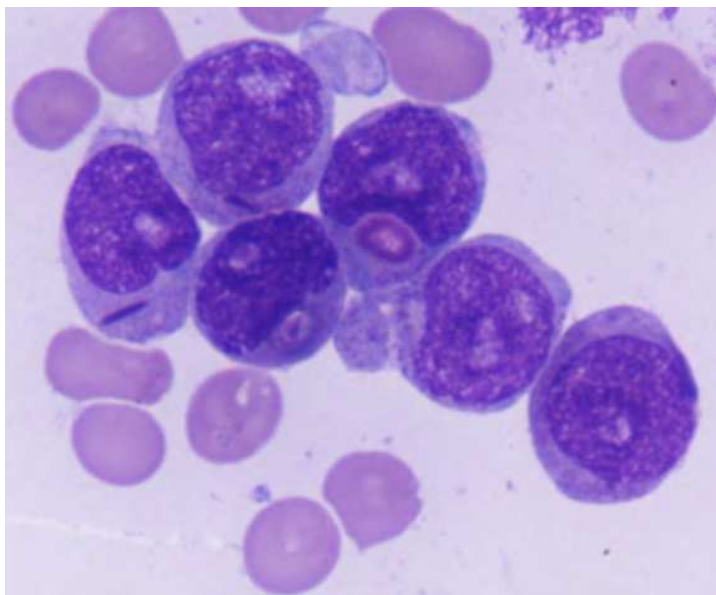


Image 1. Pseudo-Chédiak-Higashi inclusions together with atypical “thick” Auer rods in AML.

3.2 Clinical features

At diagnosis, acute leukemia should, in most of the cases, be clinically manifested within the last month with non-specific features like lethargy and fatigue or more commonly with specific features related to organ infiltration including bone marrow which results in anemia-related features, infections and bleeding. Other organ infiltration may refer not only to broad suspicion of acute leukemia but more likely to lineage assignment or even to a specific diagnosis, e.g., hepatosplenomegaly, lymphadenopathy, CNS symptoms and testicular involvement are in favor of ALL, severe bone pain in lower extremities would refer to B-ALL, thymic mediastinal mass and pleural effusion to T-ALL, bleeding tendency with overt coagulation tests defect can refer to AML-M3 and its variant and gum hypertrophy, skin involvement and hepatosplenomegaly in M4 and, more commonly, in M5.

3.3 Complete blood count (CBC)

Acute leukemia in most of the cases would present with one, or more often more abnormalities of the CBC, including anemia, leucocytosis (or less common leucopenia) and thrombocytopenia. Even when the WBC count is within normal limits the anemia, thrombocytopenia and WBC flags (in most automated cell counters) would raise fair enough suspicion.

Clinical features combined with CBC should be very sensitive in directing acute leukemia cases to be studied by peripheral blood smear.

3.4 Peripheral blood smear

Should be the backbone for the diagnosis of acute leukemia when there is leucocytosis or when leucocyte count is within reference range, as in most of the cases it provides a specific

diagnosis (ALL-L3 and AML-M3), a provisional diagnosis (ALL-L1 and AML M2, M3 variant, M4, M5b, M5c and M6) or at least a limited differential diagnosis (ALL-L2 and AML-M0, M1, M5a and M7).

When blasts are numerous in peripheral blood then special stains like SBB can be applied directly to it, this can be very useful for emergency diagnosis of AML-M3 variant especially within short time like before the weekend (Abdulsalam & Sabeeh, 2010). In cases with leucopenia, although frank blast cells may not be easily found, still there should be at least a clue to the diagnosis (including anemia, thrombocytopenia and myeloid dysplasia).

The presence of nucleated red cells and myeloid dysplasia mainly in the form of Pelger-Huet neutrophils should be investigated as the former can refer to AML-M6 and the later can suggest an AML with myelodysplasia. A bone marrow study should follow including aspirate and biopsy (when there is peripheral blood pancytopenia, and dry tap, hypocellular, diluted or difficult aspirate).

3.5 Bone marrow aspirate (BMA)

The diagnosis of acute leukemia in many instances is evident from the peripheral blood film; however, the bone marrow aspirate examination is always essential for confirmation of diagnosis, classification and application of special techniques including cytochemical stains, genetic studies, Immunocytochemistry (ICC) and immunohistochemistry (IHC).

IHC staining can be applied using the clotted marrow aspirate as a regular tissue sample after fixation and without decalcification (Bain, 2001a), to avoid bone marrow biopsy when there is no need for this procedure apart from the intention to apply immunophenotyping; however, it should be noted that the only use of clotted aspirate is for immunophenotyping, i.e., it should not be used as a regular morphology sample or any other application.

Apart from AML-M3 and its variant, the provisional and final diagnosis of the subtype of acute leukemia should not be issued before a proper BMA is performed. The classification of AML FAB groups is based on the percentages of blasts, maturing myeloid series (promyelocytes to neutrophils), monocytic series and erythroblasts from the total nucleated marrow cells. Also in some occasions many vital signs may be seen only in marrow aspirate like few Faggot cells in AML-M3 variant and even Auer rods. This phenomenon is aggravated when there is a peripheral leucopenia.

Diagnosis of acute leukemia is based on the presence of at least 20% blasts of total nucleated marrow cells, this condition may not be applicable especially in some AML cases, then 20% blasts limit should be obtained from the non-erythroid non-lymphoid marrow cells, otherwise the case would be labelled as MDS (Table 1). The reason for setting two lower thresholds is to simplify the morphology counts in practice, where in the first type of threshold the hematologist needs only to count the blast cells from all the nucleated cells in the field, this is much easier in practice but it would certainly require much higher blast threshold (which is available in almost all cases of ALL and many AML patients) than what would be required in the second form, which would be much more effort demanding and time consuming as one has to exclude erythroblasts, lymphocytes, plasma cells, macrophages and mast cells from the count.

Diagnosis of AML with myelodysplasia can only be confirmed by studying the bone marrow aspirate morphology with trilineage dysplasia. Dyserythropoiesis alone can be seen in many malignancies and is multifactorial, dysmyelopoiesis is supportive to the diagnosis of AML; however in cases where neutrophils and maturing myeloid cells are few then

absence of dysmyelopoiesis does not affect the diagnosis. Dysmegakaryopoiesis, especially in the form of micromegakaryocytes is in favour of diagnosis of AML with a preceding myelodysplastic syndrome.

3.6 Bone marrow biopsy

Is indicated when failed to obtain an adequate marrow aspirate, which may result from improper aspiration technique, presence of fibrosis (especially in ALL and AML-M7; in both conditions there may be a leucoerythroblastic anemia and tear drop poikilocytes in peripheral blood), aleukemic or subleukemic peripheral blood and bone marrow aspirate smears due to heavily packed marrow (especially in ALL) or presence of hypoplastic acute leukemia (especially in AML). It is also indicated when there is an intention to apply routine immunophenotyping (although this can be adequately applied on clotted marrow sections, see paragraph 3.5). It can be stated that the bone marrow biopsy is not an essential investigation in acute leukemia diagnosis when obtaining an adequate marrow aspirate (Bain, 2001b).

The presence of peripheral blood leucocyte count above or within the upper normal count can be used as an indicator that a bone marrow biopsy would not be essential; in contrast, leucopenia or pancytopenia suggest the need for bone marrow biopsy.

3.7 Acute Myeloid Leukemia (AML)

With Romanowsky stain morphology AML- M2, M3, M4, M5b, M5c and M6 can be recognized readily.

By adding few special stains such as Sudan black B, and not myeloperoxidase (MPO) as SBB has a little more sensitivity in detecting myeloblasts which is crucial for diagnosis of AML, plus a non-specific esterase (NSE) stain as ANAE it becomes possible to recognize AML-M1 and most cases of AML-M5a respectively (Bain, 2006).

Rare types of AML like M5c require a higher degree of morphology experience, in which malignant cells appearance is reminiscent of tissue histiocytes (Image 2) (Abdulsalam & Sabeeh, 2009a).

The AML cases that cannot be distinguished by Romanowsky and special stains morphology are M0 and M7, for which the presence of myeloid dysplasia (abnormal nuclear morphology and cytoplasm hypogranularity using a Romanowsky stain or absence of SBB stained granules from maturing myeloid cells and neutrophils) (Image 7) in the former and the blasts' cytoplasmic blebs and bone marrow fibrosis in the latter may give a hint for the probable diagnosis, however there is still the need for more positive diagnostic technique and as the flow cytometry immunophenotyping may not be available then the use of a limited number of CD markers study by ICC/IHC is the option, these include mainly anti-myeloperoxidase for M0 and CD41 for M7.

When resources are limited then it is for the best to concentrate on cytoplasmic ICC/IHC CD markers with the highest lineage sensitivity and specificity.

There is a small proportion of cases that would be only certainly subclassified after the response to treatment as in rare forms of AML-M3v in spite that SBB stain is usually of help in this form (Images 5 and 6).

Risk stratification of AML is based on genetic studies.

3.8 Acute Lymphoblastic Leukemia (ALL)

Consideration of clinical as well as hematological features permits a strong presumptive diagnosis of ALL (Bain, 2010). ALL-L3 diagnosis (which should be referred to as the

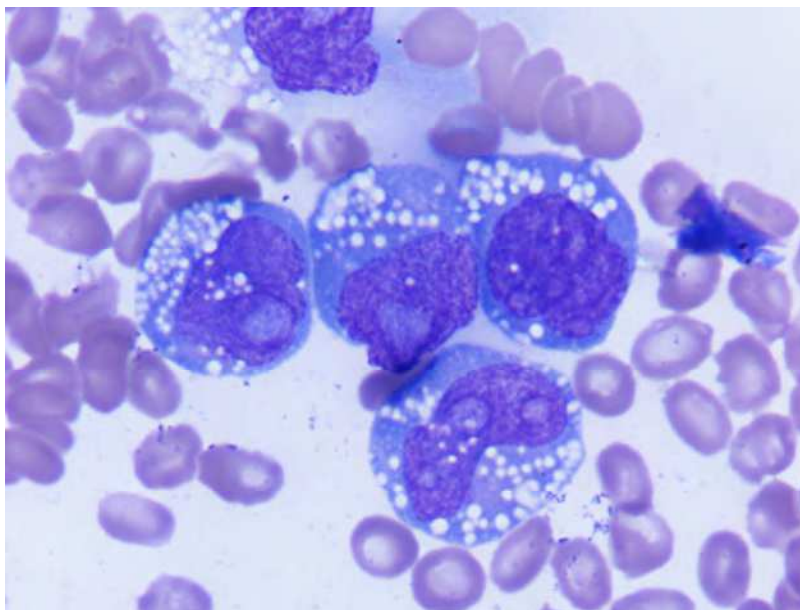


Image 2. Blast cells appearance in AML-M5c.

leukemic phase of Burkitt's lymphoma as it arises from mature B-cells) would be obvious by morphology alone and it is convenient to rely on morphological diagnosis of ALL-L1 and start treatment. Also if a patient with an acute leukemia showing heterogeneous blasts that has no morphological markers of myeloid differentiation, negative staining with SBB with unavailability of further differentiating procedures then it may be treated initially as ALL-L2, as statistically speaking it would be much more possible than AML-M0. The negative result in staining with SBB is very helpful, while the addition of the special stain PAS would improve the chances of the correct diagnosis of common ALL. However, a case with positive staining results for both SBB and PAS is an acute myeloid leukemia (Image 3).

Clinical features as bone pain and radiological sign of mediastinal mass may presumptively aid in differentiating between B- and T-ALL, however, using ICC/IHC antibodies including CD79a for B lineage and CD3 for T lineage are necessary. After setting the diagnosis of B-ALL in adults then ICC/IHC CD20 typing and PCR or FISH for BCR-ABL1 fusion gene would affect the treatment options.

In children (neonate up to 15 years) there is some reluctance for BCR-ABL1 testing due to its low frequency, only about 3%. However, it may be prudent to test for this transcript in children who have some lymphoblasts with large azurophilic granules (represent approximately 10% of cases) (Jaffe, et al, 2001) as this, beside cutting short additional costs, can offer a safer limit.

Rare cases of ALL-L2 that are confused with leukemic phase of large cell lymphoma can be differentiated through the use of TdT immunohistochemistry typing on bone marrow biopsy slide, which would be positive in ALL but not in lymphoma.

Risk stratification of ALL is based on immunophenotypic and genetic studies.

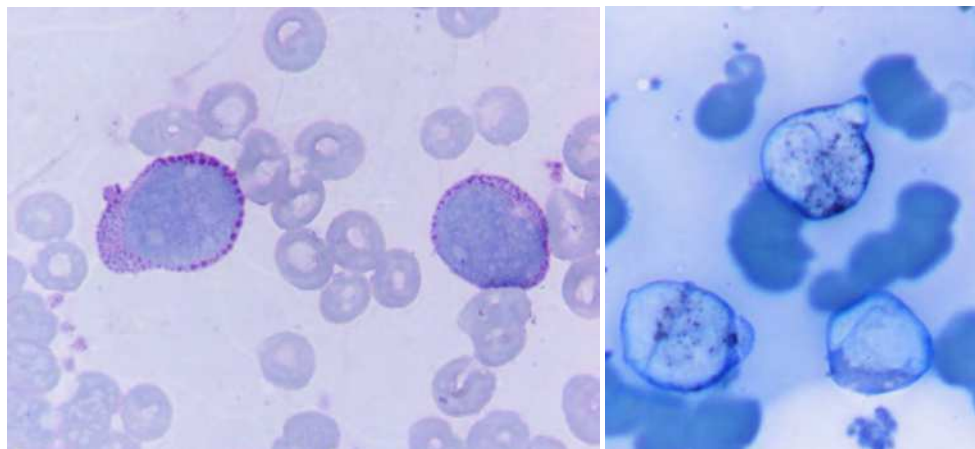


Image 3. Composite photograph of a patient with AML-M1 who had a 95% PAS-positive blasts (left image) and SBB positive blasts (right image).

3.9 Biphenotypic acute leukemia

The diagnosis of this acute leukemia requires a simultaneous application of several myeloid and lymphoid CD markers, or at least a request for the main lymphoid markers (CD3 and CD79a) after finding a SBB positive result (Matutes et al, 1997).

In resource-poor laboratories a step-by-step algorithm is followed in order to use the least possible resources, therefore, the identification of a mixed acute leukemia can be missed, as when some clinical, morphological, cytochemical or immunological markers refer to one diagnosis then the other lines of investigations are usually skipped to save expenses. However, misdiagnosis of this rare type of acute leukemia to only one of its components may, in some cases, not adversely affect the patient.

3.10 Rare types of acute leukemia

In a resource-poor laboratory these types of acute leukemia can be identified only if it happened to show some characteristic features using one of the essential techniques including, e.g., AML-M5c characteristic peripheral blood and bone marrow morphology, while others like biphenotypic acute leukemia may be misdiagnosed to only one of its components as described in paragraph 3.9. Natural killer-cell leukemia can be confused initially with reactive lymphocytosis as it results in CD3 negative and its characteristic CD56 marker is not usually tested for in an under-resourced laboratory.

3.11 Special stains

For diagnosis of AML, especially M1 and M5, the addition of Sudan black B (SBB) and a non-specific esterase stain as α -naphthyl acetate esterase is respectively essential. While for ALL a negative result (0-2%, these rare SBB positively stained blasts represent remnant normal myeloblasts) with SBB staining is crucial to support the diagnosis. The addition of PAS stain would not add a lot to support the diagnosis of ALL as it can, at least occasionally, be equally positive in AML; however, a positive PAS stained vacuolated blasts can be useful

to refer to cALL in 98% of cases (Bain, 2010a), here again CD10 ICC/IHC staining would be more meaningful.

3.11.1 Sudan Black B (SBB) stain

It is one of the few, but very useful, cytochemical stains to choose in a resource-poor laboratory. Care should always be paid for counting blasts with the right black color, intensely stained granules. The appealing characters that entail the use of SBB stain are:

- i. The reaction and non-reaction with SBB stain are both significant, as the former refer practically to AML and the latter supports the diagnosis of ALL or AML-M0.
- ii. The intensity of a positive reaction with SBB in general parallels myeloperoxidase activity. Generally local experience would decide which stain to choose. However, SBB gives a slightly more intense reaction and sensitivity than myeloperoxidase staining in the detection of myeloblasts and is safer than the older technique of MPO staining (using carcinogenic benzidine or its derivatives).
- iii. Better demonstration of Auer rods by using SBB stain than any of the usual Romanowsky stains. This would be of utmost benefit to identify all MDS cases with Auer rods, to differentiate some AML from ALL cases (Image 4) and also to follow up AML cases for morphological remission after induction chemotherapy.

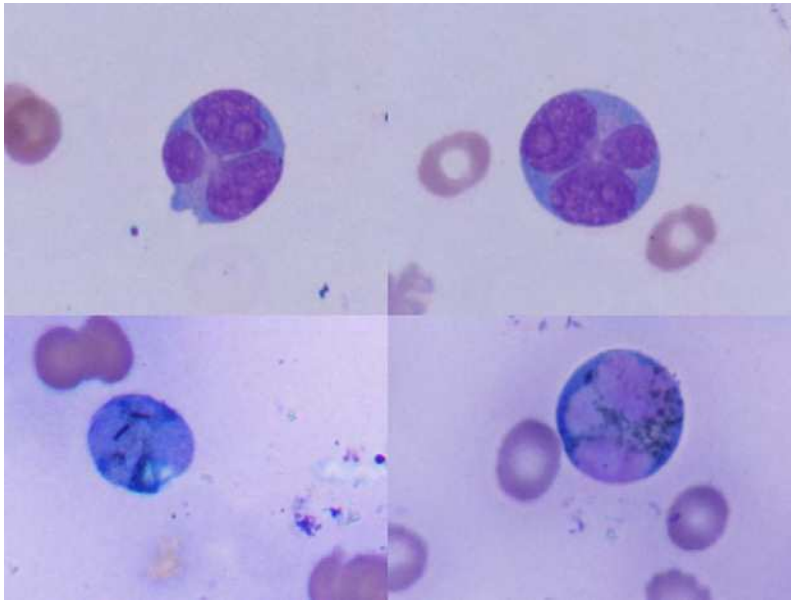


Image 4. Composite photograph of the peripheral blood film of a patient with AML-M2, the blasts showed unusual nuclear lobulation, these blasts contained SBB positive granules and Auer rods (Abdulsalam et al, 2011b)

In all AML subtypes, except for AML-M3, the presence of even one blast cell with Auer rod would refer to failure to achieve remission and indicate the need for a second induction chemotherapy course, while in AML-M3 finding an Auer rod after induction

is usually a part of response to treatment as it appears in more maturing myeloid cells (Wong, 2010) (Image 5).

- iv. The presence of 3% or more SBB stain positive blasts would characteristically refer to the diagnosis of AML-M1 rather than ALL.

Although it is now about 30 years since first reporting that in very rare cases even ALL blasts may show SBB positivity (Tricota, et al, 1982); however characters like being of less intensity than the control (remnant normal cells of the myeloid series), non-granular and diffuse reaction help to indicate that these are not myeloblasts. Also lymphoblasts would universally stain negative with MPO which can then be used to confirm the nature of the blasts.

- v. Increased SBB stain positivity at diagnosis is associated with better prognosis.
- vi. Speedy and firm enough diagnosis of AML-M3 variant cases (Image 6) to start ATRA treatment in the same day (Abdulsalam & Sabeeh, 2010).
- vii. Demonstration of myeloid series dysplasia (Image 7) (Bain, 2010b).
- viii. The stain can be easily applied to peripheral blood as well as bone marrow aspirate smears.

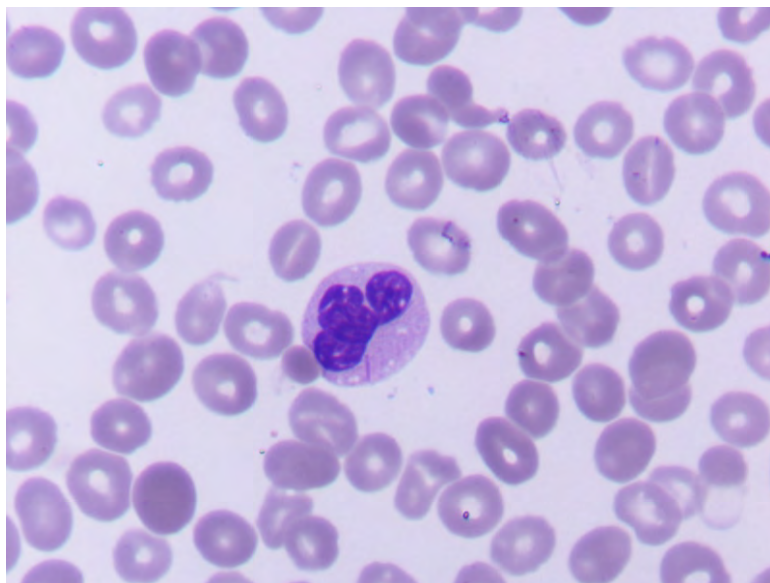


Image 5. Peripheral blood film of a patient with AML-M3 on ATRA treatment showing a dysplastic neutrophil that contains an Auer rod (Abdulsalam and Sabeeh, 2009b)

3.11.1.1 How to count the percentage of SBB positively stained blasts

The literatures are always referring to directly counting the blasts from the SBB stain slide, which is the best technique if the blasts can be easily recognized, but in practice and especially with AML-M1 this is not always feasible due to the nature of the stain which renders many blasts indistinguishable from other less immature cells. Therefore, there should be a second best technique to count the percent of smear positive SBB blasts, because it is not always possible to differentiate all the blasts directly from the SBB slide.

In the author's hematology laboratory practice the following procedure is applied by first utilizing the Leishman stain slide for counting cells into 3 categories as fractions from all the total marrow cells: 1st the blast cells; 2nd the maturing myeloid cells, which would be all assumed to stain positive, although some may actually be negative as a feature of myelodysplasia but nevertheless in calculations this would provide a higher safety threshold to avoid inappropriately classifying a case as AML and 3rd category for lymphocytes and nucleated red cells, which would be negatively stained. Then from the SBB stain slide count all the SBB positive cells and deducing the relative percentage of the SBB positive blasts.

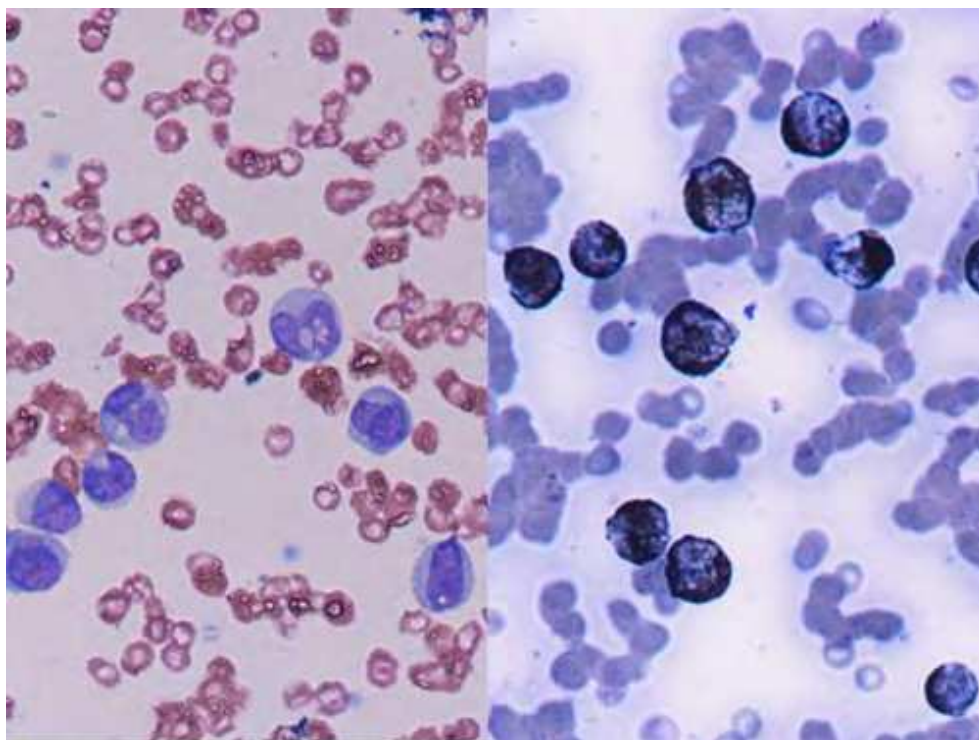


Image 6. Composite photograph showing Leishman staining (*left*) and SBB, cytochemical, staining (*right*) diagnosis of the variant form of AML-M3 (Abdulsalam & Sabeeh, 2010).

3.11.2 NSE

Including α -naphthyl acetate esterase (ANAE), or preferably, α -naphthyl butyrate esterase (ANBE) which is more specific than the acetate stain for the monocytic lineage, either stain is required to confirm the morphological diagnosis of AML-M4, M5a and M5b.

In some occasions there might be a differential diagnosis between M3v and M5b, in which cases it is best to avoid discrimination between them based only on NSE as it may be positive in both leukemias, instead a strong reaction with SBB in M3v can be used.

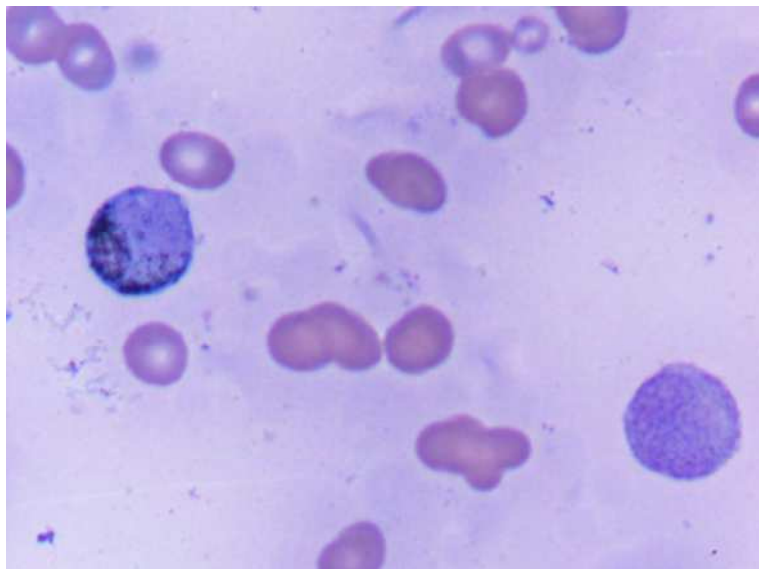


Image 7. Dysplastic metamyelocyte (bottom right) that is completely agranular with SBB staining. {Same patient in Image 4}

3.11.3 Periodic Acid Schiff (PAS)

It adds a minor support to diagnosis of ALL as a similar reaction can be seen, although less frequently in AML. Although the pattern of reaction was considered important in some literatures (Lewis et al, 2006) to differentiate between ALL (with clear cytoplasm between the positive granules) and AML (with cytoplasmic smudge positivity between the positive granules) but in practice relying on such a difference is very difficult, therefore, PAS use is considered non-essential and should be replaced by CD3 and CD79a ICC/IHC.

The other late advantage of PAS was to refer to possible cases of c-ALL; again this use has been superseded by CD10.

3.12 Immunophenotyping

Refers to identification of antigens within or on the surface of cells for the purpose of lineage assignment. It is not a proof for clonality instead of the genetic study.

In AML patients it is essential for proper diagnosis of M0 and M7. In ALL it is essential for diagnosis and risk stratification including T and B lineage assignment (as there is no reliable morphological features to differentiate between them), and subclassification into pro-, common (c), pre- and mature B-ALL and early, cortical and mature T-ALL.

A suggested list of ICC and IHC CD markers that should be available for diagnosis of acute leukemia can include: CD3 for T-ALL (CD7 is more sensitive than CD3, it almost reach 100% sensitivity for T-ALL but is not specific as it is also positive in 20% of AML cases; however, CD7 is still an excellent substitute for T-lineage assignment in rare cases of CD3 negative T-ALL where with the proper clinical and radiological features, Romanowsky and special stains morphology and other CD markers, as negative anti-MPO, then the diagnosis of ALL is evident) and CD79a for B-ALL.

When B-ALL diagnosis is confirmed then CD20 would help to decide for anti-CD20 (Rituximab) treatment option.

TdT would help to differentiate ALL-L2 (where it is positive) from leukemic phase of lymphoma (where it is negative).

For B-ALL CD10 is negative in pro-B-ALL and positive in common-ALL (c-ALL) which confers better prognosis. In pre-B-ALL cytoplasmic immunoglobulin (cIg) is positive while surface Ig (sIg) is positive only in mature B-ALL (ALL-L3 or leukemic phase of Burkitt's lymphoma, in which case TdT is negative).

Only cytoplasmic CD3 (cCD3) is positive in early T-ALL, cCD3 and CD1a are both positive in thymic or cortical T-ALL which confers better prognosis, while in mature T-ALL surface CD3 (sCD3) is positive and CD1a is negative.

Anti-myeloperoxidase, CD117 or CD33 can be used for AML-M0 and CD41 for AML-M7.

The availability of CD45 can be useful in rare occasions to ensure the hemopoietic nature of a poorly differentiated malignancy (Bain et al, 2002).

3.12.1 Flowcytometry

The newer multicolor (detecting many CD markers in/on the same single malignant cell) and multiparametric (a character comparative to that of automated blood counters studying characters like cell size and granularity) flowcytometer is one of the ultimate routine techniques in diagnosis of AML and ALL, primary risk stratification of ALL and follow up for MRD. When there is leucocytosis due to leukemic blasts then the flowcytometry study can be done on peripheral blood, otherwise, a bone marrow aspirate is the specimen of choice. However, the current price of the flowcytometer, cost of operating kits and maintenance make it unsuitable for laboratories with small budget.

3.12.2 Immunocytochemistry (ICC)

This technique should be consistently used in resource-poor laboratories for lineage and sub-lineage assignment of acute leukemia. It is applied on the bone marrow aspirate smear or, less conveniently on the peripheral blood after removal of plasma or on buffy coat (only if the blast percent is high). Sample spread can be done on a regular glass-slide (it is not essential to use a positively charged slide as in IHC) and after fixation in alcohol, ICC can be applied directly or after storage.

In acute leukemia the results of ICC (Image 8) can be interpreted in much more logical sense than IHC as the remaining normal or reactive cells can express some diagnosis-unrelated but confusing CD marker that in the aspirate can be easily detected to appear only for non-blast cells.

3.12.3 Immunohistochemistry (IHC)

Can be used as a substitute for ICC as the second best test for immunophenotyping of acute leukemia in the resource-poor laboratories if the blast percent is high, and if the results are unequivocally positive or negative or when the bone marrow aspirate is inadequate, otherwise when the blast percent is low or when the IHC positive result is in the borderline zone (20-30%) the judgment on the result of IHC can be difficult. For paraffin embedded IHC the designation between marker-positive blasts or reactive cells can be very difficult and in almost all conditions the total positivity per all marrow cells is expressed.

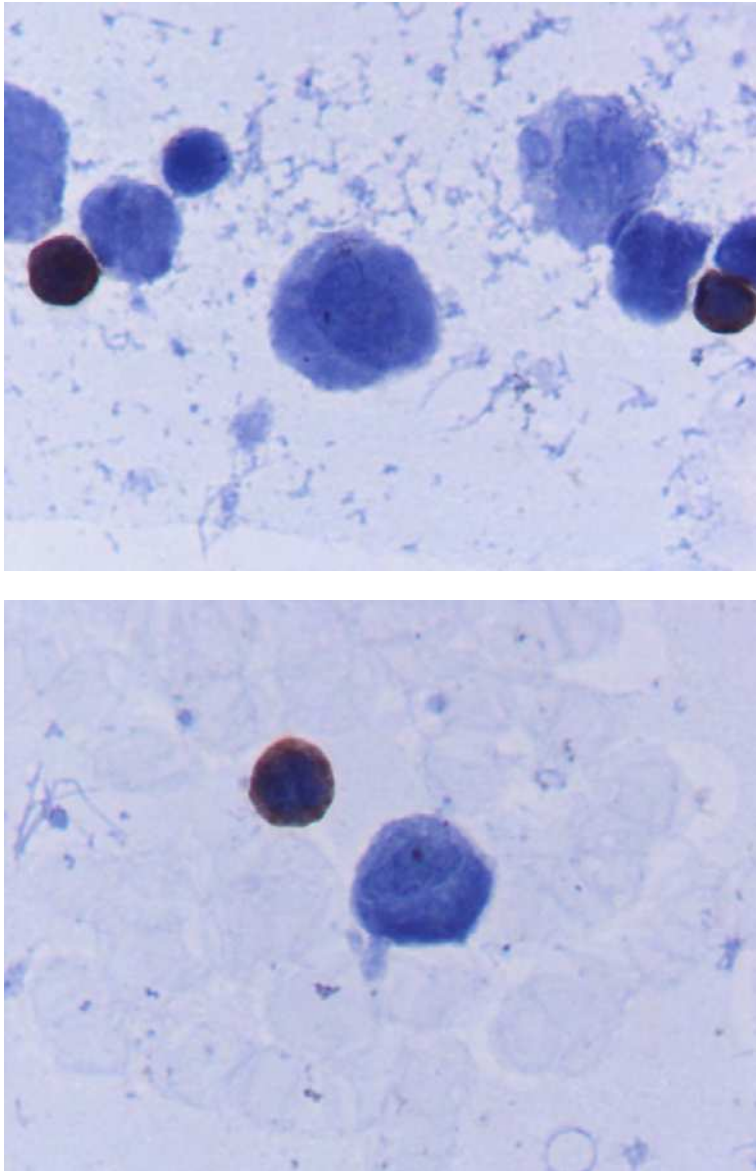


Fig. 8. Composite photograph of the same AML-M1 patient in (Image 2) showing CD 3 negative blasts (top image) with 28% “uncounted” positive small lymphocytes, and CD20 negative blasts (bottom image) with 5% “uncounted” positive small lymphocytes.

3.13 Genetic studies

Including mainly cytogenetics, InSitu Hybridization (ISH) and PCR. All of these techniques have advantages and limitations and the choice in acute leukemia should be based on at

least two different techniques that would give complementary information especially for risk stratification and follow up for MRD.

Older techniques, like Feulgen stain for quantization of DNA contents should be avoided even in under-resourced laboratories because these techniques are non-standard and confusing.

3.13.1 Cytogenetics

It should be routinely applied for every suspected case of acute leukemia. Cytogenetics would represent to genetic studies what a blood smear represents to hematology, i.e., study of morphology of chromosomes and blood cells respectively. However, it has major limitations as the procedure-inherent failure rate and inability to detect small size aberrations or cryptic translocations.

Cytogenetics, beside a molecular study, is essential for the application of the WHO classification of acute leukemia and its risk stratification.

3.13.2 InSitu Hybridization (ISH)

Including Fluorescent InSitu Hybridization (FISH) and Chromogenic InSitu Hybridization (CISH). Each technique has its advantages and limitations. FISH would represent a molecular genetic study plus demonstration of some chromosomal morphology. While CISH would represent a molecular genetic study plus demonstration of tissue morphology. In the author's opinion both techniques are not ideal for diagnosis, risk stratification and follow up of acute leukemia in an under-resourced laboratory.

3.13.3 Polymerase Chain Reaction (PCR)

Using only one detection kit multiplex RT-PCR assay is an effective, sensitive, accurate and cost-effective one-step multiple molecular re-arrangements diagnostic and risk-stratification tool. It is a complementary technique to conventional cytogenetics for risk stratification of acute leukemia and it provides a platform for the later on possibility of RQ-PCR detection of minimal residual disease (MRD) as multiplex RT-PCR is a qualitative procedure and is not used by itself as a mean for detection of MRD. For ALL, ETV6-RUNX1 and TCF3-PBX1 (both confer good prognosis), and MLL-MLLT2 and BCR-ABL1 (both confer poor prognosis) (Cerveira et al, 2000 and Shai, 2010); and for AML, FLT3 and MLL (both confer poor prognosis), and NPM1 and CEBPA (both confer good prognosis) (Strehl et al, 2001) paired primers are useful options (Salto-Tellez et al, 2003).

3.14 Chemotherapeutic trial for acute leukemia

A chemotherapeutic trial for those who cannot afford to seek a more precise diagnosis with genetic study and lineage specification abroad is a realistic option, as the response to treatment could be a very useful confirmation of the provisional diagnosis. The two examples already the author had faced are AML-M3v diagnosed provisionally only by morphology but with a dramatic response to ATRA trial, confirming the diagnosis (Image 9) and a few cases of morphologically undifferentiated acute leukemia in which the induction therapy for ALL is tried first (using vincristine and prednisolone only). If the patient responds, then a diagnosis of ALL can be deduced; if not, the regimen should be shifted to chemotherapy of AML (Abdulsalam, 2009).

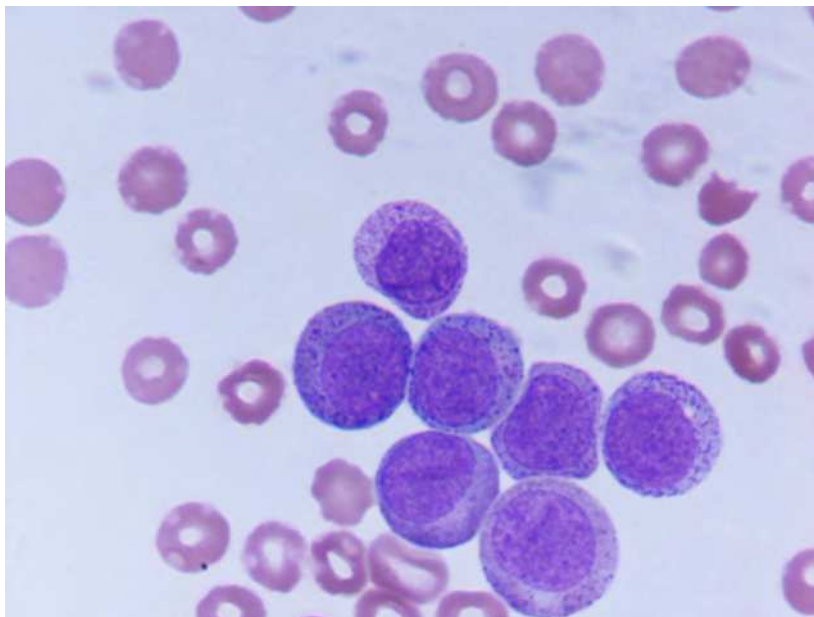


Image 9. Peripheral blood film showed 94% abnormal granulated promyelocytes. In the absence of any specialized tests, the diagnosis was made from cytological features. There was a dramatic response to ATRA, confirming the morphological diagnosis of AML-M3v (Abdulsalam & Nafila, 2009).

3.15 Lumbar puncture

Looking for cerebrospinal fluid (CSF) involvement with acute leukemia is advised in all patients with ALL, while for patients with AML it is only indicated for patients with neurological symptoms.

3.16 Remission

Durable remission in acute leukemia is based on clinical and morphological evidences. Clinical remission includes absence of symptoms and signs of leukemia. Complete blood count consistent with remission would include absence of severe anemia, neutrophil count more than $1 \times 10^9/l$ and platelet count more than $100 \times 10^9/l$ (Bain, 2010). Morphological remission of acute leukemia from peripheral blood involves absence of blasts, immature myeloid cells and nucleated red cells. Bone marrow aspirate consistent with morphological remission would include blast cells being less than 5% with absence of Auer rods. The presence of even one Auer rod on SBB stain would refer to failure to achieve remission.

Flowcytometry, cytogenetics or molecular genetics may be used to validate a morphological remission if any of these techniques were already utilized at diagnosis.

3.17 Minimal residual disease (MRD)

Detection of MRD entails the availability of either RQ-PCR or multi-color flowcytometry. Both techniques may not be routinely feasible for a laboratory with poor-resources.

4. Minimal technical requirements for application of WHO classification of acute leukemia

There should be at least a routine availability of CBC (manual or, preferably, automated), peripheral blood and bone marrow aspirate smears (and in some occasions bone marrow biopsy), SBB and a NSE stains, immunocytochemistry with/without immunohistochemistry (including at least CD3, CD79a, anti-MPO and CD41), cytogenetics and conventional PCR for the multiplex primers already mentioned in paragraph 3.13.3.

5. Conclusion

In hematology laboratories where the diagnostic resources are limited, it is essential to establish local guidelines that are practical in developing cost-effective diagnostic protocols for conditions for which the treatment is available, plus leaving the door wide open for future improvements, as to the introduction of newer techniques to the already available procedures once a newer therapeutic agent with certain lineage assignment demands has been introduced.

6. Acknowledgement

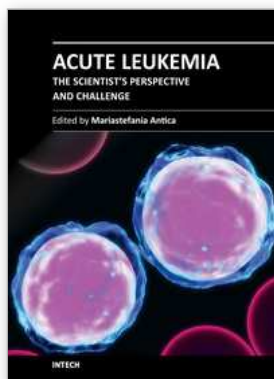
I would like to thank Dr. Nafila Sabeeh, laboratory hematologist at Al-Yarmouk Teaching hospital, for her invaluable notes.

7. References

- Abdulsalam, A. 2009. Chemotherapeutic trial for acute leukemia in Iraq. *Turkish Journal of Hematology*, 264, 216.
- Abdulsalam, A. 2010. Laboratory diagnosis of acute leukemia in Iraq, the available options. *Turkish Journal of Hematology*, 27, 320-321.
- Abdulsalam, A. 2011. "Arbitrary" criterion for the diagnosis of acute leukemia. *Turkish Journal of Hematology*, 28 (2): 149-150.
- Abdulsalam, A., Sabeeh, N. 2009a. Acute myeloid leukemia with histiocytic differentiation. *American Society of Hematology image bank*, 9, 80.
- Abdulsalam, A., Sabeeh, N. 2009b. Auer rod in a neutrophil following ATRA treatment of acute promyelocytic leukemia. *Slide atlas, BloodMed, British Society of Haematology*. Wiley-Blackwell.
- Abdulsalam, A., Sabeeh, N. 2010. Cytological/cytochemical diagnosis of the variant form of acute promyelocytic leukaemia. *Slide atlas, BloodMed, British Society of Haematology*. Wiley-Blackwell.
- Abdulsalam, A., Sabeeh, N., Bain, B. 2011a. Pseudo-Chédiak-Higashi inclusions together with Auer rods in acute myeloid leukemia. *American Journal of Hematology*, 86 (7): 602.

- Abdulsalam, A., Sabeeh, N., Bain, B. 2011b. Myeloblasts with unusual morphology. *American Journal of Hematology*, 86 (6): 499.
- Bain, B. 2001a. Bone marrow aspiration. *Journal of Clinical Pathology*, 54: 657-663.
- Bain, B. 2001b. Bone marrow trephine biopsy. *Journal of Clinical Pathology*, 54: 737-742.
- Bain, B. 2006. *Blood cell, a practical guide*. 4th ed. Blackwell publishing, Singapore.
- Bain, B. 2010a. *Leukaemia diagnosis* 4th ed. Wiley-Blackwell, Singapore.
- Bain, B. 2010b. Neutrophil dysplasia demonstrated on Sudan black B staining. *American Journal of Hematology*, 85, 9, 707.
- Bain, B., Barnett, D., Linch, D., Matutes, E., Reilly, J.T. 2002. Revised guideline on immunophenotyping in acute leukaemias and chronic lymphoproliferative disorders. *Clinical and Laboratory Haematology*, 24: 1-13.
- Cerveira, N., Ferreira, S., DoÂ ria, S., Veiga, I., Ferreira, F., Mariz, J., Marques, M., Castedo, S. 2000. Detection of prognostic significant translocations in childhood acute lymphoblastic leukaemia by one-step multiplex reverse transcription polymerase chain reaction. *British Journal of Haematology*, 109: 638-640.
- Jaffe, E., Harris, N., Stein, H., Variman, J. 2001. *World Health Organization classification of tumors, Tumors of Haemopoietic and Lymphoid tissues*. IARC press, Lyon.
- Kelaidi, C., Eclache, V., Fenaux, P. 2008. The role of lenalidomide in the management of myelodysplasia with del 5q. *British Journal of Haematology*, 140: 267-278.
- Lewis, M., Bain, B., Bates, I. 2006. *Dacie and Lewis practical haematology* 10th ed. Churchill Livingstone, Germany.
- Matutes, E., Morilla, R., Farahat, N., Carbonell, F., Swansbury, J., Dyer, M., Catovsky, D. 1997. Definition of acute biphenotypic leukemia. *Haematologica*, 82: 64-66.
- Merino, A., Esteve, J. 2005. Acute myeloid leukaemia with peculiar blast cell inclusions and pseudo-eosinophilia. *British Journal of Haematology*, 131, 286.
- Salto-Tellez, M., Shelat, S., Benoit, B., Rennert, H., Carroll, M., Leonard, D., Nowell, P., Bagg, A. 2003. Multiplex RT-PCR for the Detection of Leukemia-Associated Translocations. *Journal of Molecular Diagnostics*, 5 (4): 231-236.
- Shai, I. 2010. Application of genomics for risk stratification of childhood acute lymphoblastic leukaemia: from bench to bedside? *British Journal of Haematology*, 151: 119-131.
- Strehl, S., Konig, M., Mann, G., Haas, O. 2001. Multiplex reverse transcriptase-polymerase chain reaction screening in childhood acute myeloblastic leukemia. *Blood*, 97 (3): 805-808.
- Thörn, I., Forestier, E., Botling, J., Thuresson, B., Wasslavik, C., Björklund, E., Aihong, L., Eleonor L.E., Malec, M., Grönlund, E., Torikka, K., Heldrup, J., Abrahamsson, J., Behrendtz, M., Söderhäll, S., Jacobsson, S., Olofsson, T., Porwit, A., Lönnerholm, G., Rosenquist, R., Sundström, C. 2011. Minimal residual disease assessment in childhood acute lymphoblastic leukaemia: a Swedish multi-centre study comparing real-time polymerase chain reaction and multicolour flow cytometry. *British Journal of Haematology*, 152 (6): 743-753.
- Tricota, G., Broeckaert, A., Van Hoof, A., Verwilgdhen RL. 1982. Sudan Black B positivity in acute lymphoblastic leukaemia. *British Journal of Haematology*, 51, 615-621.

- Vardiman, J., Thiele, J., Arber, D., Brunning, R., Borowitz, M., Porwit, A., Harris, N., Le Beau, M., Lindberg, E., Tefferi, A., Bloomfield, C. 2009. The 2008 revision of the World Health Organization (WHO) classification of myeloid neoplasms and acute leukemia: rationale and important changes. *Blood*, 114, 937-951.
- Wong, F. 2010. All-*trans*-retinoic acid therapy. *British Journal of Haematology*, 149: 309.



Acute Leukemia - The Scientist's Perspective and Challenge

Edited by Prof. Mariastefania Antica

ISBN 978-953-307-553-2

Hard cover, 428 pages

Publisher InTech

Published online 22, December, 2011

Published in print edition December, 2011

This book provides a comprehensive overview of the basic mechanisms underlying areas of acute leukemia, current advances, and future directions in management of this disease. The first section discusses the classification of acute leukemia, taking into account diagnoses dependent on techniques that are essential, and thankfully readily available, in the laboratory. The second section concerns recent advances in molecular biology, markers, receptors, and signaling molecules responsible for disease progression, diagnostics based on biochips and other molecular genetic analysis. These advances provide clinicians with important understanding and improved decision making towards the most suitable therapy for acute leukemia. Biochemical, structural, and genetic studies may bring a new era of epigenetic based drugs along with additional molecular targets that will form the basis for novel treatment strategies. Later in the book, pediatric acute leukemia is covered, emphasizing that children are not small adults when it comes to drug development. The last section is a collection of chapters about treatment, as chemotherapy-induced toxicity is still a significant clinical concern. The present challenge lies in reducing the frequency and seriousness of adverse effects while maintaining efficacy and avoiding over-treatment of patients.

How to reference

In order to correctly reference this scholarly work, feel free to copy and paste the following:

Abbas H. Abdulsalam (2011). Diagnosis of Acute Leukemia in Under-Resourced Laboratories, *Acute Leukemia - The Scientist's Perspective and Challenge*, Prof. Mariastefania Antica (Ed.), ISBN: 978-953-307-553-2, InTech, Available from: <http://www.intechopen.com/books/acute-leukemia-the-scientist-s-perspective-and-challenge/diagnosis-of-acute-leukemia-in-under-resourced-laboratories>

INTECH
open science | open minds

InTech Europe

University Campus STeP Ri
Slavka Krautzeka 83/A
51000 Rijeka, Croatia
Phone: +385 (51) 770 447
Fax: +385 (51) 686 166
www.intechopen.com

InTech China

Unit 405, Office Block, Hotel Equatorial Shanghai
No.65, Yan An Road (West), Shanghai, 200040, China
中国上海市延安西路65号上海国际贵都大饭店办公楼405单元
Phone: +86-21-62489820
Fax: +86-21-62489821

© 2011 The Author(s). Licensee IntechOpen. This is an open access article distributed under the terms of the [Creative Commons Attribution 3.0 License](#), which permits unrestricted use, distribution, and reproduction in any medium, provided the original work is properly cited.