

Glaucoma in Cases of Penetrating Keratoplasty, Lamellar Procedures and Keratoprosthesis

Shimon Rumelt

*Department of Ophthalmology,
Western Galilee – Nahariya Medical Center, Nahariya,
Israel*

1. Introduction

The two main issues that concern glaucoma patients before and after penetrating keratoplasty and posterior lamellar procedures and patients that develop glaucoma after surgery are the risks of graft failure and the aggravation of the glaucoma. Failure of the corneal graft may require regrafting, which increases the risk of developing or aggravating glaucoma, while uncontrolled glaucoma may result in graft failure and further damage to the optic disc and visual field. These two problems may lead to each other creating a vicious circle. They should be treated by glaucoma and corneal specialists or by someone who is expert with both.

Glaucoma was found in 10-42% of the patients with a single corneal transplantation, 0-27% of them had preoperative glaucoma.¹⁻⁶ Preexisting glaucoma was usually a result of an initial insult such as chemical burn or secondary glaucoma. In repeated corneal transplantation, the incidence of postoperative glaucoma was higher (14-47%) than in primary transplantation.⁷⁻¹² It increases with increased number of regrafts and in aphakia. Corneal graft failure 3 years after keratoplasty occurred in 29-47% when glaucoma was present, compared with 9-30% when it was absent.^{13,14}

Patients requiring penetrating keratoplasty and lamellar procedures (deep lamellar keratoplasty, Descemet's stripping (automated) endothelial keratoplasty, Descemet's membrane endothelial keratoplasty) may suffer from preexisting various types of open and closed angle glaucomas, which may be primary or secondary. Primary open angle and primary closed angle glaucomas may preexist and corneal surgery may be required for unrelated disorders such as Fuchs' corneal dystrophy. Secondary glaucomas may occur due to open and closed globe injuries. In those injuries, the glaucoma may be of open angle and caused by obstruction of the trabecular meshwork by red blood cells (from hyphema), ghost cells (ghost cell glaucoma) or tearing of the meshwork (angle recession). It may also be closed-angle caused by peripheral anterior synechiae. Corneal transplantation may also be required in chemical burns especially alkali. In these cases, the cornea may be opaque because of chronic edema and scarring. Secondary glaucoma may also be associated with corneal abnormalities such as anterior mesenchymal dysgenesis (e.g., Peter's and Axenfeld-Rieger's anomalies). In these disorders, in addition

to corneal opacity due to scarring, the angle may be poorly formed. The common features for all these conditions are persistent corneal edema and scarring due to endothelial decompensation. The decompensation is a result of a combination of damaged or compromised endothelium (whether by trauma or other corneal disorders) and increased intraocular pressure (IOP) that contributes to egress of aqueous humor into the corneal layers. Corneal opacity due to persistent edema and scarring is more common in these conditions than in normal population.

Repeated or even primary corneal transplantation may also result in secondary glaucoma. The attributing factors for secondary glaucoma include 1. Donors button undersizing, which results in corneal graft over-stretching, causing corneal flattening and angle closure. 2. Trauma to the angle by the inadvertent touch by surgical instruments. The damage might be micro or macroscopic. 3. Corticosteroid-induced glaucoma, since topical and sometimes systemic corticosteroids are being frequently use after transplantation to decrease the risk for corneal graft rejection or to treat it. 4. Posterior synechiae that may develop due to postoperative intraocular inflammation especially if the angle is traumatized or becomes shallow. The most common forms of post-keratoplasty glaucoma in single and repeated corneal transplantation are chronic angle closure followed by steroid-induced glaucoma.

2. Assessment of patients requiring penetrating keratoplasty

The preoperative office evaluation of patients requiring penetrating keratoplasty or lamellar procedure whether or not having glaucoma includes defining the primary indication for surgery. Certain indications may require certain precautions or additional treatment to prevent loss of the graft clarity. For example, corneal transplantation for infectious diseases such as herpetic, fungal or acanthamebic keratitis require prolonged postoperative anti-herpetic, fungal or acanthamebic treatment to prevent reactivation. Defining the associated ocular disorders of the recipient and donor is paramount.¹² Corneal vascularization increases the risk of corneal graft rejection especially if involves three or more quadrants and requires prolonged use of corticosteroids as well as immuno-suppressants. Ocular surface disorders such as entropion and trichiasis also increase the likelihood of graft loss due to persistent rubbing of the ocular surface that results in corneal epithelial defects and ulcers that may lead to perforation.¹⁵ Limbal cell deficiency in corneal cicatricial disorders such as ocular cicatricial pemphigoid and erythema multiforme (Steven Johnson disease) provides poor supporting environment to the graft, while dry eyes do both (poor supporting and increased friction upon blinking). Poor blinking and lagophthalmos may also cause dryness of the ocular surface resulting in persistent epithelial defects, ulcers and even perforation. These findings should be pretreated.

Cataract, glaucoma and retinal disorders may be associated with poor visual prognosis despite of clear corneal graft and should be evaluated before any corneal procedure. Defining the associated systemic disorders in recipient and donor are also essential. Diabetes mellitus is also manifested as fragile epithelium and slow epithelial healing, which could endanger the corneal graft.

Before any corneal surgery, best-corrected visual acuity of each eye should be obtained and recorded. This will assist in surgery decision making. Ultrasound is part of the evaluation if the cornea is severely opaque and fundus cannot be evaluated. It is used to rule out retinal detachment and intraocular masses (e.g., choroidal melanoma). When ocular disorders other

than corneal disease exist, such as glaucoma and retinal disorders, they should be evaluated for their contribution to visual acuity. The evaluation includes potential acuity meter (PAM), Lambda and laser interferometry. With these instruments, if the visual acuity is improved, the eye has a potential for visual recovery and a corneal surgery should be attempted. In non-verbal patients as children or in patients with mental retardation, a less accurate method to evaluate the potential for visual recovery is electroretinography (ERG). When anamnesis cannot be obtained, poor prognostic factors for visual improvement are nystagmus, which develops in the first 3 postnatal months, and esotropia that develop in the first 6 postnatal months and indicate severe irreversible amblyopia. Exotropia on the other hand may be acquired at older age and therefore, with poor anamnesis is not a poor prognostic factor for visual recovery.

The preoperative evaluation should include a complete ocular examination including examining the anterior chamber angle, especially following ocular trauma, burns, preexisting glaucoma and candidates for large diameter grafts. If the cornea is opaque, ultrasound biomicroscopy (UBM) is a good alternative for gonioscopy. In presence of shallow anterior chamber, peripheral anterior synechiae or partially closed angle even with normal IOP, placement of anterior chamber IOL is contraindicated in triple procedures, because it may result in the development of secondary glaucoma.

3. Preoperative tips

Consider alternative treatment options for penetrating keratoplasty, especially if glaucoma exists. If the corneal opacity is central and localized (e.g., in Peter's anomaly), optical iridectomy may be a better surgical alternative. Rotational autokeratoplasty is an alternative for eccentric. If the corneal opacity is minimal, surgery may not be warranted. It is always imperative to consider whether the expected visual acuity will be better than the preoperative visual acuity. If not, it is better to avoid surgery.

It is important to perform complicated surgical procedures such as filtration surgery in uncontrolled and controlled glaucoma patients before corneal transplantation or posterior lamellar procedures. The IOP should be controlled at time of the penetrating keratoplasty or posterior lamellar procedures. Otherwise, the graft may become edematous and lost. In patients with glaucoma, any procedure should spare the limbus and conjunctiva as much as possible to allow glaucoma filtration surgery.

4. Surgical steps of penetrating keratoplasty to increase the success rate

Oversized donor corneal button is always required to decrease the risk for development of secondary glaucoma and aggravating a preexisting one. The details for oversizing are described below.

Specular microscopy of the donor button to ensure an endothelial cell count of more than 2,000 mm² without endothelial polymegatism or pleomorphism will at least guarantee that the corneal graft has safety margins and that the risk of endothelial decompensation will be decreased.

Pretreatment of preexisting glaucoma is a crucial step in successful penetrating and posterior lamellar procedures. Therefore, it is important recognizing the type and the etiology of preexisting glaucoma. Surgical pretreatment should be considered even in medically controlled glaucoma, because these patients may become uncontrolled after

surgery and this may endanger the transparency of the corneal graft. Trabeculectomy is the treatment of choice for primary open angle glaucoma. Antimetabolites such as mitomycin-C (MMC) are indicated for all patients under the age of 55 even in primary surgery, for repeated surgery and for combined procedures. Trabeculectomy should be preferred over glaucoma drainage devices in triple procedures and in the presence of corneal graft. MMC should be applied in all cases of secondary glaucomas, triple procedure or in the presence of corneal graft although potential diffusion of the drug may endanger the endothelium. MMC 0.04% is soaked by a small piece of sponge and is placed under the scleral flap before penetrating into the anterior chamber or under the conjunctival flap for 2min avoiding its edges. It should not be placed over corneal button-recipient bed interface. Such a low concentration and short exposure minimize the risks for complications such as poor healing, scleral melting, anterior chamber reaction and increased IOP.

In angle closure glaucoma, laser iridotomy and laser iridoplasty or synechiolysis are warranted. Laser iridotomy may facilitate aqueous flow from the posterior into the anterior chamber and deepen the anterior chamber. Laser iridoplasty causes shrinkage of the peripheral iris and retracts the base of the iris to open the angle, while, synechiolysis has a similar effect by breaking peripheral anterior synechiae and opening the angle. The last two procedures are beneficial if peripheral anterior synechiae have been present for less than 6 months. Peripheral iridectomy may replace laser iridotomy only if iridotomy cannot be performed due to corneal opacity, thick iris or when laser is unavailable. The procedures are described below.

Penetrating keratoplasty should be delayed until the intraocular inflammation subsides and the IOP is stable within the target pressure range. This should be at least 3 months after any intraocular surgery.

5. Prevention of secondary glaucoma

Several precautions should be employed to prevent a secondary glaucoma. As mentioned, preoperative evaluation of the anterior chamber angle is essential especially in patients with preexisting glaucoma. If the angle is already compromised (close, narrow or has peripheral anterior synechiae), the risks of development of glaucoma or aggravation of preexisting one increase. It is important to oversize corneal donor button by 0.5-0.75 mm. In keratoconus or keratoglobus, an over-sizing of 0.25 mm is sufficient to decrease the risk of postoperative angle closure, while preventing too steep postoperative graft. For large graft diameter (8.0-9.5 mm) that is required sometimes for corneal perforations, large descematocele or widespread disease, an over-sizing of 0.75-1.0 mm is advocated. Avoiding manipulations near the angle with surgical instruments is important. The only exception is when synechiolysis is performed. The angle may also be filled with viscoelastic agent to protect it during the procedure, but the viscoelastic material should be aspirated at the conclusion of the surgery to prevent postoperative high IOP. To decrease damage to the trabecular meshwork, preoperative and postoperative intraocular inflammation should be controlled. This may be done by topical corticosteroids with high corneal penetrance such as prednisolone acetate (Pred Forte®). The frequency of drop instillation depends on the degree of inflammation and it is tapered gradually according to the response. Additional systemic corticosteroids may be employed for severe or recurrent sterile uveitis. Usually, 1 gr/kg/day of prednisone is sufficient.

6. Post-keratoplasty glaucoma

If glaucoma develops after corneal surgery, a distinction between immediate postoperative and late postoperative glaucoma should be made. Immediate postoperative glaucoma develops within a week after surgery in 42-55% of the primary keratoplasties. The causes for its development include viscoelastic agent left in the anterior chamber and blocking the drainage of the aqueous humor through the angle and corticosteroid-induced glaucoma. The later develops after the initiation of corticosteroid treatment and occurs at least in 20-30% of the patients. It can occur with any form of corticosteroid although it occurs more often after topical use. The increase in IOP in these cases is usually reversible if diagnosed early and if corticosteroids are discontinued. Therefore, topical and if necessary systemic corticosteroids should be replaced immediately with non-steroidal anti-inflammatory (NSAID) medications. Corticosteroid-induced glaucoma may be avoided by employment of topical NSAID such as ketorolac tromethamine 0.5% (Acular® or Tradol®), diclofenac sodium (Voltaren® (0.1%), Solaraze® (3%)) or indomethacin 1% (Indoptic®). Its incidence is also lowered with IOP sparing corticosteroids such as loteprednol etabonate 0.5% (Lotemax®) or rimexolone 1% (Vexol®) but because of their low potency, they may be more frequently required.

Late postoperative glaucoma may develop weeks or months after surgery. The incidence of this complication is 10-42% after primary keratoplasty. The risk factors for its development include preexisting glaucoma in 27-80% of the cases, aphakia in 20-39%, semi-flexible, closed-loop anterior chamber IOL in 23-50%, regrafting in 43% and wound dehiscence in 50%. Anterior mesenchymal disorders are risk factors for glaucoma in 50-90% of the patients, while open or closed globe injury in 31-77%. Glaucoma may be encountered in up to 47% of the patients with pseudophakic or aphakic bullous keratopathy, and the corneal edema may be a result of it. Certain old types of IOLs have also been associated with late postoperative glaucoma including iris-fixed anterior chamber IOL due to uveitis-glaucoma-hyphema (UGH) syndrome, caused by rubbing of the IOL against the iris. Large corneal grafts and posterior lamellar grafts may also increase the risk for glaucoma development because they may interfere with the angle. The same may occur from the sutures if they are long, tight and full thickness. The causes for late postoperative glaucoma include synechial angle closure, changes in angle ultrastructure, direct mechanical damage to angle by surgical instruments, chronic postoperative inflammation causing toxic effects and presence of vitreous in the angle. Immune graft rejection was found to be more common in patients developing postoperative glaucoma than in those who did not develop it.^{16,17} The glaucoma also increases with the number of corneal transplantation procedures.¹⁷

7. Post-keratoplasty evaluation of preexisting and secondary glaucoma

The evaluation of the anterior chamber is important not only before corneal transplantation and other posterior lamellar procedures but also after surgery, because if there is a progressive closure of the angle or formation of peripheral anterior synechiae, they may be treated before the development of glaucoma or to prevent its worsening. Periodic gonioscopy for development of anterior chamber angle closure is performed with gonioscopic lens when the peripheral cornea is clear. A 4 mirror hand-held lens has the advantages of avoiding viscoelastic material and of short diameter that allow indentation of the cornea. This allows distinguishing between apposition of the iris against the angle

and true closure. It also allows breaking of fresh anterior synechiae if present. Indentation should be performed cautiously immediately after surgery, because it can result in wound dehiscence. Other gonioscopic lenses include the Goldman three and four mirror lenses, which have a broader base (diameter) and cannot indent only the cornea. They also require viscoelastic agent. Newer imaging modalities of the anterior chamber angle include the anterior segment optical coherence tomography (OCT) using 1310nm wavelength, which has a resolution of 10 μ m and Scheimpflug camera (Pentacam®) that has UV-free blue light source of 475nm with a similar resolution. Scheimpflug camera requires a clear cornea and direct visualization of the angle is still a better choice. When the peripheral cornea is opaque, ultrasound biomicroscopy (UBM) is the imaging of choice. It may also assist in evaluation of the ciliary body for congestion as part of uveal effusion syndrome and for aqueous misdirection. Thus, it may elucidate the mechanism of closed angle glaucomas.

Periodic IOP measurements are essential to disclose the development of glaucoma or aggravation of preexisting one. They should be performed in scheduled meetings during different hours of the day to reveal high IOP spikes in patients with high diurnal variations. In cases of doubt, a diurnal IOP curve is indicated and is usually performed every 4 hours between 8:00 and 20:00, but may be performed more frequently (i.e., every 2 hours) and during nighttime as well. IOP measurements should be especially performed when a patient is treated with topical and/or systemic corticosteroids or receives corticosteroid in other forms (e.g., inhalations). If newly IOP elevation is disclosed, recognizing the type of secondary glaucoma is important in treatment decision making (see above). IOP measurements of with Goldmann applanation tonometry may be challenging, because of corneal graft edema, which underestimate the real IOP and corneal graft astigmatism that distorts the image. When measured with Goldmann, the prism may be rotated to aim the red mark on it to the least curved corneal meridian (the negative axis). To overcome the astigmatism, the IOP may be measured twice, one in 90 degrees from the other, and the mean IOP may be calculated from these two measurements. IOP measurements may be performed by pneumatic tonometer, Tono-Pen or Mackay-Marg tonometer if they are impossible to be obtained with Goldmann. Alternatively, the IOP may be qualitatively estimated with a glass rod or by digital palpation. In eyes with corneal scarring, the IOP is overestimated.

When the diagnosis of postoperative or secondary glaucoma is established and the patient is being treated, it is important to avoid discontinuation of the anti-glaucoma medications, unless the patient is closely being followed-up. The course of postoperative glaucoma may be unpredictable and unstable. There might be high long-term fluctuations; i.e. cycles of normal IOP may alternate with increased IOP and the ophthalmologist may mislead to think that the glaucoma has resolved.

Actually, when a diagnosis of secondary glaucoma is made, the patient should always be on anti-glaucoma medications, unless he/ she develops excessive low IOP or intermittent ocular hypotony. In such cases, the anti-glaucoma medications should be discontinued while the patient is followed- up closely. These cases may represent a transition to phthisis bulbi. In cases of ocular hypotony, corticosteroids either topically or systemically may induce some IOP elevation, but if this does not result, pars plana vitrectomy with silicone oil injection into the vitreous might prevent phthisis. Pars plana vitrectomy with silicone oil injection is indicated for chronic ocular hypotony even if the visual acuity is no light perception, because it may prevent phthisis bulbi.

8. Treatment of progressive angle closure

The treatment of postoperative progressive angle closure even with normal IOP includes peripheral laser iridotomy and topical corticosteroids to control anterior chamber inflammation. If the IOP increases, a prompt surgical synechiolysis is warranted.

9. Treatment of secondary glaucoma

Open angle glaucoma is treated in the following order. The first line of treatment is medical with alpha-agonists (brimonidine tartrate) and beta-blockers (timolol maleate, betaxolol). In phakic eyes, prostaglandin analogs (latanoprost) and adrenergic agents (dipivefrin, epinephrine) may be added. In aphakic and pseudophakic eyes, prostaglandin analogs and adrenergic agents may induce cystoid macular edema (CME), which may result in a decrease in visual acuity, and therefore should be avoided. Topical carbonic anhydrase inhibitors (dorzolamide, brinzolamide) may cause graft failure due to toxicity to endothelial cells. Miotics may initiate intraocular inflammation by breaking the blood-aqueous barrier and may increase the likelihood of corneal graft rejection. In aphakic eyes, the risk of retinal detachment also increases. Therefore, these agents should be spared if possible.

The adverse effects of beta-blockers include superficial punctate keratopathy, corneal anesthesia and dry eyes. Alpha-adrenergic agents may also cause superficial punctate keratopathy and dry eyes.

If medical treatment fails, trabeculectomy with MMC (option for two such procedures) should be considered (Figure 1). However, some authors suggested that the prognosis might be poorer than for placement of a glaucoma drainage implant. If a trabeculectomy is performed, a soaked sponge (WekCel) of MMC 0.2-0.4 mg/ml under the scleral flap before penetrating the anterior chamber (or under the conjunctiva avoiding its edge) for 2-3 min should be added. The MMC should not be placed over corneal button-recipient bed interface. Then the area should be copiously irrigated with balanced salt solution or saline. This procedure may be repeated if it failed once. In some cases, the filtration procedure may be functioning well causing a decrease in IOP, but to insufficient level (above the target pressure). In such a case, an additional trabeculectomy rather than anti-glaucoma medications may be successful decreasing further the IOP to the desired level because they may diminish the filtration through the trabeculectomy resulting in its failure for long term. Also, with a successful second trabeculectomy, the patient may not need long-term topical medications, which are a burden. An alternative for MMC is 5-fluorouracil (5FU). Five-mg may be injected subconjunctivally before or at intervals after surgery, but is less potent. Another option is to place 50mg/ml of 5-FU over or under the scleral flap intraoperatively. It inhibits epithelial proliferation, while MMC is better against fibrous proliferation. Both drugs may be injected in conjunction.

The complications of trabeculectomy with MMC in the presence of corneal graft are similar to those without a graft, but in addition, damage to the endothelium may be caused by the MMC, if it penetrates into anterior chamber. The same precautions that apply for placing MMC during surgery for primary open angle glaucoma should be applied here.

If one or two trabeculectomies with MMC have been failed or as a first surgical option, glaucoma shunt tube may be performed. Anterior or posterior drainage devices are available. Anterior drainage devices connect the anterior chamber with the subconjunctival space. Schlemm's canal or suprachoroidal space are easier to implant and require only limited healthy conjunctiva to function. Among the anterior drainage devices are Ex-Press,

Solx Gold shunt and iStent. Posterior drainage devices also drain the anterior chamber through a silastic tube, but the tube is connected to a plate that is placed under the conjunctiva posteriorly. This is the reason that they are called posterior devices. Two types of posterior shunt tubes exist. The first type is with control of the flow (with a “valve” or flow resistance) includes Ahmed (New World Medical, Rancho Cucamonga, CA) and Krupin-Denver (Hood Laboratories, Pembroke, MA) drainage implants. The second type is without pressure control and includes Molteno single or double plate (IOP, Inc., Costa Mesa, CA, USA, and Molteno Ophthalmic Limited, Dunedin, New Zealand), Baerveldt (Advanced Medical Optics, Santa Ana, California, USA), Shocket (self-assembled) and Eagle Vision (Eagle Vision, Inc. Memphis, TN, USA) implants. The later require blocking the aqueous flow for a few days externally by temporary suture or internally by passing a suture through the lumen of the tube or injecting viscoelastic agent. The implantation may also be performed as a two-stage implantation, to decrease the risk for postoperative hypotony. Ahmed and Krupin implants should be preferred over the implants without a valve, because the risk for postoperative overflow and hypotony that may result in endothelial-iris and lens touch is decreased. Ahmed has a convenient plate to implant and suture in variable sizes including for pediatric population.

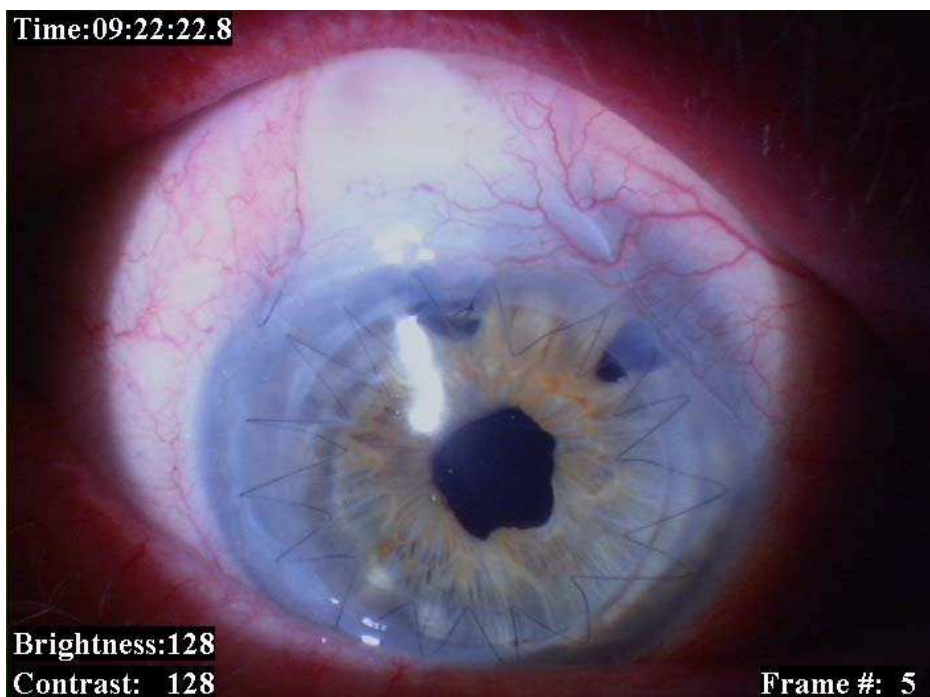


Fig. 1. Trabeculectomy in presence of clear corneal graft in a pseudophakic eye. Note the two patent peripheral iridectomies

The experience with anterior drainage devices is limited to a short follow-up, since they are relatively new. Results with Ex-press are promising.¹⁸ The success rate defined as IOP below 21mmHG in 15 corneal transplanted eyes with closed angle glaucoma was 87% over a mean

follow-up of 12 months, but a longer follow-up is required. The implantation is performed under 5x5mm partial thickness scleral flap similar to limbal-based trabeculectomy and MMC 0.05% is applied for 3min and rinsed after it. No data exist yet concerning the other anterior devices. In cases of corneal transplantation or posterior lamellar procedure, the position of the shunt tube may play a critical role in preservation of clear graft. In phakic eyes, the tube is usually placed through the anterior chamber angle. This results in control of the glaucoma in 68-96%.¹⁹⁻²⁵ However, placement of the tube into the anterior chamber may endanger the transparency of the graft due to tube-endothelial touch or turbulent flow of aqueous through the tip even in the absence of touch. Additional causes include eye rubbing and pressure on the cornea on sleeping. This complication is unique for corneal grafts and for compromised corneas (e.g., in Fuchs' endothelial dystrophy), since it has been demonstrated that progressive endothelial cell loss is observed after placement of glaucoma drainage tube into the anterior chamber angle, and this may occur even in the absence of endothelial-tube touch. Forty-two percent of the eyes with corneal transplants develop corneal decompensation.²³

It is possible to redirect the tube placed into the anterior chamber angle through an existing iridectomy to the posterior chamber in aphakic or pseudophakic eyes as long as the iris would not block it. Another alternative in pseudophakic or aphakic eyes, is to place the tube into the posterior chamber through the ciliary sulcus, by an incision made 1mm posterior to the limbus.²⁶ This procedure is especially advantageous in eyes with corneal transplants or which are candidates for corneal transplantation or posterior lamellar grafts, Fuchs' corneal dystrophy, shallow anterior chamber and extensive synechial angle closure. A meticulous anterior vitrectomy is required if cases of vitreous loss.

For placement of glaucoma shunt tube into the ciliary sulcus, limbal peritomy is performed in the upper temporal (or if not feasible, inferonasal) quadrant and dissection is carried posteriorly over the sclera. The drainage plate is secured to the sclera with 6-0 polyester sutures 8 to 10mm posterior to the limbus between the superior and the horizontal recti muscles. A 2 to 5mm-long scleral tunnel is fashioned with angled crescent knife and the drainage tube is passed beneath it. Alternatively, the tube may be covered with scleral, corneal, pericardial or dural patch adjacent to the external sclerostomy. The tube is passed into the ciliary sulcus through a sclerostomy performed 1mm posterior to the limbus at 11 or 1 o'clock position under a half-thickness, limbal based scleral flap of 3x3mm. The sclerostomy is performed with a myringotomy blade that is inserted with its shaft perpendicular to the limbus and beveled parallel to the iris plane (as performed for scleral-fixated intraocular lens). The position of the tip of the blade is observed through the dilated pupil to confirm its position and avoid ciliary body separation. The edge of the tube is protruding 3mm into the posterior chamber. It should not exceed the dilated pupil margin to avoid glare and should not be too short to avoid blockage by ciliary processes. The fornix-based conjunctival flap is secured to the limbus with 7-0 polygalactin sutures (Figures 2,3). At the conclusion of the surgery betamethasone acetate 3mg and gentamicin sulfate 20mg are injected subconjunctivally 180° away from the implant plate. Topical corticosteroid, antibiotic and cycloplegic are prescribed and tapered gradually. The main potential complications include ciliary body separation and suprachoroidal hemorrhage. These were not observed in a series of patients that underwent this procedure.²⁶⁻²⁸ The corneal grafts remained clear for years of follow-up and the glaucoma was controlled following this procedure. Placement of the shunt tube into the posterior chamber through the ciliary sulcus is contraindicated in phakic eyes because it may endanger the integrity of the crystalline lens.

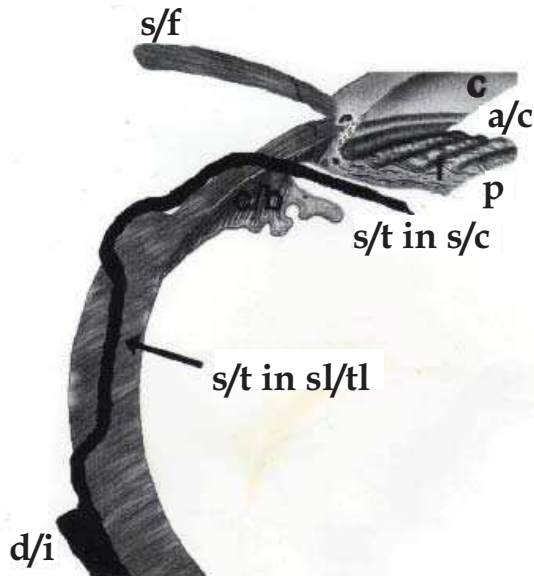


Fig. 2. A diagram showing a side view of placement of a glaucoma drainage device in the ciliary sulcus. c - cornea, a/c - anterior chamber, I - iris, p - pupil, s/f - scleral flap, c/b - ciliary body, s/t in c/s - shunt tube in the ciliary sulcus, s/t in sl/tl - shunt tube in scleral tunnel, d/i - implant disc

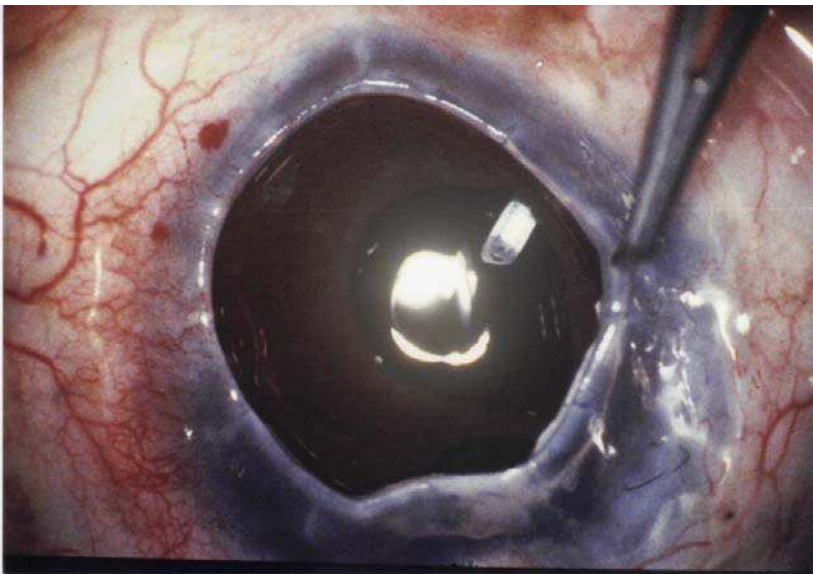


Fig. 3. The tip of ciliary sulcus glaucoma shunt tube behind the iris during surgery before placing a corneal graft

In cases of posterior segment disorders, when pars plana vitrectomy is required, the tube may be placed into the vitreous cavity through it.^{30,31} A meticulous vitrectomy is a prerequisite so vitreous strands will not block the tube. The common feature for placement of the shunt tube into the posterior chamber through the ciliary sulcus or into the vitreous cavity through the pars plana is placing the tip of the tube away from the corneal graft, which decreases the risk of endothelial cell loss and corneal graft decompensation.

For pars plana placement of glaucoma drainage device, a limbal peritomy is performed and the lateral and superior rectus muscles are engaged by 4-0 silk traction sutures. The sclera is exposed further back by elevating the conjunctiva and Tenon's capsule with blunt dissection. The plate is secured to the superotemporal sclera with 6-0 polyester sutures. Then a three-port pars plana vitrectomy is performed through sclerostomies 3.5mm from the limbus. The tube is introduced 5mm into the vitreous through the superotemporal sclerostomy. A sclera, corneal, dural or pericardial patch may be used to cover the tube and the conjunctival-Tenon flap is sutured to the limbus with 7-0 polygalactin sutures. A Pars Plana Clip (Model PC, New World M, Inc., Rancho Cucamonga, CA, USA), which can be used with any drainage device, or Hoffman elbow, which is mounted on a Baerveldt 350-mm² implant (Advanced Medical Optics, Inc., Santa Ana, CA, USA) may be used. New pars plana Ahmed and Baerveldt implants are also available and the procedure may be performed using even the regular glaucoma setones, preferably those with a "valve". Fluid-gas exchange provides a temporary tamponade and prevents postoperative hypotony. Pars plana vitrectomy and placement of glaucoma shunt device may be performed endoscopically in eyes with media opacity such as corneal opacity.³² This procedure allows controlling the glaucoma first and then performing corneal surgery later to improve visual acuity. Possible unique complications for this procedure include vitreous hemorrhage, retinal detachment and choroidal detachment. Although corneal graft failure is reduced if the glaucoma drainage device is placed through the ciliary sulcus or pars plana and if the glaucoma is controlled, it should be remembered that there are other causes that may result in graft failure.

In posterior lamellar grafts, if a glaucoma shunt tube is introduced into the anterior chamber, the graft may block the tip of the tube resulting in increased IOP. It can be avoided by trimming the tip of the tube, so it will not be blocked. It is also possible to pre-plane the corneal surgery and to prepare a thin lamellar graft or perform a DMEK rather than DSAEK (Figures 4,5).²⁹ Tube-endothelial touch without blockage may also occur and is manifested as corneal edema. It may increase the risk for corneal graft rejection. If tube-endothelial touch or tube blockage is suspected, the diagnosis may be confirmed by direct visualization with slit lamp biomicroscopy or indirectly with UBM, Scheimpflug camera (Pentacam) or anterior segment OCT. When tube-endothelial touch or tube blockage is confirmed, the tube should be trimmed. The trimming should be performed so that the opening of the tip would not face the corneal graft, because turbulence at the tip may cause progressive loss of endothelial cells and corneal decompensation that will require a new transplant. The opening should not face the iris as well because it may be blocked. The tip may also be redirected if long and mobile enough. This can be done by retrieving the tube from the anterior chamber, creating a new passage into the chamber and suturing the old route. Just moving the tube in the existing route is usually unhelpful. If the graft is edematous at the time of managing the tube, regrafting may be performed later when the IOP is stable and the eye is quiet, if the edema has not been resolved.

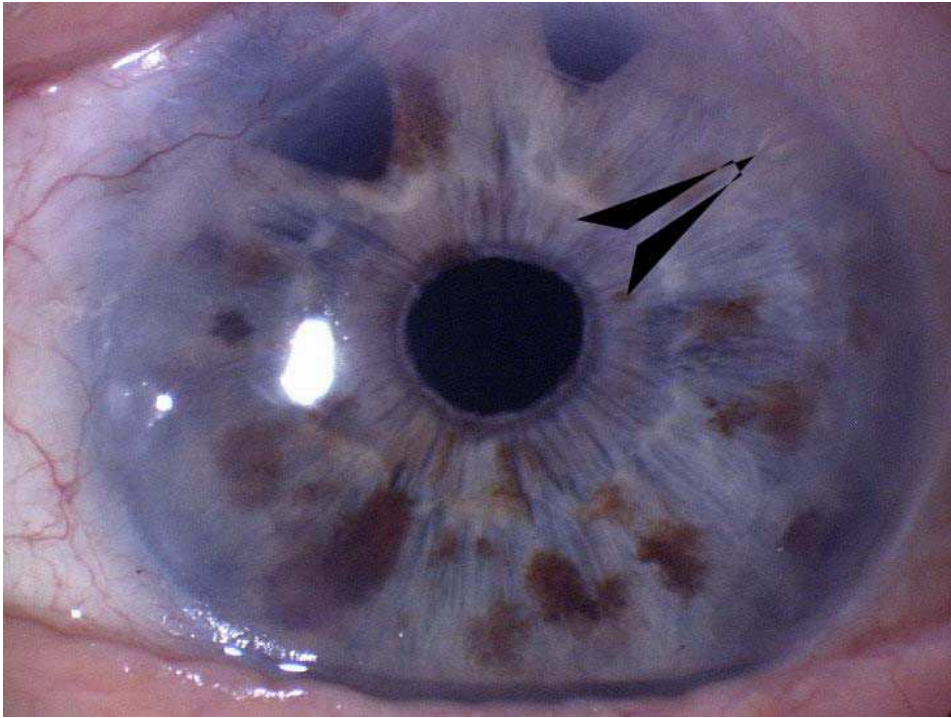


Fig. 4. Glaucoma shunt tube (arrow) in an eye after Descemet's membrane - endothelial keratoplasty (DMEK). Note the clear lamellar graft

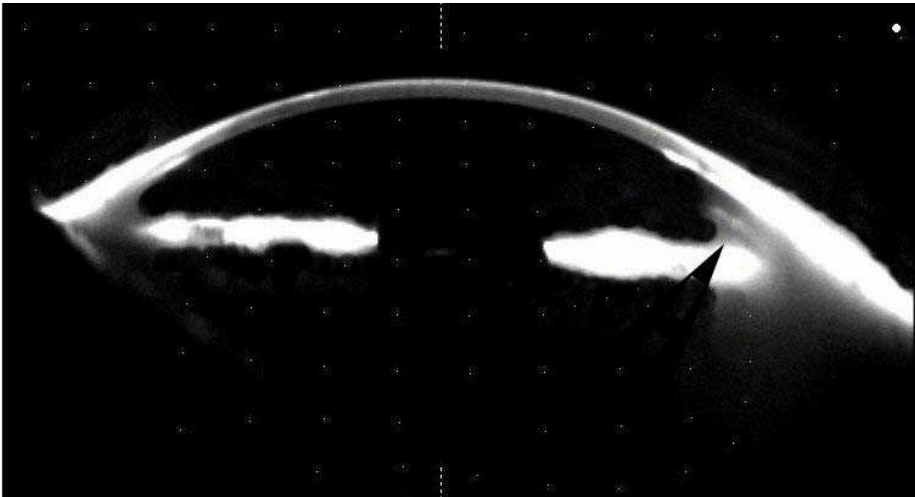


Fig. 5. Pentacam image of the same eye as in figure 4 showing the position of the tube in the anterior chamber (arrow)

Laser procedures for the angle such as selective trabeculoplasty have a limited value in the long-term treatment of secondary open angle glaucomas and therefore, were not included in the sequence of treatment. The main reason is their limited effect in this type of glaucoma. Even in primary open angle glaucoma, where it is more effective, the success rate is only 50% 5 years after the procedure.

10. Closed angle glaucoma

Closed angle glaucoma should be confirmed by gonioscopy or UBM or with other imaging techniques (anterior segment OCT or Scheimpflug camera). The first treatment modality, which is usually simplest, if the cornea is clear, is peripheral laser iridotomy. This is usually performed with Neodymium: Yttrium-Aluminum-Garnet (Nd:YAG) laser. After instillation of topical pilocarpine 2% or 4% and topical analgesic (e.g., oxybuprocaine HCl 0.4% or proparacaine HCl 0.5%) eye drop, a spot of 10mJ is placed over the peripheral iris. Two pulses may be used simultaneously. The size of the spot is constant depending on the instrument (50-70 μ m). The spot is placed at the periphery of the iris in the superior half to avoid glare and over a thin part of the iris (usually a crypt) avoiding blood vessels. If bleeding occurs, the cornea is pressed by a contact lens until bleeding ceases. The procedure may be performed with contact lens such as Abraham (+66D), Wise (+103D), CGI or without it. The advantages of a contact lens are additional magnification, focusing the beam, absorbing part of the heat, stabilizing the eye and maintaining the eyelids open. Topical glycerin may be placed over the cornea before the procedure if it is edematous. Topical apraclonidine (Iopidine®) 0.5%-1.0% or other alpha 2 agonist (e.g., brimonidine tartrate) is administered following the procedure to decrease IOP spikes and corticosteroids such as prednisolone acetate 1% qid are prescribed of a week to decrease intraocular inflammation and risk for synechiae formation. Additional anti-glaucoma medications may be added. This procedure facilitates aqueous flow from the posterior into the anterior chamber and may result in deepening of the anterior chamber and lowering the IOP. The major complication is acceleration of cataract. If Nd:YAG laser is unavailable, Argon laser iridotomy may be performed. The parameters for this procedure depend on the iris pigmentation. For brighter iris, the power is lower than for darker ones. The preparatory stretch burns are of 200-600mW, 0.2-0.6 sec, 200-500 μ m. The penetration burns are of 800-1000mW, 0.2 sec, 50 μ m. The iridotomy size should be increased to 150-500 μ m. The position of the Argon iridotomy in this case is preferably supero-nasal to prevent injury to the macula. The treatment before and after the procedure is identical to Nd:YAG laser iridotomy. Perforation of the iris is obtained when aqueous mixed with pigment is flowing from the posterior to the anterior chamber through the iridotomy. The lens should be visible through the iridotomy, since positive transillumination is not reliable. When laser iridotomy is not feasible, surgical peripheral iridectomy should be performed. Complications include visual disturbances such as halo and glare, development and progression of cataract, corneal burns that are usually transient, temporary increase in IOP, intraocular inflammation and rarely retinal injury, CME and malignant glaucoma.

If laser iridotomy does not result in decrease in IOP, surgical peripheral goniosynechiolysis or laser peripheral iridoplasty may be performed. This should be performed as early as possible and preferably if the angle closure is of less than 6 months. Otherwise, it is usually useless, because of scarring. Peripheral goniosynechiolysis is performed through a paracentesis. It may be performed under viscoelastic material or with anterior chamber maintainer. A spatula is transferred along the peripheral iris to withdraw it from the angle.

Goniosynechiolysis may be performed in a similar way with viscoelastic agent injected toward the angle to open it. However, the viscoelastic material should be removed at the conclusion of the procedure to prevent postoperative high IOP. Laser iridoplasty is performed after instillation of topical anesthetic eye drop with Argon laser, 200-400mW, 0.3-0.6 sec, 500 μm , 20-40 burns in a row with 2-beam diameter space between each spot over 360° peripheral iris avoiding blood vessels. The procedure is performed with a contact lens such as the Abraham (+66D), Wise (+103D), CGI or Goldmann three-mirror lens (through the center, non-mirror part) or without it. The preparations before and the management following the procedure are similar to this described above for Nd:YAG laser iridotomy. The procedure is aimed to contract the peripheral iris away from the angle. The contraindications for the procedure include extensive synechial closure and flat anterior chamber. The complications of the procedure include corneal burns, increased IOP, iritis, new synechiae formation and mydriasis.

If the IOP did not decrease substantially to the target level following these two procedures, medical treatment with anti-glaucoma medications including pilocarpine 2% four times a day may be added. If pilocarpine is added, it is worthwhile to have two consecutive days off this medication every month. This decreases the probability to have fixed small pupil, which may be an obstacle if cataract extraction is required.

If the IOP remained high or becoming high despite of medical treatment, other surgical procedures may be performed. The usual approach is to have trabeculectomy first. Trabeculectomy in this case may require a long tunnel (or sclerostomy) that will penetrate the peripheral cornea anterior to the peripheral anterior synechiae.

When a trabeculectomy is failed, a glaucoma shunt tube may be placed as mentioned earlier. In aphakic and pseudophakic eyes it may be placed into the ciliary sulcus.

11. Steroid-induced glaucoma

Steroid-induced glaucoma is defined as elevation of IOP following administration of topical and/or systemic corticosteroids that remains high after their discontinuation. Steroid responder is a patient in whom the IOP returns to normal after discontinuation of the steroids. These medications are often used after corneal transplantation to prevent or treat corneal graft rejection. They are also used to treat postoperative intraocular inflammation. Differentiation between steroid-induced glaucoma and inflammatory (uveitic) glaucoma may be performed by increasing the topical corticosteroid dosage for several days. If IOP remains high despite decreased intraocular inflammation, a corticosteroid-induced glaucoma is most reasonable.

In cases of steroid responders or steroid-induced glaucoma, discontinuation of the corticosteroids is mandatory. Patients, who are steroid responders, should be aware that they are "allergic" to steroid in the specific form that causes their IOP to increase. This should be written in their medical chart and added to a note (or a card) for the patient, specify that he should not receive this type of drug. For episodes of graft immune rejection, a combination of topical NSAID (sodium diclofenac 0.1% or ketorolac tromethamine 0.5%) and topical cyclosporine-A may be employed. Systemic cyclosporine-A or other drugs such as PO tacrolimus 0.1mg/kg/day may be added. Another option is to use IOP-sparing corticosteroids such as loteprednol etabonate 0.5% (Lotemax®) or rimexolone 1% (Vexol®). Judicious use of systemic corticosteroids instead of topical corticosteroids may be adopted if they do not cause an increase in IOP.

The treatment of steroid-induced glaucoma follows the same principles applied for primary open-angle glaucoma (see above).

12. Glaucoma in patients with corneal and posterior segment disorders

Glaucoma in cases of posterior segment disorders (e.g. proliferative diabetic retinopathy, neovascular glaucoma, uveitic glaucoma) along with corneal disorders are more challenging to treat. Pars plana vitrectomy may require a temporary keratoprosthesis for visualization of the posterior segment. Following which, a corneal transplantation is being performed. Otherwise, pars plana vitrectomy may be performed endoscopically. In both instances, if the glaucoma is refractory to medical treatment, a pars plana implantation of glaucoma drainage implant is advised.

Cyclodestructive procedures should be avoided if possible, because the degree of IOP reduction and intraocular inflammation are unpredictable. Excessive intraocular inflammation may cause intense pain, CME and hypotony that may result in phthisis bulbi. External inflammation may cause excessive scarring of the conjunctiva, preventing other procedures such as trabeculectomy to be performed. The corneal graft may also fail. Cyclodestructive procedures should be reserved only for painful eyes with no potential for visual rehabilitation. If cyclodestructive procedures are employed, transscleral cyclophotocoagulation (contact or non-contact, Nd:YAG or diode laser) or transcorneal ciliary processes photocoagulation should be preferred over cyclocryoablation. The former causes less postoperative pain, postoperative inflammatory reaction and phthisis bulbi than cyclocryoablation. Even when transscleral cyclophotocoagulation (contact or non-contact, Nd:YAG or diode laser) or transcorneal ciliary processes photocoagulation is being performed, it may be applied to half to two thirds of the ciliary body to prevent these complications. This book contains a chapter on controlled cyclophotocoagulation to decrease complications.

For cyclodestructive procedures, sub-Tenon, peribulbar or retrobulbar anesthesia with 2% lidocaine (or a 1:1 mixture with 0.75% bupivacaine) is used. Transscleral Nd:YAG (1064nm) may be contact or non-contact, continuous or pulsed. Eight to 25 applications of 1.5-10J are placed 2-3mm beyond the limbus over 180°. This position corresponds to the location of the ciliary body and is confirmed by transillumination. Trans scleral Diode (810nm), 10-20 applications of 5-6mJ over 180-270° is performed 2mm posterior to the limbus. Following the procedure, topical corticosteroids such as prednisolone acetate 1% qid or more and atropine sulfate 1% tid for a few weeks are warranted. Analgesia may also be required. The anti-glaucoma medications are tapered gradually according to the decrease in IOP. The success of the procedure is usually assessed 4 weeks after treatment. The complications include hyphema, corneal decompensation, chronic intraocular inflammation, CME, epiretinal membranes, chronic hypotony and even phthisis bulbi. They may be fewer with Diode laser with G-probe.³³

13. Prognosis

The prognosis of preexisting glaucoma depends on its type.¹⁷ It is usually more favorable for primary open angle glaucoma as long as precautions have been taken during the penetrating keratoplasty or the lamellar grafting. The prognosis for graft survival is also

better than with other types of preexisting glaucoma, as long as the IOP is well controlled and the corneal graft has a healthy endothelium.

The prognosis for secondary open angle glaucoma is similar. If the IOP is poorly controlled, there are increased risks for corneal decompensation and development of bullous keratopathy that may require additional grafting. However, performing corneal transplantation in an eye with uncontrolled glaucoma is inadvisable. Resolution of post-keratoplasty glaucoma has been observed in chronic angle closure glaucoma after an additional corneal transplantation probably due to changes in the angle configuration by applying the above advises. In steroid responders, the IOP returns to normal following discontinuation of the corticosteroids.

With the approaches described in this chapter, it would be possible to improve the outcomes of patients with corneal transplants and coexisting glaucoma.

13.1 Follow-up

Patients undergoing corneal surgery and having or developing glaucoma usually have concurrent disorders and are more challenging to treat. These patients should be followed-up regularly at least every 3 months for their lifetime. If they experience ocular pain, decrease in vision or redness of the eye, they should immediately report to their ophthalmologist. It is essential not to postpone the next step in treatment if the current one is not sufficient to abolish the risk of further deterioration.

14. Controversies in management of glaucoma in patients with corneal grafts

Whether trabeculectomy with MMC or glaucoma drainage implant is the surgical treatment of choice for glaucoma in patients with corneal grafts is still controversial. Different authors have reported comparable results with both. At present, it is up to the decision of the surgeon according to his experience. Comparative studies are required for a definite answer. Such studies will be required also to decide whether simultaneous procedures have the same success rate as separate procedures and whether the new anterior glaucoma devices such as Solx gold shunt or iStent, will have a benefit over the posterior ones.

15. Glaucoma in cases of permanent keratoprosthesis

Several types of keratoprosthesis are available including one that pass through the cornea and fused eyelids (type II) and the more common ones through the cornea only (type I, e.g., Boston and osteo-odonto-keratoprosthesis) (Figures 6,7). Keratoprosthesis is usually reserved for eyes in which other corneal procedures have failed and the prognosis for additional ones is poor. A publication on repeated corneal transplantation demonstrated that as the number of repeated corneal grafts is increased, the prognosis for long-term survival of the regrant decreases.¹² Most of the regrants do fail due to graft rejection, glaucoma and other complications. These findings have led keratoprosthesis specialists to advocate keratoprosthesis. However, the publication was intended to elaborate the importance of proper preventive measures and early and correct treatment of corneal transplantation complications of rather than to advocate the use of keratoprosthesis. With better preventive measures and treatments, it will be possible to decrease the necessity for repeated transplantation and of course to avoid keratoprosthesis.

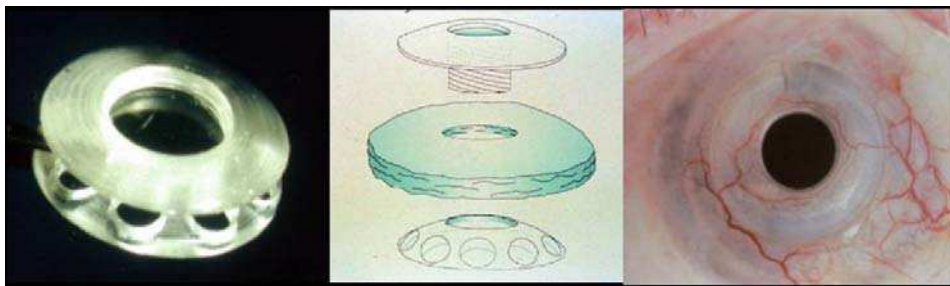


Fig. 6. Type I keratoprosthesis (courtesy of Peter Rubin, MD)

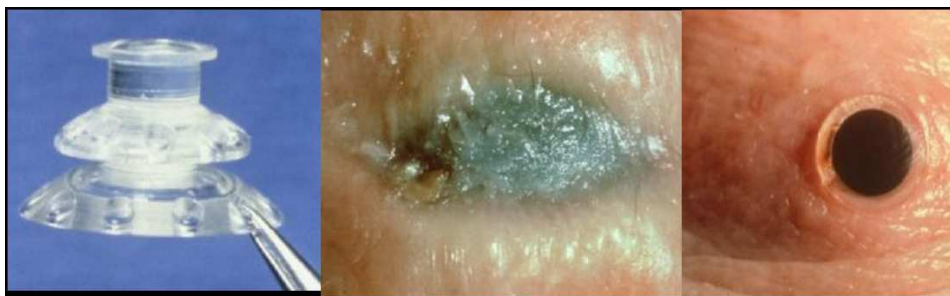

Fig. 7. Type II keratoprosthesis (courtesy of Peter Rubin, MD)

Many of the patients undergoing keratoprosthesis have multiple ocular pathologies and glaucoma is one of them. Between 36-76% of the eyes with keratoprosthesis have glaucoma.³⁴⁻³⁹ Of these, about 2-28% develop glaucoma after the implantation of keratoprosthesis, usually because of progressive angle closure. This may be caused because of inadvertent injury to the angle and postoperative intraocular inflammation. A peripheral iridectomy may decrease the risk of postoperative angle closure. The prosthesis may also serve as a scaffold for retoprosthetic membrane that may cover the angle. The use of corticosteroids for prolonged period may also cause corticosteroid-induced glaucoma in susceptible patients.

Glaucoma is more frequent in keratoprosthetic patients than in repeated corneal transplantation. One of the most challenging situations in the presence of keratoprosthesis is to detect and follow-up glaucoma, because it is impossible to check the IOP using the standard methods such as Goldmann applanation tonometry or Schiøtz indentation tonometry. These instruments are employed through normal cornea and not through a keratoprosthesis, which cannot be indented. In many cases, visualization of the optic disc may be difficult and therefore, changes in cupping are difficult to observe or document directly, or indirectly using Heidelberg Retinal Tomography (HRT), scanning laser polarimeter (GDx) or OCT. Reliable visual fields may also be difficult to obtain and the maximal field that may be obtained is 60° with type I and 40° with type II.

It is paramount to obtain the history of glaucoma in patients with keratoprosthesis and to document it. In presence of keratoprosthesis, IOP qualitative estimation may be performed by digital palpation over the sclera. It should not be performed over the keratoprosthesis or the glaucoma shunt plate. Qualitative estimation with glass rod over the conjunctiva is

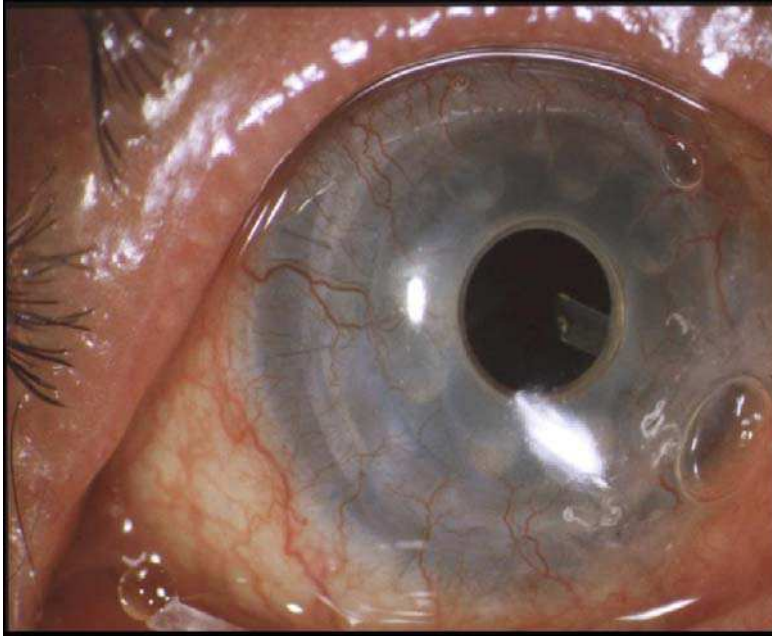


Fig. 8. The tip of Ahmed shunt tube seen through type I keratoprosthesis. It was placed into the vitreous through the pars plana (courtesy of Peter Rubin, MD)

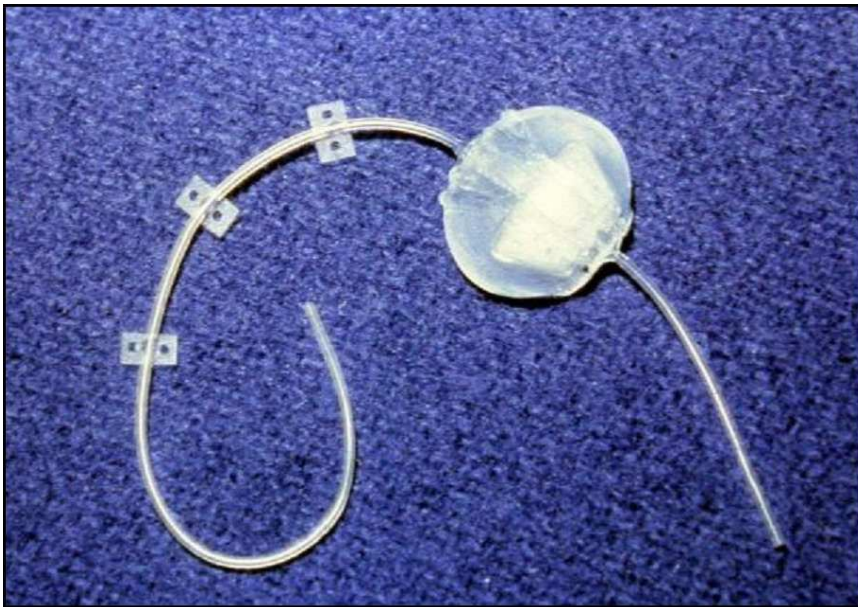

Fig. 9. A modified Ahmed closed shunt (courtesy of Peter Rubin, MD)

more challenging as quantitative estimation of the IOP by Tonopen or Schiotz indentation tonometry through the limbal area. If the IOP cannot be estimated in follow-up visits, it is also possible to follow patients by observing the optic disc and visual fields for deterioration as is done with some patients without keratoprosthesis who do not allow checking their IOP. New transducers are being developed to allow IOP measurements in patients with keratoprosthesis.

In patients who are candidate for keratoprosthesis, it is preferable to implant glaucoma drainage device and to wait for 3-6 months before placing the keratoprosthesis especially when the IOP is refractory to medical treatment or the damage to the optic disc is advanced. This period would allow the postoperative intraocular inflammation to subside and to the IOP to stabilize.

The response to medical treatment in patients with keratoprosthesis is limited because there is no absorption area in patients with type II and limited absorption area with type I keratoprosthesis and the glaucoma is usually more severe compared with glaucoma in penetrating keratoplasty. The next step is introducing a glaucoma drainage device (Figure 8). A placement of glaucoma shunt tube into the vitreous through the pars plana may be better than into the anterior chamber that is already crowded because of the backplate of the prosthesis. In aphakic eyes, it is mandatory to ascertain that no vitreous remains in the anterior chamber, by meticulous anterior vitrectomy. Since the patients are either aphakic or pseudophakic, the tube may be inserted through the ciliary sulcus. Recently, it was suggested to place the valved drainage tube such as Ahmed valve in the lacrimal sac, ethmoid or maxillary sinuses and to avoid the subconjunctival plate.^{38,39} The shunt tube was modified for this purpose (Figure 9) and was placed into the lacrimal sac or the ethmoid sinus through an external dacryocystorhinostomy incision although it may be placed in a similar manner as a Pyrex tube in conjunctivo-dacryo-cystorhinostomy. Placement into the maxillary sinus was performed through a lower eyelid crease or subciliary incision but it is also possible to go through the inferior fornix. Penetration may be performed with intravenous catheter and the tube may be passed through it after removing the catheter hub. These procedures may decrease the failure of glaucoma shunt tube from fibrosis around the subconjunctival plate. The main risk in these cases is endophthalmitis. Therefore, I would not advocate these procedures if the lacrimal sac or the sinus is not sterile. Therefore, such a procedure should be avoided in patients with active sinusitis or history of this disorder. In one series of 37 patients, one (3%) developed endophthalmitis.³⁸ Cyclophotocoagulation may be employed as an adjunct treatment to glaucoma drainage implants for painful eyes with no potential for visual rehabilitation.^{42,43}


16. References

- [1] Thoft RA, Gardon JM, Dohlman CH. Glaucoma following penetrating keratoplasty. *Trans Am Acad Ophthalmol Otolaryngol* 1974;78:352-64.
- [2] Polack FM. Keratoplasty in aphakic eyes with corneal edema: results in 100 cases with 10-year follow-up. *Ophthalmic Surg* 1980;11:701-7.
- [3] Goldberg DB, Schanzlin DJ, Brown SI. Incidence of increased intraocular pressure after keratoplasty. *Am J Ophthalmol* 1981;92:372-7.
- [4] Foulks GN. Glaucoma associated with penetrating keratoplasty. *Ophthalmology* 1987;94:871-4.

- [5] Polack FM. Glaucoma in keratoplasty. *Cornea* 1988;7:67-9.
- [6] Simmons RB, Stern RA, Teekhasaene C, Kenyon KR. Elevated intraocular pressure following penetrating keratoplasty. *Trans Am Ophthalmol Soc* 1989;87:79-91.
- [7] Cowden J, Kaufman HE, Polack FM. The prognosis of keratoplasty after previous graft failures. *Am J Ophthalmol* 1974;78:523-5.
- [8] Robinson CH. Indications, complications and prognosis for repeated penetrating keratoplasty. *Ophthalmic Surg* 1979;10:27-34.
- [9] Insler MS, Pechous B. Visual results in repeat penetrating keratoplasty. *Am J Ophthalmol* 1986;102:371-5.
- [10] MacEwen CJ, Khan ZUH, Anderson E, MacEwen CG. Corneal re-graft: indications and outcome. *Ophthalmic Surg* 1988;19:706-12.
- [11] Rapuano CJ, Cohen EJ, Brady SE et al. Indications and outcomes of repeat penetrating keratoplasty. *Am J Ophthalmol* 1990;109:689-95.
- [12] Bersudsky V, Blum-Hareuveni T, Rehany U, Rumelt S. The profile of repeated corneal transplantation. *Ophthalmology* 2001;108:461-9.
- [13] Sugar A. An analysis of corneal endothelial and graft survival in pseudophakic bullous keratopathy. *Trans Am Ophthalmol Soc* 1989;87:762-801.
- [14] Byrd S, Tayeri T. Glaucoma associated with penetrating keratoplasty. *Clin Ophthalmol* 1999;39:17-28.
- [15] Rumelt S, Blum-Hareuveni T, Bersudsky V, Rehany U. Persistent epithelial defects and ulcers in repeated corneal transplantation: incidence, causative agents, predisposing factors and treatment outcomes. *Eye*, 2008;246:1139-1145.
- [16] Aldave AJ, Rudd JC, Cohen EJ et al. The role of glaucoma therapy in the need for repeat penetrating keratoplasty. *Cornea* 2000, 19:772-6.
- [17] Rumelt S, Bersudsky V, Blum-Hareuveni T, Rehany U. Preexisting and postoperative glaucoma in repeated corneal transplantation. *Cornea*, 2002;21:759-765.
- [18] Kirkness CM. Penetrating keratoplasty, glaucoma, and silicone drainage tubing. *Dev Ophthalmol* 1987;14:161-5.
- [19] Ates H, Palamar M, Yagci A, Egrilmez S. Evaluation of mini Ex-Press glaucoma shunt implantation in refractory penetrating glaucoma. *J Glaucoma* 2010;19:556-60.
- [20] McDonnell PJ, Robin JB, Schanzlin DJ et al. Molteno implant for control of glaucoma in eyes after penetrating keratoplasty. *Ophthalmology* 1988;95:364-9.
- [21] Kirkness CM, Ling Y, Rice NSC. The use of silicone drainage tubing to control postkeratoplasty glaucoma. *Eye* 1988;2:583-90.
- [22] Beebe WE, Starita RJ, Fellman RL, Lynn JR, Gelender H. The use of Molteno implant and anterior chamber tube shunt to encyclus band (ACTSEB) for treatment of glaucoma in penetrating keratoplasty. *Ophthalmology* 1990;97:1414-22.
- [23] Sherwood MB, Smith MF, Driebe WT Jr et al. Drainage tube implants in the treatment of glaucoma following penetrating keratoplasty. *Ophthalmic Surg* 1993;24:185-9.
- [24] Rapuano CJ, Schmidt CM, Cohen EJ, et al. Results of alloplastic tube shunt procedures before, during, or after penetrating keratoplasty. *Cornea* 1995;14:26-32.
- [25] Coleman AL, Mondino BJ, Wilson MR, Casey R. Clinical experience with the Ahmed glaucoma valve implant in eyes with prior or concurrent penetrating keratoplasties. *Am J Ophthalmol* 1997;123:54-61.

- [26] Rumelt S, Rehany U. Implantation of glaucoma drainage implant tube into the ciliary sulcus in patients with corneal transplants. *Arch Ophthalmol* 1998;116:685-7.
- [27] Tello C, Espana EM, Mora R, et al. Baerveldt glaucoma implant insertion in the posterior chamber sulcus. *Br J Ophthalmol* 2007;91:739-42.
- [28] Weiner A, Cohn AD, Balasubramaniam M, Weiner AJ. Glaucoma tube shunt implantation through the ciliary sulcus in pseudophakic eyes with high risk of corneal decompensation. *J Glaucoma* 2010;19:405-11.
- [29] Bersudsky V, Treviño A, Rumelt S. Management of endothelial decompensation because of glaucoma shunt tube touch by Descemet membrane endothelial keratoplasty and tube revision. *Cornea* 2011;30:709-11.
- [30] Gandham SB, Costa VP, Katz LJ, Wilson RP, SA, Belmont J, Smith M. Aqueous tube-shunt implantation and pars plana vitrectomy in eyes with refractory glaucoma. *Am J Ophthalmol* 1993;116:189-95.
- [31] Ritterband DC, Shapiro D, Trubnik V, et al. Cornea Glaucoma Implant Study Group (COGIS). Penetrating keratoplasty with pars plana glaucoma drainage devices. *Cornea* 2007;26:1060-6.
- [32] Tarantola RM, Agarwal A, Lu P, Joos KM. Long-term results of combined endoscope-assisted pars plana vitrectomy and glaucoma tube shunt surgery. *Retina* 2011; 31:275-83.
- [33] Fishbaugh G. Overview and new technology in cyclodestructive procedures. *Insight* 1999;19:26-9.
- [34] Netland PA, Terada H, Dohlman CH. Glaucoma associated with keratoprosthesis. *Ophthalmology* 1998;105:751-7.
- [35] Zerbe BL, Belin MW, Ciolino JB. Boston Type 1 Keratoprosthesis Study Group. Results from the multicenter Boston Type 1 Keratoprosthesis Study. *Ophthalmology* 2006; 113:1779.
- [36] Aldave AJ, Kamal KM, Vo RC, Yu F. The Boston type I keratoprosthesis: improving outcomes and expanding indications. *Ophthalmology* 2009;116:640-51.
- [37] Bradley JC, Hernandez EG, Schwab IR, Mannis MJ. Boston type 1 keratoprosthesis: the university of California Davis experience. *Cornea* 2009;28:321-7.
- [38] Chew HF, Ayres BD, Hammersmith KM, et al. Boston keratoprosthesis outcomes and complications. *Cornea* 2009;28:989-96.
- [39] Rivier D, Paula JS, Kim E, Dohlman CH, Grosskreutz CL. Glaucoma and keratoprosthesis surgery: role of adjunctive cyclophotocoagulation. *J Glaucoma* 2009;18:321-4.
- [40] Rubin PA, Chang E, Bernardino CR, Hatton MP, Dohlman CH. Oculoplastic technique of connecting a glaucoma valve shunt to extraorbital locations in cases of severe glaucoma. *Ophthalm Plast Reconstr Surg* 2004;20:362-7.
- [41] Dohlman CH, Grosskreutz CL, Chen TC, et al. Shunts to divert aqueous humor to distant epithelialized cavities after keratoprosthesis surgery. *J Glaucoma* 2010; 19:111-5.
- [42] Rivier D, Paula JS, Kim E, Dohlman CH, Grosskreutz CL. Glaucoma and keratoprosthesis surgery: role of adjunctive cyclophotocoagulation. *J Glaucoma* 2009;18:321-4.

- [43] Parthasarathy A, Aung T, Oen FT, Tan DT. Endoscopic cyclophotocoagulation for the management of advanced glaucoma after osteo-odonto-keratoprosthesis surgery. *Clin Experiment Ophthalmol* 2008;36:93-4.



Glaucoma - Basic and Clinical Concepts

Edited by Dr Shimon Rumelt

ISBN 978-953-307-591-4

Hard cover, 590 pages

Publisher InTech

Published online 11, November, 2011

Published in print edition November, 2011

This book addresses the basic and clinical science of glaucomas, a group of diseases that affect the optic nerve and visual fields and is usually accompanied by increased intraocular pressure. The book incorporates the latest development as well as future perspectives in glaucoma, since it has expedited publication. It is aimed for specialists in glaucoma, researchers, general ophthalmologists and trainees to increase knowledge and encourage further progress in understanding and managing these complicated diseases.

How to reference

In order to correctly reference this scholarly work, feel free to copy and paste the following:

Shimon Rumelt (2011). Glaucoma in Cases of Penetrating Keratoplasty, Lamellar Procedures and Keratoprosthesis, Glaucoma - Basic and Clinical Concepts, Dr Shimon Rumelt (Ed.), ISBN: 978-953-307-591-4, InTech, Available from: <http://www.intechopen.com/books/glaucoma-basic-and-clinical-concepts/glaucoma-in-cases-of-penetrating-keratoplasty-lamellar-procedures-and-keratoprosthesis>

INTECH

open science | open minds

InTech Europe

University Campus STeP Ri
Slavka Krautzeka 83/A
51000 Rijeka, Croatia
Phone: +385 (51) 770 447
Fax: +385 (51) 686 166
www.intechopen.com

InTech China

Unit 405, Office Block, Hotel Equatorial Shanghai
No.65, Yan An Road (West), Shanghai, 200040, China
中国上海市延安西路65号上海国际贵都大饭店办公楼405单元
Phone: +86-21-62489820
Fax: +86-21-62489821

© 2011 The Author(s). Licensee IntechOpen. This is an open access article distributed under the terms of the [Creative Commons Attribution 3.0 License](#), which permits unrestricted use, distribution, and reproduction in any medium, provided the original work is properly cited.