

# Psychiatric Manifestations of Neurosyphilis

Fabian Friedrich and Martin Aigner  
*Department of Psychiatry and Psychotherapy,  
Division of Social Psychiatry,  
Medical University of Vienna  
Austria*

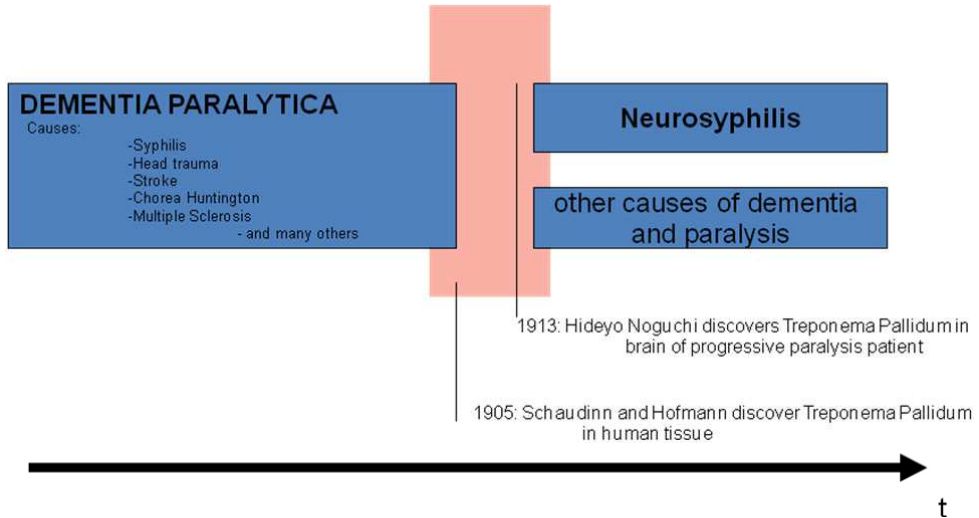
## 1. Introduction

### 1.1 Historical aspects

The first case of syphilis occurred in Europe around the year 1493. Martin Alonzo Pinzon, commander of one of the three ships of Christopher Columbus, is considered as first documented victim of syphilis. The term "syphilis" was first described by the Italian physician and poet Giralomo Fracastoro in his epic noted poem titled "Syphilis sive morbus gallicus". The first well-recorded European syphilis outbreak occurred in 1494 during the siege of Naples by the French king Charles VIII (Hutto, 2001; Oriel, 1994; Bankl, 2002).

A worldwide spread of syphilis could then be observed. In scientific reports around the 19th century specific forms of neurosyphilis were grouped under the multicausal term "*Paralytic Dementia*". This term was defined as a syndrome, in which various forms of diseases such as syphilis, alcoholism, head injuries, hereditary diseases, and others were included. All of them presented demential and paralytical symptoms as common course (see graph 1). By the end of the 19th century approx. 45% of male patients hospitalized in psychiatric clinics in German speaking countries suffered from paralytic dementia. The number of patients suffering from neurosyphilis remains unclear. At the same time Emil Kraepelin reported that 34% of male patients suffered from a syphilis related paresis (Diefendorf, 1906).

In 1905, Schaudinn and Hoffmann discovered **Treponema pallidum** in tissue of patients with syphilis. One year later, the first effective test for Syphilis, the "Wassermann Test", was developed. In 1909, Nobel laureate Paul Ehrlich developed, together with his assistant Sahachiro Hata, Salvarsan, an arsenic compound, which is considered as the first effective treatment against syphilis before the penicillin era (Gensini et al, 2007). In 1913, Noguchi Hideyo demonstrated the presence of *Treponema pallidum* in the brain of progressive paralysis patients and was the first to establish a link between an infection with *Treponema pallidum* and the "Progressive paralysis" and "Tabes dorsalis" (Rulliere, 1992). The Austrian psychiatrist Julius Wagner Ritter von Jauregg tried inoculation of malaria parasites, which proved to be very successful in the case of dementia paralytica caused by neurosyphilis. It had been observed that patients who developed high fevers could be cured of syphilis as *Treponema pallidum* does not survive temperatures exceeding 41 ° C. In 1927, the discovery earned him the Nobel Prize in Physiology and Medicine (Nobel Lectures, 1965).



Graph 1. From the multicausal term „Dementia paralytica“ to „Progressive paralysis“ as a form of neurosyphilis

### 1.2 Epidemiological aspects

The discovery of penicillin and its widespread manufacture after World War II led to a decrease in syphilis infection rates. Until the 1990s syphilis has become a rare disease. Due to the low incidence a “syphilis eradication program” was planned by the Centers for Disease Control and Prevention (CDC) (Klausner et al, 2005). At present, it is obvious that the disease has not been eradicated. Estimations of the World Health Organization speak of 10-12 million new infections each year, primarily in developing countries of Africa and South America. Epidemiological data show a dramatic increase of infectious syphilis since the mid 1990s, mainly in the countries of the former Soviet Union, but also in Western European countries. A similar trend has been observed in the United States of America. According to recent epidemiological data rates of syphilis have been increasing in the United States and Europe, primarily among young adults and among men who have sex with men in urban areas or with individuals infected with HIV. It is important to mention, that the increase of syphilis prevalence is namely due to new infections (Lautenschlager, 2006; Geusau, 2004; Wöhr, 2007).

### 1.3 Clinical aspects

Due to the variety of its clinical presentations syphilis is called the chameleon of diseases, potentially affecting every organ of the body. Therefore, it is easy to overlook the symptoms at any stage. All symptoms of secondary stage will resolve with or without treatment and the patient enters the asymptomatic latent period in which an infection can be detected only by laboratory diagnosis. Two thirds of these patients remain asymptomatic. If left untreated, years to decades after primary infection, up to 30% of the affected individuals may develop tertiary syphilis. Tertiary syphilis can manifest as benign gummas, as cardiovascular disease (e.g. aneurysm of the ascending aorta), or as neurosyphilis (Workowski & Berman, 2006; Wöhr, 2007).

However, the central nervous system may be involved already in the secondary stage. In this context the authors would like to refer to psychiatric manifestations of syphilitic arteriitis with secondary thrombosis (Berlit, 2006; Wöhr, 2007).

Clinical manifestations of neurosyphilis can be divided into different subtypes (table 1). The asymptomatic form is characterized by the presence of a CNS infection as indicated by CSF abnormalities in the absence of psychiatric or other symptoms. Further, neurosyphilis is divided in a meningeal, a meningovascular, a parenchymatous, and a gummatous subform (Freedberg et al, 1999). This classification seems useful and is widely used (Flood et al, 1998, Friedrich et al, 2009).

I.	Asymptomatic
II.	Meningeal
	- acute meningitis
	-with hydrocephalus
	-with vertex involvement
	-with basilar involvement
	- spinal pachymeningitis
III.	Meningovascular
	- cerebral
	- spinal
	-meningomyelitis
	-acute transverse meningitis
IV.	Parenchymatous
	- general paresis
	- tabes dorsalis
	- optic atrophy
V.	Gummatous
	- cerebral compression symptoms
	- spinal compression symptoms

Table 1. Classification of neurosyphilis (Freedberg et al, 1999)

## 2. Psychiatric manifestations of neurosyphilis

Clinical manifestations as well as psychiatric symptoms of syphilis are diverse and have to be considered as non-specific. Table 2 gives an overview of psychiatric manifestations of neurosyphilis, classified according to the Tenth revision of the International Classification of Disease and Related Health Problems (= ICD-10) diagnoses.

Only few and inconsistent data about the prevalence of psychiatric manifestations of neurosyphilis can be found. In a retrospective analysis Timmermans et al (2004) report that approximately 51% of 161 patients diagnosed with neurosyphilis presented neuropsychiatric symptoms. A Danish study carried out over 17 years by Danielsen et al (2004) reports of 92 patients suffering of neurosyphilis: 36% of these patients initially presented with neurological symptoms, 17% with psychiatric manifestations.

Clinical manifestations of neurosyphilis are protean as stated above. A retrospective analysis of 117 patients by Flood et al (1998) shows a wide range of courses and symptoms

of neurosyphilis: 32% were asymptomatic, 33% presented personality changes, 28% of the patients had ataxia, 23% had a stroke, and 17% had ocular symptoms. 17% of the patients reported bladder disturbance, whilst 10% had typical shooting pains due to tabes dorsalis. Headache, dizziness, or hearing loss was observed in 10% of the patients, 7% of the patients had cerebral seizures. Mitsonis et al (2008) examined medical records of 81 patients suffering from neurosyphilis. Between 1965-1984 approx. 27% of the individuals showed psychiatric manifestations, while between 1985-2005 almost 86% had psychiatric symptoms. The reason for this difference could not be explained by the authors.

Hoche (1912)	ICD-10: DD	Literatur
simple demential course	F0: dementia	Montejo et al 1995; Goeman et al 1996; Russouw et al 1997; Antonowicz 1998; Fox et al. 2000; Hutto et al 2000; Fujimoto et al 2001; Polsky et al 2001; Morikawa et al 2002; Xue et al 2004; Timmermans et al 2004; Blatz et al 2005; Lee et al 2005; Lessig et al 2006; Mahmoudi et al. 2006; Brinar et al 2006; Gabriel et al 2007; Van Eijsden et al 2008; Luo et al 2008; Lee et al 2009; Ates et al 2009; Mehrabian et al 2009; Yu et al 2010; Güler et al 2010
	F0:others	Zifko et al 1995; Russouw et al 1997; Boerner 1997; Flood et al 1998; Denays et al 1999; Mancuso et al 2000; Sobhan et al 2004; Ilankovic et al 2004; Lair et al 2004; Blatz et al 2005; Estevez 2006; Foatelli et al 2006; Sanchez et al 2007; Mannekote et al 2008; Tibrewal et al 2008
	F1	Cnossen et al 1995; Hutto et al 2000; Hutto 2001; Saik et al 2004; Blatz et al 2005; Yu et al 2009; Spiegel et al 2010
paranoid course	F2	Patkar et al 1997; Russouw et al 1997; Hutto et al 2000; Kohler et al. 2000; Kararizou et al 2006; Taycan et al 2006; Turan et al 2007; Friedrich et al. 2009
depressive course	F3	Zifko et al 1995; König et al 1996; Masmoudil et al 1996; Russouw et al 1997; Hutto et al 2000; Ide et al 2004; Blatz et al 2005; Mirsal et al 2007; Woo et al 2007; Cubala et al 2008
euphoric-expansive course	F31: mania	Bschor et al. 1995; Dawson & Baldwin 1996; Palicio et al 1996; Mimura et al 1997; Russouw et al 1997; Dunivin & Foust 1999; Kornischka 1999; Mendez 2000; Mahendran 2001; Spiegel et al 2010
	F4	Boyle et al 1995, Schreiber 1996; Aigner et al 1997; Hutto et al 2000
	F6	Zifko et al 1995; Tso et al 2008

(DD= differential diagnosis; F= ICD-10 Chapter V: Mental and behavioural disorders)

Table 2. Publications with psychiatric differential diagnosis of neurosyphilis according to ICD-10 compared to the classification of Hoche (1912);

In an earlier survey carried out by Hooshmand and colleagues (1972), data of 241 neurosyphilis patients were analysed for the period between 1965 and 1970. The majority of the patients presented with rather mild complaint forms of primarily peripheric neuropathic symptoms, while psychiatric manifestations seemed to be rare: 5% presented depression, 3% manic states and 2% presented personality changes.

Danielsen et al (2004) carried out another analysis of the various forms of neurosyphilis distinguishing between frequency and occurrence of psychiatric symptoms: 27% of patients were asymptomatic, while 10% were diagnosed with a meningovascular, 50 % with a parenchymatous, and 13% with a non-classifiable form of syphilis. Psychiatric manifestations could only be found in parenchymatous forms of neurosyphilis.

In his work from 1912, Hoche divides the course of psychopathological forms of progressive paralysis into an euphoric-expansive, a depressed, a paranoid, and a simple dementia onset form. This nomenclature is also found in today's psychiatric textbooks as a valid classification. In this context Bonhoeffer's axiom of non-specific noxa concerning organic psychosyndromes has to be mentioned: different kinds of primary or secondary affections of the brain can result in an organic brain syndrome, which does not seem to be differentiable in psychopathological terms. On the other hand, different types of organic brain syndromes can be found despite identical underlying somatic disease (Bonhoeffer, 1917). Table 2 shows a wider diagnostic spectrum with further progressions for psychiatric manifestations of neurosyphilis.

Analysing the psychopathological aspects with reference to the ICD-10 (see table 2) different kinds of manifestations of acute (e.g. amnesic passage syndrome), and chronic organic psychosyndromes (e.g. organic personality changes) can be observed. A great number of publications focus on demential syndromes (e.g. Yu et al, 2010; Ates et al, 2009). Goeman and colleagues (1996) for example report in their survey on the occurrence of dementia symptoms in a 15-year-old boy with congenital syphilis. Meteo-Ayuso's (2000) recommendation for dementia symptoms accompanying syphilis is a symptomatic treatment with acetylcholinesterase inhibitors and / or memantines. Furthermore, various national Alzheimer societies recommend syphilis serologic testing as part of routine medical investigation of a demential syndrome (e.g. Schmidt et al, 2010).

A few case reports on substance dependence in association with neurosyphilis are available. Hutto (2001, 2000) reports of a patient initially treated for cocaine dependency, depression, and psychotic symptoms. Initial syphilis screening detected the eventual presence of neurosyphilis. Similar cases can be found for alcohol dependence (e.g. Cnossen et al, 1995; Blatz et al, 2005; Hutto, 2000). These cases show in particular the eventual co-occurrence of a syphilis infection and psychiatric disorders.

Manifestations of syphilis with psychotic symptoms can vary from specific forms of hallucinations (e.g. Russouw et al, 1997) to various schizophrenia like symptoms (e.g. Kornischka, 1999; Friedrich et al, 2009). Some authors report of an improvement of psychotic symptoms after the initiation of causal penicillin therapy (e.g. Mannekote et al, 2008; Friedrich et al, 2009). However, it should be noted that the overall benefit of antibiotic therapy in advanced neuronal damage is limited. Only a few data is available on different antipsychotic treatment regimens for syphilitic psychotic state images: Turan et al (2007) carried out an evaluation of ziprasidone in comparison to olanzapine, Taykan et al (2006) the effect of quetiapine and risperidone. Furthermore, Rothenhäusler (2007) recommends the application of quetiapine and aripiprazole for the treatment of "syphilitic psychosis", in addition to antibiotic therapy.

Some publications report of mood disorders associated with neurosyphilis: depressive states (e.g. Frank et al, 1996) are described, as well as manic episodes (e.g. Mahendran et al, 2001). Rozwens and colleagues (2003) report that approx. 27% of patients with psychiatric manifestations of neurosyphilis presented depressive symptoms in association with psychomotoric retardation, melancholia, and suicidal thoughts.

The reader should be aware that apart from manifestations classified by the ICD-10-F further psychiatric-related manifestations of neurosyphilis may occur, such as epileptic seizures (eg, Gürses et al, 2007; Sinha et al, 2008), autism (eg, Blatz et al, 2005), paresis (eg, Chen et al, 2005), pain symptoms (Mao et al, 2009), parkinsonism (Spitz et al, 2008), and Huntington's chorea (Ozben et al, 2009).

### 3. Discussion and conclusion

In past decades, neurosyphilis has been perceived as a rare, almost forgotten and “historic disease”. The rise of new infections with *Treponema pallidum* has confronted junior colleagues in the medical community with a variety of symptoms and manifestations that they have rarely seen in association with syphilis. Most of them have little knowledge of the complex appearance, the diagnosis, and the therapeutic options for this infectious disease (Aigner et al, 1997). The appropriate screening for syphilis in serum by *Treponema* antibody tests, such as the *Treponema Pallidum Particle Agglutination Test* (TPPA), is necessary to reveal a tertiary syphilis. These tests are, in particular for asymptomatic patients in the stage of late latency, the only reference to an infection with *Treponema pallidum* (Wöhr, 2007). Depending on the activity of the illness indicated by high titers of nontreponemal tests, further evaluation for neurosyphilis by clinical and cerebrospinal fluid investigations is indicated. It is recommended that each patient with clinically evident psychiatric symptoms should have blood screening for syphilis – and in case of positive test results – a lumbar puncture.

The cost-benefit analysis of routine syphilis screening has been questioned in the recent past and current studies. In 2007, Cheng and colleagues (2007) emphasizes in terms of syphilis screening and intervention in 500.000 pregnant women the importance and efficacy of these tests. Recent epidemiological data show that syphilis is not only a problem of the so-called developing countries. There has been a recent increase of infection rates in industrialized countries of the Western world as well. Therefore, routine blood screening for syphilis in the psychiatric field remains a vital part of the investigation of psychiatric inpatients. Due to diversity of clinical manifestations of neurosyphilis (table 2) it is impossible to carry out a diagnosis only on the basis of clinical symptoms.

The Centers for Disease Control and Prevention (CDC) defines confirmed neurosyphilis as any syphilis stage and a reactive CSF-Venereal Disease Research Laboratory (VDRL). Further the CDC defines presumptive neurosyphilis as any syphilis stage, a nonreactive CSF-VDRL, an elevated CSF protein or white blood cell (WBC) count in the absence of other known causes of these abnormalities, and clinical symptoms or signs consistent with neurosyphilis without other known causes for these abnormalities (Centers for Disease Control and Prevention, 2010; Marra, 2009). Recommended therapy for neurosyphilis is the use of Aqueous crystalline penicillin G 18-24 million units per day, administered as 3-4 million units IV every 4 hours or continuous infusion, for 10-14 days. Furthermore, benzathine penicillin, 2.4 million units IM once per week up to 3 weeks are recommended after completion of the treatment regimen. If CSF pleocytosis was present initially, a CSF

examination should be repeated every 6 months until a normal cell count can be found. In the presence of a penicillin allergy, the use of ceftriaxone 2g daily (IV or IM) is suggested for 10-14 days as alternative treatment (Centers for Disease Control and Prevention, 2010). Further, the authors would like to point out that there are no consensus and guidelines on how to deal with psychiatric manifestations in association with neurosyphilis (Sanchez et al, 2007). Therefore, an analysis of existing data and the initiation of prospective surveys are important for an effective and comprehensive treatment of affected patients in the future. Psychiatrists play an essential role in the detection of syphilis and its late manifestations. Some authors (Hutto, 2001; Mirsal et al, 2007) state that psychiatric patients may have a higher risk to acquire syphilis during their lifetime. Impulse control dysfunctions, a high-risk sexual behavior, such as promiscuity or unprotected sex, or cognitive impairment and difficulties in seeking health care and assistance may be the cause for it. Finally, there has to be a discussion on possibilities of co-morbidities in neurosyphilis and resulting difficulties in diagnosis. It often seems to be difficult to distinguish between pre-existing psychiatric disorders with secondary aggravation due to neurosyphilis and a secondary psychiatric disorder as a result of neurosyphilis. The situation gets even more complicated in the presence of a co-infection with HIV. Immunodeficiency may lead to a more rapid progression of syphilis to the stage of neurosyphilis, eventually with manifestations even a short time after infection (de Almeida et al, 2010; Marra, 2009).

#### 4. Acknowledgement

No conflict of interest.

#### 5. References

- Aigner M, Ossege M, Bach M & Lenz G (1997). Indikationskriterien zum gezielten Luesscreening. *Nervenarzt*; 68: 752-753.
- Antonowicz JL (1998). Missed diagnoses in consultation liaison psychiatry. *Psychiatr Clin North Am*; 21: 705-714.
- Arbeitsgruppe für STD und dermatologische Mikrobiologie der österreichischen Gesellschaft für Dermatologie (2009). *Leitlinien zur Therapie der klassischen Geschlechtskrankheiten und Sexually Transmitted Infections*; www.oegdv.at
- Ates MA, Algul A, Gecici O, Semiz UB, Yilmaz O & Gulsun M (2009). Olanzapine treatment in Jarish-Herxheimer reaction due to neurosyphilis with dementia: a case report. *J Psychopharmacol* 23: 999-1000.
- Ayuso-Meteo JL (2000) Psychiatric aspects of infections. In: *New Oxford Textbook of Psychiatry*, Gelder MG, Lopez-Ibor JrJJ, Andreasen NC (eds) Vol 2, 1168-1173. Oxford.
- Bankl H (2002) *Kolumbus brachte nicht nur die Tomaten*. Kremayr & Scheriau, Wien
- Berlit P(2006) *Klinische Neurologie*. Springer Medizin Verlag, Heidelberg
- Blatz R, Kühn HJ, Hermann W, Rytter M & Rodloff AC (2005) Neurosyphilis oder Neuroborreliose – retrospektive Auswertung von 22 Auswertungen. *Nervenarzt* 76: 724-732
- Boerner RJ (1997) Organic psychosyndrome with progressive paralysis – a case report. *Nervenheilkunde* 16: 464-467.
- Bonhoeffer K (1917) Die exogenen Reaktionstypen. *Arch Psychiatr Nervenkr* 58:58-70

- Boyle A, Zafar R, Riley V & Lindsay J (1995) Neurosyphilis presenting with dissociative symptoms. *J Neurol Neurosurg Psychiatry* 59: 452-453.
- Brinar VV & Habek M (2006) Dementia and white-matter demyelination in young patient with neurosyphilis. *Lancet* 368: 2258
- Bschor T, Nurnbach-Ross B & Albrecht J (1995) Organic origin of manic psychosis. A case report of progressive paralysis. *Nervenarzt* 66: 54-56.
- Centers for Disease Control and Prevention (2010) Sexually Transmitted diseases Treatment Guidelines, 2010. *MMWR* 59: RR12.
- Chen CW, Chiang HC, Chen PL, Hsieh PF, Lee YC & Chang MH (2005) General paresis with reversible mesial temporal T2-weighted hyperintensity on magnetic resonance image: a case report. *Acta Neurol Taiwan* 14: 208-212.
- Cheng JQ, Zhou H, Hong FC, Zhang D, Zhang YJ, Pan P et al (2007) Syphilis screening and intervention in 500 000 pregnant women in Shenzhen, the People's Republic of China. *Sex Transm Infect* 83: 347-350.
- Crossen WM, Niekus H, Nielson O, Vegt M & Blansjaar BA (1995) Ceftriaxone treatment of penicillin resistant neurosyphilis in alcoholic patients. *J Neurol Neurosurg Psychiatry* 59: 194-195.
- Cubala WJ & Czarnowska-Cubala M (2008) Neurosyphilis presenting with depressive symptomatology: is it unusual? *Acta Neuropsychiatr* 20: 110.
- Danielsen AG, Weismann K, Jorgensen BB, Heidenheim M & Fugleholm AM (2004) Incidence, clinical presentation, and treatment of neurosyphilis in Denmark, 1980-1997. *Acta Derm Venereol* 84:459-462.
- Dawson G & Baldwin B (1996). Neurosyphilis and secondary mania in elderly patients. *Ir J Psychol Med* 13: 24-25.
- de Almeida SM, Bhatt A, Riggs PK, Durelle J, Lazaretto D, Marquie-Beck J, Mc Cutchan A, Letendre S & Ellis R (2010). Cerebrospinal fluid human immunodeficiency virus viral load in patients with neurosyphilis. *J Neurovirol* 16:6-12.
- Denays R, Collier A, Rubinstein M & Atsama P (1999) A 51-year old woman with disorientation and amnesia. *Lancet* 354 : 1786.
- Diefendorf AR (1906) Etiology of Dementia Paralytica. *BMJ* September; 744-748
- Dunivin DL & Foust MJ (1999) A case study from the department of defense psychopharmacology demonstration project: mania and neurosyphilis. *Prof Psychol Res Pr* 30: 346-351.
- Estevez RF (2006) Neurosyphilis presenting as rhabdomyolysis and acute renal failure with subsequent irreversible psychosis and dementia. *Psychosomatics* 47: 538-539
- Flood JM, Weinstock HS, Guroy ME, Bayne L, Simon RP & Bolan G (1998) Neurosyphilis during the AIDS epidemic, San Francisco, 1985-1992. *J Infect Dis* 177: 931-940.
- Foatelli FM, Gernay P, Lievens I & Ansseau M (2006) Syndrome malin der neuroleptiques et paralysie generale. *Rev Med Liege* 61: 807-811.
- Fox PA, Hawkins DA & Dawson S (2000) Dementia following an acute presentation of meningovascular neurosyphilis in an HIV-1- positive patient. *Aids* 14: 2062-2063.
- Frank U, Wolfersdorf M, Loble M & Hafele M (1996) Paranoide Depression bei progressiver Paralyse, Vitamin B-12 Mangel und subklinischer Hyperthyreose. *Nervenheilkunde* 15: 173-177.




- Freedberg IM, Eisen A, Wolff K, Austen KF, Goldsmith LA, Katz S & Fitzpatrick T (1999). *Fitzpatrick's Dermatology in General Medicine- Volume II*. Fifth Edition, Mc Graw-Hill. New York, San Francisco.
- French P, Gomberg M, Janier M, Schmidt B, van Voorst Vader P & Young H (2009) IUSTI: 2008 European Guidelines on the Management of Syphilis. *Int J STD AIDS* 20 : 300-309.
- Friedrich F, Geusau A, Greisenegger S, Ossege M & Aigner M (2009) Manifest psychosis in neurosyphilis. *Gen Hosp Psychiatry* 31:379-381.
- Fujimoto H, Imaizumi T, Nishimura Y, Miura Y, Ayabe M, Shoji H & Abe T (2001) Neurosyphilis showing transient global amnesia-like attacks and magnetic resonance imaging abnormalities mainly in the limbic system. *Int Med* 40: 439-442.
- Gabriel JP, Velon A, Ribeiro P, Santos MA & Silva MR (2007) Demential syndrome secondary to neurosyphilis. *Synapse* 7: 63-67.
- Gensini GF, Conti AA & Lippi D (2007) The contributions of Paul Ehrlich to infectious disease. *J Infect* 54: 221-224.
- Geusau A, Mayerhofer S, Schmidt B, Messeritsch E & Tschachler E (2004) The year 2002 re-emergence of syphilis in Austria. *Int J STD AIDS* 15:496-497.
- Goeman J, Hoksbergen I, Pickut BA, Dom L, Crols R & De Deyn PP (1996) Dementia paralytica in a fifteen-year-old boy. *J Neurol Sci* 144 : 214-217.
- Güler E & Leyhe T (2010) A late form of neurosyphilis manifesting with psychotic symptoms in old age and good response to ceftriaxone therapy. *International Psychogeriatrics*, article in press.
- Gürses C, Kürtüncü M, Jirsch J, Yesilot N, Hanagasi H, Bebek N, Baykan B, Emre M, Gökyigit A & Andermann F (2007) Neurosyphilis presenting with status epilepticus. *Epileptic Disord* 9: 51-56.
- Hoche A (1912) Dementia paralytica. In: *Handbuch der Psychiatrie* .Aschaffenburg G (Ed). Deuticke; Leipzig
- Hooshmand H, Escobar MR & Kopf SW (1972) Neurosyphilis: a study of 241 patients. *JAMA* 219:726-729.
- Hutto B & Adimora A (2000) Syphilis in Psychiatric Inpatients: prevalence, treatment and implications. *Gen Hosp Psychiatry* 22:291-293.
- Hutto B (2001) Syphilis in clinical psychiatry. *Psychosomatics* 42: 453-460
- Ide M, Mizukami K, Fujita T, Ashizawa Y & Asada T (2004) A case of neurosyphilis showing a marked improvement of clinical symptoms and cerebral blood flow on single photon emission computed tomography with quantitative penicillin treatment. *Prog Neuropsychopharmacol Biol Psychiatry* 28: 417-420.
- Ilanovic N, Ivkovic M, Sokic D, Ilanovic A, Milovanovic S, Filipovic B, Tiosavljevic D, Ilanovic V & Bojic V (2004) Dementia paralytica (neurosyphilis): a clinical case study. *World J Biol Psychiatry* 4: 135-138.
- Kararizou E, Mitsonis C, Dimopoulos N, Gkias K, Markou I & Kalfakis N (2006) Psychosis or simply a new manifestation of neurosyphilis? *J Int Med Res* 34: 335-337.
- Klausner JD, Kent CK, Wong W, McCright J & Katz MH (2005) The public health response to epidemic syphilis, San Francisco, 1999-2004. *Sex Transm Dis* 32:S11-S18.
- Kohler CG, Pickholtz J & Ballas C (2000) Neurosyphilis presenting as schizophrenialike psychosis. *Neuropsychiatry Neuropsychol Behav Neurol* 13: 297-302.

- König F, Frank U, Wolfersdorf M, Löble M & Häfele M (1996) Paranoide Depression bei progressive Paralyse, Vitmain B-12Mangel und subklinischer Hyperthyreose. *Nervenheilkunde* 15: 173-177.
- Kornischka J (1999) Maniforme Psychose bei Neurolyues. *Psych Prax* 26: 256.
- Lair L & Naidech AM (2004) Modern neuropsychiatric presentation of neurosyphilis. *Neurol* 63: 1331-1333
- Lautenschlager S (2006) Syphilisdiagnostik: Klinische und labormedizinische Problematik. *JDDG* 12: 1058-1073.
- Lee CH, Lin WC, Lu CH & Liu JW (2009) Initially unrecognized dementia in a young man with neurosyphilis. *Neurologist* 15: 95-97
- Lee JW, Wilck M & Venna N (2005) Dementia due to neurosyphilis with persistently negative CSF VDRL. *Neurol* 65 : 1838
- Lessig S & Tecoma E (2006) Perils of the prozone reaction: neurosyphilis presenting as an RPR-negative subacute dementia. *Neurol* 66: 777
- Luo W, Ouyang Z, Xu H, Chen J, Ding M & Zhang B (2008) The clinical analysis of general paresis with 5 cases. *Neuropsychiatry Clin Neurosci* 20: 490-493
- Mahendran R (2001) Clozapine in the treatment of hypomania with neurosyphilis. *J Clin Psychiatry* 62 : 477-478
- Mahmoudi R, Maheut-Bosser A, Hanesse B & Paille F (2006) La Neurosyphilis: une cause rare de démence. *Rev Med Interne* 27: 976-978
- Mancuso A, Sbrana R, Ghersi L, Bernareggi N & Gorini M (2000) Neurosyphilis: an atypical case. *Neurol Sci* 21: S165-S166
- Mannekote ST & Singh VK (2008) A case of neurosyphilis presenting with treatment-resistant psychotic symptoms and progressive cognitive dysfunction. *Ger J Psychiatr* 11: 153-155
- Mao S, Liu Z (2009) Neurosyphilis manifesting as lightning pain. *Eur J Dermatol* 19: 504-506
- Marra CM (2009) Update on Neurosyphilis. *Curr Infect Dis Rep* 11:127-134
- Masmoudil K, Joly H, Rosa A & Mizon JP (1996) Does general paresis always exist in non-AIDS patient ? *Rev Med Int* 17: 576-578
- Mehrabian S, Raycheva MR, Petrova EP, Tsankov NK & Traykov LD (2009) Neurosyphilis presenting with dementia, chronic chorioretinitis and adverse reactions to treatment : a case report. *Cases J* 2: 8334
- Mendez MF (2000) Mania in neurologic disorders. *Curr Psychiatry Rep* 2: 440-445.
- Mimura M, Kato M, Ishii K, Yoshino F, Saito F & Kashima H (1997) A neuropsychological and neuroimaging study of a patient before and after treatment of parietic neurosyphilis. *Neurocase* 3: 275-283
- Mirsal H, Kalyoncu A, Pektas Ö & Beyazyürek M (2007) Neurosyphilis presenting as psychiatric symptoms: an unusual case report. *Acta Neuropsychiatr* 19: 251-253
- Mitsonis CH, Kararizou E, Dimopoulos N, Triantafyllou N, Kapaki E, Mitropoulos P, Sfagos K & Vassilopoulos D (2008) Incidence and clinical presentation of Neurosyphilis: a retrospective study of 81 cases. *Int J Neurosci* 118: 1251-1257
- Montejo M, Ruiz-Irastorza G, Aguirrebengoa, Onate K & Aurrekoetxea J (1995) Neurosyphilis as a cause of dementia: does it still exist ? *J Infect* 30: 186-187
- Morikawa M, Kosaja J, Imai T, Ohsawa H, Iida J & Kishimoto T (2002) A case of general paresis showing marked treatment-associated improvement of cerebellar blood flow by quantitative imaging analysis. *Ann Nucl Med* 16: 71-74

- Nobel Lectures (1965), Physiology or Medicine 1922-1941: Wagner-Jauregg J. *The Treatment of Dementia Paralytica by Malaria Inoculation*. Elsevier Publishing Company; Amsterdam
- Oriel JD (1994) *The scars of Venus: A History of Venereology*. Springer Verlag: London.
- Ozben S, Erol C, Ozer F & Tiras R (2009) Chorea as the presenting feature of neurosyphilis. *Neurol India* 57 : 347-349
- Palicio L & Basauri VA (1996) Neurosyphilis with psychiatric manifestations – a forgotten condition? *Ir J Psychol Med* 13: 26-27
- Patkar AA, Peng AT & Alexander RC (1997) Neurosyphilis occurring in a patient with schizohrenia: a cautionary tale. *J Nerv Ment Dis* 185 : 119-120.
- Polsky I & Samuels SC (2001) Neurosyphilis: Screening does sometimes reveal an infectious cause of dementia. *Geriatrics* 56: 61-62
- Rothenhäusler HB (2007) Neurosyphilis – Diagnose und Therapie vor psychiatrischem Hintergrund. *Fortschr Neurol Psychiatr* 75:737-747
- Rozwens A, Radziwillowicz P, Jakuszkowiak K & Cubala WJ (2003) Neurosyphilis with its psychopathological implications. *Psychiatr Pol* 37:477-494
- Rulliere R (1992) Die japanische Medizin. In: R. Toellner: *Illustrierte Geschichte der Medizin*. Andreas Verlag; Salzburg.
- Russouw HG, Roberts MC, Emsley RA & Truter R (1997) Psychiatric manifestations and magnetic resonance imaging in HIV-negative neurosyphilis. *Biol Psychiatry* 41: 467-473
- Saik S, Kraus JE, McDonald A, Mann SG & Sheitman BB (2004) Neurosyphilis in newly admitted psychiatric patients: three case reports. *J Clin Psychiatry* 65: 919-921
- Sanchez FM & Zisselman MH (2007) Treatment of psychiatric symptoms associated with neurosyphilis. *Psychosomatics* 48: 440-445
- Schmidt R, Marksteiner J, Dal Bianco P, Ransmayr G, Bancher C, Benke T, Wancata J, Fischer P, Leblhuber CF et al (2010) Konsensusstatement „Demenz 2010“ der Österreichischen Alzheimer Gesellschaft. *Neuropsychiatr* 24: 67-87
- Schreiber W (1996) Ein Fall von „Syphilitischer Neurasthenie“. Zur neuen Brisanz eines fast vergessenen Chamäleons. *Psych Prax* 23 : 98-99
- Sinha S, Harish T, Taly AB, Murthy P, Nagarathna S & Chandramuki A (2008) Symptomatic seizures in neurosyphilis: an experience from a university hospital in south India. *Seizure* 17: 711-716
- Sobhan T, Rowe HM, William GR & Munoz C (2004) Three cases of psychiatric manifestations of neurosyphilis. *Psychiatr Serv* 55 : 830-832
- Spiegel DR, Weller AL, Pennell K & Turner K (2010) The successful treatment of mania due to acquired immunodeficiency syndrome using ziprasidone. *Journal of Neuropsychiatry and Clinical Neurosciences* 22 : 111-114
- Spitz M, Maia FM, Gomes HR, Scaff M & Barbosa ER (2008) Parkinsonism secondary to neurosyphilis. *Mov Disord* 23: 1948-1949
- Taycan O, Ugur M & Ozmen M (2006) Quetiapine vs. risperidone in treating psychosis in neurosyphilis: a case report. *Gen Hosp Psychiatry* 28: 359-361
- Tibrewal P, Kumar I, Zutshi A & Math SB (2008) Valproate for treatment of agitation in neurosyphilis: a case report. *Prim Care Companion J Clin Psychiatry* 10: 163
- Timmermans M & Carr J (2004) Neurosyphilis in the modern era. *J Neurol Neurosurg Psychiatry* 75: 1727-1730

- Tso MK, Koo K & Tso GY (2008) Neurosyphilis in a non-HIV patient: more than a psychiatric concern. *Mcgill J Med* 11: 160
- Turan S, Emul M, Duran A, Mert A & Ugur M (2007) Effectiveness of olanzapine in neurosyphilis related organic psychosis. A case report. *J Psychopharmacol* 21: 556-558
- Van Eijdsden P, Veldink JH, Linn FH, Scheltens P & Biessels GJ (2008) Progressive dementia and mesiotemporal atrophy on brain MRI: Neurosyphilis mimicking pre-senile Alzheimer's disease. *Eur J Neurol* 15: e14-e15
- Wöhrl S & Geusau A (2007) Clinical update: syphilis in adults. *Lancet* 369: 1912-1914
- Woo B, Jeevarakshagan S, Sevilla C & Obrocea G (2007) Psychiatric and neuro-ophthalmological manifestations of syphilis. *Psychosomatics* 48 : 451
- Workowski KA & Berman SM (2006) Sexually transmitted diseases treatment guidelines. *MMWR Recomm Rep* 55: 1-94
- Xue XY & Meng SY (2004) Epidemiological analysis of reversible dementia in an outpatient department of neurology. *Chin J Clin Rehab* 8: 5388-5390
- Yu Y, Wei M, Huang Y, Jiang W, Liu X, Xia F, Li D & Zhao G (2010) Clinical presentation and imaging of general paresis due to neurosyphilis in patients negative for human immunodeficiency virus. *J Clin Neurosci* 17: 308-310
- Zifko U, Schmidt B, Grisold B & Stanek G (1995) Neurosyphilis - a case report and review of the literature concerning the differential diagnosis to Lyme borreliosis. *Wien Med Wochenschr* 145 : 191-194



## **Syphilis - Recognition, Description and Diagnosis**

Edited by Dr. Neuzha Satomi Sato

ISBN 978-953-307-554-9

Hard cover, 130 pages

**Publisher** InTech

**Published online** 21, November, 2011

**Published in print edition** November, 2011

Syphilis, a sexually transmitted disease was first described in 15th century, is caused by *Treponema pallidum* subsp. *pallidum* and occurs worldwide. This book is a collection of chapters presenting the novel knowledge about the *T. pallidum* and some historical and up to date information about venereal disease and syphilis. The collection of articles includes: immunological aspects recognition of *T. pallidum* by the pattern recognition receptors of the innate immune; the whole genome analysis of treponemes and new targets for its molecular diagnosis; some historical aspects of venereal diseases treatment; natural history of syphilis including clinical manifestation and epidemiology; a clinical aspects dealing with psychiatric manifestations of neurosyphilis; spatial and temporal patterns of primary syphilis and secondary syphilis described by the spatial and space-time scan statistics; a commonly used methods for laboratorial diagnosis, the serological response to treatment of syphilis and safety in blood transfusion. I hope this book will be useful for students and research fellows as well for the wide audience.

### **How to reference**

In order to correctly reference this scholarly work, feel free to copy and paste the following:

Fabian Friedrich and Martin Aigner (2011). Psychiatric Manifestations of Neurosyphilis, *Syphilis - Recognition, Description and Diagnosis*, Dr. Neuzha Satomi Sato (Ed.), ISBN: 978-953-307-554-9, InTech, Available from: <http://www.intechopen.com/books/syphilis-recognition-description-and-diagnosis/psychiatric-manifestations-of-neurosyphilis>

**INTECH**  
open science | open minds

### **InTech Europe**

University Campus STeP Ri  
Slavka Krautzeka 83/A  
51000 Rijeka, Croatia  
Phone: +385 (51) 770 447  
Fax: +385 (51) 686 166  
[www.intechopen.com](http://www.intechopen.com)

### **InTech China**

Unit 405, Office Block, Hotel Equatorial Shanghai  
No.65, Yan An Road (West), Shanghai, 200040, China  
中国上海市延安西路65号上海国际贵都大饭店办公楼405单元  
Phone: +86-21-62489820  
Fax: +86-21-62489821

© 2011 The Author(s). Licensee IntechOpen. This is an open access article distributed under the terms of the [Creative Commons Attribution 3.0 License](#), which permits unrestricted use, distribution, and reproduction in any medium, provided the original work is properly cited.