

RPGN - Clinical Features, Treatment and Prognosis

Mitra Naseri

*Mashhad University of Medical Sciences,
Islamic Republic of Iran*

1. Introduction

Rapidly progressive glomerulonephritis (RPGN) is one of the nephrology emergencies which needs special attention. RPGN is a clinical description which determines by symptoms and signs of glomerulonephritis (GN); edema, hypertension and gross hematuria, and evidence of acute renal failure (severe decrease in glomerular filtration rate presents as oliguria or anuria, and increased serum levels of BUN and creatinine). Definite diagnosis of the disorder is based on kidney biopsy's findings. Early diagnosis and appropriate treatment plays a critical role in renal saving and preventing permanent glomerular damage.

This chapter will focus on clinical manifestations, therapeutic protocols and prognostic factors in patients with different subtypes of RPGN.

Rapidly progressive glomerulonephritis (RPGN) is defined as a syndrome with abrupt or insidious onset of hematuria, proteinuria, anemia, and rapidly progressing acute renal failure (ARF), and special findings on light microscopy examination of kidney biopsy's specimen; crescentic lesions which usually involved most glomerular architectures (Hirayama, et al., 2008; Rutgers et al., 2004). It also characterized by rapid loss of renal function (GFR < 50% within 3 months) with histological findings of crescent lesions which usually involves > 50 % of glomeruli (Couser, 1988).

RPGN can be primary or secondary. Secondary forms occur in any form of severe glomerulonephritis including membranoproliferative GN, IgA nephropathy, post infectious GN, and systemic lupus erythematosus (SLE). Primary RPGN is an autoimmune disease which is divided into three immunopathologic categories: (Rutgers et al., 2004; Haas & Eustace, 2004):

Type I RPGN: glomerulonephritis with antibodies directed against the glomerular basement membrane (GBM) (anti-GBM mediated GN)

Type II RPGN: immune-complex induced glomerulonephritis

Type III RPGN: Antineutrophil cytoplasmic antibody associated glomerulonephritis (ANCA-associated glomerulonephritis or pauci-immune GN)

RPGN type 1 and 2 are responsible for 10-20 % and 40 % of all cases respectively. **RPGN type 2** can be found in different forms of systemic disease such as post infectious GN (PSGN), Ig-A nephropathy, Henoch-Schönlein purpura (HSP), SLE, membranous GN (MGN) or membranoproliferative GN (MPGN). A few cases of idiopathic immune-complex-mediated RPGN have been reported (Jindal, 1999).

Interestingly different forms of RPGN share similar clinical features including hematuria, proteinuria, edema, hypertension and symptoms of ARF. Patients with Anti-GBM antibody or pauci-immune RPGN (ANCA-associated vasculitis) may have pulmonary hemorrhage and hemoptysis (Jindal, 1999). In pauci-immune RPGN the initial symptoms are non-specific; often fatigue, fever, night sweats and arthralgias are first clinical manifestations (Jindal, 1999).

2. Histopathology characteristics of RPGN and laboratory findings

Variable clinical manifestations and non-specific histologic changes complicate diagnosis and classification of vasculitis. To confirm the diagnosis light microscopy and immunofluorescence examinations of kidney biopsy should be accompanied by appropriate serologic tests, including ANCA (Vizjak et al., 2003).

2.1 Light microscopy findings

Histopathologically, RPGN is characterized by a vasculitis which involves glomerular capillaries, and results in formation of cellular crescents within most glomeruli (Hricik et al., 1998). The hallmark histologic lesions are crescents; a morphologic expression of severe glomerular injury. In severe glomerular injury rupture of the glomerular capillaries allows inflammatory mediators to spill into Bowman's space, resulting in epithelial cell proliferation and invasion of monocyte and macrophage to Bowman's space (Couser, 1988; Jennette & Falk, 1998; Jennette & Thomas, 2001). Crescents are divided into cellular, fibrocellular or fibrous types. Hallmarks of irreversible glomerular or tubulointerstitial injuries are glomerular sclerosis, fibrous or fibrocellular crescents, and interstitial fibrosis. The lesions usually are seen in various stages of activity or resolution. Necrotizing inflammation in small cortical arteries is reported in 10% of biopsy specimens. Inflammation of medullary vasa recta with papillary necrosis is another finding that may be found (Lionaki et al., 2007).

In acute pauci-immune glomerulonephritis (RPGN type III) fibrinoid necrosis accompanies crescents. These lesions occur at the same frequency irrespective of the presence or absence of associated vasculitis (D'Agati et al., 1986). Acute lesions range from focal segmental fibrinoid necrosis affecting less than 10% of glomeruli to severe diffuse necrotizing and crescentic glomerulonephritis that may injure all glomeruli. Periglomerular granulomatous inflammation may occur, but is not specific for pauci-immune glomerulonephritis (Lionaki et al., 2007).

3. Histopathology characteristics on immunofluorescent microscopy

Anti-GBM glomerulonephritis is characterized by linear staining for IgG and usually C3 along the glomerular capillary. Immune complex-mediated glomerulonephritis, which is found in severe forms of various types of glomerulonephritis such as PSGN, IgA nephropathy, and lupus nephritis, is characterized by granular glomerular staining for one or more immunoglobulins and/or complement components, and pauci-immune glomerulonephritis is characterized by mild or absent glomerular tuft staining for immunoglobulins and/or complement (Rutgers et al., 2004).

Anti-neutrophil cytoplasmic antibodies (ANCA) associated glomerulonephritis are usually pauci-immune; however, immunofluorescence microscopy often reveals a low level of

staining (less than +2, in the 0–4 scale (Harriset al., 1998)). **Figure 1** presents histologic findings in light and immunofluorescent microscopy.

3.1 Electron microscopy findings

On electron microscopy examination absence of electron-dense immune complex deposits (type I RPGN), multiple electron-dense deposits (type II RPGN), and few or no electron-dense deposits (type III RPGN) are main findings (**figure 2**) (Haas, M. & Eustace, 2004).

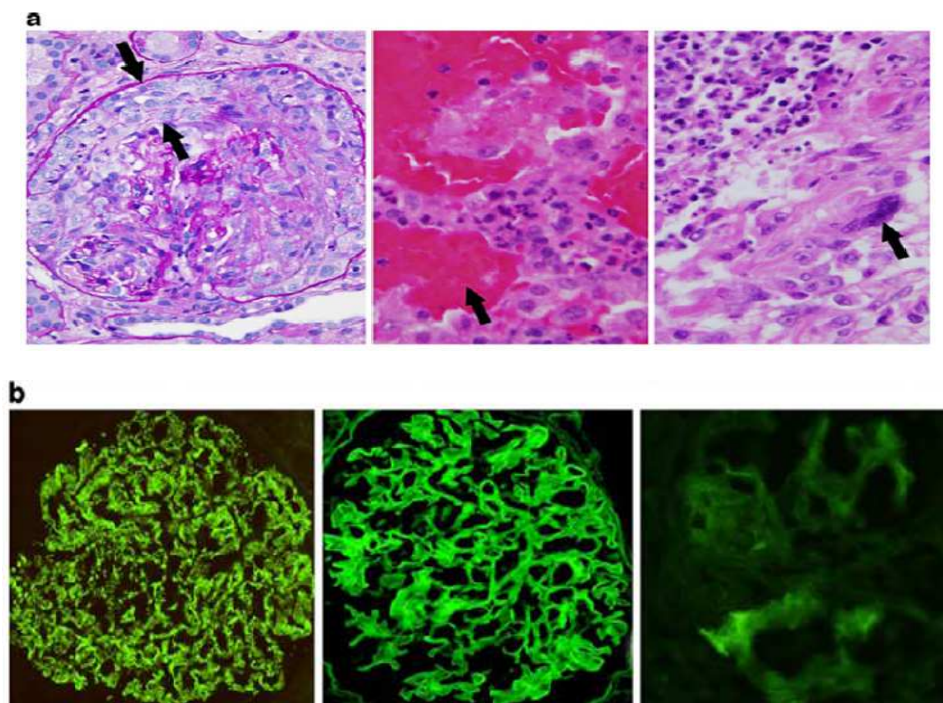


Fig. 1. Histopathologic findings in light and immunofluorescent microscopy (Lionakiet al., 2007) **a/left**; light microscopic demonstration of ANCA-associated necrotizing GN (with a crescent), arrows; (alveolar capillaritis with intra-alveolar hemorrhage); arrow; **middle** (and pulmonary necrotizing granulomatous inflammation with a multinucleated giant cell) arrow; **right b/middle**; Immunofluorescence microscopy can separate crescentic glomerulonephritis into anti-GBM with linear IgG staining, (**left**) immune complex with granular staining, (**right**); or pauci-immune categories with little or no immunoglobulin staining

4. Anti-neutrophil cytoplasmic and anti-GBM antibodies

Anti-neutrophil cytoplasmic antibodies (ANCA) are characteristic markers of small vessel vasculitides; Wegener's granulomatosis (WG), Microscopic polyangiitis (MPA), Churg-Strauss Syndrome (CSS), and idiopathic pauci-immune necrotizing glomerulonephritis for them the term ANCA associated vasculitides (AAV) has long been used (Jennette et al., 1989).

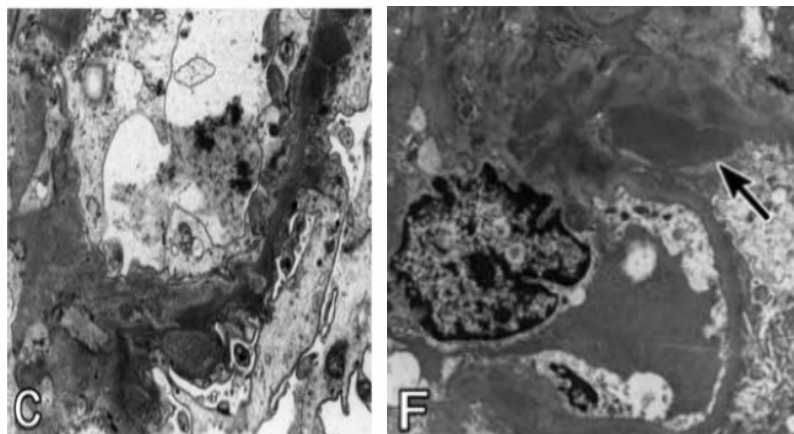


Fig. 2. Electron microscopy findings (Haas, M. &Eustace, 2004)

C: Electron microscopy showing multiple sub-epithelial electron-dense deposits, some appearing partially resorbed, with extension of the glomerular basement membrane (GBM) around the deposits (uranyl acetate and lead citrate stain, original magnification $\times 6300$)

F: Electron microscopy showing a large subepithelial deposit in a "notch" area (arrow), as well as mesangial deposits (uranylacetate and lead citrate stain, original magnification $\times 3800$).

The standard approach for detection of ANCA is indirect immunofluorescence (IIF) technique followed by antigen-specific quantitative assays .Myeloperoxidase (MPO) and proteinase3 (PR3) are major ANCA antigens (Falk .&Jennette, 1988; Goldschmeding et al., 1989; Niles et al., 1989).

In patients with RPGN, there are two major sub classes of ANCA, namely perinuclear (p -ANCA) and cytoplasmic (c -ANCA) (Guillevinet al., 1999) .The main epitope of p-ANCA is myeloperoxidase(MPO), and that of c-ANCA is proteinase-3 (PR3) (Asarodet al., 2000). MPO-ANCAis a useful serum marker for MPA and idiopathic pauci-immune crescentic GN, and PR3-ANCA is regarded as a serum marker for Wegener's granulomatosis and MPA (Asarodet al., 2000). Majority (approximately80- 85%) of cases of pauci-immune crescentic glomerulonephritis are ANCA positive(Haueret al., 2002;Jennette, 2003). Greater than 95% of cytoplasmic ANCA are PR3-ANCA and >95 %of perinuclear ANCA are MPO-ANCA (Lionakiet al., 2007). The c and p-ANCAs are mostly directed against the azurophilic granule proteins proteinase 3 (PR3)and myeloperoxidase (MPO), respectively .Detection of c and especially p-ANCAs are not equivalent to the presence of PR3-and MPO-ANCA. It is recommended to detect ANCA by an antigen-specific ELISA (Savigeet al., 2000; Cohen Tervaert et al., 1991).

Anti-GBM antibodies which are directed to the non-collagenous part ofthe $\alpha 3$ chain of type IV collagen, can also be evaluated byboth IIF and ELISA(Rutgers et al., 2004) .The ANCA-GBM dot-blot is a qualitative assay that uses nitrocellulose strips on which purified antigens are blotted at preset spots .MPO and PR3 antigens that are used in these tests are produced from human leukocytes .The GBM-ANCA dot-blot assay has been revealed reactivities that had not been detected by ELISA(**Table 1**) (Rutgers et al., 2004).

	MPO-ANCA	PR3-ANCA	Anti-GBM antibodies
Sensitivity	80–86% ^a	92–95% ^a	100%
Specificity	100%	100%	91–94% ^a
Inter-observer effect	5%	1%	8–24% ^b

Table 1. Characteristics of the GBM-ANCA Dot-Blot Assay (Rutgers et al., 2004)

5. RPGN, Pulmonary–renal syndrome (PRS), and ANCA-associated vasculitis (AAVs)

The ANCA-associated vasculitis (WG, MPA, and CSS) are a group of rare autoimmune conditions characterized by the development of necrotizing vasculitis. They share a number of clinical features and are therefore treated using similar treatment protocols.

The AAVs are rare with an annual incidence of 20/million in Europe, with WG as the most common and CSS the least frequent (Ntatsaki et al., 2010). In far-east, MPA is more common than WG. It's thought that they arise from interaction between an environmental factor and a genetically predisposing agent (Ntatsaki et al., 2011).

Pulmonary–renal syndrome (PRS) is defined as combination of diffuse alveolar hemorrhage (DAH) and glomerulonephritis (Savage et al., 1997; Seo & Stone, 2004; Jennette & Falk, 2003).

This syndrome is caused by different diseases, including various forms of primary systemic vasculitis especially WG and MPA, ANCA-associated systemic vasculitis (AAV), Good pasture's syndrome, SLE, and infection-associated or drug induced glomerulonephritis (Westman et al., 1997; Brusselle, 2007).

Immunologic injuries or non-immunologic mechanisms are involved in pathogenesis of PRS. Immunologic mechanisms such as production of anti-GBM antibodies, ANCA, immune complexes mediated injuries and non-immunologic mechanisms such as thrombotic microangiopathy (Rondeau et al., 1989) have been suggested. Pulmonary involvement in the majority of cases is the result of small-vessel vasculitis that involves arterioles, venules and alveolar capillaries (necrotic pulmonary capillaritis). These lesions are clinically expressed with DAH (Levy & Winearls, 1994). In the majority of cases the underlying renal pathology is a form of focal proliferative glomerulonephritis (Jayne et al., 2000), with fibrinoid necrosis, as well as micro vascular thrombi, and extensive crescent formation accompanies glomerular tuft disease (Walters et al., 2010).

According to results of ANCA pulmonary renal syndrome can be categorized into two sub-groups:

1. ANCA-positive Pulmonary–renal syndrome
2. ANCA-negative Pulmonary–renal syndrome

Circulating ANCAs are detected in the majority of pulmonary–renal syndromes (The Wegener's Granulomatosis Etanercept Trial [WGET] Research Group 2005; Dickersin et al., 1994.) Three major systemic vasculitis syndromes are associated with positive ANCAs consists of Wegener's granulomatosis, microscopic polyangiitis and Churg–Strauss syndrome (The Wegener's Granulomatosis Etanercept Trial [WGET] Research Group, 2005), and idiopathic pulmonary–renal syndrome (Bolton & Turgill, 1989).

Majority of cases of pulmonary-renal syndromes are related to ANCA associated vasculitis (Brusselle, 2007). Pulmonary-renal syndrome in ANCA-negative systemic vasculitis is very rare and has been reported in Behçet's disease, HSP, IgA nephropathy and in mixed cryoglobulinaemia and rarely in thrombotic thrombocytopenic purpura (TTP) (Naseri & Zabolinejad, 2008).

ANCA-positive Pulmonary-renal syndrome : More than 80 % of patients with necrotizing pauci immune small-vessel vasculitis have circulating ANCA (Jennette & Falk, 1997). The main clinicopathological expressions of AAV are WG, MPA, CSS and renal-limited vasculitis (RLV). The highest incidence is for WG in northern Europe (Haugeberg et al., 1998; Watts et al., 2000, 2008; Lane et al., 2000; Reinhold-Keller et al., 2005), while the incidence of MPA/RLV is higher in Japan (Fujimoto et al., 2006).

Wegener's granulomatosis (WG): Friedrich Wegener in 1939 was the first investigator to recognize a group of diseases characterized by extra vascular necrotizing granulomatous inflammation of the respiratory tract with vasculitis and/or glomerulonephritis (Schultz & Tozman, 1995). In 1983, Fauci et al reported details of 85 patients with Wegener's granulomatosis followed over a 21-year period. Their diagnosis was based on upper and lower respiratory tract complications, renal disease, and variable involvement of other organs with disseminated vasculitis. Tissue biopsies confirmed the characteristic clinical findings (Fauci et al., 1983). Pathologically Wegener's granulomatosis was characterized by small-vessel necrotizing vasculitis and granulomatous inflammation involving mostly the upper and lower respiratory tracts and the kidneys (Sugimoto et al., 2007).

Diffuse alveolar hemorrhage is the most serious complication in small-vessel vasculitis. Respiratory symptoms including cough and hemoptysis. CXR or chest CT-scan may reveal diffuse lung infiltrate. Clinical manifestations, pathologic and serologic findings play important role in the diagnosis of WG. 75- 90 % of patients with active disease have PR3-ANCA (Langford, 2005; Ozaki, 2007). The role of PR3-ANCA in the pathogenesis of the disease is not clear, but in vitro evidence suggests that PR3-ANCA can directly or indirectly damage endothelial cells (Preston et al., 2002). With the recognition of association between ANCA and Wegener's granulomatosis, the concept of Wegener's granulomatosis has been modified and recently a less restrictive definition has been proposed, termed "Wegener's vasculitis." This term includes ANCA-positive patients with clinical presentations of WG such as sinusitis, pulmonary infiltrates, nephritis, and documented necrotizing vasculitis, but without biopsy-proven granulomatous inflammation. Both classic Wegener's granulomatosis and Wegener's vasculitis are different manifestations of the same disease process. The term "Wegener's syndrome" is a more generic term suggested by the working classification of ANCA-associated vasculitides (Tervaert, & Stegeman, 2003).

Diagnostic criteria have been reported by the research group of intractable vasculitis, ministry of Health, Labor, and Welfare {MHLW} of Japan for definite diagnosis of AAV including WG (Table 2) (Ozaki, 2007). Necrotizing granulomatous lesions commonly affect the ear, nose and throat (E), lung (L), and kidney (K). Systemic symptoms in WG are classified as the following :

1. E Symptoms: nasal symptoms; purulent rhinorrhea, epistaxis, and a saddle nose, eye symptoms; ophthalmic pain, visual disturbance, and exophthalmia, ear symptoms; otalgia and otitis media, and throat symptoms; pharyngeal ulcer, hoarseness, and laryngeal obstruction.

2. lung (L)symptoms: bloody sputa, cough, and dyspnea
3. Kidney(K)symptoms :hematuria, proteinuria, rapidly progressive renal failure, edema, and hypertension

1. Symptoms
(1) E symptoms
Nose (purulent rhinorrhea, epistaxis, and saddle nose)
Eyes (ophthalmic pain, visual disturbance, and exophthalmia)
Ears (otalgia and otitis media)
Throat (pharyngeal ulcer, hoarseness, and laryngeal obstruction)
(2) L symptoms
Bloody sputa, cough, and dyspnea
(3) K symptoms
Hematuria, proteinuria, rapidly progressive renal failure, edema, and hypertension
(4) Others due to vasculitis
(a) General symptoms: fever (38°C or higher, 2 weeks or longer), weight loss (6 kg or more for 6 months)
(b) Local symptoms: purpura, polyarthritis/polyarthralgia, episcleritis, mononeuritis multiplex, ischemic heart disease, gastrointestinal bleeding, and pleuritis
2. Histological findings
(1) Necrotizing granulomatous vasculitis with giant cells at the sites of E, L, and/or K
(2) Necrotizing crescentic glomerulonephritis without immune deposits
(3) Necrotizing granulomatous vasculitis of arterioles, capillaries, and venules
3. Laboratory findings
(1) Positive PR3-ANCA (or C-ANCA by an indirect immunofluorescence)
<Diagnosis>
1. Definite WG
(1) Positive for 3 or more of the symptoms, including E, L, and K symptoms
(2) Positive for 2 or more of the symptoms, and positive for either of the histological findings
(3) Positive for 1 or more of the symptoms, positive for either of the histological findings, and positive PR3-ANCA/C-ANCA
2. Probable WG
(1) Positive for 2 or more of the symptoms
(2) Positive for 1 of the symptoms, and positive for either of the histological findings
(3) Positive for 1 of the symptoms, and positive PR3-ANCA/C-ANCA

Table 2. Diagnostic criteria for Wegener's granulomatosis (Ozaki, 2007)

Biopsies of the nasal mucosa, lung, and kidney reveal necrotizing granulomatous vasculitis and necrotizing crescentic glomerulonephritis without immune deposits(Ozaki, 2007). WG with E, L, and K involvement is classified as the generalized form, while when there is no kidney involvement, E only, L only, or E +L, the term of limited form is used. The therapeutic strategies are different for each forms (Ozaki, 2007).

Microscopic polyangiitis (MPA)

Renal and pulmonary symptoms are characteristic in MPA, and interstitial pneumonitis and pulmonary hemorrhage are common clinical features .MPO-ANCA is positive in 50-75% of patients and biopsy of the lung and kidney reveals necrotizing vasculitis of arterioles, capillaries, and venules with few immune deposits necrotizing and crescentic GN (Ozaki; 2007). Granulomatous inflammation and asthma are not seen in MPA (Jennette &Falk, 1997).

Table 3 presents diagnostic criteria for microscopic polyangiitis(Ozaki, 2007).

Allergic granulomatous angiitis (AGA) or Churg-Strauss syndrome(CSS)

Churg and Strauss was firstly described allergic granulomatous angiitis(Churg, & Strauss, 1951). The disease is characterized by presence of asthma, eosinophilia, and necrotizing granulomatous inflammation .Clinical manifestations of small-vessel vasculitis; palpable purpura of the lower extremities, mononeuritis multiplex, abdominal pain, and gastro - intestinal bleeding develop several years after the onset of asthma.Positive MPO-ANCA are seen and skin biopsy shows necrotizing vasculitis of small vessels with massive eosinophilic infiltration and extravascular granulomatosis(Ozaki, 2007). **Table 4** presents diagnostic criteria for CSS(Ozaki, 2007).

1. Symptoms
(1) Rapidly progressive glomerulonephritis
(2) Pulmonary hemorrhage
(3) Other organ symptoms: Purpura, subcutaneous hemorrhage, gastrointestinal bleeding, and mononeuritis multiplex
2. Histological findings
(1) Necrotizing vasculitis of arterioles, capillaries, and ve- nules, and perivascular infiltration of inflammatory cells
3. Laboratory findings
(1) Positive MPO-ANCA
(2) Positive CRP
(3) Proteinuria, hematuria, elevation of BUN and serum creatinine
<Diagnosis>
1. Definite MPA
(1) Positive for 2 or more of the symptoms, and positive histological findings
(2) Positive for 2 or more of the symptoms including the symptoms (1) and (2), and positive MPO-ANCA
2. Probable MPA
(1) Positive for 3 of the symptoms
(2) Positive for 1 of the symptoms, and positive MPO- ANCA

Table 3. Diagnostic criteria for microscopic polyangiitis(Ozaki, 2007)

SLE and AAV

Systemic lupus erythromatosis is an autoimmune disorder .Variety of autoantibodies are present in SLE patients including ANCA which have been reported in 3-69 %of cases(Molnaretal., 2002;Edgar et al., 1995; Pradhan et al., 2004).Some studies(Chinet al., 2000; Nishiyaet al., 1997) have reported p-ANCA in 37.3-42 %of patients with lupus nephritis, mainly those who have diffuse proliferative GN(DPGN), and minority of patients without renal involvement. In Pradhan et al's study predominant ANCA pattern was p-ANCAwhile c-ANCApattern was not found in any patient(Pradhan et al., 2004).Their study revealed that ANCA can be used as a serological marker to differentiate vasculitides in lupus nephritis cases from SLE without nephritis.

-
1. Symptoms
 - (1) Bronchial asthma and/or allergic rhinitis
 - (2) Eosinophilia
 - (3) Symptoms due to vasculitis
 - (a) General symptoms: fever (38°C or higher, 2 weeks or longer), weight loss (6 kg or more for 6 months)
 - (b) Local symptoms: mononeuritis multiplex, gastrointestinal bleeding, purpura, polyarthritis/polyarthralgia, and myalgia (muscle weakness)
 2. Characteristic clinical course
 - (1) Symptoms (1) and (2) precede the development of (3)
 3. Histological findings
 - (1) Granulomatous or necrotizing vasculitis of small vessels with marked infiltration of eosinophils
 - (2) Extravascular granulomas
- <Diagnosis>
1. Definite
 - (1) Positive for 1 or more of the symptoms (1) and (2), and positive for either of the histological findings (Definite AGA)
 - (2) Positive for 3 of the symptoms, and the characteristic clinical course (Definite Churg-Strauss syndrome)
 2. Probable
 - (1) Positive for 1 of the symptoms, and positive for either of the histological findings (Probable AGA)
 - (2) Positive for 3 of the symptoms, but not the characteristic clinical course (Probable Churg-Strauss syndrome)
-

Table 4. Diagnostic criteria for Churg-Strauss syndrome (Ozaki, 2007)

Organ involvement	ANCA serology			Other autoantibodies				
	anti-MPO (12/59)	anti-LF (10/59)	anti-CG (8/59)	ANA (59/59)	anti-dsDNA (45/59)	anti-ssDNA (40/59)	anti-nRNP (38/59)	anti-Sm (16/59)
Skin (50)	4	0	1	48	42	40	38	16
Renal (41)	12	10	8	34	29	28	28	12
DPGN with crescents (21)	5	3	4	19	16	17	15	3
FPGN with crescents (14) *	5	3	2	12	10	10	9	4
RPGN with crescents (4)	2	4	1	2	2	1	2	3
MPGN with crescents (2)	0	0	1	1	1	0	2	2
Joint (35) **	0	6	3	26	18	20	35	12
Serositis (16)	0	6	2	14	14	12	10	10
Haematological (8)	0	0	2	4	4	5	2	2
GI tract (8)	0	0	2	6	6	4	2	2
CNS (8)	0	0	3	3	3	4	2	2

Table 5. Correlation of organ involvement with ANCA serology and other autoantibodies in SLE patients(Pradhan et al., 2004)

Atypical or X-ANCA has been reported among SLE patients by Savige et al, This antibody showing specificities to cathepsin G and lactoferrin (Savige et al., 1996). **Table 5** shows correlation of organ involvement with ANCA serology and other autoantibodies in SLE patients (Pradhan et al., 2004).

6. Treatment of RPGN

Untreated RPGN typically progresses to end-stage renal disease over a period of weeks to a few months. Early diagnosis and initiation of appropriate therapy is essential to minimize the degree of irreversible renal injuries. The therapy of most patients involves pulse methylprednisolone followed by daily oral prednisone, oral or intravenous (IV) cyclophosphamide, and in some cases plasmapheresis. Empiric therapy with IV methylprednisolone should be begun in patients with severe disease with adding of plasmapheresis especially if the patient has hemoptysis (Appel et al., 2010), If a renal biopsy performs soon after initiating empiric therapy the histological abnormalities will not alter.

6.1 Treatment of ANCA associated vasculitis (AAV)

Pauci-immune crescentic glomerulonephritis is a severe form of glomerular inflammation, which if left untreated, usually progresses to end-stage renal failure in weeks or months, AAV is responsible for 80 % of cases (Sakai et al., 2002). The evidence based studies for the management of the AAV is well established and the strategy of induction, consolidation and maintenance therapy is accepted. Guidelines have been designed by both the British Society for Rheumatology (Lapraik et al., 2007) and European league against rheumatism (Mukhtyar et al., 2009) on the management of the AAVs. The AAVs are conventionally treated with a strategy of remission induction followed by maintenance therapy using glucocorticoids combined with cyclophosphamide during induction and azathioprine (AZA) for maintenance (Ntatsaki et al., 2011). Current standard treatment is combination of cyclophosphamide and steroids, but the optimal doses, routes of administration, and duration of therapy remain poorly defined (Hotta, et al., 2005). As immunosuppressive therapies increase the risk of infection, therefore one of the most important aspects of successful treatment strategies should be sufficient attenuation of inflammation without serious immunosuppression which leading to life-threatening infection.

Corticosteroids

For the induction of remission corticosteroid regimen is recommended which includes a daily intravenous pulse of methylprednisolone (15 mg/kg) for 3 days, followed by oral prednisone (1mg/kg/day) for 3 weeks, which then tapered progressively (Pagnoux et al., 2008). In pauci-immune RPGN and MPA usefulness of combination of methylprednisolone pulse therapy for 3 days, oral corticosteroid of 1mg/kg/day for 1 month, and cyclophosphamide of 2 mg/kg/day for 6 to 12 months has been confirmed in several studies (Salama, et al., 2002; Jindal, 1999; Hoffman, 1997; Guillevin et al., 1991).

Cyclophosphamide (CYC)

Different therapeutic agents have been used in treatment of AAV. Standard therapy for AAV is treatment with combination of cyclophosphamide and prednisolone (Pagnoux et al., 2008). After induction with daily oral or pulse intravenous cyclophosphamide therapy, relapse rates of 15% at 12 months (Haubitz et al., 1998), and 38% at 30 months (Guillevin et al., 1997)

have been reported. In long-time follow-up 50 % of patients experience relapse within 5 years (Hoffman et al., 1992). Treatment with cyclophosphamide is effective, but also very toxic (Hoffman et al., 1992). Repeated treatment with cyclophosphamide increases adverse effects. To avoid cyclophosphamide-related toxicity, alternative induction treatments are needed (Stassen et al., 2007).

Mycophenolate mofetil (MMF): MMF is considered as a potent immuno suppressive drug with favorable side effects, so it has been considered as an alternative to cyclophosphamide treatment in patients with AAV (Stassen et al., 2007; Pesavento et al., 1999; Haidinger et al., 2000; Joy et al., 2005; Koukoulaki, & Jayne, 2006). MMF is a drug which usually is well tolerated. In patients with auto-immune diseases such as SLE, MMF is effective in inducing remission with short-term efficacy which is comparable with cyclophosphamide (Chanet et al., 2000, 2005; Ong et al., 2005; Ginzler et al., 2005). Induction treatment with MMF and oral steroids consisted of oral MMF 1000 mg twice daily and oral prednisolone 1 mg/kg once daily (maximum 60 mg). If patients are still in remission after 1 year, MMF is tapered by 500 mg every 3 months and Prednisolone is tapered after 6 weeks by 10 mg every 2 weeks until a dose of 30 mg was reached, and by 5 mg every 2 weeks until 10 mg. Next, the dose is reduced 2.5 mg every month (Stassen et al., 2007). Stassen et al reported that combination of oral steroids and MMF induced complete and partial remission in 78% and 19 % of patients respectively (Stassen et al., 2007). Therefore they suggested oral steroids with MMF in patients with relapses of AAV intolerant to cyclophosphamide therapy. Bone marrow suppression is an uncommon side effect of MMF treatment which can result in anemia, leucocytopenia or thrombocytopenia in a number of patients. Fortunately this side effect responds to temporary dose reduction in nearly all patients (Stassen et al., 2007).

Methotrexate (MTX)

For remission maintenance in patients who are intolerant of AZA or relapse while taking it other alternative agents such as MTX or MMF have been recommended (Ntatsaki et al., 2011). Methotrexate is an alternative drug for cyclophosphamide which is currently studied (De Groot et al., 2005; Sneller et al., 1995; Stone et al., 1999). According to one randomized (De Groot et al., 2005) and two uncontrolled studies (Sneller et al., 1995; Stone et al., 1999) MTX effectively induced remission in 90 % and 71-74 % of patients respectively, but relapses occurred more frequently than when cyclophosphamide was used (70% vs. 47%) (De Groot et al., 2005). MTX is excreted by kidney, therefore should be used with caution in those with renal impairment (Ntatsaki et al., 2011; Metzler et al., 2007).

Groot et al conducted an unblinded, randomized, controlled trial study to determine whether MTX could replace treatment with cyclophosphamide and oral corticosteroids (De Groot et al., 2005). They found that MTX can replace cyclophosphamide for initial treatment of early AAV, but it was less effective for induction of remission in patients with extensive disease or those with pulmonary involvement. In addition the relapse was more common in patients who treated with MTX than those who received cyclophosphamide. Patients were randomized to receive either MTX 7.5 mg/week increasing to 20 mg/week at 8 weeks or LEF loading dose 100 mg/day for 3 days, followed by 20 mg /day until Week 4, then 30 mg/day for 2 years. Their study showed no differences in efficacy or safety between two treatments. Pagnoux et al (Pagnoux et al 2008) compared AZA with MTX in maintaining remission in WG and MPA patients who had achieved remission with intravenous pulse of cyclophosphamide. They found no significant difference in adverse events and relapses rates either during the 12-month treatment phase or subsequent follow-up between two groups.

Intravenous immunoglobulins(IVIG)

ANCAs can induce cytokine-primed neutrophils undergo degranulation and respiratory bursts during which they release toxic oxygen species and lytic enzymes (Falk et al., 1990). Anti-idiotypic antibodies with inhibitory effects on ANCA in vitro have been found in a pooled human gamma globulin preparation (Pall et al., 1994.) Evidence showed that IVIG acts in different phases of the immune response including neutralization of circulating pathogenic antibodies, Fc receptor modulation, blockade or suppression of antibody-dependent cell toxicity, natural killer cell function, auto antibody production and complement activation, and acceleration of neutrophil apoptosis (Kazatchkine & Kaveri, 2001; Tsujimoto et al., 2002).

Beneficial effect of high-dose intravenous immunoglobulin in ANCA-associated vasculitis has been approved by different studies (Ito-Ihara et al., 2006; Tuso et al., 1992; Jayne et al., 1993; Richter et al., 1995). Ito et al evaluated IVIG monotherapy (400 mg/kg/day for 5 days) in AAV patients. Their study showed that IVIG decreased the leukocyte count, C-reactive protein level, Birmingham Vasculitis Activity Score and improved the systemic symptoms (Ito-Ihara et al., 2006). Other studies suggested that IVIG induces remission in 40–82% of patients (Richter et al., 1995; Jayne et al., 1991; Levy et al., 1999; Jayne et al., 2000). IVIG appears to have an important place in the management of ANCA-RPGN, but its indications have not been determined. Because IVIG is an expensive drug additional studies on its cost-effectiveness and rational introduction into clinical practice are needed (Hotta et al., 2005).

Anti-B-cell therapy(Rituximab)

Beneficial effects of Rituximab which is a monoclonal antibody against anti-CD20 have been reported in several case series (Gottenberg et al., 2005; Omdal et al., 2005; Speckset al., 2001), and uncontrolled studies (Eriksson, 2005; Keogh et al., 2005a, 2005b; Smith et al., 2006). The main problem of treatment with rituximab is that relapses commonly occurred after 6–9 months (Keogh et al., 2005a, 2005b; Smith et al., 2006).

Apheresis therapies

Results of clinical trial of apheresis therapies, either plasmapheresis or cytoapheresis in AAV are disappointing. These studies showed no benefit (Glöckner et al., 1988; Cole et al., 1992; Zäuner et al., 2002), benefits just in dialysis dependent patients (Pusey et al., 1991) or benefits on preserving the renal function (Furuta et al., 1998; Hasegawa et al., 2005).

Pusey et al. Found that plasma exchange is of added benefit in dialysis-dependent patients because in patients who were initially dialysis-dependent, renal function was more likely to have recovered when treated with plasma exchange plus drugs rather than drugs alone (Pusey et al., 1991). Report from the European community group suggested that adding plasma exchange to immunosuppressive therapy was not beneficial if there was severe tubular atrophy and fewer than 33 % of the glomeruli were normal (De Lind van Wijngaarden et al., 1998).

In contrast to AAV in anti-GBM RPGN, the beneficial effect of plasma exchange has been well established. It might be attributable to the direct role of anti-GBM antibody in the pathogenesis of anti-GBM antibody RPGN, while in AAV no direct role for ANCA has been established (Hotta et al., 2005). The main advantage of Apheresis therapies is that no severe infectious episodes have been noted (Nagase et al., 1998; Sawada et al., 2003). Japan nationwide survey of RPGN (Yamagata et al., 2004) recommends cytoapheresis in patients with aggressive forms of RPGN (rapid deterioration of renal function like the PR3-ANCA-

associated RPGN, or pulmonary renal syndrome complicated by severe inflammation, or relapses with high MPO-ANCA titer).

Anti-TNF-alpha

Insights into the role of Th1 cytokines in the pathogenesis of WG have led to trial therapies with antagonists of tumor necrosis factor-alpha (TNF α) and inhibitors of monocyte function, such as interleukin-10 (Kamesh et al., 2002). Etanercept (Enbrel; soluble receptors), infliximab (Remicade; human-mouse chimeric antibody against TNF), and adalimumab (Humira; human anti-TNF antibody) are biological antagonists of TNF (Ozaki, 2007). Etanercept have been reported ineffective in maintaining remission and a higher rate of malignancy have been noted in patients who have received the drug (Wegener's granulomatosis etanercept trial [WGET] research group, 2005). In an open label study, infliximab was added to standard immuno suppressive therapy in 16 patients with acute AAV at first presentation or relapse and in 16 with persistent disease despite multiple immuno suppressive regimens, 88% of patients achieved remission within a mean of 6.4 weeks (Booth et al., 2004).

Anti-T cell antibodies: Different studies have been reported that active systemic vasculitis is mediated in part by T cell-induced injury. This finding has led to the evaluation of anti-T cell antibodies in patients with Wegener's granulomatosis who are resistant to cytotoxic therapy (Lockwood et al., 1993; Hagenet al., 1995; Schmitt et al., 2004).

In one study, the administration of a combination of two humanized monoclonal antibodies led to long-lasting remission in four patients with different forms of refractory vasculitis (Lockwood et al., 1993). In other study 15 patients with refractory disease received anti-thymocyte globulin (ATG) which resulted in a partial or complete remission in 9 and 4 patients, respectively (Schmitt et al., 2004). The role of these experimental therapies remains to be determined.

Intravenous azathioprine

High dose intravenous azathioprine has been tested for treating a variety of immune-mediated diseases. In one report, four patients with WG who had not responded to oral cyclophosphamide were treated with monthly infusions of azathioprine (Benenson et al., 2005). Two reached remission of disease, one of whom developed renal involvement during relapse, which responded to retreatment.

15-Deoxyspergualin

15-deoxyspergualin (gusperimus), a drug with anti-proliferative effect on antigen-stimulated B cells, has been evaluated in a small number of patients who didn't respond to cyclophosphamide or had contraindications to the use of cyclophosphamide. The administration of 15-deoxyspergualin in 20 patients resulted in complete or partial remission in six and eight respectively (Bircket al., 2003). All patient experienced transient leucopenia with each treatment cycle. In another study seven patients treated with 15-deoxyspergualin and glucocorticoids, all reached complete or partial remission. The main problem was that to maintain remission prolonged treatment up to 4 years was required (Schmitt et al., 2005). In addition serial monitoring of white blood count is required to avoid excessive leucopenia.

Radiation therapy

Radiation therapy has been evaluated in patients with WG and air way involvement (Eagleton et al., 1979; Neviani et al., 2002). The use of ionizing radiation for non-malignant

disease is controversial. Current data do not support its use in systemic disorder like Wegener's granulomatosis (Stone et al., 2010).

Stem cell transplantation: High-dose, myeloablative chemotherapy with stem cell transplantation has been used for the treatment of refractory severe vasculitis. There are few case reports of successful treatment in patients with WG (Kötter et al., 2005). More studies are required to determine the role of stem cell transplantation in the management of resistant AAV.

Prophylaxis against *Pneumocystis carinii* pneumonia (PCP)

Opportunistic infections especially *Pneumocystis carinii* pneumonia are potentially fatal complications of immunosuppressive therapy in RPGN and AAV. The estimated incidence of PCP is approximately 6 percent (Ognibene et al., 1995). Different approaches to prophylaxis against PCP infection during initial immunosuppressive therapy have been suggested: trimethoprim-sulfamethoxazole one single strength (80 mg/400 mg) tablet daily or one double strength tablet (160 mg/800 mg) three times per week or Atovaquone in patients who are allergic to sulfonamides or do not tolerate trimethoprim-sulfamethoxazole. During treatment with methotrexate and glucocorticoids, the addition of trimethoprim-sulfamethoxazole increases the risk of pancytopenia, therefore Atovaquone is suggested for prophylaxis in such patients. It has been recommended to continue PCP prophylaxis in maintenance immunosuppressive therapy phase until the CD4-positive T cell count exceeds 300/microL (Mansharamani et al., 2000). Patients who have received trimethoprim-sulfamethoxazole for prophylaxis during induction, should continue the prophylaxis when azathioprine is used and switch to atovaquone when methotrexate is replaced for maintenance therapy.

Some patients have low CD4-positive T cell counts for prolonged periods after the cessation of cyclophosphamide and require prolonged PCP prophylaxis; in addition glucocorticoids should be tapered to the lowest possible dose. If patients develop neutropenia when receive prophylaxis, the drug should be switched to atovaquone (Stone et al., 2010).

Management of RPGN and AAV in pregnancy: As with active disease in non-pregnant patients, prednisone alone is relatively ineffective, and to induce remission combined therapy with cyclophosphamide is needed. The major challenges of treatment during pregnancy are potentially serious adverse effects which can occur with both MMF and cyclophosphamide. In addition, insufficient data about the safety of rituximab is available. High risk of skeletal and palatal defects, as well as malformations of the limbs and eyes has been noted in case of fetal cyclophosphamide exposure during the first trimester. Although fetal risk is much smaller during the second and third trimesters, pancytopenia and impaired fetal growth can occur. MMF fetal exposure increases the risk of miscarriage and congenital malformation such as cleft lip and palate. As a result, some consider MMF to be contraindicated in pregnancy. The safer immunosuppressive drugs that have been effective in WG and MPA include glucocorticoids, azathioprine, cyclosporine and tacrolimus. Alternatives that could be considered include cyclophosphamide or rituximab in the second or third trimester once organogenesis is complete (Stone et al., 2010).

6.1.1 Prognosis of RPGN and ANCA associated vasculitis

RPGN If left untreated typically progresses to end-stage renal disease over a period of weeks to a few months. Patients with fewer crescents may present slowly progressive

course (Baldwin et al., 1987). Despite various immuno suppressive therapy protocols mortality of ANCA positive RPGN is still high, and the major cause of death is infectious complications (Booth et al., 2003; De Lind van Wijngaarden et al 1998). Outcome of AAV depends on patient's age, degree of renal impairment at presentation and presence of pulmonary involvement. During the first 6 months of treatment mortality is very high as a result of aggressive course of the disease and toxic effects of early immuno suppressive treatments (Sakai et al 2002; Booth et al., 2003). Although the introduction of steroids and cyclophosphamide pulse therapy have improved the overall mortality of AAV, the 2-year mortality rate is still high (20% in 2-year follow-up) (Booth et al., 2003; Hogan et al., 1996; Falk et al 2000; Franssen et al 2000). Serum creatinine, dialysis dependency, and percentage of non-crescentic glomeruli at diagnosis have been considered as the best predictors of disease outcome (Bajema et al., 1999; Levy et al., 2001; Slot et al., 2003). The prognosis for patients with anti-GBM antibody disease is poor (Hirayama, et al., 2008), and renal survival and mortality rates of 20.9% and 23.3% at 6 months after onset have been reported respectively. Early diagnosis and starting treatment without delay might improve the prognosis (Hirayama, et al., 2008). A large nationwide survey of RPGN in Japan showed that mortality correlates with age, severity of renal dysfunction, presence of pulmonary involvement, and high C-reactive protein level (Sakai et al., 2002). The mortality rate of Japanese patients was higher than in European or American patients because of the high incidence of lethal infection (Hotta et al., 2005).

Japan Nationwide Survey of RPGN noted that 6-month renal and patients' survival for PR3-ANCA-associated RPGN were 88.2% and 92.3% respectively, while for MPO-ANCA they were 69.9% and 74.2% respectively (Yamagata et al., 2005). Patients' survival is very low in MPA if the disease presents as pulmonary renal syndrome (Gallagher et al., 2002; Lauque et al., 2000; Niles et al., 1996). Introduction of immuno suppressive agents considerably has improved the outcome of AAV over the past 30 years. WG and MPA if left untreated have a rapidly progressive and usually fatal course (Ntatsaki et al., 2011). Walton reported a mean survival of 5 months in patients with WG, and mortality rate of 82% and 89% in 1 and 2 year follow-up respectively (Walton, 1958). Standard treatments significantly have improved prognosis in WG and MPA, and some studies have reported 5-year survival rates of 81% for MPA and 87% for WG (Eriksson et al., 2009). In European Vasculitis Study, there was 11.1% mortality at 1 year (Little et al., 2010). High age at presentation, severe renal involvement (high serum creatinine level at presentation), pulmonary involvement, high ESR and high scores of disease activity and damage were poor prognostic factors (Holle et al., 2011).

Suzuki et al.'s study confirmed that ANCA-associated vasculitis is the most serious etiologies of RPGN (Suzuki et al., 2010). In nationwide survey by Yamagata and Koyama (Koyama et al., 2009; Yamagata et al., 2005), and Suzuki's study main causes of patients' death were infectious complications, including DIC which was mainly linked to pneumonia by opportunistic pathogens (Pneumocystis carinii, Candida albicans, and cytomegalovirus). Researchers hope they will find new immuno suppressive drugs with highest efficacy, lowest side effects and high safety during pregnancy to improve patients' survival and quality of life. It's a dream that undoubtedly will be achieved in next years.

7. Conclusion

RPGN is a nephrology emergency which needs special attention. If the disease left untreated typically progresses to end-stage renal disease over a period of weeks to a few

months. When there is a strong clinical suspicion special immuno suppressive treatment should be started as soon as possible (preferably after kidney biopsy). Despite various immuno suppressive therapy protocols mortality of ANCA positive RPGN patients is still high, also prognosis of anti-GBM antibody disease is poor. Actually treatment of RPGN and AAV are serious challenges in nephrology medicine which needs more clinical trial studies in larger groups of patients.

8. Acknowledgement

The author would like to appreciate all authors and researchers whose studies have been applied in this chapter.

9. References

- Koyama, A. Yamagata, K. Makino, H. Arimura, Y. Wada, T. Nitta, K. Nihei, H. Muso, E. Taguma, Y. Shigematsu, H. Sakai, H. Tomino, Y. Matsuo, S. & Japan RPGN Registry Group (2009). A nationwide survey of rapidly progressive glomerulonephritis in Japan :etiology, prognosis and treatment. *Clinical and Experimental Nephrology J*, Vol.13, No.6, (Dec 2009) PP. 633-50, 1342-1751
- Appel, GB. Kaplan, AA. Glasscock, RJ.&Sheridan AM.(2010.)Overview of the classification and treatment of rapidly progressive crescenticglomerulonephritis, In :Up to date, Oct 2010, Available from<www.up o date. com>
- Benenson, E, Fries, JW, Heilig, B, Pollok M, &Rubbert, A .(2005.)High-dose azathioprine pulse therapy as a new treatment option in patients with active Wegener's granulomatosis and lupus nephritis refractory or intolerant to cyclophosphamide . *Clin Rheumatol*, Vol.24, No.3, (Jun 2005), PP.251-7, 0770-3198
- Birck, R .Warnatz, K .Lorenz, HM Choi, M .Haubitz, M .Grünke, M .Peter, HH .Kalden,, JR . Göbel, U .Drexler, JM .Hotta, O.Nowack, R .&van der Woude, FJ .(2003).15-Deoxyspergualin in patients with refractory ANCA-associated systemic vasculitis : a six-month open-label trial to evaluate safety and efficacy . *J Am Soc Nephrol*, Vol. 14, No.2, (February 2003), PP.440-7, 1046-6673
- Bolton WK .&turgill BC.(1989).Methylprednisolone therapy for acute crescentic rapidly progressive glomerulonephritis .*Am J Nephrol*, Vol .9, PP .368-375 .
- Booth, AD. Mike, KA .Aine, B. Ellis, P.Gaskin, G. Neild, GH. Plaisance, M. Pusey, CD.Jayne, DR. & renal research group .(2003).Outcome of ANCA-associatedrenal vasculitis :a 5-year retrospective study .*Am JKidney Dis*, Vol.41, No.4, (Apr 2003), PP.776-84
- Booth, A .Harper, L .Hammad, T. Bacon, P. Griffith, M. Levy, J. Savage, C. Pusey, C. Jayne, D.(2004).Prospective study of TNF alpha blockade with infliximab in anti-neutrophil cytoplasmic antibody-associated systemic vasculitis .*J Am Soc Nephrol*, Vol.15, No.3, (Mar2004) , PP.717, 1046 -6673
- Chan, TM .Tse, KC. Tang, CS. Mok, MY.&Li, FK.(2005) Long-term study of mycophenolatemofetil as continuous induction and maintenance treatment for diffuseproliferative lupus nephritis .*J Am Soc Nephrol*, Vol .16, No, 4, (April 2005), PP .1076-84, 1046-6673

- Chan, TM.Li, FK .Tang, CS. Wong, RW. Fang, GX .&Ji YL .(2000). Efficacy of mycophenolate mofetil in patients with diffuse proliferative lupus nephritis .HongKong-Guangzhou Nephrology Study Group .N Engl J Med, Vol.343, (October2000), PP.156-62
- Chin, HJ. Ahn, C. Lim, CS. Chung, HK .&Lee JG) .(2000) Clinicalimplications of anti-neutrophil cytoplasmic antibody test inlupus nephritis .Am J Nephrol, Vol. 20, No.1, (Jan 2000), PP.57-63, 0250-8095
- Churg, J .& Strauss, L .(1951).Allergic granulomatosis, allergic angiitisand periarteritis nodosa, Am J.Pathol, Vol.27, No, 2, (Apri1951,) PP, 277-301
- Cole, E .Cattran, D .Magil, A. Greenwood, C. Churchill, D. Sutton, D. Clark, W .Morrin, P. Posen, G. Bernstein, K .(1992) .A prospective randomizedtrial of plasma exchange as additive therapy in idiopathic crescenticglomerulonephritis .Am J Kidney Dis, Vol.20, No.3, (Sep1992), PP .230-9
- D'Agati, V. Chander, P .Nash, M .& Mancilla-Jimenez, R. (1986) .Idiopathic microscopic polyarteritis nodosa :ultra structuralobservations on the renal vascular and glomerular lesions .AmJ Kidney Dis, Vol.7, No.1, (Jan1986), PP .95-110
- De Groot, C .Rasmussen, N .Bacon, PA .Cohen Tervaert, JW.Feighery, C .Gregorini, G .Gross, WL.Luqmani, R .& Jayne, DRW .(2005) .Randomized Trial of Cyclophosphamide Versus Methotrexate for Induction of Remission in Early Systemic Antineutrophil Cytoplasmic Antibody-Associated Vasculitis .Arthritis & Rheumatism, Vol .52, No .8, (August 2005), pp .2461-2469, 1529-0131
- De Groot, K. Rasmussen, N.Bacon, PA. Tervaert, JW. Feighery, C.&Gregorini, G, (2005.)Randomized trial of cyclophosphamide versus methotrexate for induction ofremission in early systemic antineutrophil cytoplasmic antibody-associatedvasculitis .Arthritis Rheum, Vol.52, No.8, (August 2005), PP.2461-9, 1529-0131
- De Lind van Wijngaarden, RAF. Hauer, HA.& Wolterbeek, R .(1998 .)Treatment decisions in severe ANCA-associated glomerulonephritis .J Am Soc Nephrol, Vol.16 PP.52A, 1046-6673
- Dickersin, K .Scherer, R .Lefebvre, C .(1994.)Identifying relevant studies for systematic reviews .BMJ, Vol .309, No.6964, (Nov 1994), PP.1286-1291
- Eagleton, LE.Rosher, RB .Hawe, A .&Bilinsky, RT .(1979).Radiation therapy and mechanical dilation of endobronchial obstruction secondary to Wegener's granulomatosis . Chest, Vol.76, No.5, (Nov 1979) , PP.609-10, 0012-3692
- Eriksson, P.(2005) .Nine patients with anti-neutrophil cytoplasmic antibody-positive vasculitis successfully treated with rituximab .J Intern Med, Vol .257, No.6, (Jun2005), PP.540-8, 0954-6820
- Eriksson, P. Jaconsson, L .Lindell, A .Nilsson, JA .&Skogh, T .(2009).Improved outcome in Wegener's granulomatosis andmicroscopic polyangiitis? A retrospective analysis of95 cases in two cohorts .J Intern Med, Vol.265, No.4, (Apr2009,) PP:.496-506, 0954-6820
- Falk, RJ .&Jennette, JC .1988) .Anti-neutrophil cytoplasmic auto antibodies with specificity for myeloperoxidase in patientswith systemic vasculitis and idiopathic necrotizing

- and crescenticglomerulonephritis .N Engl J Med, Vol.318, (June 1988), PP .1651-1657
- Falk, RJ. Nachman, PH .Hogen, SL .&Jennette, JC.(2000). ANCA glomerulonephritisand vasculitis :A Chapel Hill perspective .Semin Nephrol, Vol.20, No.3, (May2000), PP . 233-43
- Falk, RJ .Terrell, RS.Charles, LA .&Jennette, J C .(1990).(nti-neutrophil cytoplasmic antibodies induce neutrophils to degranulate and produceoxygen radicals in vitro . Proc Natl Acad Sci USA, vol .87, No.11, (June1990), PP .4115-19
- Franssen, CFM.Stegeman, CA .&Kallenberg, CG.(2000.)Antiproteinase3-and antimyeloperoxidase-associated vasculitis .KidneyInt, Vol .57, (January 2000), PP.2195-206, 0085-2538
- Furuta, T.Hotta, O. Yusa, N. Horigome, I. Chiba, S .& Taguma Y) .(1998). Lymphocyt apheresis to treat rapidly progressive glomerulonephritis :a randomized comparison with steroid-pulse treatment .Lancet, Vol.352, No.9123, (Jul1998), PP.203-4
- Gallagher, H.Kwan, JTC .&Jayne, DR .(2002).Pulmonary renal syndrome :a 4-year, single-center experience .Am J Kidney Dis, Vol.39, No.1, (Jan 2002), PP.42-47
- Ginzler, EM.Dooley, MA. Aranow, C. Kim, MY .Buyon, J .&Merrill, JT .(2005) Mycophenolate mofetil or intravenous cyclophosphamide for lupus nephritis. N Engl J Med, Vol.353, (Nov 2005), PP.2219-28
- Glöckner, WM. Sieberth, HG .Wichmann, HE. Backes, E.Bambauer, R. Boesken, WH. Bohle, A. Daul, A. Graben, N .& Keller, F .(1988).Plasmaexchange and immuno suppression in rapidly progressiveglomerulonephritis :a controlled, multi-center study . ClinNephrol, Vol.29, No.1, (Jan1988), PP .1-8, 0301-0430
- Goldschmeding, R. van der Schoot, CE .Ten BokkelHuinink, D.Hack, CE. Van den Ende, ME. Kallenberg, CG. von dem Borne, AE.(1989).Wegener's granulomatosis auto antibodiesidentify a novel diisopropylfluorophosphate-binding proteinin the lysosomes of normal human neutrophils .J Clin Invest, Vol .84, No.5, (Nov1989), PP :1577-1587
- Gottenberg, JE.Guillevin, L. Lambotte, O. Combe, B. Allanore, Y .& Cantagrel, A.(2005).Tolerance and short term efficacy of rituximab in 43 patients with systemicautoimmune diseases .Ann Rheum Dis, Vol.64, (November 2004), PP.913-20, 0003-4967
- Guillevin, L. Cohen, P .Gayraud, M.Lhote, F. Jarrousse, B .&Casassus, P .(1999).Churg-Strauss syndrome :Clinical study and long-term follow-up of 96 patients .Medicine, Vol.78, No.1 ,(Jan 1999), PP .26-37
- Guillevin, L. Cordier, JF .Lhote F. Cohen, P. Jarrousse, B. Royer, I. Lesavre, P. Jacquot, C. Bindi, P. Bielefeld, P. Desson, JF. Détrée, F.Dubois, A. Hachulla, E. Hoen, B. Jacomy, D. Seigneuric, C. Lauque, D .(1997).A prospective, multicenter, randomizedtrial comparing steroids and pulse cyclophosphamide versus steroids and oral cyclophosphamide in the treatment of generalized Wegener's granulomatosis .Arthritis Rheum, Vol.40, No.12, (Dec1997), PP.2187-98, 1529-0131
- Guillevin, L. Jarrousse, B .Lok, C. Lhote, F. Jais, JP. Le ThiHuong, Du D .&Bussel, A . (1991).Long-term follow-up after treatmentof polyarteritis nodosa and Churg-

- Strauss angitis with comparison of steroids, plasma exchange and cyclophosphamide to steroids and plasma exchange .A prospective randomized trial of 71 patients .The cooperative study group for polyarteritis nodosa . *J Rheum*, Vol.18, No.4, (pr1991), PP .567-574, 1462-0324
- Haas, M .&Eustace, J .(2004). Immune complex deposits in ANCA-associated crescentic glomerulonephritis :A study of 126 cases .*Kidney International*, Vol .65, (January 2004), pp .2145-2152, 0085-2538
- Jennette, JC .(2003).Rapidly progressive glomerulonephritis.*KidneyInt*, Vol.63, PP.1164-1177, 0085-2538
- Hagen, EC .De Keizer, RJ .Andrassy, K.van Boven, WP. Bruijn, JA.vanes, LA .& van der Woude FJ.(1995) Compassionate treatment of Wegener's granulomatosis with rabbit anti-thymocyte globulin .*Clin Nephrol*, Vol. 43No.6, (Jun 1995) , PP.351-9, 0301-0430
- Haidinger, M .Neumann, I .Grutzmacher, H. Bayer, P .&Meisl, FTh.(2000). Myco phenolate mofetil (MMF)treatment of ANCA-associated small-vessel vasculitis :a pharmacokinetically controlled study .*Clin Exp Immunol*, Vol.120, No. 1, PP .72
- Harris, Jennette AA .Falk, RJ .& JC .(1998).Crescentic glomerulonephritis with a paucity of glomerular immunoglobulin localization.*Am J Kidney Dis*, vol.32, No.1, (Jul 1998) , PP.179-184
- Hasegawa, M.Watanabe, A.Takahashi, H. Takahashi, K. Kasugai, M.Kawamura, N.Kushimoto, H. Murakami, K. Tomita, M.Nabeshima, K. Oohashi, A. Kondou, F.Ooshima H.Hiki, Y .& Sugiyama, S .(2005).Treatment with cytoapheresis for antineutrophil cytoplasmic anti-body associated renal vasculitis and its effect on anti-inflammatory factors .*Ther Apher Dial*, Vol.9, No.4, (Aug2005), PP.297-302, 1477-9979
- Haubitz, M. Schellong, S .Göbel, U. Schurek, HJ. Schaumann, D.Koch, KM. &Brunkhorst, R .(1998).Intravenous pulse administration of cyclophosphamide versus daily oral treatment in patients with antineutrophil cytoplasmic antibody-associated vasculitis and renal involvement :a prospective, randomized study .*Arthritis Rheum*, Vol .41, No.10, (Oct1998), PP.1835-44, 1529-0131
- Hauer, HA.Bajema, IM .Van houwelingen, HC. Ferrario, F .Noël, LH .Waldherr, R .Jayne, DRW. Rasmussen, N. Bruijn, JA .& Hagen, EC .(2002).Renal histology in ANCA-associated vasculitis :Differences between diagnostic and serologic subgroups . *Kidney Int* Vol.61, (August 2001), PP:.80-89, 0085-2538
- Hoffman, GS .(1997).Treatment of Wegener's granulomatosis :time to change the standard of care? *Arthritis Rheum*, Vol.40, No.12, (Dec 1997), PP .2099-2104, 1529-0131
- Hoffman, GS. Kerr, GS. Leavitt, RY. Hallahan, CW .Lebovics, RS .&Travis, WD . (1992)()Wegener granulomatosis :an analysis of 158 patients .*Ann Intern Med*, Vol.16, No.6, (March1992), PP.488-98, 0003-4819
- Hogan, SL. Nachman, PH. Wilkman, AS.Jennette, JC .& Falk, RJ .(1996).Prognostic markers in patients with antineutrophil cytoplasmic autoantibody associated microscopic polyangitis and glomerulonephritis . *J Am Soc Nephrol*, Vol.7, No.1, (Jan 1996) , PP .23-32, 1046-6673

- Hogan, SL.Nachman, PH.Wilkman, AS. Jennette, JC .&Falk, RJ .(1996).Prognostic markers in patients with antineutrophil cytoplasmic autoantibody-associated microscopic polyangiitis and glomerulonephritis . *J Am Soc Nephrol*, Vol. 7, No.1, (Jan 1996), PP.23-32, 1046-6673
- Holle, JU .Gross, WL.Latza, U.Nölle, B .Ambrosch, P .Heller, M .Fertmann, R .&Reinhold-Keller, E .(2011).Improved outcome of 445 Wegener's granulomatosis patients in a German vasculitis centre over four decades . *Arthritis Rheum*, Vol.63, No.1, (Jan 2011), PP .257-66, 1529-0131
- Hotta, S. Ishida, A. Kimura, T. & Taguma, Y.(2005) .Improvements in treatment strategies for patients with antineutrophil cytoplasmic antibody-associated rapidly progressive glomerulonephritis . *Therapeutic apheresis and dialysis*, Vol .10, No.5, (November 2005), PP.390-395, 1744-9979
- Ito-Ihara, T. Ono, T .Nogaki, F. Suyama, K. Tanaka, M. Yonemoto, S. Fukatsu, A. Kita, T. Suzuki, K. & Muso E.(2006).Clinical efficacy of intravenous immunoglobulin for patients with MPO-ANCA associated rapidly progressive glomerulonephritis . *Nephron Clin Pract*, Vol. 102, No.1, (Sep 2005), PP .c35-c42, 1660-2110
- Tuso, P. Moudgil, A. Hay, J. Goodman, D. Kamil, E. Koyyana, R. & Jordan, SC . (1992).Treatment of antineutrophil cytoplasmic autoantibody-positive systemic vasculitis and glomerulonephritis with pooled intravenous gamma globulin . *Am J Kidney Dis*, Vol.20 ,No.5, (Nov 1992), PP.504-8
- Jayne, DR. Davies, M. Fox, CJ. Black, CM. & Lockwood, CM .(1991).Treatment of systemic vasculitis with pooled intravenous immunoglobulin . *Lancet*, Vol.337, No.8750, PP.1137-9
- Jayne, DR. Esnault, VL .&Lockwood CM .(1993).ANCA anti-idiotypic antibodies and the treatment of systemic vasculitis with intravenous immunoglobulin . *J Autoimmun*, Vol .6, No.2, (Apr 1993), PP .207-19, 0896-8411
- Jayne, DR. W. Chapel, H. Adu, D. Misbah, S. O'Donoghue, D. & Scott D(2000).Intravenous immunoglobulin for ANCA-associated systemic vasculitis with persistent disease activity . *QJM*, vol.93, No.7, (May 2000), PP.433-9, 1460-2725
- Jennette, JC .&Falk, RJ .(1998) .Pathogenesis of the vascular and glomerular damage in ANCA-positive vasculitis . *Nephrol Dial Transplant*, Vol.13, No.1, PP.6-20, 0931-0509
- Jennette, JC .&Falk, RJ .(1997).Small-vessel vasculitis . *N Engl J ed.*, Vol .337, No.21, (November 1997), PP.1512-23
- Jennette, JC. Thomas, DB(2001).(rescentic glomerulonephritis. *Nephrol Dial Transplant*, Vol. 16, No.6, PP.80-82,, 0931-0509
- Jennette, JC .Wilkman, AS .&Falk RJ.(1989).Anti-neutrophil cytoplasmic autoantibody-associated glomerulonephritis and vasculitis. *Am J Pathol*, Vol.135, No.5,)Nov 1989,(PP.921-930
- Jennette, J .& Falk, R .(2003).Renal and systemic vasculitis, In : *Comprehensive clinical nephrology*,)second ed ,(edited by Johnson, R .Feehally, J, PP .341-357 Mosby, 0723432589, Retrieved from <www.google.com>

- Jindal, KK .(1999) .Management of idiopathic crescentic and diffuse proliferative glomerulonephritis :evidence-based recommendations .*Kidney Int*, Vol.55, No.70, PP .S33-40, 0085-2538.
- Joy, MS. Hogan, SL .Jennette, JC .Falk, RJ .&Nachman, PH .(2005).A pilot study usingmycophenolate mofetil in relapsing or resistant ANCA small vessel vasculitis . *Nephrol Dial Transplant*, Vol.20, No.12, (Sep 2005), pp .2725-32, 0931-0509
- Kamesh, L .Harper, L.&Savage, CO .(2002) .ANCA-positive vasculitis . *J Am Soc Nephrol*, Vol.13, No.7, (July 2002), PP .1953, 1046-6673
- Kazatchkine, MD.&Kaveri, SV.(2001).Immuno modulation of autoimmune and inflammatory diseases with intravenous immunoglobulin .*N Engl J Med*, Vol.345, No.10, (Sep 2001), PP.747-55
- Keogh, KA. Wylam, ME.Stone, JH.& Specks, U.(2005) .Induction of remission by B lymphocyte depletion in eleven patients with refractory antineutrophil cytoplasmic antibody-associated vasculitis .*Arthritis Rheum*, Vol .52, No.1, (Jan2005), PP .262-8, 1529-0131
- Keogh, KA. Ytterberg, SR .Fervenza, FC. Carlson, KA. Schroeder, DR .&Specks U . (2006).Rituximab for refractory Wegener’s granulomatosis :report of a prospective, open-label pilot trial .*Am J Respir Crit Care Med*, Vol .173, No.2, (October 2005), PP .180-7
- Kötter, I.Daikeler, T .Amberger, C.Tyndall, A.& Kanz, L.(2005).Autologous stem cell transplantation of treatment-resistant systemic vasculitis--a single center experience and review of the literature .*Clin Nephrol*, Vol. .64, No.6, (Dec 2005), PP.485-9, 0301-0430
- Koukoulaki, M.& Jayne, DR .(2006).Mycophenolate mofetil in anti-neutrophil cytoplasmantibodies-associated systemic vasculitis .*Nephron Clin Pract*, Vol.102, No.3-4, (November 2005) PP.c100-7, 1660-2110
- Koyama, A.. Yamagata, K. Makino, H. Arimura, Y. Wada, T. Nitta, K.Nihei, H. Muso, E .. Taguma, Y. Shigematsu, H.Sakai, H. Tomino, Y. Matsuo, S. & Japan RPGN Registry Group) .2009.(Nationwide survey of rapidly progressive glomerulonephritis in Japan :etiology, prognosis and treatment diversity .*Clinical and Experimental Nephrology J*, Vol. 13, No.6,)Dec 2009), PP .633-50, 1342-1751
- Lapraik, C. Watts, R .Bacon, P.Carruthers, D .Chakravarty, K. D’Cruz, D. Guillevin, L.Harper, L .Jayne, D .Luqmani, R .Mooney, J .Scott, D.(2007).BSR & BHRP guidelines for the management of adults with ANCA associated vasculitis . *Rheumatology*, Vol.46, (April 2007,) PP1-11, 1462-0324
- Lauque, D. Cadranel, J. Lazor, R. Pourrat, J. Ronco, P. Guillevin, L .&Cordier, JF . (2000).Microscopic polyangiitis with alveolarhemorrhage .A study of 29 cases and review of the literature.*Medicine*. Baltimore, Vol.79, No.4, (Jul2000), PP .222-233
- Levy, JB.&Winearls, CG .(1994).Rapidly progressive glomerulonephritis :what should be first-line therapy? *Nephron*, Vol 67, No.4, PP.402-407, 0028-2766
- Jayne, DR.Chapel, H .Adu, D .Misbah, S .O’Donoghue, D .Scott, D .& Lockwood CM . (2000.)Intravenous immunoglobulin for ANCA-associated systemic vasculitis with persistent disease activity .*QJM*, Vol.93, No.7, (Jul2000), PP.433-439

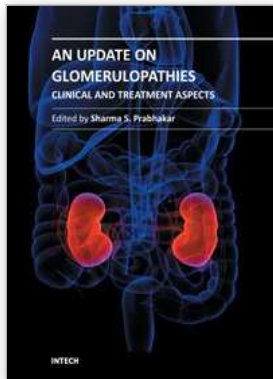
- Levy, Y. Sherer, Y .George, J. Langevitz, P. Ahmed, A .& Bar-Dayana, Y .(1999) .Serologic and clinical response to treatment of systemic vasculitis and associated autoimmune disease with intravenous immunoglobulin .*Int Arch Allergy Immunol*, Vol.119, No.3, (Jul 1999)PP.231-8, 1018-2438
- Lionaki, S. Jennette, JC.&Falk, RJ .(2007). Anti-neutrophil cytoplasmic (ANCA) and anti-glomerular basement membrane (GBM) auto antibodies in necrotizing and crescentic glomerulonephritis.*Semin Immunopathol*, Vol.29, No .4 ,(Nov2007), PP.459-474, 1863-2297
- Little, MA. Nightingale, P. Verburgh, CA.Hauser, T. De Groot, K. Savage, C. Jayne, D. Harper, L .(2010)Early mortality in systemic vasculitis :relative contribution of adverse events and active vasculitis .*Ann Rheum Dis*, Vol.69, No.6, (Jun2010), PP. 1036-43, 0003-4967
- Lockwood, CM .Thiru, S .&Isaacs, JD. Hale, G. Waldmann, H.(1993) .Long-term remission of intractable systemic vasculitis with monoclonal antibody therapy .*Lancet*, Vol. 341, No.8861, (Jun1993), PP.1620-2
- Mansharamani, NG. Garland, R.Delaney, D .&Koziel, H .(2000).Management and outcome patterns for adult *Pneumocystis carinii* pneumonia, 1985 to 1995 :comparison of HIV-associated cases to other immunocompromised states .*Chest*, Vol.118, No.3, (Sep2000), PP.704-711, 0012-3692
- Metzler, C. Miehle, N. Manger, K .Iking-Konert, C . .De Groot, K.Hellmich, B . .Gross, WL . .& Reinhold-Keller, E .(2007) .Levated relapse rate under oral methotrexate versus leflunomide for maintenance of remission in Wegener's granulomatosis. *Rheumatology*, Vol .46, No .7, (January 2007), PP .1087-91, 1462-0324
- Molnar, K. Kovacs, L. Kiss, M.Husz, S. Dobozy, A .&Pokoerny, G .(2002) .Anti-neutrophil cytoplasmic antibodies in patients with systemic lupus erythematosus .*Clin Exp Dermatol*, Vol. 27, No.1, (Jan2002), PP.56-61, 0307-6938
- Edgar, JD. Mc Millan, SA. Bruce, IN .&Conlan SK .(1995) .An audit of ANCA in routine clinical practice .*Postgrad Med J*, Vol .71, N., 840(Oct1995), PP .605-12, 0032-5473
- Mukhtyar, C. Guillevin, L.Cid, M. Dasgupta, B. De Groot, K. GrossW, Hauser, T . Hellmich, B. Jayne, D. Kallenberg, C G M. Merkel, P A . Raspe, H . Salvarani, C . Scott, DGI Stegeman, C. Watts, R .Westman., K .Witter, J .Yazici, H & Luqmani, R.(2009).EULAR recommendations for the management of primary small and medium vasculitis .*Ann Rheum Dis*, Vol.68, No.3, (March 2009),, PP .310-7, 0003-4967
- Mukhtyar, C.Flossmann, O.Hellmich, B.Bacon, P.Cid, M .&Cohen-Terrvaretm, JW(.2008) . Outcomes from studies of antineutrophil cytoplasm antibody associated vasculitis : a systematic review by the European League against rheumatism systemic vasculitis task force. *Ann Rheum Dis*, Vol.6, No.7, (Jul2008), PP .1004-1010, 0003-4967
- Nagase, K. Sawada, K .Ohnishi, K.Egashira, A. Ohkusu, K .& Shimoyama T . (1998).Complications of leukocytapheresis.*Ther Apher*, Vol.2, No.2, (May1998), PP . 120-4

- Naseri, M. & Zabolinejad, N.(2008).ANCA-Negative Pulmonary-Renal Syndrome with Pathologic Findings Suggesting Thrombotic Thrombocytopenic Purpura.Iran J Ped, Vol.17, No.1, (March 2007), PP.63-8, 2008-2114
- Neviani, CB .Carvalho Hde, A .Hossamu, C.Aisen, S.& Nadalin, W.(2002) .Radiation therapy as an option for upper airway obstruction due to Wegener's granulomatosis . Otolaryngol Head Neck Surg, Vol. 126, No.2, (Feb2002), PP.195-6, 0194-5998
- Niles, JL .Bottinger, EP. Saurina, GR. Kelly, KJ. Pan, G. Collins, AB .&McCluskey, RT . (1996).The syndrome of lung hemorrhage andnephritis is usually an ANCA-associated condition .Arch InternMed, Vol.156, No.4, PP. 440-445
- Niles, JL. McCluskey, RT .Ahmad, MF.& Arnaout MA.(1989).Wegener's granulomatosis auto antigen is a novel serineproteinase .Blood, Vol .74, No. .6, (Nov 1989), PP.1888-1893, 0006-4971
- Nishiya, K. Chikazawa, H.Nishimura, S.Hisakawa, N.&Hashimoto K .(1997).Anti-neutrophil cytoplasmic antibody inpatients with systemic lupus erythematosus is unrelated toclinical features .Clin Rheumatol, Vol.16, No.1, (Jan 1997), PP.70-5, 0770-3198
- Ntatsaki, E. Mooney, J .&Watts, RA) .2011 .(ANCA vasculitis :time for a change in treatment paradigm? Not yet.Rheumatology, Vol.50, No.2, (February 2011), PP.1-6, 1462-0324
- Ntatsaki, E..Watts, RA .& Scott, DGI.(2010).Epidemiology ofANCA-associated vasculitis . Rheum Dis Clin North Am, Vol.36, No.3 ,(Aug2010), PP .447-61
- Ognibene, FP .Shelhamer, JH.Hoffman, GS .Kerr, GS .Reda, D .Fauci, AS .& Leavitt, RY. (1995) .Pneumocystis carinii pneumonia :a major complication of immunosuppressive therapy in patients with Wegener's granulomatosis .Am J Respir Crit Care Med, Vol .151, No.3, (Mar 1995), PP .795-799
- Omdal, R. Wildhagen, K. Hansen, T. Gunnarsson, R.& Kristoffersen, G .(2005) .Anti-CD20therapy of treatment-resistant Wegener's granulomatosis :favourable buttemporary response .Scand J Rheumatol, vol.34, No.3, (2005 May), PP.229-32, 0300-9742
- Ong ,LM.Hooi, LS .Lim, TO. Goh, BL. Ahmad, G .&Ghazalli, R.(2005) . Randomized controlled trial of pulse intravenous cyclophosphamide versus mycophenolatemofetil in the induction therapy of proliferative lupus nephritis . Nephrology(Carlton), Vol.10, No.5, (Oct2005), PP.504-10, 1320-5358
- Pagnoux, C. Mahr, A .Hamidou, MA .Boffa, JJ. Ruivard, M. Ducroix, JP. Kyndt, X. Lifermann, F. Papo, T. Lambert, M. Noach, JL. Khellaf, M. Merrien, D .Puechal, X . Vinzio, S.Cohen, P. Mouthon, L .Cordier, JF .&Guillevin, L .(2008). Azathioprine or Methotrexate Maintenancefor ANCA-Associated Vasculitis .N Engl J Med, Vol.359, No.26, (December 2008), PP.2790-803
- Pagnoux, C.Mahr, A .Hamidou, MA. Boffa, JJ .Mouthon, L .Cordier, JF.Guillevin, L .&French Vasculitis Study Group .(2008).Azathioprineor methotrexate maintenance for ANCA-associatedvasculitis .N Engl J Med, Vol .359, No.26, (December 2008), PP.2790-803
- Pall, AA. Varaganam, M .Adu, D, Smith, N .Richards, N T .Taylor, C M .& J Michael . (1994.)Anti-idiotypic activityagainst anti-myeloperoxidase antibodies in pooled

- humanimmunoglobulin .*Clin Exp Immunol*, Vol.95, No.2, (February1994), PP.257-62
- Pesavento, T. Falkenhain, M.Rovin, B.&Hebert, L.(1999) .Mycophenolate mofetil therapy (MMF) in anti-neutrophil cytoplasmic antibody (ANCA) vasculitis .*J Am Soc Nephrol*, Vol.10, PP.114A, 1046-6673
- Pradhan, VD. Badakere, SS .Bichile, LS .&Almeida, AF.(2004)(Anti-neutrophil Cytoplasmic Antibodies (ANCA) in Systemic Lupus Erythematosus :Prevalence, clinical associations and correlation with otherauto antibodies, *JAPI*, Vol .52, (July 2004), PP.533-7
- Pusey, CD. Rees, AJ .Evans, DJ..Peters, D K.& Lockwood, C M.(1991).(Plasma exchange in focalnecrotizing glomerulonephritis without anti-GBM antibodies. *Kidney Int*, Vol.40, (May 1991), PP .757-63, 0085-2538
- Richter, C. Schnabel, A. Csernok, E .De Groot, K. Reinhold-Keller, E.& Gross, WL .(1995) . Treatment of anti-neutrophil cytoplasmic antibody (ANCA)- associated systemic Vasculitis with high-dose intravenous immunoglobulin .*Clin Exp Immunol*, Vol.101, No.1, (July 1995), PP.2-7
- Richter, C. Schnael, A. Csernok, E. De Groot, K .Reinhold-Keller, E .& Gross, W L .(1995) . Treatment of antineutrophilcytoplasmic antibody (ANCA)associated systemicvasculitis with high-dose intravenous immunoglobulin .*Clin Exp Immunol*, Vol.101, No.1, (July 1995), PP.2-7
- Rondeau, E.Levy, M .Dosquet, P .Ruedin, P .Mougenot, B .Kanfer, A.& Sraer, JD. (1989 .) Plasma exchange and immunosuppression for rapidly progressive glomerulonephritis :prognosis and complications .*Nephrol Dial Transplant*, Vol.4, No.3, PP. 4:196-200, 0931-0509
- Sakai, H .Kurokawa, K .Koyama, A. Arimura, Y. Kida, H. Shigematsu, H. Suzuki, S. Nihei, H. Makino, H. Ueda, N.Kawamura, T. Gejyo, F.Saito, T.Harada, T. Hiki, Y .& Yoshida, M.(2002) .Guideline for management ofrapidly progressive glomerulonephritis in Japan .*Jpn J Nephrol*, Vol.44, No .2, (Mar 2002), PP.55-82, o385—2385
- Salama, AD .Dougan, T .Levy, JB .Cook HT.Morgan, SH .Naudeer, S .Maidment, G .George, AJT.Evans, D .Lightstone, L .& Pusey, CD.(2002).Goodpasture's Disease in the Absence of Circulating Anti-Glomerular Basement Membrane Antibodies as Detected by Standard Techniques .*American Journal of Kidney Diseases*, Vol. 39, No, (June 2002), pp .1162-1167
- Savage, CO .Harper, L .&Adu, D .(1997.)Primary systemic vasculitis .*Lancet*, Vol.349, No.9051, (Feb1997), PP.553-558
- Savige, JA. Chang, L. Wilson, D .& Buchanan, RR .(1996).Auto antibodiesand target antigens in anti-neutrophil cytoplasmic antibody (ANCA) associated vasculitides . *Rheumatol Int*, Vol. 16, No .3, PP.109-14, 0172-8172
- Sawada, K.Muto, TShimoyama, T. Satomi, M. Sawada, T.Nagawa, H. Hiwatashi, N . Asakura, H. .&Hibi, T. (2003).Multicenter randomizedcontrolled trial for the treatment of ulcerative colitis withleukocytapheresis column .*Curr Pharm Des*, Vol.9, No.4, PP .307-21, 1381-6128

- Schmitt, WH .Birck, R .& Heinzl, PA.(2005.)Prolonged treatment of refractory Wegener's granulomatosis with 15-deoxyspergualin :an open study in seven patients .Nephrol Dial Transplant, Vol.20, No.6, (Jun2005), PP.1083-92, 0931-0509
- Schmitt, WH .Hagen, EC.&Neumann, I.Nowack, R.Flores-Suárez, LF.van der Woude, FJ.(2004) .Treatment of refractory Wegener's granulomatosis with antithymocyte globulin (ATG) :(an open study in 15 patients .Kidney Int, Vol.65, No.4, (Apr2004), PP.1440-8, 0085-2538
- Seo, P.& Stone, JH.(2004).The antineutrophil cytoplasmic antibody-associated vasculitides.Am J Med, Vol.117, No.1, (Jul2004 I), PP.39-50
- Smith, KG. Jones, RB. Burns, SM.&Jayne, DR .(2006).Long-term comparison of rituximab treatment for refractory systemic lupus erythematosus and vasculitis :remission, relapse and re-treatment .Arthritis Rheum, vol .54, No.9, (Sep2006), PP.2970-82, 1529-0131
- Sneller, MC. Hoffman, GS. Talar-Williams, C. Kerr, GS .Hallahan, CW.& Fauci AS(.1995).An analysis of forty-two Wegener's granulomatosis patients treated with methotrexate and prednisone .Arthritis Rheum, Vol .38, No.5, (May1995), PP.608-13, 1529 -0131
- Specks, U. Fervenza, FC. McDonald, TJ.& Hogan, MC.(2001) .Response of Wegener's granulomatosis to anti-CD20 chimeric monoclonal antibody therapy . ArthritisRheum, Vol.44, No.12, (Dec 2001), PP.2836-40, 1529-0131
- Stassen, PM. Cohen Tervaert, JW .& Stegeman, CA .(2007).Induction of remission in active anti-neutrophil cytoplasmic antibody-associated vasculitis with mycophenolate mofetil inpatients who cannot be treated with cyclophosphamide .Ann Rheum Dis, Vol.66, No.6, (December2006), PP .798-802, 0003-4967
- Stone, JH . Kaplan, AA . Falk, RJ. Appel, GB .& Sheridan, AM .(2010).Initial immunosuppressive therapy in Wegener's granulomatosis and microscopic polyangiitis.In : Up to date, Oct 2010, Available from :< www.up to date. com>
- Stone, JH. Tun, W .&Hellman, DB .(1999.)Treatment of non-life threatening Wegener'sgranulomatosis with methotrexate and daily prednisone as the initial therapy ofchoice .J Rheumatol, vol.26, No.5, (May1999), PP .1134-9, 1462-0324
- Stone, JH. Falk, RJ. Glassock, RJ. Appel, GB. & Sheridan, AM.(2010).Treatment of cyclophosphamide-resistant Wegener's granulomatosis and microscopic polyangiitis .In :Up to date, Oct 2010, Available from :< www.up to date.com>
- Suzuki, Y .Takeda, Y .Sato, D .Kanaguchi, Y .Tanaka, Y .Kobayashi, S .Suzuki, K .Hashimoto, H.Ozaki, S .Horikoshi, S .& Tomino, Y.(2010).Clinico epidemiological manifestations of RPGN and ANCA-associated vasculitides :an 11-year retrospective hospital-based study in Japan .Mod Rheumatol, Vol.20, No.1, (Feb 2010), PP .54-62, 1439-7595
- The Wegener's Granulomatosis Etanercept Trial [WGET]Research Group .(2005 .).Etanercept plus standard therapy for Wegener's granulomatosis .N Engl J Med, Vol. 352, No.4, (Jan 2005), PP.351-36
- Tsujimoto, H .Takeshita, S .Nakatani, K.Kawamura, Y. Tokutomi, T .& Sekine, I .(2002) . Intravenous immunoglobulintherapy induces neutrophils apoptosis in Kawasaki disease .Clin Immunol, Vol.103, No.2, (May 2002), PP.161-8, 0271-9142

- Vizjak, A.Rott, T .Koselj-kajtna, M.Rozman, B. Kaplan-Pavlovic, SA .&Ferluga, DA. (2003 .) Histology and immunohistologic study and clinical presentationof anca-associated glomerulonephrits with correlatioonto ANCA antigen specificity.American Journal of Kidney Diseases, Vol. 41, No. 3, (November, 2002), pp. 539-549
- Walters, GD .Willis, NS .& Craig, GC .(2010.)Interventions for renal vasculitis in adults .A systematic review .BMC Nephrology, Vol.11, (June 2010), PP.12, 1471-2369
- Walton, EW.(1958) .Giant cell granuloma of the respiratory tract.Br J Med, Vol .2, No .5091, (August1958), PP.265-270
- Wegener's granulomatosis etanercept trial [WGET]research group .(2005.) Etanercept plus standard therapy for Wegener's granulomatosis .N Engl J Med, Vol.352, No.4, (January 2005), PP.351-361
- Yamagata, K .Hirayama, K. Mase, K. Yamaguchi, N. Kobayashi, M .Takahashi, H .& Koyama, A).(2004)(Apheresis for MPO-ANCA-AssociatedRPGN-Indications and Efficacy: Lessons Learned from Japan Nationwide Survey of RPGN .Journal of Clinical Apheresis, Vol .20, No.4, (December 2005), PP.244–251, 0733-2459
- Zäuner, I. Bach, D.Braun, N. Krämer, BK. Fünfstück, R. Helmchen, U. Schollmeyer, P . & Böhler, J.(2002). Predictive value of initialhistology and effect of plasmapheresis on long-term prognosisof rapidly progressive glomerulonephritis .Am J Kidney Dis, Vol.39, No.1, (Jan 2002), PP .28–35



An Update on Glomerulopathies - Clinical and Treatment Aspects

Edited by Prof. Sharma Prabhakar

ISBN 978-953-307-673-7

Hard cover, 468 pages

Publisher InTech

Published online 02, November, 2011

Published in print edition November, 2011

An Update on Glomerulopathies - Clinical and Treatment Aspects is a systemic overview of recent advances in clinical aspects and therapeutic options in major syndromes of glomerular pathology. The book contains twenty four chapters divided conveniently into five sections. The first section deals with primary glomerulopathies, and the second section is devoted to glomerulopathies complicating infectious conditions. The third section deals with systemic autoimmune disorders and vasculitides which constitute major causes of glomerular disease and often renal failure. The fourth section includes chapters discussing the glomerular involvement in some major metabolic and systemic conditions. The final section has chapters which relate to some general aspects of glomerular diseases. This book will form an excellent reference tool for practicing and academic nephrology community.

How to reference

In order to correctly reference this scholarly work, feel free to copy and paste the following:

Mitra Naseri (2011). RPGN - Clinical Features, Treatment and Prognosis, An Update on Glomerulopathies - Clinical and Treatment Aspects, Prof. Sharma Prabhakar (Ed.), ISBN: 978-953-307-673-7, InTech, Available from: <http://www.intechopen.com/books/an-update-on-glomerulopathies-clinical-and-treatment-aspects/rpgn-clinical-features-treatment-and-prognosis>

INTECH

open science | open minds

InTech Europe

University Campus STeP Ri
Slavka Krautzeka 83/A
51000 Rijeka, Croatia
Phone: +385 (51) 770 447
Fax: +385 (51) 686 166
www.intechopen.com

InTech China

Unit 405, Office Block, Hotel Equatorial Shanghai
No.65, Yan An Road (West), Shanghai, 200040, China
中国上海市延安西路65号上海国际贵都大饭店办公楼405单元
Phone: +86-21-62489820
Fax: +86-21-62489821

© 2011 The Author(s). Licensee IntechOpen. This is an open access article distributed under the terms of the [Creative Commons Attribution 3.0 License](#), which permits unrestricted use, distribution, and reproduction in any medium, provided the original work is properly cited.