

Ultrasound-Guided Peripheral Nerve Block in the Anesthetic Considerations for Vascular Surgery – An Alternative Choice for Neuroaxial Anesthesia Techniques

Yusuke Asakura¹ and Hideki Takagi²

¹Department of Anesthesiology,

²Department of Orthopedic Surgery,

*Nagoya Kyoritsu Hospital, Nagoya,
Japan*

1. Introduction

Abdominal aortic aneurysm, with its incidence approaching approximately 8% in the population, accounts for more than 8,000 deaths annually in the United States. It is a multifactorial disease associated with atherosclerosis. Age, male gender, smoking, and the family history of abdominal aortic aneurysm are thought to be the risk factors for the disease (Ashton et al., 2002, Fleming et al., 2005). The natural history of abdominal aortic aneurysm is characterized by the progressive enlargement of the aneurysm, which ultimately leads to the rupture and the subsequent death of the patient.

The aorta wall consists of a thin intima, a thick tunica media, and an adventitia, composed of endothelium for a thin intima, smooth muscle layers for a thick tunica media, and a connective tissue including the vasa vasorum and nervi vascularis for the adventitia, respectively. The wall of aorta is particularly vulnerable to an injury owing to the continuous exposure to high pulsate blood pressure and shear stress. Once degenerated which most commonly occurs by atherosclerosis, cystic medial necrosis, a condition in which the collagen and elastic fibers in the tunica media of the aorta are degenerated and replaced by the mucoid connective tissues, will immediately take place. It will subsequently result in the circumferential weakness, dilatation, and as a consequence, the development of aneurysm. The other etiological conditions that lead to the development of aneurysm include some hereditary basis such as Marfan's and Ehlers-Dnlos syndromes, the infection including syphilis and tuberculosis, and vasculitis associated with autoimmune diseases such as Takayasu's arteritis and rheumatoid arthritis (White et al., 1993, Shah et al., 1997).

The prognosis of abdominal aortic aneurysm is strongly correlated with the size of aneurysm, and the risk of rupture is 1-2% for 5 years for an aneurysm less than 5cm in diameter, whereas it is more than 20-40% for those more than 5cm in diameter. Hence, an elective operation is indicated if the diameter of aneurysm is >5.5cm (Sakalihan et al., 2005).

2. Treatment options for abdominal aortic aneurysm: Endovascular abdominal aortic aneurysm repair (EVAR)

Traditionally, abdominal aortic aneurysm had been treated with prophylactic open surgical repair, which usually had required the surgical procedure consisting of the cross-clamping of the aorta for more than 30 minutes. It exerted a profound impact on the peri-operative mortality of those with pre-existing impaired ventricular function and reduced coronary reserve through the increases in arterial blood pressure, systemic vascular resistance, and the reduction of cardiac output. In addition, ischemic complications may subsequently take place following a cross-clamping of aorta such as occlusive mesenteric ischemia, acute tubular necrosis of the kidneys, and paraplegia (Lloyd et al., 1996).

In 1991, Parodi and co-workers reported the first clinical application of endovascular surgery, namely endovascular aortic aneurysm repair (hereafter referred to as EVAR), for abdominal aortic aneurysm repair (Parodi et al., 1991). It has revolutionized the traditional approach for the treatment of abdominal aortic aneurysm. The prominent advantage of this approach is its less invasiveness as compared with the traditional open surgical abdominal aortic reconstruction, which is particularly suitable for those who are considered to unfit for open surgical abdominal aortic aneurysm reconstruction owing to their serious pre-existing comorbidities (EVAR trial participants, 2005). This approach has enabled to reconstruct abdominal aortic aneurysm surgically without the large incisions of abdominal walls and the prolonged aortic cross-clamp times, and with the significantly less blood loss and fluid shifts. The technique commonly is undertaken with the bilateral groin incisions to obtain an access to the common femoral arteries. Approximately two decades later since its first report in 1991, this approach has come to account for nearly a half of elective repairs of abdominal aortic aneurysm in the United States and in European countries (Shermerhorn et al., 2008).

Currently, two large randomized controlled trials evaluating the efficacy and the safety of EVAR in terms of 30-day peri-operative mortality as well as its long term durability as compared with the standard open surgical vascular reconstructions are undergoing in European countries (Prinssen et al, 2004, Greenhalgh et al., 2004). One is conducted in Netherland and Belgium, and the other is undergoing in the United Kingdom. Interestingly, the results of both trials were quite similar with each other. Although the 30-day peri-operative mortalities as well as the rate of complications were significantly lower in EVAR group than in the open surgical reconstruction group in both studies, the cumulative survival advantage of EVAR group over those with the open surgical reconstruction group had disappeared following 2 years after randomization (Blankensteijn et al., 2005, Greenhalgh et al., 2005). In addition, the rate of subsequent requirement of the secondary interventions was higher in EVAR group, and the quality of life as reported by the participants was also higher in the open repair group (Blankensteijn et al., 2005, Greenhalgh et al., 2005).

The other study is also now undergoing in the United Kingdom comparing the efficacy and the safety of EVAR as compared with no intervention on those who were especially considered to unfit for open repair and excluded for that reason, and it revealed no cumulative survival benefit of EVAR over no intervention group, presumably owing to the serious comorbidities of the participants (EVAR trial participants, 2005). However, the similar study now undergoing in the United States showed the more prominent lower peri-operative mortality in those who had undergone EVAR in highly comorbid participants, which suggests that EVAR, owing to its less invasive nature as compared with the standard

open repair, is particularly suitable for those who were considered to unfit for open repair owing to their serious comorbidities (Timaran et al., 2007).

3. Anesthesia for endovascular aortic aneurysm repair

Shortly after the introduction of EVAR in the treatment of abdominal aortic aneurysm, general anesthesia was preferentially used for the anesthetic management of EVAR because of the following reasons;

1. The first generation device had required the induced hypotension technique during the deployment of the graft.
2. The procedure times were often long.
3. The considerable number of patients had required conversion to open repair during the EVAR procedure.

However, as the second-generation fully stented modular stent graft had come to be widely used, which, through the refinement of the first-generation brand, do not require the induced hypotension technique during the deployment of the graft, and as the physicians had gained the experiences with newer generation devices, which subsequently resulted in the shorter procedure times, a variety of regional anesthesia techniques has come to be used. These techniques include paravertebral peripheral nerve block, spinal anesthesia, continuous spinal anesthesia, epidural and combined spinal anesthesia, and regional anesthesia. Owing to the serious comorbidities of the patients who are undergoing EVAR procedure, the use of less invasive anesthetic techniques for the anesthetic management of EVAR, such as regional anesthesia techniques, has been shown to result in the lower peri-operative mortality, reduced ICU admission and stay, reduced hospital length of stay, and the reduced rate of early complications (Asakura et al. 2009b, Asakura, 2010a, Ruppert et al, 2006, Verhoeven et al., 2005).

The use of neuroaxial anesthesia including epidural and spinal anesthesia may have potentially beneficial effects on patients such as the suppression of the surgical stress, positive effect on post-operative nitrogen balance, and reduced blood loss, these advantages are often counterbalanced by the increased risk of developing subdural and epidural hematoma in patients undergoing EVAR who are frequently medicated with anticoagulants pre-operatively and with the use of heparin during the surgical procedure (Asakura et al. 2008a, Asakura, et al. 2009b, Asakura, 2010a, Park et al., 2001). The incidence of development of hematoma associated with the use of neuroaxial anesthesia is relatively low and is estimated to be approximately 1:150,000-1:200,000 in normal individuals (Horlocker et al., 2000). Although it is difficult to precisely ascertain the relative risk of the incidence of subsequent development of epidural/subdural hematoma in the population who is undergoing anticoagulant therapy, the consensus statement regarding the use of neuroaxial anesthesia and the concomitant use of anticoagulant drugs has been recently provided from the American Society of Regional Anesthesia, given the considerable number of case reports published thus far reporting the development of epidural hematoma in whom an anticoagulation therapy was administered (Horlocker et al., 2010).

Bleeding in the neuroaxial space which most commonly occurs in an epidural space due to the presence of prominent venous plexus, is a potentially catastrophic complication of neuroaxial anesthesia, and the only minor proportion of patients fully recovered neurologically after the prompt diagnosis and the immediate decompression laminectomy. Among 61 cases of spinal hematoma that had been previously reported in the review of

literature, 25 of those had received intravenous or subcutaneous injection of heparin. Furthermore, 5 additional cases had undergone vascular surgery, which means that they were treated with heparin intra-operatively (Vandermeulen et al. 1994). Hence, nearly a half of reported cases were associated with the use of heparin. Although the use of neuroaxial anesthesia in patients who are going to receive heparin is not totally contraindicated, the consensus statement suggests that the careful cautions must be paid in patients receiving neuroaxial anesthesia who are treated with anticoagulant medications (Horlocker et al. 2010).

4. Peripheral nerve block; an alternative for neuroaxial anesthesia in the anesthetic management of EVAR

An alternative regional anesthesia technique that can be used is peripheral nerve blockade (PNB), which has been shown to provide an effective unilateral analgesia with a fewer serious neurological complications even with the use of heparin (Asakura, et al, 2008a, Gray, 2006). Historically, the technique of peripheral nerve block appeared in the early 20th century, but the needle advancement was guided by mostly the knowledge of anatomy. Hence, the rate of success was limited, and it was somewhat like an art of the skilled hands. However, as a result of the advance of ultrasound machine technology (Asakura, et al., 2008b), the anesthesiologists come to perform peripheral nerve block with more than 90% rate of success virtually without any complications. As such, ultrasound-guided peripheral nerve block has come to gain popularity recently worldwide (Marhofer et al. 2007).

4.1 Lumbar plexus block for the anesthetic management of EVAR

During the surgical procedure of EVAR, skin incisions are made in the groin areas to gain the access to the common iliac arteries. The nerve to the lower extremity and groin areas are supplied from the lumbar and sacral plexus (Fig.1). The plexus runs between the psoas major muscle and the quadrates lumborum muscle which is termed as the psoas compartment. The lumbar plexus is formed from ventral rami with L1-4 in addition to the various types of additional contribution from T12 and L5. The branches of lumbar plexus form iliohypogastric, ilioinguinal, genitofemoral, lateral femoral cutaneous, femoral, and obturator nerves. The first lumbar ventral ramus supplies iliohypogastric and ilioinguinal nerves. The genitofemoral and the lateral femoral cutaneous nerves originate from the second ramus. The femoral nerve is formed from the united ventral rami of L2-4. From the anterior division of L2-4, the obturator nerve is formed. The psoas compartment block is usually performed by advancing the needle into the space between the psoas major and the quadrates lumborum muscles, and the once the plexus is approached, a large volume of local anesthetics is injected which subsequently anesthetize the hip and anterolateral thigh.

For the standard lumbar plexus block, the patient is usually placed in the lateral decubitus position, with the hip fixated and the operative side uppermost. The block is conducted by the standard nerve stimulation method (Asakura, et al., 2008a). A 21-gauge 100-mm-long needle is advanced perpendicular to the skin until it contacts to the transverse process of the 5th lumbar spine. A nerve stimulator is set to deliver 0.5-1.0mA current impulse at 2Hz. By further advancing the needle, the localization of the lumbar plexus is confirmed by identifying the contraction of the quadriceps femoris (Asakura, et al., 2008a, Capdevila, et al., 2002).

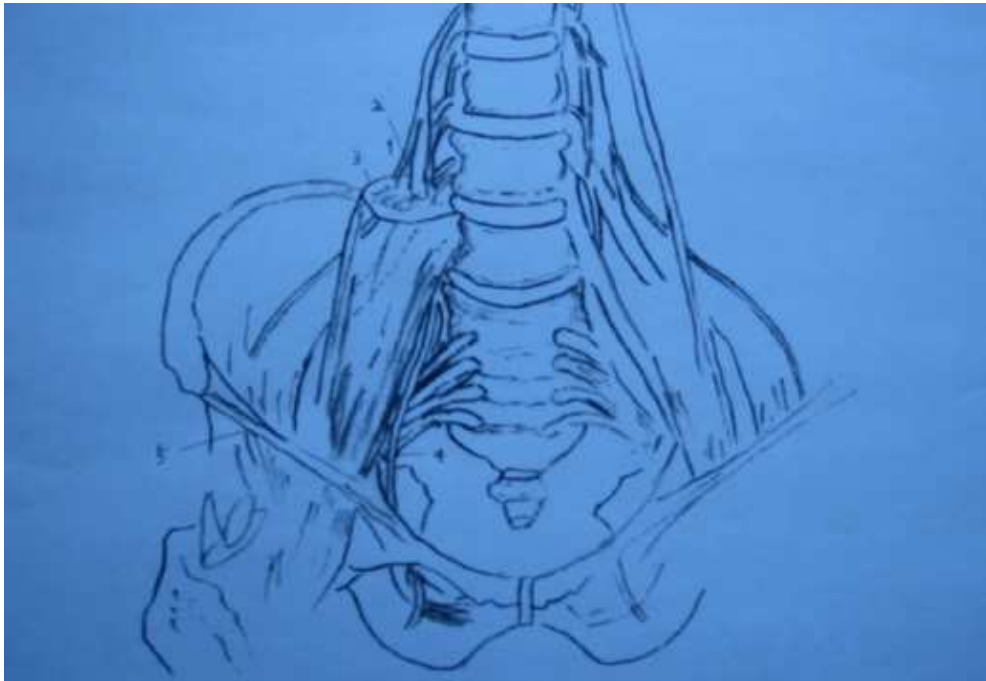


Fig. 1. A schematic presentation of the lumbar and the sacral plexus. 1) lateral femoral cutaneous nerve; 2) femoral nerve; 3) psoas major muscle; 4) obturator nerve; 5) inguinal ligament.

Following the confirmation of the negative aspiration of blood and the cerebrospinal fluids, a large volume of local anesthetics are usually injected. The procedure has been traditionally carried out by the nerve stimulation method under the confirmation of the landmarks of the body. After confirming the top of the iliac crest, a line is drawn to the spinous process of the 4th lumbar spine. Classically, a textbook describes to advance the needle 5cm lateral to the midline of the spine on this line. However, a considerable number of serious complications associated with the use of lumbar plexus block, such as intrathecal injection, epidural injection, inadvertent vascular puncture, and retroperitoneal bleeding (Aida et al., 1996, Aveline et al., 2004, Ludot, et al., 2008, Weller, et al., 2003) have been reported. These complications have, at least in part, resulted from the depth of the plexus inside the body, which also makes it difficult to perform ultrasound-guided lumbar plexus block partly owing to the presence of bony structures. In particular, the use of heparin during the surgical procedures of EVAR makes the retroperitoneal bleeding as the serious complication with the use of lumbar plexus block, although the complication is often self-limiting in contrast to the bleeding in neuroaxial space, which often results in the irreversible neurological damage. Hence, we analyzed the computed tomography of the consecutive patients in our facility that had undergone any elective surgery and characterized the precise localization of the lumbar plexus at the fourth lumbar spine level in the Japanese population.

In the study, axial transverse sections of computed tomography of the fourth lumbar spine level were used to measure the following distances; a distance from the skin to the transverse process, a distance from the skin to the lumbar plexus nervous trunks, a distance from the median sagittal plane to the lumbar nerve trunks, and a distance from the skin to the lateral border of psoas major muscle (Fig.2). On the basis of cadaver study, the lumbar plexus was identified to run between the fleshy slip of the main part of psoas major and the accessory part of the psoas that constitutes the posterior part of the psoas major muscle (Kirchmair et al., 2001). These two parts of the muscle fuses to form the psoas major. The femoral nerve and the lateral femoral cutaneous nerve run inside a thin fascia at the level of the junction of the posterior third and the anterior two-thirds of the muscle. In the measurements made from the computed tomography, the junction of the posterior third and anterior two-third of the psoas major was used as the plane of the femoral nerve (Fig.3).

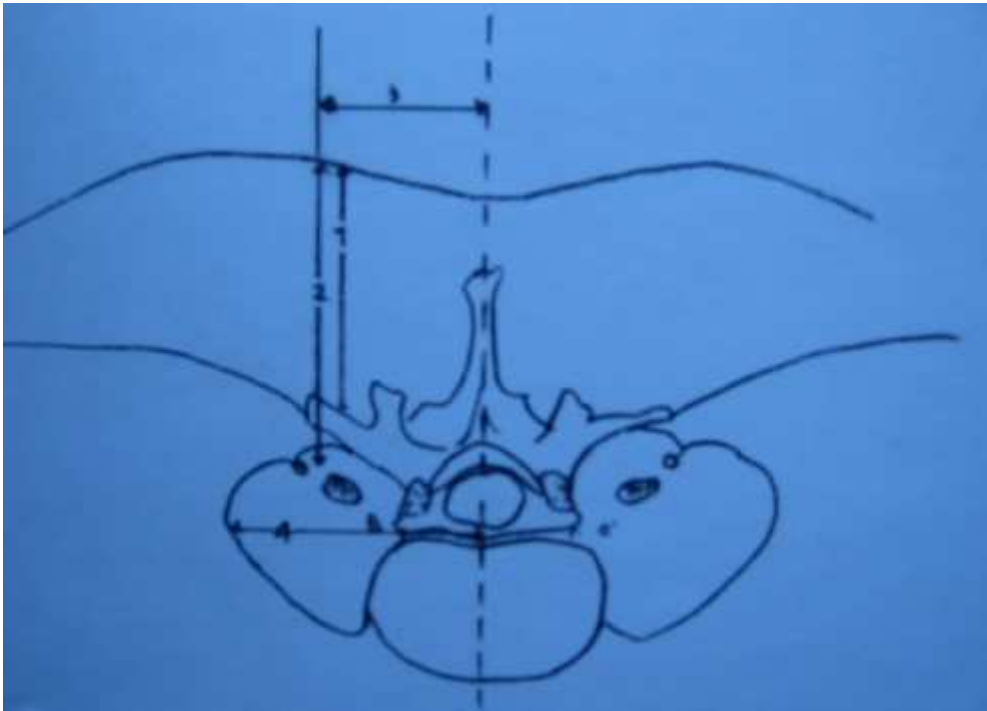


Fig. 2. The following variables were measured; 1)The distance from the skin to the transverse process, 2) The distance from the skin to the femoral nerve, 3) The distance from the median sagittal line to the femoral nerve, 4) The distance from the median sagittal line to the lateral border of the psoas major muscle.

4.2 Anatomical localization of the lumbar plexus in the Japanese population

Although several literatures have described the anatomical localization of lumbar plexus thus far, no similar information in the Japanese population is totally lacking (Farny et al., 1994, Kirchmair et al., 2001). The present study was undertaken in order to precisely identify

the anatomical localization of the lumbar plexus in the Japanese population. The study included 100 Japanese adult patients (59 males and 41 females) who had undergone any elective surgical procedure in our facility. The measurements of the distance from the skin to the transverse process, the distance from the skin to the femoral nerve, the distance from the median sagittal plane to the femoral nerve, and the distance from the median sagittal plane to the lateral border of the psoas major muscle in the Japanese population are significantly smaller than those described previously in the Canadian population, which presumably had made the procedure to be complicated-prone one (Farny et al., 1994). In their report, the distance from the skin to the transverse process in the Canadian females was reported to be $70 \pm 13\text{mm}$ and the distance from the skin to the transverse process in the Canadian males was $75 \pm 22\text{mm}$.

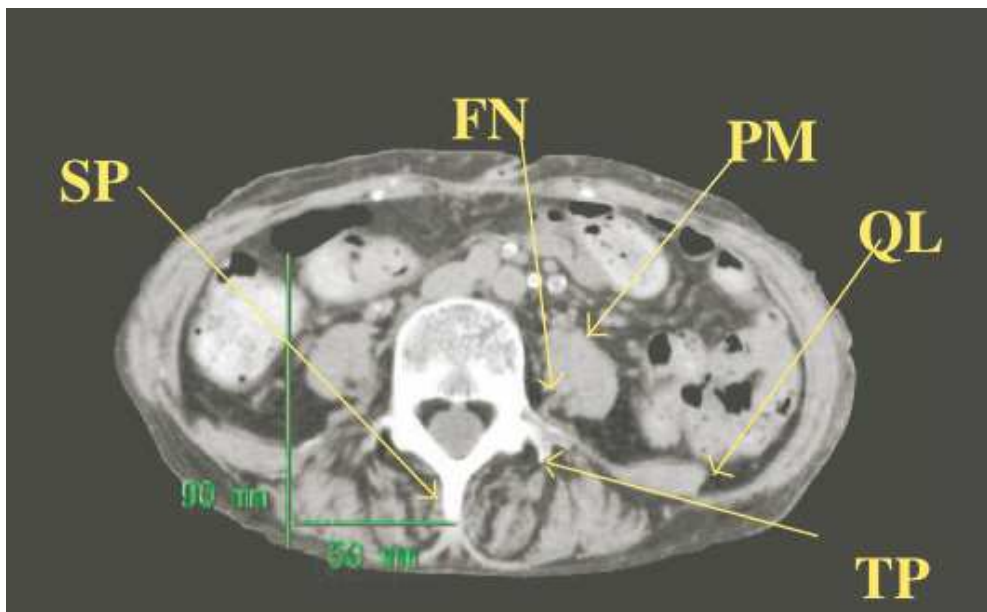


Fig. 3. Localization of the spinous process (SP), transverse process (TP), femoral nerve (FN), psoas major muscle (PM), and quadratus lumborum muscle (QL) on the computed tomography at the 4th lumbar spine level is shown.

By contrast, in our hands, the same distance that corresponds to the Japanese male was 49.32mm (median: 47, range: 30-72mm), and that corresponds to the Japanese female was 48.41mm (median: 47, range: 25-86mm) (Fig.4). Similarly, the average distance from the skin to the femoral nerve in the Canadian males and females were reported to be $99 \pm 21\text{mm}$ and $90 \pm 14\text{mm}$, respectively, whereas that corresponds to the Japanese males was 66.6mm (median: 64, range: 64-90mm), and that to the Japanese female was 65.9mm (median: 66, range: 50-80mm) (Fig.5). The distance from the median sagittal plane to the lateral border of the psoas muscle in the Canadian males and females were reported to be $72.7 \pm 10\text{mm}$ and $60 \pm 8\text{mm}$, whereas those correspond to the Japanese males and females were 54.88mm (median: 55, range: 47-64), and 49.31mm (median: 50; range: 34-67mm) (Fig.6). In addition,

although there was no description regarding the distance from the median sagittal plane to the femoral nerve in the Canadian population, we measured those variables in the Japanese males and females. The distance from the median sagittal plane to the femoral nerve in the Japanese male was 34.47mm (median: 35, range: 27-42mm), and that corresponds to the Japanese female was 32.63mm (median: 32, range 27-45mm) (Fig.7).

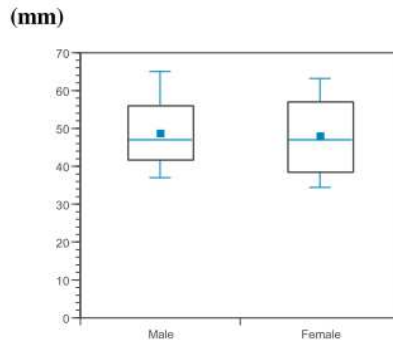


Fig. 4. The distance from the skin to the transverse process in the Japanese males (n=59) and the Japanese females (n=41). Results are expressed by the box-and-whisker plots.

In the standard textbook in the field of anesthesiology, the needle is suggested to advance at the point 3cm caudal to the line connecting the both iliac crest and 5cm lateral to the median sagittal line (Wedel et al., 2005). However, the average distance from the median sagittal line to the lateral border of the psoas major muscle in the Japanese female is 49.31mm, and there is a substantial risk of peritoneal puncture in approximately a half of this population if the needle is advanced at the point described in the textbook. In addition, although the needle is suggested to advance until it contacts to the transverse process of the fifth lumbar spine, there is some possibility that the needle will not contact to the transverse process if it is advanced at the point where the textbook recommends.

Moreover, the literature suggests that the nerve trunks are located approximately 90(female)-99(male) mm deep inside the body in the Canadian population (Farny et al., 1994). However, they are located far more superficial levels in the Japanese population (male; 66.6mm, female 65.9mm). Accordingly, there is a potential risk of peripheral nerve damage if the needle is advanced as suggested by the textbook.

In the Japanese population, the nerve trunks are located approximately 30mm lateral from the median sagittal line (male; 34.47mm, female; 32.63mm). Literature suggests that the development of inadvertent epidural spread occurs in approximately 9-16% of the patients, and this adverse event is attributable to the retrograde diffusion of the local anesthetics to the epidural space (Enneking, et al., 2005). Given the nearer distance from the median sagittal line to the femoral nerve in the Japanese population than in the Caucasian population, it must be always kept in mind that the Japanese patients carry more risks of inadvertent epidural spread than those described in the textbook previously.

(mm)

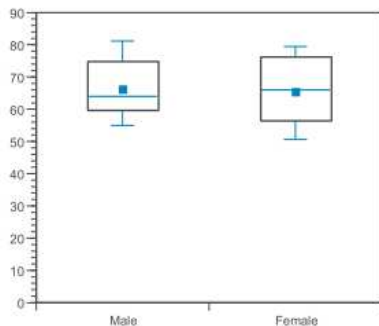


Fig. 5. The distance from the skin to the femoral nerve in the Japanese males (n=59) and females (n=41).

(mm)

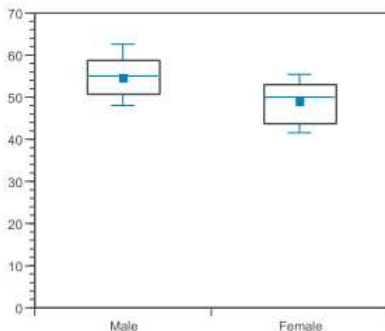


Fig. 6. The distance from the median sagittal line to the lateral border of the psoas major muscle in the Japanese males (n=59) and females (n=41).

(mm)

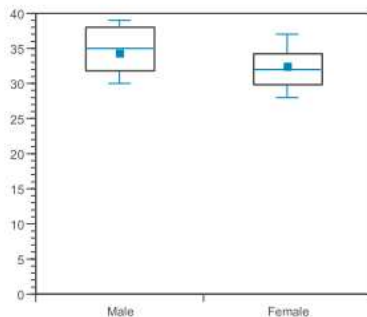


Fig. 7. The distance from the median sagittal line to the femoral nerve in the Japanese males (n=59) and females (n=41).

4.3 Examples that would develop serious complications following lumbar plexus block

Followings are the typical examples of the Japanese patients who would develop serious complications if the needle would have advanced as suggested by the textbook. Figure 8 shows the computed tomography at the 4th lumbar supine level from the 70-year-old female. In this case, if the needle is advanced 5cm laterally from the median sagittal line into the depth at 9cm level, the needle would puncture peritoneal cavity.

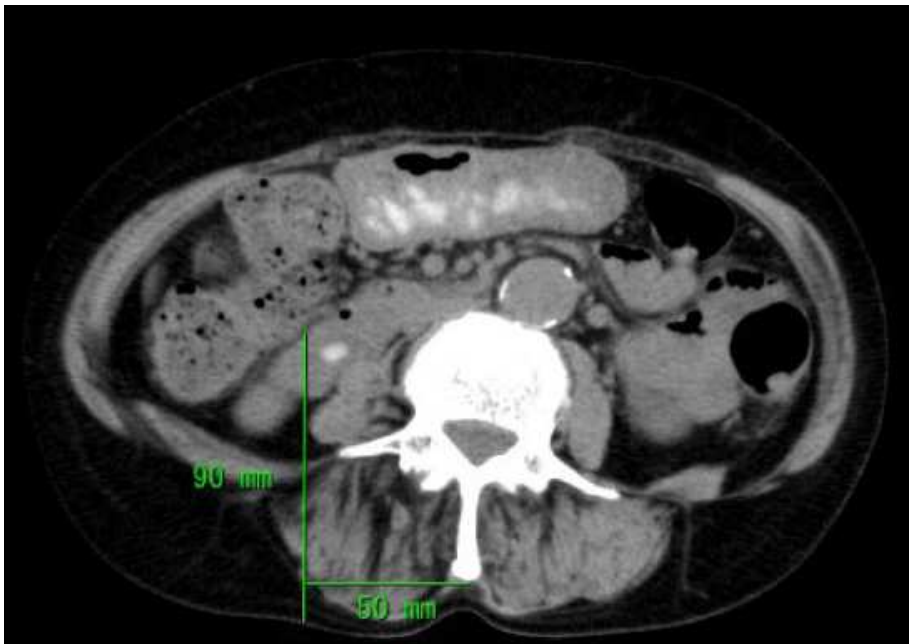

Fig. 8. The computed tomography of a 70-year-old female at the 4th lumbar spine level. Note that if the needle had advanced as suggested by the textbook, it would have punctured the peritoneal cavity.

Similarly, in cases which are shown in figure 9, 10, and 11, the inadvertent peritoneal puncture and possible colonic perforations would have developed if the needle had been advanced as suggested by the textbook.

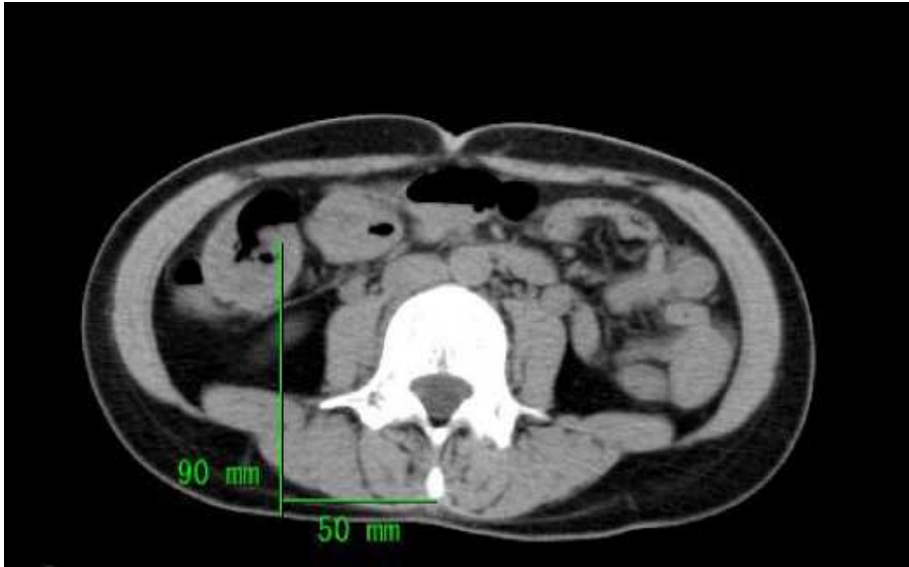

Fig. 9. Computed tomography of the 4th lumbar spine level from a 37-year-old female.

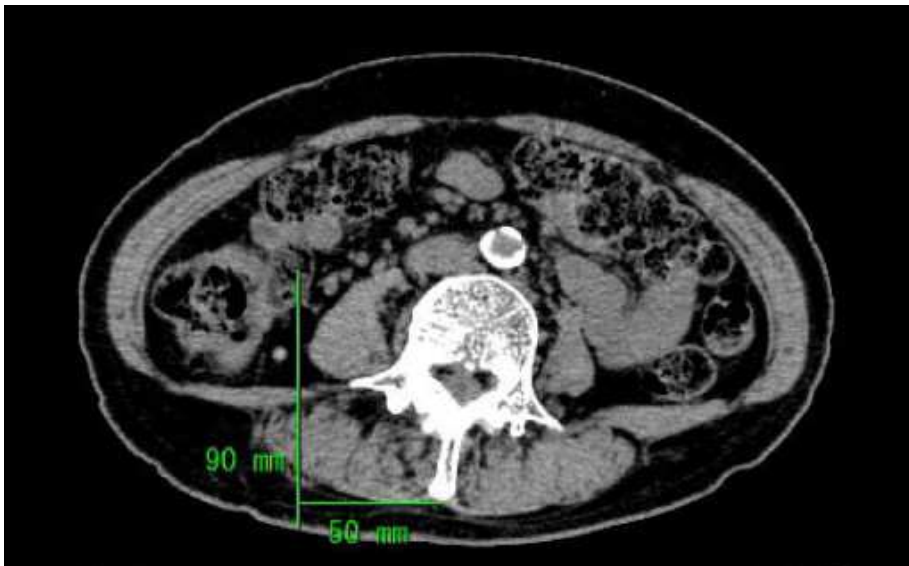


Fig. 10. Computed tomography of the 4th lumbar spine level from a 70-year-old female. Similarly, the needle would have penetrated the peritoneal cavity if the needle had been advanced as suggested by the textbook.

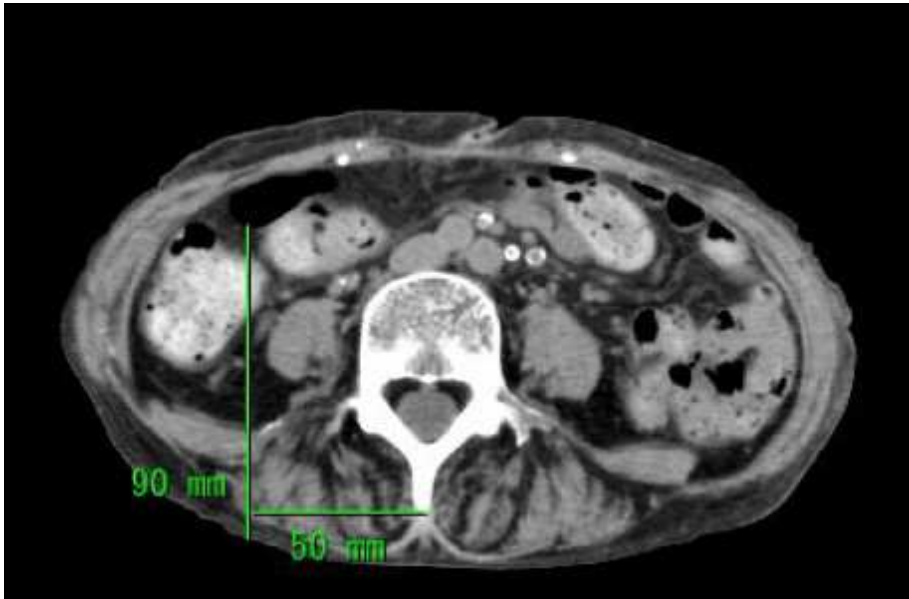


Fig. 11. The computed tomography at the 4th lumbar spine from a 74-year-old female.

In figure 12 and 13, the left kidney has descended as low as to the 4th lumbar supine level. In these cases, if the needle was advanced as suggested by the textbook, inadvertent renal puncture would have developed.

In figure 14 and 15, inferior vena cava is present 3cm laterally from the median sagittal line at the depth of 9cm from the skin. Thus, if the needle would have advanced 3cm laterally from the median sagittal line, there would be the risk of inadvertent inferior vena cava puncture, which may result in serious consequences such as retroperitoneal hematoma, and inadvertent vascular injection of local anesthetics.

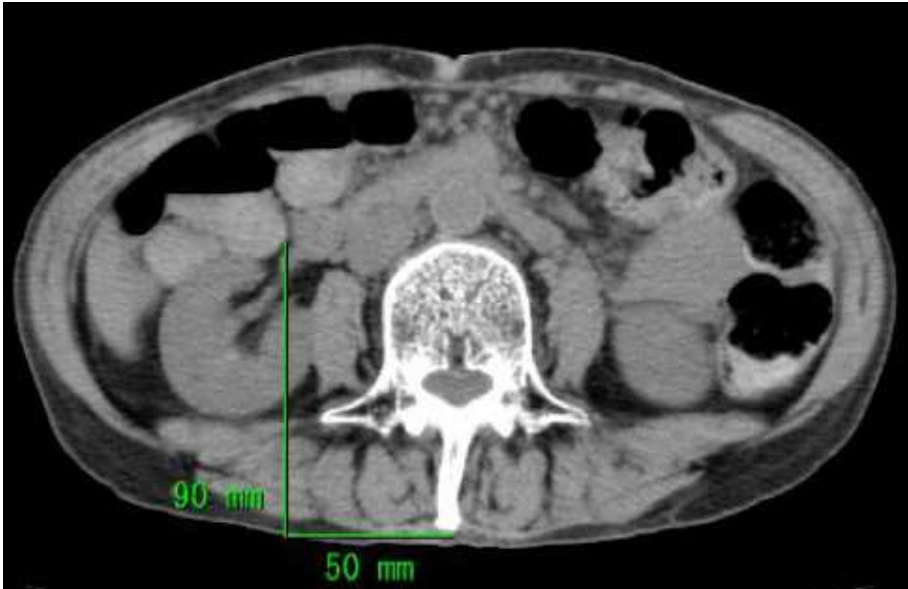


Fig. 12. Computed tomography of the 4th lumbar spine level from a 62-year-old female.

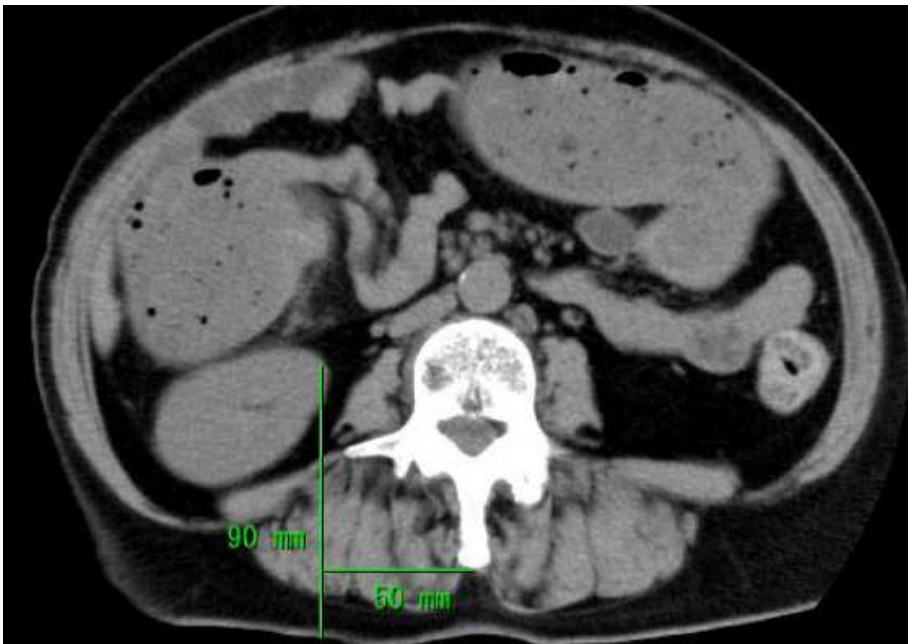


Fig. 13. Computed tomography of the 4th lumbar spine level from a 62-year-old female. In these two cases, if the needle had been advanced as suggested by the textbook, an inadvertent renal puncture would have developed.

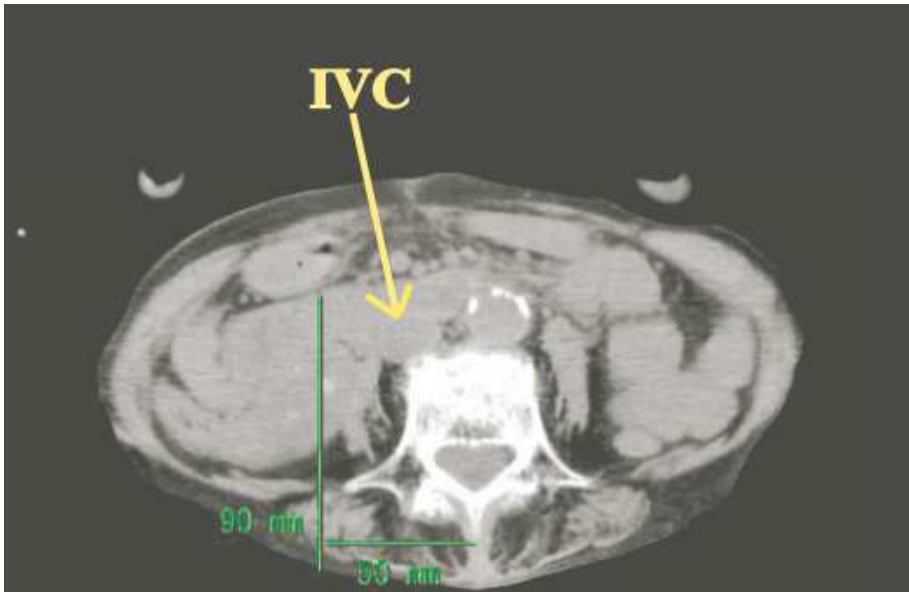


Fig. 14. The computed tomography at the 4th lumbar spine level from a 90-year-old female. Inferior vena cava is distended (indicated by the arrow), and there is a potential risk of inadvertent inferior vena cava puncture in this case.

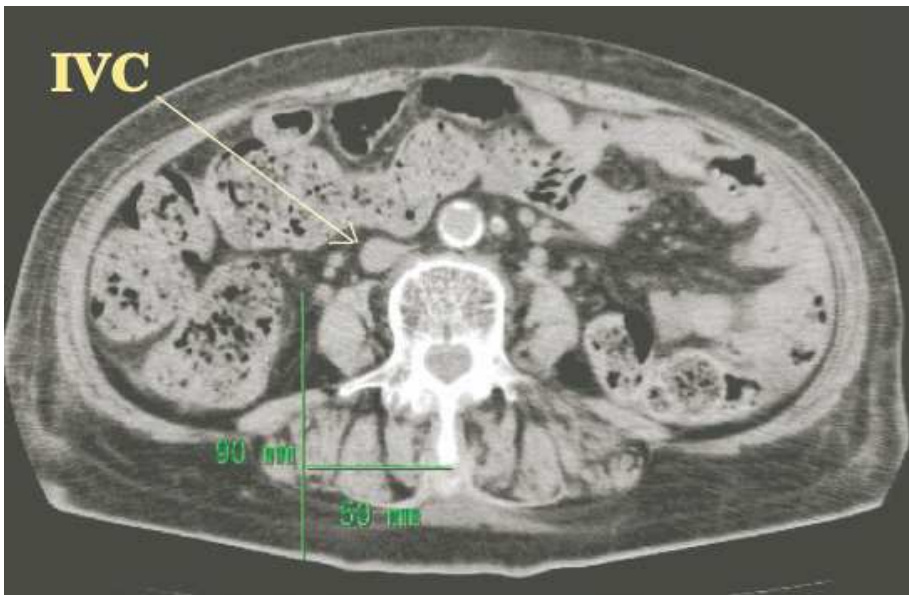


Fig. 15. The computed tomography at the 4th lumbar spine level from a 76-year-old female. In this case, inferior vena cava is laterally deviated (indicated by the arrow), and there is a potential risk of inadvertent inferior vena cava puncture.

From our observations, we suggest that the needle should be advanced 32 (female)-35 (male) mm laterally from the median sagittal line in the Japanese population. If the needle puncture point is more than 5cm laterally from the median sagittal line, there is a risk of inadvertent peritoneal puncture. In addition, the nerve trunks of lumbar plexus present at the depth of 64-66mm inside the body from the skin.

4.4 Ultrasound-guided lumbar plexus block

Lastly, the possibility of ultrasound-guidance for lumbar plexus block is going to be discussed. With the aid of ultrasound, it has come to be feasible to directly visualize the peripheral nerves, the needle, and the spread of local anesthetics. The ultrasound-guidance for peripheral nerve block has been shown to be efficacious in femoral nerve block, sciatic nerve block, brachial plexus block, and peripheral nerves of body trunks (Asakura, et al., 2010a, Asakura, et al., 2010b, Gray, 2006). However, bony structure has a high absorption coefficient of ultrasound, which makes the ultrasound-imaging of lumbar plexus limited in resolution, in addition to the location of nerve trunks deep inside the body. In general, the visualization of nerve structures by ultrasound requires the use of high frequency probes offering high-resolution images. However, the higher the frequency is, the smaller the penetration depth would be (Marhofer et al., 2007). In other words, for the blockade of nerves located deep inside the body, the ultrasound probes with lower frequency are required, which often are insufficient for offering high-resolution images required for identifying nerve structures. In the standard textbook in the field of anesthesiology, there are subtitles dealing with ultrasound-guided supraclavicular and interscalene brachial plexus block, infraclavicular block, axillary block, ilioinguinal block, femoral nerve block, and sciatic nerve block, but no single description of ultrasound-guided lumbar plexus block (Gray, 2005). The first attempt to identify the structures of lumbar plexus by ultrasound using a curved array transducer with a frequency at 4 MHz appeared in 2001 using the healthy volunteers (Kirchmair et al., 2001). They reported the successful identification of psoas muscle, erector spinae, and quadratus lumborum muscle by ultrasonography but not the nerve structures of lumbar plexus. Shortly thereafter, an attempt of ultrasound-guided lumbar plexus block using cadavers appeared from the same group, which confirmed the feasibility and accuracy of ultrasound guidance in advancing the needle to the psoas major muscle, but again without identifying the nerve structures (Kirchmair et al., 2002). Hence, the knowledge of anatomical localization of the nerve structures of the lumbar plexus would appear to be the prerequisite for performing the "ultrasound-assisted" lumbar plexus block. In 2004, however, the successful identification of the nerve trunks of lumbar plexus in the pediatric cases has been reported (Kirchmair et al., 2004). The successful identification of the lumbar plexus in these pediatric cases had resulted from the superficial localization of the nerve trunks, which allowed the researchers to utilize the higher frequency (5-8MHz) transducer ultrasound equipments. So far, the direct visualization of the nerve trunks of lumbar plexus in adult cases appears to be unsuccessful. However, by combining the nerve stimulation in addition to the ultrasound assistance, the identification of lumbar plexus becomes feasible even in adult cases (Asakura et al., 2008a). More importantly, the direct visualization of the adjacent structures such as the kidneys by ultrasound may prevent an inadvertent renal puncture or peritoneal puncture and hence may reduce the incidence of the development of complications associated with the lumbar plexus block.

5. Conclusion


Endovascular aortic aneurysm repair has provided a substantial improvement in the peri-operative patients' outcome including 30-day peri-operative mortality as compared with the traditional open surgical vascular reconstruction largely owing to its less invasive nature, especially in those whom serious comorbidities are present. In order to reduce the substantial risks associated with the anesthesia for EVAR in such seriously comorbid patients, various attempts have thus far been made. Particularly, the use of loco-regional anesthesia technique is a promising way to reduce the risks associated with the use of general anesthesia, such as the reduction in the incidence of development of respiratory complications. However, obstacles have also been met especially with the use of neuroaxial anesthesia because of the increased risks of developing subdural/epidural hematoma. Peripheral nerve block is the possible promising alternative for the use of neuroaxial anesthesia. During the surgical procedures of EVAR, skin incisions are made in the groin areas in order to gain the access to the femoral arteries. Anesthesia at the groin areas can be obtained by the posterior lumbar plexus block, which is traditionally approached by the nerve stimulation method. In comparison with the Caucasian population, the nerve trunks of lumbar plexus are located far more superficial and far more close to the median sagittal plane in the Japanese and possibly in Asian populations. In order to prevent the potential risks of inadvertent renal and peritoneal puncture as well as inadvertent epidural spread, the lumbar plexus block should be carried out with the assistance of ultrasound-guidance.

6. References

- Asakura, Y.; Kandatsu, N.; Hashimoto, A.; Kamiya, M.; Akashi, M.; & Komatsu, T. (2009a) Ultrasound-guided neuroaxial anesthesia: accurate diagnosis of spina bifida occulta by ultrasonography. *Journal of Anesthesia*, Vol.23, 2009, 312-3
- Asakura, Y.; Ishibashi, H.; Ishiguchi, T.; Kandatsu, N.; Akashi, M.; & Komatsu, T. (2009b) General versus locoregional anesthesia for endovascular aortic aneurysm repair: influences of the type of anesthesia on its outcome. *Journal of Anesthesia*, Vol. 23, 2009, 158-61
- Asakura, Y. (2010a) In reply: The anesthetic technique of choice for better outcomes in high-risk elderly patients undergoing endovascular repair of aortic aneurysm. *Journal of Anesthesia*, Vol.24, 2010, 500-501
- Asakura, Y.; Kandatsu, N.; Kato, N.; Sato, Y.; Fujiwara, Y.; & Komatsu T. (2008a) Ultrasound guided sciatic nerve block combined with lumbar plexus block for infrainguinal artery bypass graft surgery. *Acta Anaesthesiologica Scandinavica* Vol.52, 2008, 721-2
- Asakura, Y.; Mizuno, T.; Kato, N.; Sato, Y.; Fujiwara, Y.; & Komatsu T. (2008b) Respiratory status that facilitates subclavian venous catheterization. *Acta Anaesthesiologica Scandinavica* Vol. 52, 2008, 867-9
- Asakura, Y.; Tsuchiya, H.; Niede, Y.; Yano, T.; Kato, T.; & Takagi H. (2010b) Deep vein thrombosis: how long will it remain? *Journal of Anesthesia* Vol.24, 2010, 490-1
- Asakura, Y.; Yano, T.; Takagi, H.; Tsuchiya, H.; & Kato T. (2010c) The incidence of development of motor blockade by ropivacaine is concentration dependent, and most studies regarding the continuous FNB after total knee arthroplasty used 0.2% to 0.3% ropivacaine. *Journal of Arthroplasty* Vol.25, 2010, 837-8

- Ashton, H.A.; Buxton, M.J.; Day, N.E.; Kim, L.G.; Marteau, T.M.; Scott, R.A.; Thompson, S.G.; Walker, N.M.; Multicenter Aneurysm Screening Study (MASS) Group. The multicenter aneurysm screening study (MASS) into the effect of abdominal aortic aneurysm screening on mortality in men: a randomized controlled trial. *Lancet* Vol.360, 2002, 1531-9
- Aveline, C.; & Bonnet, F. Delayed retroperitoneal hematoma after failed lumbar plexus block. *British Journal of Anaesthesia* Vol.93, 2004, 589-91
- Capdevila, X.; Macaire, P.; Dadure, C.; Choquet, O.; Biboulet, P.; Ryckwaert, Y.; & D'Athis F. Continuous psoas compartment block for post-operative analgesia after total hip arthroplasty. New landmarks, technical guidelines, and clinical evaluation. *Anesthesia and Analgesia* Vol.94, 2002,1606-13.
- Enneking, F.K.; Chan, V.; Greger, J.; Hadzic, A.; Lang, S.A.; & Horlocker, T.T. Lower extremity peripheral nerve blocks: Essentials of our current understanding. *Regional Anesthesia and Pain Medicine* Vol.30, 2005, 4-35.
- EVAR trial participants. Endovascular aneurysm repair and outcome in patients unfit for open repair of abdominal aortic aneurysm (EVAR trial 2): randomized controlled trial. *Lancet* Vol.365, 2005, 2187-92
- Farny, J.; Drolet, P.; & Girald, M. Anatomy of the posterior approach to the lumbar plexus block. *Canadian Journal of Anaesthesia*, Vol.41, 1994, 480-5
- Fleming, C.; Whitlock, E.P.; Beil, T.L.; & Lederle, F.A. Screening for abdominal aortic aneurysm: a best-evidence systematic review for the U.S. preventive service task force. *Annals of Internal Medicine* Vol.142, 2005, 203-11
- Gray, A.T. (2005) Ultrasound-guidance for regional anesthesia. In: *Miller's Anesthesia*, 7th edition, Miller R.D. (Eds.), 1675-1704, Elsevier, Churchill Livingstone, ISBN: 978-0-8089-2413-5.
- Gray, A.T. Ultrasound-guided regional anesthesia: current state of the art. *Anesthesiology* Vol.104, 2006, 368-73.
- Greenhalgh, R.M.; Brown, L.C.; Kwong, G.P.; Powell, J.T.; & Thompson, S.G.; EVAR trial participants. Comparison of endovascular aneurysm repair with open repair in patients with abdominal aortic aneurysm (EVAR trial 1), 30-day operative mortality results: randomized controlled trial. *Lancet* Vol.364, 843-8.
- Horlocker, T.T.; & Wedel, D.J. Neurologic complications of spinal and epidural anesthesia. *Regional Anesthesia and Pain Medicine* Vol.25, 2000, 83-98
- Horlocker, T.T.; Wedel, D.J.; Rowlingson, J.C.; Enneking, F.K.; Kopp, S.L.; Benzon, H.T.; Brown, D.L.; Heit, J.A.; Mulroy, M.F.; Rosenquist, R.W.; Tryba, M.; & Yuan, C.S. Regional anesthesia in the patient receiving antithrombotic or thrombolytic therapy. *Regional Anesthesia and Pain Medicine* Vol.35, 2010, 64-101.
- Kirchmair, L.; Entner, T.; Wissel, J.; Moriggl, B.; Kapral, S.; & Mitterschiffthaler, G. A study of the paravertebral anatomy for ultrasound-guided posterior lumbar plexus block. *Anesthesia and Analgesia* Vol.93, 2001, 477-81
- Kirchmair, L.; Entner, T.; Kapral, S.; & Mitterschiffthaler, G. Ultrasound guidance for the psoas compartment block: an imaging study. *Anesthesia and Analgesia* Vol.94, 2002, 706-10
- Kirchmair, L.; Enna, B.; Mitterschiffthaler, G.; Moriggl, B.; Greher, M.; Marhofer, P.; Kapral, S.; & Gassner I. Lumbar plexus in children. A sonographic study and its relevance to pediatric regional anesthesia. *Anesthesiology* Vol.101, 2004, 445-50

- Lloyd, W.E.; Paty, P.S.; Darling, R.C. 3rd; Chang, B.B.; Fitzgerald, K.M.; Leather, R.P.; & Shah, D.M. Results of 1000 consecutive elective abdominal aortic aneurysm repairs. *Cardiovascular Surgery* Vol.4, 1996, 724-26.
- Ludot, H.; Thari, J.Y.; Belouadah, M.; Mazoit, J.X.; & Malinovsky, J.M. Successful resuscitation after ropivacaine and lidocaine-induced ventricular arrhythmia following posterior lumbar plexus block in a child. *Anesthesia & Analgesia* Vol.106, 2008,1572-4
- Marhofer, P.; & Chan, V.W. Ultrasound-guided regional anesthesia: Current concepts and future trends. *Anesthesia and Analgesia* Vol.104, 2007, 1265-9
- Park, W.Y.; Thompson, J.S.; & Lee, K.K. Effect of epidural anesthesia and analgesia on perioperative outcome. A randomized controlled veterans affairs cooperative study. *Annals of Surgery* Vol.234, 2001, 560-571
- Parodi, J.C.; Palmaz, J.C.; & Barone, H.D. Transfemoral intraluminal graft implantation for abdominal aortic aneurysm. *Annals of Vascular Surgery* Vol.5, 1991, 491-499
- Ruppert, V.; Leurs, L.J.; Steckmeier, B.; Buth, J.; & Umscheid, T. Influence of anesthesia type on outcome after endovascular aortic aneurysm repair: an analysis based on EUROSTAR data. *Journal of Vascular Surgery* Vol.44, 2006,16-21
- Shah, P.K. Inflammation, metalloproteinases, and increased proteolysis: an emerging pathophysiological paradigm in aortic aneurysm. *Circulation* Vol.96, 1997, 2115-17
- Schermerhorn, M.L.; O'Malley, A.J.; Jhaveri, A.; Cotterill, P.; Pomposelli, F.; & Landon, B.E. Endovascular versus open repair of abdominal aortic aneurysms in the Medicare population. *New England Journal of Medicine* Vol.358, 2008, 464-74
- Sakalihasan, N.; Limet, R.; & Defawe, O.D. Abdominal aortic aneurysm. *Lancet* Vol.365, 2005, 1577-89
- Timaran, C.H.; Veith, F.J.; Rosero, E.B.; Modrall, J.G.; Arko, F.R.; Clagett, G.P.; & Valentine, R.J. Endovascular aortic aneurysm repair in patients with the highest risk and in-hospital mortality in the United States. *Archives of Surgery* Vol.142, 2007, 520-524
- Vandermeulen, E.P.; Van Ake, H.; & Vermynen, J. Anticoagulants and spinal-epidural anesthesia. *Anesthesia and Analgesia* Vol.79, 1994, 1165-77
- Verhoeven, E.L.; Cina, C.S.; Tielliu, I.F.; Zeebregts, C.J.; Prins, T.R.; Eindhoeven, G.B.; Span, M.M.; Kapma, M.R.; & van den Dungen, J.J. Local anesthesia for endovascular abdominal aortic aneurysm repair. *Journal of Vascular Surgery* Vol.42, 2005, 402-9.
- Wedel, D.J.; & Horlocker, T. (2005) Nerve blocks. In: *Miller's Anesthesia, 7th edition*, Miller R.D. (Eds.), 1639-74, Elsevier, Churchill Livingstone, ISBN: 978-0-8089-2413-5.
- Weller, R.S.; Gerancher, J.C.; Crews, J.C.; & Wade, K.L. Extensive retroperitoneal hematoma without neurologic deficit in two patients who underwent lumbar plexus block and were later anticoagulated. *Anesthesiology*, Vol.98, 2003, 581-5.



Aneurysmal Disease of the Thoracic and Abdominal Aorta

Edited by Dr. Ruth Bush

ISBN 978-953-307-578-5

Hard cover, 226 pages

Publisher InTech

Published online 16, December, 2011

Published in print edition December, 2011

The first successful open surgical repair of an abdominal aortic aneurysm was in 1951 by Dubost and represented a tremendous milestone in the care of this challenging disease. The introduction of endovascular repair in 1991 by Parodi furthered the care of these patients by allowing for lower morbidity and mortality rates and also, enabling surgeons to extend surgical treatment to patients traditionally deemed too high of a surgical risk. This new book on Aortic Disease covers many interesting and vital topics necessary for both the practicing surgeon as well as a student of vascular disease. The book starts with background information on the evolution of aortic management from traditional open surgical repair to modern endovascular therapies. There is also a chapter covering the data supporting current treatment modalities and how these data have supported modern management. Also, the use of endovascular means for care of the challenging situation of ruptured aneurysms is discussed. In addition to management of abdominal aneurysm, there is a chapter on treatment of aneurysms of the ascending aorta. Along with surgical treatment, one must also understand the molecular basis for how blood vessels remodel and thus, the role of cathepsins in aortic disease is elucidated. Lastly, chapters discussing the perioperative management of radiation exposure and ultrasound-guided nerve blocks as well as the need for high-quality postoperative nutrition will lend well to a full understanding of how to management patients from presentation to hospital discharge. We hope you enjoy this book, its variety of topics, and gain a fuller knowledge of Aneurysmal Disease of the Thoracic and Abdominal Aorta.

How to reference

In order to correctly reference this scholarly work, feel free to copy and paste the following:

Yusuke Asakura and Hideki Takagi (2011). Ultrasound-Guided Peripheral Nerve Block in the Anesthetic Considerations for Vascular Surgery – An Alternative Choice for Neuroaxial Anesthesia Techniques, Aneurysmal Disease of the Thoracic and Abdominal Aorta, Dr. Ruth Bush (Ed.), ISBN: 978-953-307-578-5, InTech, Available from: <http://www.intechopen.com/books/aneurysmal-disease-of-the-thoracic-and-abdominal-aorta/ultrasound-guided-peripheral-nerve-block-in-the-anesthetic-considerations-for-vascular-surgery-an-al>

INTECH
open science | open minds

InTech Europe

University Campus STeP Ri
Slavka Krautzeka 83/A
51000 Rijeka, Croatia

InTech China

Unit 405, Office Block, Hotel Equatorial Shanghai
No.65, Yan An Road (West), Shanghai, 200040, China
中国上海市延安西路65号上海国际贵都大饭店办公楼405单元

Phone: +385 (51) 770 447
Fax: +385 (51) 686 166
www.intechopen.com

Phone: +86-21-62489820
Fax: +86-21-62489821

© 2011 The Author(s). Licensee IntechOpen. This is an open access article distributed under the terms of the [Creative Commons Attribution 3.0 License](#), which permits unrestricted use, distribution, and reproduction in any medium, provided the original work is properly cited.