

# Differential Diagnosis of Ectopic Pregnancy - Morbidity and Mortality

Panagiotis Tsikouras et al.,\*

*Department of Obstetrics and Gynecology , Democritus University of Thrace  
Greece*

## 1. Introduction

The term ectopic pregnancy refers to a gestation in which the fertilized ovum implants on any tissue other than the endometrial membrane lining the uterine cavity. Fig 1 presents the various types of ectopic pregnancy and their relative frequencies. The classic clinical symptoms of ectopic pregnancy are pelvic pain, amenorrhea, and vaginal bleeding, spotting (40-50%). However, only 50% of patients present typical symptomatology. Patients may present with other symptoms common to early pregnancy, including nausea (frequently after rupture), breast fullness, fatigue, abdominal pain, heavy cramping, shoulder pain, and recent dyspareunia. Physical findings during examination should be pelvic unilateral tenderness, especially on movement of cervix (75%), enlarged uterus or palpable adnexal mass; crepitant mass on one side or in cul-de-sac (50%). Approximately 20% of patients with ectopic pregnancies are hemodynamically compromised at initial presentation, which is highly suggestive of rupture. Body temperature ranges from 37.2 to 37.8 °C while the pulse is variable: normal before but rapid after rupture. Today, using modern diagnostic techniques, most ectopic pregnancies may be diagnosed prior to rupturing [1].

Diagnosis of ectopic pregnancy has been greatly improved by the advent of rapid serum beta-human chorionic gonadotropin (beta-HCG) tests and then the widespread adoption of transvaginal pelvic ultrasonography (TVUS) [2].

Serum beta-HCG levels can definitively rule out pregnancy if negative, although there have been case reports of pathology-proven ruptured ectopic pregnancy and hemorrhagic shock despite an undetectable serum beta-HCG [3]. In the early stages of a normal intrauterine pregnancy (IUP), the serum beta-HCG rises along a well-defined curve. Therefore, serial beta-HCG tests can be useful for determining the ultimate location of a pregnancy of unknown location. The lower limit of normal rise in beta-HCG (using a 99% confidence interval) is 53% in 2 days [4]. Patients with a beta-HCG level that falls more than 50% in 2

---

\*Marina Dimitraki<sup>1</sup>, Alexandros Ammari<sup>1</sup>, Sofia Bouchlariotou<sup>1</sup>, Stefanos Zervoudis<sup>2</sup>, Panagiotis Oikonomidis<sup>2</sup>, Constantinos Zakas<sup>2</sup>, Theodoros Mylonas<sup>1</sup>, Anastasios Liberis<sup>1</sup>, Vasileios Liberis<sup>1</sup> and Georgios Maroulis<sup>1</sup>

<sup>1</sup>*Department of Obstetrics and Gynecology , Democritus University of Thrace, Greece*

<sup>2</sup>*Department of Obstetrics and Gynecology, Rhea Hospital, Athens, Greece*

days are at low risk of having an ectopic pregnancy [5]. As ruptured ectopic pregnancies have been reported at a wide range of beta-HCG levels, the beta-HCG level should not be a factor in determining whether or not transvaginal ultrasonography should be performed. (The prevalence of false-positive serum hCG results is low, with estimates ranging from 0.01-2%. False-positive serum hCG results are usually due to interference by non-hCG substances or the detection of pituitary hCG. Some examples of non-hCG substances that can cause false-positive results include human LH, antianimal immunoglobulin antibodies, rheumatoid factor, heterophile antibodies, and binding proteins. Most false-positive results are characterized by serum levels that are generally less than 1000 mIU/mL and usually less than 150 mIU/mL[6].)

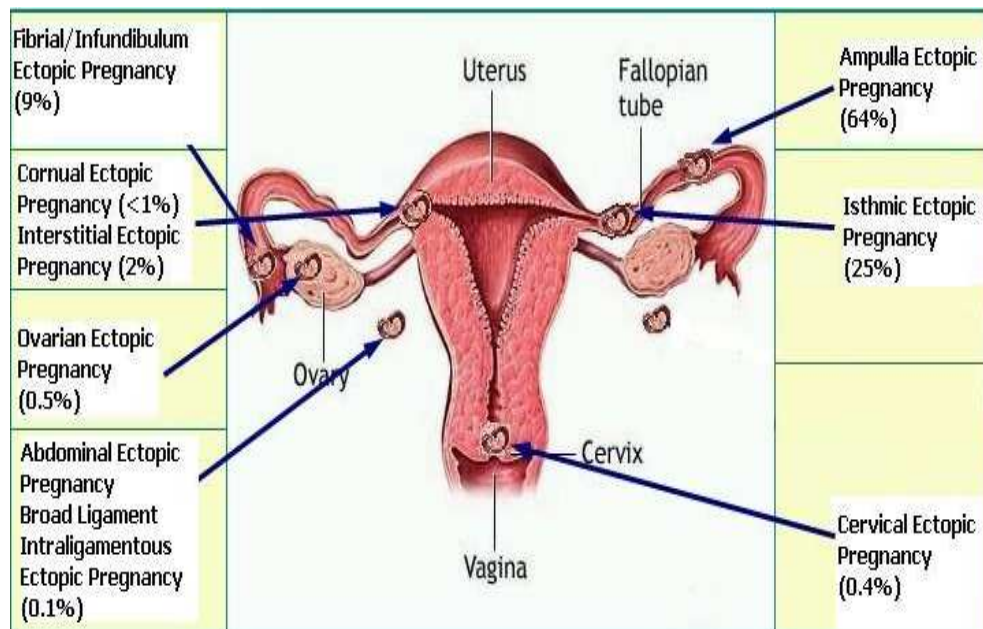


Fig 1. Various types of ectopic pregnancy and their relative frequencies

Serum progesterone levels tend to be stable over time during the first trimester and concentrations are higher in normal intrauterine pregnancy. A single serum progesterone level has been used alone to discriminate between normal and failing intrauterine pregnancies, but it cannot accurately discriminate between intrauterine and ectopic pregnancies [7]. Levels of  $<5\text{ng/ml}$  are associated with a viable pregnancy in 0.16% of cases. Low progesterone levels in combination hCG levels is “essentially 100% predictive of a  $\square$  with an abnormal rise in nonviable pregnancy” (intra or extrauterine). A progesterone level of less than  $15\text{ ng/ml}$  is seen in: 81% of ectopics, 93% of abnormal intrauterine pregnancies, 11% of normal intrauterine pregnancies [8].

The human chorionic gonadotropin (hCG) ratio of hemoperitoneum to venous serum ( $R_{P/V}$ ) has been demonstrated to improve early diagnosis of ectopic pregnancy, according to a recent study. Investigators observed that the  $R_{P/V}$  was higher in ectopic pregnant subjects (median 4.07) than in patients with hemoperitoneum and intrauterine pregnancy (hIUP; median 0.6), with 1.0 as their suggested threshold value for differential diagnosis [9].

Research is ongoing concerning CA 125, pregnancy-associated plasma protein-A, vascular endothelial growth factor and creatine kinase. None of them have yet shown superiority to serial beta-HCG measurements in distinguishing between intrauterine pregnancy and ectopic pregnancy [10].

Furthermore, pelvic sonography is the imaging test of choice to investigate early pregnancy complaints. As sonogram findings of early normal IUP development (<7 weeks) are well correlated with beta-HCG level, the absence of a normal IUP on sonogram together with a beta-HCG level above the discriminatory zone virtually rules out a normal IUP.

Pelvic sonography is usually conducted first using the transabdominal approach (which can reliably identify intrauterine pregnancies at a beta-HCG level above 6500 mIU/mL), and then the transvaginal approach (which can extend the discriminatory zone down to 1500 mIU/mL). M-mode imaging is useful for measuring the fetal heart rate. Color Doppler ultrasonography can help identify some ectopic pregnancies by identifying a placental blood flow pattern in the adnexa. The following sonographic findings are of special interest: An intrauterine gestational sac containing a yolk sac, or fetal pole: A definitive IUP virtually rules out ectopic pregnancy (aside from heterotopic pregnancies). An intrauterine gestational sac larger than 16 mm without a fetal pole, or larger than 8 mm without a yolk sac; or an intrauterine fetal pole larger than 5 mm without heart motion: These findings are indicative of failed intrauterine pregnancy. A gestational sac with a mean sac diameter less than 5 mm greater than the crown-rump length has an 80% risk of pregnancy loss [11]. An extrauterine sac containing a yolk sac or a fetal pole, with or without heart motion Fig 2: Although definitive for ectopic pregnancy, only 16-32% of ectopics have this finding on transvaginal sonogram [12].

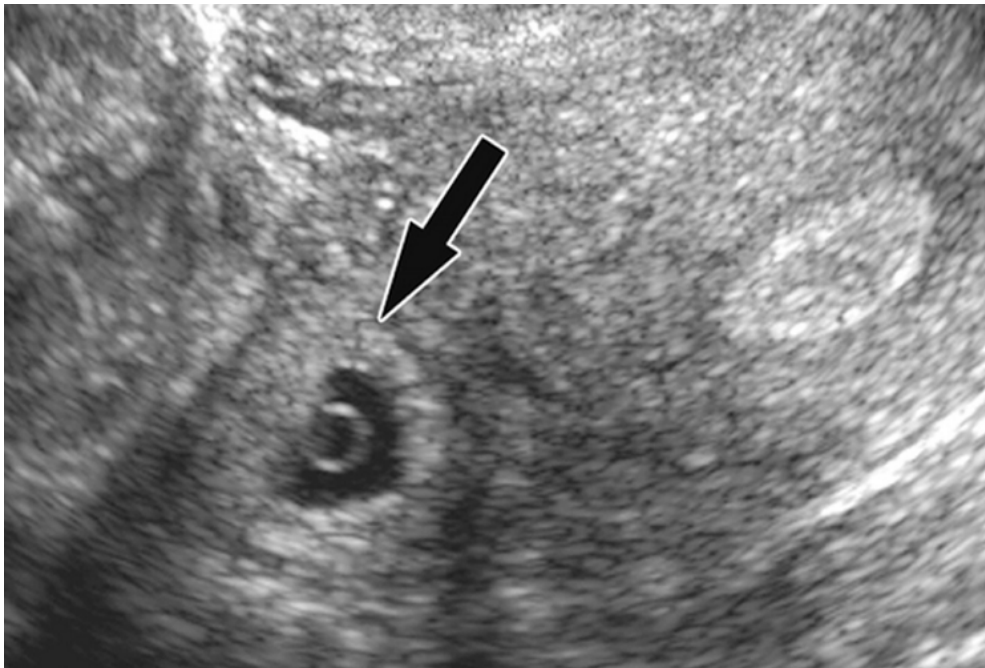


Fig. 2. Vaginal Ultrasound showing gestational sac with yolk sac in extra uterine location.

Tubal ring is a thick-walled cystic structure in the adnexa, independent of the ovary and uterus, and is highly predictive of ectopic pregnancy [13]. It can sometimes be confused with a corpus luteum cyst when the ovary is not well visualized. The corpus luteum cyst wall tends to be thinner and less echogenic than the endometrium and the cyst tends to contain clear fluid [14]. When surrounded by free fluid, it can sometimes be confused with a hemorrhagic ovarian cyst [15]. A complex adnexal mass is the sign most frequently found in ectopic pregnancies [16]. It can be somewhat cystic-appearing or entirely solid in nature, surrounded by free fluid, and ill-defined. If it cannot be moved independently of the ovary, it is unlikely to be an ectopic pregnancy [17]. A moderate amount of anechoic free fluid (tracking more than one third of the way up the posterior wall of the uterus), or any echogenic free fluid, has a higher chance of being ultimately diagnosed as an ectopic pregnancy [18].

Culdocentesis is the transvaginal needle aspiration of fluid from the posterior cul-de-sac of Douglas. A positive result means aspiration of 0.5 ml of nonclotting blood, while negative result is associated with aspiration of 0.5 ml of serous fluid. If no fluid is aspirated, the test is inadequate. In positive cases, if the hematocrit of aspirated fluid is over 15%, ruptured ectopic pregnancy is possible, while a hematocrit of aspirated fluid below 15% is usually in favor of other causes of intraabdominal hemorrhage, such as hemorrhagic corpus luteum cyst, tubal reflux of intrauterine blood, previous attempt at culdocentesis or (19-21). A positive culdocentesis is found in 70-90% of cases in ectopic pregnancy. A positive culdocentesis indicates the presence of a hemoperitoneum (21) but does not give the source of the blood and does not necessarily indicate tubal rupture. The volume of blood recovered does not correlate with the volume of the hemoperitoneum. A positive culdocentesis test in combination with a positive pregnancy test predicts the presence of an ectopic pregnancy, in approximately 95% of cases. (22-3) However double decidual sac sign, or gestational sac <8 mm without yolk sac or fetal pole is in favor of the diagnosis of ectopic pregnancy. While considered diagnostic of IUP by experienced sonographers, this can be easily confused with the pseudogestational sac found in ectopic pregnancy (caused by breakdown of stimulated endometrial lining) and lead to falsely ruling out of ectopic pregnancy [12]. The pseudogestational sac (seen in 10-20% of ectopic pregnancies [24] can be differentiated by its central location in the uterus, oval shape, thin echogenic rim, and lack of double decidual sac sign [11]. A thin endometrial stripe (<8 mm) appears to be somewhat predictive of eventual diagnosis of ectopic pregnancy in patients with a beta-HCG below 1,000 mIU/MI [25] but there is sufficient overlap with eventual failed IUPs and normal IUPs that this is a poor diagnostic test [26].

Numerous conditions may have a presentation similar to an extrauterine pregnancy (EP). The most common differential diagnosis hemorrhagic are: a ruptured corpus luteum cyst or ovarian follicle (RC), and a spontaneous abortion or threatened abortion (SA). Other differential diagnosis are appendicitis (A), salpingitis(S), ovarian torsion(OT), and urinary tract disease(UD): cystitis, ureteric colic. Intrauterine pregnancies with other abdominal or pelvic problems such as degenerating fibroids must also be included in the differential diagnosis.

Specifically, differential diagnosis of ectopic pregnancy includes : Miscarriage (Includes anembryonic gestation, threatened abortion, incomplete abortion, complete abortion, missed abortion.) Often presents with vaginal bleeding in the first trimester, accompanied by abdominal discomfort secondary to uterine contractions. History may yield disappearance of pregnancy symptoms such as breast tenderness and nausea. Ultrasound shows

intrauterine pregnancy or products of conception. Pelvic examination may note dilation of the cervix, as well as presence of tissue at the cervical os. Consecutive serum chorionic gonadotrophin levels often do not rise appropriately (66% in 48 hours), and progesterone levels often  $<15.9$  nmol/L ( $<5$  ng/mL). Acute appendicitis: Anorexia and periumbilical pain followed by nausea, RLQ (Right Lower Quadrant) abdominal pain, tenderness localizing at Mc Burney's point; rebound tenderness and vomiting usual, precedes shift of pain to right lower quadrant. Vaginal bleeding in appendicitis occur unrelated to menses, temperature is  $37.2$ - $37.8$  C and pulse are variable. No masses founded by pelvic examination. Ultrasound sensitivity of 85% to 90% and specificity of 92% to 96%; may show appendix with outer diameter  $>6$  mm, no compressibility, lack of peristalsis, or periappendiceal fluid. WBC  $>10,000$  cells/ $\mu$ l (rarely normal); red cell count normal; sedimentation rate slightly elevated. Ovarian torsion: Sudden onset, severe, unilateral lower abdominal pain that worsens intermittently over many hours. Peritoneal signs are often absent. Ovarian enlargement secondary to impaired venous and lymphatic drainage is the most common sonographical finding in ovarian torsion. Absence of arterial blood flow may also be used for diagnostic purposes, but this is often absent in the early stages of torsion. PID (pelvic inflammatory disease) or tubo-ovarian abscess: Lower abdominal tenderness on palpation, pain usually in both lower quadrants, with or without rebound, adnexal tenderness, adnexal masses only when pyosalpinx or hydrosalpinx is present and cervical motion tenderness. May also have body temperature  $>38.4^{\circ}\text{C}$  [ MORE THAN 38 ] and abnormal cervical or vaginal discharge. Occurrence of hypermenorrhea or metrorrhagia or both. Nausea and vomiting are infrequent. Although rare in pregnancy, can occur in the first 12 weeks of gestation before the decidua seals off the uterus from ascending bacteria. WBC often  $>10,000$  cells/ $\text{mm}^3$ ; red cell count normal; sedimentation rate normal. Ultrasound not used in uncomplicated PID, but is a valuable adjunct in diagnosis of tubo-ovarian abscess. Ruptured corpus luteal cyst or follicle: Non-specific nausea, vomiting, low fever, and pelvic pain, which is often sharp, intermittent, sudden in onset, and severe unilateral, becoming general with progressive bleeding. At times the ruptured cyst may lead to profuse bleeding and result in haemorrhagic shock. Period delayed, then bleeding, often with pain. Temperature not over  $37.2$ ; pulse normal unless blood loss marked, then rapid. Laboratory findings: white cell count normal to  $10,000$  / $\mu$ l; red cell count normal; sedimentation normal. Doppler ultrasonography usually diagnostic, especially when transvaginal and transabdominal modalities are used together. Nephrolithiasis: Classically writhing in pain, pacing about, and unable to lie still, in contrast to a patient with peritoneal irritation, who remains motionless to minimise discomfort. Often presents with unilateral or bilateral flank pain. Haematuria (presence of  $>1$  RBC/hpf) and pyuria ( $>5$  WBC/hpf on a centrifuged specimen) common. Due to potential risks to the fetus, the only imaging modalities used in pregnant women are ultrasonography (direct visualisation of the stone, hydroureter  $>6$  mm in diameter, and perirenal urinoma suggesting calyceal rupture) and MRI (if ultrasound is non-diagnostic). UTI (urinary tract disease): Dysuria with accompanying urinary urgency, frequency, and abdominal discomfort along the surface of the bladder. May have pyuria ( $>5$  WBC/hpf on a centrifuged specimen). Presence of nitrites is highly specific for a UTI, but its absence should not exclude the diagnosis.

Finally, bowel colitis, inguinal or crural hernia and muscular pain should be included in the differential diagnosis of abdominal pain in lower quadrants.

Ectopic pregnancy is responsible for a significant proportion of maternal mortality and morbidity. According to the WHO, ectopic pregnancy accounts for 0.1 to 4.9% of the total

maternal deaths worldwide. [27] The range varies in different regions of the world, exhibiting the highest prevalence in developed countries. Table 1 . [27] It should be mentioned at this point that in developing countries, hemorrhage is the leading cause of maternal deaths.

It is responsible for an enormous amount of hospital admissions, surgical interventions and blood transfusions worldwide.

The mortality rate has declined from 35.5 maternal deaths per 10,000 ectopic pregnancies in 1970 to only 3.8 maternal deaths per 10,000 ectopic pregnancies in 1989. [28] Mortality from ectopic pregnancy is the commonest cause of maternal death, replacing mortality resulting from illegal abortion. [29]

World Region	Percentage (%)
Asia	0.1
Africa	0.5
Latin America	0.5
Developed countries	4.9

Table 1. Variability of maternal deaths due to ectopic pregnancy in different regions of the world.

Studies have shown that African-American women have a mortality ratio 3 to 18 times higher than white women [29-30]

Delay of treatment and misdiagnosis are the main factors that lead to mortality. Approximately 50 percent of ectopic pregnancies are misdiagnosed at the initial visit to an emergency department. [31-2]

The significant fall of maternal mortality is due to modern diagnostic advances and minimally invasive treatments.


## 2. References

- [1] Vicken PS., Wood E, Ectopic Pregnancy, emedicine.medscape.com Updated: Mar 8, 2011
- [2] Cohen HL, Moore WH. History of emergency ultrasound. *J Ultrasound Med.* Apr 2004;23(4):451-8.
- [3] Grynberg M, Teysseire J, Andre C, Graesslin O. Rupture of ectopic pregnancy with negative serum beta-hCG leading to hemorrhagic shock. *Obstet Gynecol.* Feb 2009;113(2 Pt 2):537-9.
- [4] Barnhart KT, Sammel MD, Rinaudo PF, Zhou L, Hummel AC, Guo W. Symptomatic patients with an early viable intrauterine pregnancy: HCG curves redefined. *Obstet Gynecol.* Jul 2004;104(1):50-5.
- [5] Dart RG, Mitterando J, Dart LM. Rate of change of serial beta-human chorionic gonadotropin values as a predictor of ectopic pregnancy in patients with indeterminate transvaginal ultrasound findings. *Ann Emerg Med.* Dec 1999;34(6):703-10.
- [6] Ackerman R, Deutsch S, Krumholz B. Levels of human chorionic gonadotropin in unruptured and ruptured ectopic pregnancy. *Obstet Gynecol* 1982;60:13-14.

- [7] Mol BW, Lijmer JG, Ankum WM, van der Veen F, Bossuyt PM. The accuracy of single serum progesterone measurement in the diagnosis of ectopic pregnancy: a meta-analysis. *Hum Reprod.* Nov 1998;13(11):3220-7.
- [8] Lipscomb GH, Stovall TG, Ling FW. Non surgical treatment of ectopic pregnancy. *NEJM* 200;343(18):1325-1329
- [9] Wang Y, Zhao H, Teng Y, Lu L, Tong J. Human chorionic gonadotropin ratio of hemoperitoneum versus venous serum improves early diagnosis of ectopic pregnancy. *Fertil Steril.* 2008 .
- [10] Cabar FR, Fettback PB, Pereira PP, Zugaib M. Serum markers in the diagnosis of tubal pregnancy. *Clinics (Sao Paulo).* Oct 2008;63(5):701-8.
- [11] Dighe M, Cuevas C, Moshiri M, Dubinsky T, Dogra VS. Sonography in first trimester bleeding. *J Clin Ultrasound.* Jul-Aug 2008;36(6):352-66.
- [12] Patel MD. "Rule out ectopic": Asking the right questions, getting the right answers. *Ultrasound Q.* Jun 2006;22(2):87-100.
- [13] Brown DL, Doubilet PM. Transvaginal sonography for diagnosing ectopic pregnancy: positivity criteria and performance characteristics. *J Ultrasound Med.* Apr 1994;13(4):259-66.
- [14] Stein MW, Ricci ZJ, Novak L, Roberts JH, Koenigsberg M. Sonographic comparison of the tubal ring of ectopic pregnancy with the corpus luteum. *J Ultrasound Med.* Jan 2004;23(1):57-62.
- [15] Hertzberg BS, Kliever MA, Bowie JD. Adnexal ring sign and hemoperitoneum caused by hemorrhagic ovarian cyst: pitfall in the sonographic diagnosis of ectopic pregnancy. *AJR Am J Roentgenol.* Nov 1999;173(5):1301-2.
- [16] Frates MC, Brown DL, Doubilet PM, Hornstein MD. Tubal rupture in patients with ectopic pregnancy: diagnosis with transvaginal US. *Radiology.* Jun 1994;191(3):769-72.
- [17] Blaivas M. Color doppler in the diagnosis of ectopic pregnancy in the emergency department: is there anything beyond a mass and fluid?. *J Emerg Med.* May 2002;22(4):379-84.
- [18] Dart R, McLean SA, Dart L. Isolated fluid in the cul-de-sac: how well does it predict ectopic pregnancy?. *Am J Emerg Med.* Jan 2002;20(1):1-4.
- [19] Glezerman M, Press F, Carpman M. Culdocentesis is an obsolete diagnostic tool in suspected ectopic pregnancy. *Arch Gynecol Obstet.* 1992;252(1):5-9
- [20] Wyte CD. Diagnostic modalities in the pregnant patient. *Emerg Med Clin North Am.* 1994 Feb;12(1):9-43. Review  
Cartwright PS, Vaughn B, Tuttle D. Culdocentesis and ectopic pregnancy. *J Reprod Med.* 1984 Feb;29(2):88-91.
- [21] Falfoul A, Makni MY, Bellasfar M, Tnani M, Kaabar N, Kharouf M. [The role of culdocentesis in the diagnosis of ectopic pregnancy. Prospective study of 478 cases]. *J Gynecol Obstet Biol Reprod (Paris).* 1991;20(7):917-22. French.
- [22] Romero R, Copel JA, Kadar N, Jeanty P, Decherney A, Hobbins JC. Value of culdocentesis in the diagnosis of ectopic pregnancy. *Obstet Gynecol.* 1985 Apr;65(4):519-22
- [23] Nyberg DA, Laing FC, Filly RA, Uri-Simmons M, Jeffrey RB Jr. Ultrasonographic differentiation of the gestational sac of early intrauterine pregnancy from the pseudogestational sac of ectopic pregnancy. *Radiology.* Mar 1983;146(3):755-9.

- [24] Dart RG, Dart L, Mitchell P, Berty C. The predictive value of endometrial stripe thickness in patients with suspected ectopic pregnancy who have an empty uterus at ultrasonography. *Acad Emerg Med.* Jun 1999;6(6):602-8.
- [25] Seeber B, Sammel M, Zhou L, Hummel A, Barnhart KT. Endometrial stripe thickness and pregnancy outcome in first-trimester pregnancies with bleeding, pain or both. *J Reprod Med.* Sep 2007;52(9):757-61.
- Khan KS, Wojdyla D, Say L, Gülmezoglu AM, Van Look PF. WHO analysis of causes of maternal death: a systematic review. *Lancet.* 2006 Apr 1;367(9516):1066-74. Review.
- [26] Goldner TE, Lawson HW, Xia Z, Atrash HK. Surveillance for ectopic pregnancy--United States, 1970-1989. *MMWR CDC Surveill Summ* 1993.
- [27] Dorfman SF. Epidemiology of ectopic pregnancy. *Clin Obstet Gynecol.* 1987 Mar;30(1): 173-80.
- [28] Anderson FW, Hogan JG, Ansbacher R. Sudden death: ectopic pregnancy mortality. *Obstet Gynecol.* 2004 Jun;103(6):1218-23.
- [29] Abbott J, Emmans LS, Lowenstein SR. Ectopic pregnancy: ten common pitfalls in diagnosis. *Am J Emerg Med* 1990;8:515-22.
- [30] Kaplan BC, Dart RG, Moskos M, Kuligowska E, Chun B, Adel Hamid M, et al. Ectopic pregnancy: prospective study with improved diagnostic accuracy. *Ann Emerg Med* 1996;28:10-7.





## **Ectopic Pregnancy - Modern Diagnosis and Management**

Edited by Dr. Michael Kamrava

ISBN 978-953-307-648-5

Hard cover, 248 pages

**Publisher** InTech

**Published online** 26, October, 2011

**Published in print edition** October, 2011

Ectopic pregnancy is the second major cause of maternal mortality in the United States and a leading cause of maternal morbidity and mortality in the world. This book contains the practical methods to early diagnosis of various forms of ectopic pregnancies and their modern management. Ectopic Pregnancy - Modern Diagnosis and Management is a comprehensive book which guides the reader through all features of ectopic pregnancy, both practical and academic, covering all aspects of diagnosis and management of ectopic pregnancy in a clear, concise, and practical fashion. The book is organized so that it can either be read cover to cover for a comprehensive tutorial or be kept desk side as a reference to the ectopic pregnancies. Each chapter introduces a number of related ectopic pregnancy and its diagnosis, treatment and co-morbidities supported by examples. Included chapters bring together valuable materials in the form of extended clinical knowledge from practice to clinic features.

### **How to reference**

In order to correctly reference this scholarly work, feel free to copy and paste the following:

Panagiotis Tsikouras, Marina Dimitraki, Alexandros Ammari, Sofia Bouchlariotou, Stefanos Zervoudis, Panagiotis Oikonomidis, Constantinos Zakas, Theodoros Mylonas, Anastasios Liberis, Vasileios Liberis and Georgios Maroulis (2011). Differential Diagnosis of Ectopic Pregnancy - Morbidity and Mortality, Ectopic Pregnancy - Modern Diagnosis and Management, Dr. Michael Kamrava (Ed.), ISBN: 978-953-307-648-5, InTech, Available from: <http://www.intechopen.com/books/ectopic-pregnancy-modern-diagnosis-and-management/differential-diagnosis-of-ectopic-pregnancy-morbidity-and-mortality>

**INTECH**  
open science | open minds

### **InTech Europe**

University Campus STeP Ri  
Slavka Krautzeka 83/A  
51000 Rijeka, Croatia  
Phone: +385 (51) 770 447  
Fax: +385 (51) 686 166  
[www.intechopen.com](http://www.intechopen.com)

### **InTech China**

Unit 405, Office Block, Hotel Equatorial Shanghai  
No.65, Yan An Road (West), Shanghai, 200040, China  
中国上海市延安西路65号上海国际贵都大饭店办公楼405单元  
Phone: +86-21-62489820  
Fax: +86-21-62489821

© 2011 The Author(s). Licensee IntechOpen. This is an open access article distributed under the terms of the [Creative Commons Attribution 3.0 License](#), which permits unrestricted use, distribution, and reproduction in any medium, provided the original work is properly cited.