

# Immediate Dental Implants and Bone Graft

Khalid S. Hassan<sup>1</sup> and Adel S. Alagl<sup>2</sup>,

<sup>1</sup>*Department of Preventive Dental Sciences, Division of Periodontics,  
College of Dentistry, University of Dammam,  
Faculty of Dental Medicine, Al-Azhar University, Assiut Branch,*

<sup>2</sup>*Chairman of Department of Preventive Dental Sciences,  
College of Dentistry, University of Dammam,*

<sup>1</sup>*Egypt*

<sup>1,2</sup>*Saudi Arabia*

## 1. Introduction

Dental implants were initiated in 1922 by Branemark, who and associates described the relationship between titanium implant and bone which termed osteointegration, defined as the direct structural and functional connection between living bone and the surface of an implant (Albrektsson et al., 1981). Immediate implant placement, defined as the placement of dental implant immediately into fresh extraction socket site after tooth extraction, has been considered a predictable and acceptable procedure (Schwartz et al., 2000). In addition, with immediate implant placement there is minimal use of surgical drills because the socket is already found except for slight increase of the socket length in an attempt to improve primary stability (Barzilay et al., 1991). The decreased surgical trauma of immediate placement type will decrease the risk of bone necrosis and permit bone remodeling process to occur, i.e. the healing period is rapid and allows the woven bone to be transformed into lamellar bone (Hansson et al., 1983; Ericsson, 2000). Moreover, the natural socket is rich in periodontal cells and matrix, which makes the healing faster and more predictable.

Based on the review article by Penarrocha et al., 2004 and the time elapsed between tooth extraction and implantation, the following classification has been established relating the receptor zone to the required therapeutic approach. (a) Immediate implantation, when the remnant bone sufficient to ensure primary stability of the implant, which is inserted in the course of surgical extraction of the tooth to be, replaced (primary immediate implants). (b) Recent implantation, when approximately 6-8 weeks have elapsed from extraction to implantation - a time during which the soft tissues heal, allowing adequate mucogingival covering of the alveolus (secondary immediate implants). (c) Delayed implantation, when the receptor zone is not optimum for either immediate or recent implantation. Bone promotion first carried out with bone grafts and/or barrier membranes, followed approximately six months later by implant positioning (delayed implants). (d) Mature implantation, when over nine months have elapsed from extraction to implantation. Mature bone is found in such situations.

Block and Kent, 1991 described indications and contraindications for immediate dental implants placement into the extraction sites. Summarized in the following indications; 1) traumatic loss of teeth with a small amount of bone loss; 2) tooth lost because of gross decay without purulent exudates or cellulites; 3) inability to complete endodontic therapy; 4) presence of severe periodontal bone loss without purulent exudates; 5) adequate soft tissue health to obtain primary wound closure. Contraindications, include; 1) presence of purulent exudates at the time of extraction; 2) adjacent soft tissue cellulites and granulation tissue; 3) lack of an adequate bone apical to the socket; 4) adverse location of the mandibular neurovascular bundle, maxillary sinus and nasal cavity; 5) poor anatomical configuration of remaining bone. In order to achieve good osseointegrated dental implant with a high degree of predictability, the implant must be 1) sterile; 2) made of a highly bio-compatible material, e.g. titanium; 3) inserted with/and a traumatic surgical procedure that avoids overheating; 4) placed with initial stability; and 5) not functionally loaded during healing period of 4-6 months (Branemark et al., 1989).

It is important to note that, after tooth extraction there are four stages of healing. In the initial angiogenic stage, blood clotting occurs with capillary formation within the first five days after tooth extraction. In the second stage (new-bone formation stage) the entire socket transforming into granulation tissues. In the third stage (bone-growth stage) immature woven bone forms within four to five weeks. In the last stage (bone-reorganization stage), which occurs after six weeks and continues for six months. In addition, bone can take up to 52 weeks to fully mature (Block et al., 2002). Moreover, the periosteum has an important role to alveolar bone formation. Cells from the inner layer of the periosteum are responsible for bone remodeling, and the cortical bone receives 80% of its arterial blood supply from the periosteum. Therefore, careful a traumatic tooth extraction and maintenance of the periosteum helps in preservation of alveolar bone (Misch, 1999).

Regarding bone remodeling after tooth extraction, in the anterior maxilla the facial bone will resorb up to 25% within the first year after tooth extraction and up to 40% to 60% over the next three years. In the posterior region, the rate of bone loss is greater reaching up to 50% within the first year after extraction, especially if a portion of the buccal plate is lost during extraction resulting in limited bucco-lingual dimension, which reducing the available bone for placement of implants (Misch and Judy, 2000).

Several clinical as well as animal studies (Babbush et al., 1986, Whhrle et al., 1992, Sagara et al., 1993, Piattelli et al., 1997, Levine et al., 1998 and Piattelli et al., 1998) demonstrated that when the implants are loaded immediately after placement, the osseointegration could occur under specific circumstances. The clinical success is dependent on a number of factors summarized in the following: 1) bone quality in the insertion site; 2) surface pattern of the implant material; 3) design of the implant; 4) amount of loading, e.g. the occlusal condition; and 5) immobilization of the implants immediately after surgery.

## **2. Bone-grafting materials and immediate dental implant**

Following an extraction, there is a 25% decrease in the width of the alveolar bone during the first year, and an average 4mm decrease in height during the first year following multiple extractions (Carlson & Persson, 1967). Misch (1999) have observed a 40%-60% decrease in alveolar bone width after the first two to three years post extraction, and Christensen (1996) reports an annual resorption rate of at least 0.5% to 1% during the remainder for the rest of a Patient's life. Preservation of bone contour for dental implants, pontic design, denture

stability, soft tissue aesthetics, and maintaining the periodontal status of adjacent teeth are important considerations following an extraction.

The natural pattern of resorption of the alveolar ridge after tooth extraction would result in a different ridge that could be problematic for future of implant placement. To achieve both functional and aesthetic requirements, it might be necessary to plan implant placement after tooth extraction and socket grafting/ridge preservation. Bone graft materials have played an important role in periodontal regeneration for many years (Hoexter, 2002). To preserve alveolar bone width and height for implant placement or for prosthetic concerns, allografts, xenografts and alloplasts have been used to graft extraction sites.

Additionally, in an effort to preserve and create sufficient bone for implant placement after tooth extraction, Michael et al., 2002 used human mineralized cancellous bone as a graft material. Their results indicate that restoration of extraction sites using human mineralized bone has potential. It can preserve or recreate an extraction site's bone bulk in preparation for implant placement.

## 2.1 Autografts

The gold standard of bone grafting materials is autografts. Autografts are obtained from the same patient, taken from one site and placed in another site and forms bone by the process of osteogenesis and osteoinduction. Osteogenesis is defined as bone growth from viable bone cells known as osteoblasts, osteoinduction is the process that involves materials that are capable of inducing cells to differentiate into osteoblasts. Autograft materials are obtained intraorally from edentulous areas, tuberosity mandibular symphysis and mandibular ramus. Extra oral autografts are obtained from iliac crest, rib, tibia and calvarium. The advantages of autograft bone material is that it maintains bone structures such as minerals, collagen and viable osteoblasts and bone morphogenic proteins (BMPs), while the main disadvantage is the morbidity of a second surgical site (Hoexter, 2002). Authors such as Brugnami et al., 1996 and Dealemans et al., 1997 recommended the use of autografts instead of allografts, due to the absence of immune reactions associated with the former. In this sense, the general impression appears to be that autologous grafts are the best choice for osseointegrative purposes. Recently, Hassan et al., 2008 demonstrated a comparative evaluation of immediate dental implant with autogenous versus synthetic guided bone regeneration. The major aim of this clinical and radiographic study was to compare autogenous and synthetic bone grafting with dental implant placement. The results showed that the autogenous bone graft appeared to be superior and the graft of choice because it maintained bone structure and has activated the osteogenesis process (Fig.1, 2&Table1).

One region that has not been previously described as a potential donor site is the mandibular torus, defined as hyperostosis or enlargement of the lingual aspect of the mandible. The mandibular tori generally occur bilaterally in the premolar region, but the hyperostoses may extend distally to the third molar and mesially to the lateral incisor. The lingual tori are unnecessary bony extensions, which may limit tongue space and create phonetic difficulties. When considering any type of prosthetic reconstruction, the tori can become an obstacle. In the study of Scott D and Ganz DMD, 1997 utilizing mandibular tori as a source for onlay bone augmentation with immediate implant placement. The author postulates that an ideal site to harvest bone for augmentation procedures would be a local area of excess bone (exostosis) that offers no structural or aesthetic benefits to the patient. In addition, When local bone augmentation is required, and the mandibular tori are present, they can be considered as excellent potential donor sites. However, these hyperostoses will

be exhibited by only a minute segment of the patient population. When the donor site and recipient site are located within the same half of the mandibular arch, the surgical procedure is reduced to one mutually inclusive incision, which gains access to the donor bone on the lingual aspect and the recipient site on the buccal aspect. The removal of the tori can be accomplished with minimal trauma and low postoperative morbidity. Therefore, the cortical and cancellous nature of the bone, with a thickened outer cortical plate of haversian bone, makes it an excellent choice as a donor site for onlay grafting procedures.

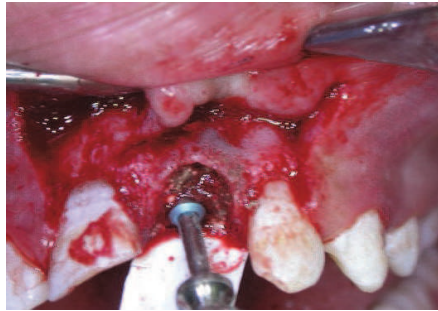


Fig. 1. Immediate dental implant placement into fresh socket augmented with autogenous bone graft.

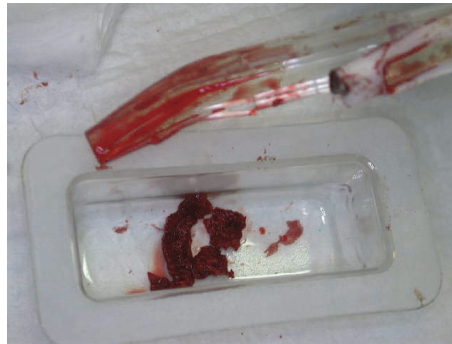


Fig. 2. Autogenous bone graft collected from the same surgical site by safe scraper.

	Bone density			Marginal bone loss		
	GI	GII	P-value	GI	GII	P-value
3M	102.49 ±10.20	99.89 ±14.32	0.470	3.56 ±0.21	3.87 ±0.43	0.067
6M	110.06 ±7.67	102.54 ±13.44	0.185	3.20 ±0.23	3.70 ±0.30	0.001 **
9M	120.93 ±8.66	105.11 ±11.81	0.013	2.73 ±0.21	3.41 ±0.32	0.0001 **
12M	134.56 ±11.29	109.66 ±12.13	0.0009 **	2.50 ±0.21	3.27 ±0.24	0.000 **

Table 1. Bone density (in pixels) and marginal bone loss (in mm) in the Autogenous grafted group (I) and the synthetic grafted group (II) during different observation periods.

## 2.2 Allografts

Allograft bone is obtained from individuals of the same species, derived from human-cadaver bone that has been selected and tested to be free of HIV and transmitted diseases. The most common allograft used is dematerialized freeze-dried bone allograft (DFDBA), provide type I collagen, which comprises most of the organic component of bone (Scahallhorn, 1972). In addition, allograft contains BMPs, which stimulate osteoinduction. There are thirteen proteins have been identified (BMP1-BMP13) which are osteoinductive compounds and stimulate new bone formation (Hoexter, 2002). Fugazzatto (2004) demonstrated that, a combination of osseous coagulum collected during preparation and freeze-dried bone allograft placed at immediate implant insertion and loading. After six months from surgery, there was a clinically immobile implant and healthy surrounding soft tissues; no postoperative gingival recession. Moreover; there was no probing depth exceed than 3mm an any aspect of the implant; no bleeding on probing; no sensitivity to pressure; and does not exculpate around the implant.

## 2.3 Xenografts

Xenografts are graft materials derived from the inorganic portion of animal bones; the most common source is bovine the removal of the organic component are processed to remove their antigenicity, while the remaining inorganic components provide a natural matrix as well as an excellent source of calcium. The disadvantage of xenografts is that they are only osteoconductive and the resorption rate of bovine cortical bone is slow. In addition, patients may have anxiety to mad cow disease or bovine spongiform encephalitis (Berlungh and Lindhe, 1997). Cornelini et al.,evaluated the use of a porous bone mineral matrix xenograft (Bio-Oss) as an adjunct to a biodegradable barrier membrane (Bio-Gide) to support healing following the immediate placement of transmucosal implants into extraction sockets. Their results revealed that, the radiographic bone level remained unchanged compared to baseline in the test and control groups. No differences were observed between test and control groups in terms of mean probing attachment level. At proximal sites, the soft tissue margin was located 2.6 mm more coronal than the shoulder of the implant in the test group, compared to 1.3 mm in the control group. They concluded that the use of deproteinized bovine bone mineral as a membrane support at immediately placed transmucosal implants may offer an advantage in areas with high esthetic demands in terms of soft tissue support.

## 2.4 Alloplasts

Alloplastic bone grafts are synthetic materials that have developed to replace human bone to avoid transmitted diseases such as HIV, bovine spongiform encephalitis (BSE), or hepatitis. They are biocompatible and osteoconductive materials. The most common types of alloplasts used are calcium phosphates, bioactive glasses and biocompatible composite polymers. Moreover, the main disadvantage of alloplasts is that they are unpredictable in allowing bone formation; therefore, particles can be uncounted within the grafted site (Knapp et al., 2003). Furthermore, the natural biocorals are calcium carbonate materials, with similar to the natural bone hydroxyapatite structure.

Advanced synthetic bioactive resorbable bone graft materials having similar chemical and mechanical properties as the host bone, can provide the means to modify existing bone topography. In the study performed by Scott and Maurice, 2002 using a synthetic bioactive restorable bone graft of low-temperature HA material mixed with autogenous bone graft for implant reconstruction. The implants were allowed to osseointegrate for four months, at this

time the site was re-entered and examined. The results were showed that, the underlying implants were found to be covered with a thick layer of mature bone. In addition, the histological section revealed that mature bone was seen surrounding the remaining crystals of bioactive restorable particulates.

Paulino Castellon et al., 2004 demonstrated that immediate implant placement in sockets augmented with HTR synthetic bone. The restorative phase was initiated after six months from implant placement. The results of this study recorded that, the gingival contour was excellent in 61% and good in 35% of cares. They concluded that, immediate implant placement in combination with HTR synthetic bone graft is a predictable procedure and provides a good bone for successful prosthetic reconstruction.

In a study performed by Stanley et al., 1997 using bioglass cones as endosseous ridge maintenance implants to prevent ridge resorption. A bioactive glass can be regarded as a three-dimensional silica network, which is modified by incorporating oxides such as sodium oxide, calcium oxide, phosphorus pentoxide, aluminum oxides and barium oxide or halides such as calcium fluoride. The results of this study showed that a loss of 14.3% of the implants was seen and 7.7% of the implants requiring re-contouring (dehiscence) when the cones are placed into fresh extraction sockets during a 5-years, suggest that favorable clinical results can be obtained with this materials.

### **3. Combined bone-grafts and immediate dental implant**

Bone defects can originate from infections, periodontal diseases or during the placement of implants, which can provoke a vestibular or lingual dehiscence due to the reduced buccal lingual dimension of the crest associated with the presence of fistula, root fractures, endodontic complications or from atrophies that developed after previous extractions.

A variety of regenerative techniques using combinations of bone grafts and barrier membranes have been suggested promoting bone regeneration in localized defects at implants placed into extraction sockets (Schwartz and Chaushu, 1997, Mayfield, 1999).

It is important to note that autogenous bone graft appeared to be the graft of choice in treatment of intrabony defects and defects around dental implants. The ability of bone replacement graft to bind with bone and enhance both osteoinduction and osteoconduction are important. In the study of Hassan, 2009 used a combined technique of using autogenous bone graft and polyglycolic polylactic acid polymer in an attempt to obtain osteoinductive as well as the osteoconductive actions. The grafting materials used in this study included both autogenous bone graft and synthetic graft. They are safe materials because there is no disease transmission. The synthetic co-polymer used in these cases proved to be extremely easy to handle because of the various forms available (sponge, powder, and gel) which easily adapt to the various cases requiring use of a filler with subsequent formation of new bone. In addition, due to its synthetic origin, there is a complete absence of biologic risk. The histological findings showed that the co-polymer remained in the site of the graft until completion of the natural healing processes. At the same time, it is penetrated and gradually and totally replaced by trabecular bone.

In this study, the Safe-Scraper was used for autogenous bone collection from the intact area with good crestal bone in the same surgical field to avoid patient morbidity. Moreover, this work attempted also to avoid the common donor sites that are usually submitted to autogenous bone grafting, such as maxillary tuberosity and mental and mandibular retromolar areas, to preserve the tissues and to avoid morbidity of the donor area.

In this study using, a full-thickness mucoperiosteal flap with vertical releasing incisions where necessary. Teeth carefully luxated and removed with forceps. Extraction sockets were debrided with hand instruments to remove granulation tissue and prepared for implantation. Various sizes of titanium plasma spray implants (diameters 3.25 and 3.75 mm, lengths 14-16 mm) then placed according to standard protocol. Implants were then placed with the collar of the implant at the level of the bone crest on the labial aspect. Where the labial plate was damaged or absent, the level of the labial crest before loss was estimated in the following way. A periodontal probe was placed horizontally at the bone crest of intact portions of the labial plate on either side of the dehiscence defect. Then, the implant was placed with the collar positioned at this level. All implants were placed with primary stability and were completely housed within the extraction socket. After implant placement, the following measurements (bone sounding) were taken using the same William's color-coded periodontal probe (Hu-Friedy, USA). 1) Vertical height of the defect, measured from the most apical extent of the defect to the coronal aspect of the implant collar. 2) Horizontal depth of the defect, estimated by measuring the horizontal distance from the implant collar to a periodontal probe placed against the intact portions of the labial plate at the level of the implant collar. After local anesthesia, these measurements were taken again after six and nine months. Group I patients received autogenous bone grafts collected during preparation using a Safe-Scraper (Micross, Reggio Emilia, Italy) for cortical bone collection and mixed with a synthetic bioabsorbable polylactic polyglycolic acid polymer (Fisiograft). Group II patients received autogenous bone grafts alone.

Furthermore, the results of this study showed a significant gain in clinical attachment levels, as well as reduction in PPD after the composite graft. There was a statistical significant difference between both groups regarding horizontal bone sounding suggesting that the use of Fisiograft combined with autogenous bone graft in this study was found to give optimum regenerative results (Fig.3, 4&Table.2).

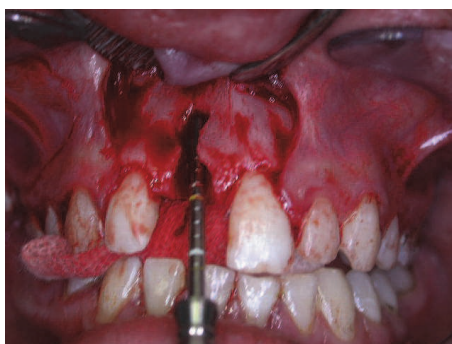

Fig. 3. Labial dehiscence at maxillary central incisor.

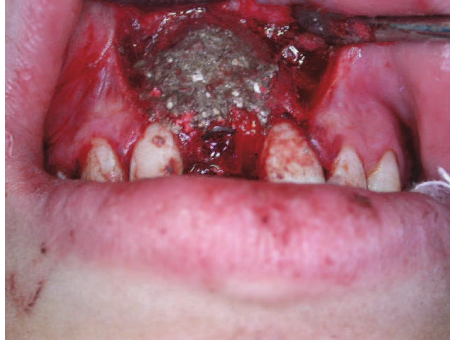

Fig. 4. Immediate dental implant placement into fresh socket and augmented with combined bone graft.

	GI n=10		GII n=10	
	VDH	HDD	VDH	HDD
Baseline	11.0±0.05	3.1±0.2	11.1±0.04	2.7±0.2
6m	5.3±0.04	1.9±0.3	5.6±0.04	1.7±0.2
9m	5.2±0.04	1.8±0.3	5.4±0.04	1.7±0.2
p-value	0.001	0.01	0.001	0.01

VDH= Vertical height of the defect      HDD= Horizontal depth of the defect

Table 2. Vertical and horizontal bone sounding (Probing bone level measurements) at the base line and different postoperative periods in the tested groups.

#### 4. Conclusion

1. To achieve a good osseointegrated implant with a high degree of predictability, the immediate implant might be placed with bone graft and without immediate loading. For aesthetic needs, can be used provisional restoration and free from occlusion.
2. The immediate dental implant placement with autogenous bone graft was significantly superior to synthetic bone graft. In addition, the immediate placement- delayed loaded dental implant remains the procedure of choice for predictably achieving osseointegration.
3. The combination of autogenous bone and synthetic grafts showed a slight superiority to autogenous bone graft alone, suggesting that it could be an optimum bone substitute for treatment of dehiscence around immediate dental implant.

#### 5. Acknowledgment

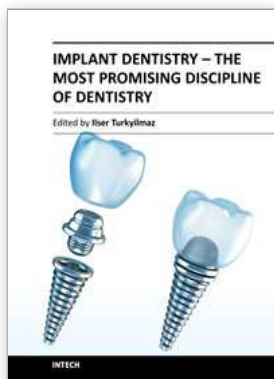
The authors would like to express many thanks for assistant staff in College of Dentistry, University of Dammam, Kingdom of Saudi Arabia and Prof. Ahmed Kassim, Professor of Oral Medicine and Periodontology, Dean of Faculty of Dental Medicine, Al-Azhar University, Assiut Branch, Egypt.



## 6. References

- Albrektsson T, Branemark P, Hansson H & Lindstrom J. (1981). Osteointegration titanium implants. *Acta Orthop Scand* 52: 155-159
- Babbush CA, Kent JN & Misliek DJ. (1986). Titanium plasma sprayed screw implants for the reconstruction of the edentulous mandible. *J Oral Maxillofac Surg* 44: 274- 282
- Barzilay, I, Graser, GN, & Iranpour, B. (1991). Immediate implantation of pure titanium implant into an extraction socket: Report of a pilot procedure. *Int J Oral Maxillofac Implants* 6: 277-284
- Berlungh TM & Lindhe J. (1997). Healing around implants placed in bone defects treated with Bio-Oss: an experimental study in the dog. *Clin Oral Implants Res* 8: 117-124
- Block MS & Kent JN. (1991). Placement of endosseous implants, into tooth extraction sites. *J Oral Maxillofac Surg* 49: 1269-1276
- Block MS, Finger I, & Lytle R. (2002). Human mineralized bone in extraction sites before implant placement-preliminary results. *J Am Dent Assoc* 133: 1631-1638
- Branemark P, Zarb GA & Albrektsson T. (1989). *Tissue integration prosthesis*. Berlin Quintessence Publishing
- Brugnami F, Then P, & Moproi H. (1996). Histological evaluation of human extraction sockets treated with demineralized freeze-dried bone allograft and cell occlusive membrane. *J Periodontol* 67:821-5
- Carlson G & Persson G. (1967). Morphologic changes of the mandible after extraction and wearing of dentures: a longitudinal clinical and x-ray cephalometric study covering 5 years *Odont Rev*; 18:27-54
- Christensen GJ. (1996). Ridge Preservation: Why Not? *J Am Dent Assoc*. 127:669-670
- Cornelini R, Cangini F, Martuscelli G, Wennström J. (2004). Deproteinized bovine bone and biodegradable barrier membranes to support healing following immediate placement of transmucosal implants: a short-term controlled clinical trial. *Int J Periodontics Restorative Dent* 24(6):555-63
- Dealemans P, Hermanns M, & Godet F. (1997). Autologous bone graft to augment the maxillary sinus in conjunction with immediate endosseous implants: a retrospective study up to 5 years. *Int J Periodontics Restorative Dent* 17: 27-39
- Ericsson, I. (2000). Early functional loading of branemark dental implants: 5-years clinical follow up study. *Clin Implant Dent Relat Res* 2 (2): 70-77
- Fugazzotto PA. (2004). Guided bone regeneration at immediate implant insertion and loading: A care report. *Implant Dent* 13: 223-227
- Hansson, HA, Albrektsson, T, & Branemark, PI. (1983). Structural aspects of the interface between tissue and titanium implants. *J Prosth Dent* 50:108-113
- Hassan K S, Kassim A, & Al Ogaly A. (2008). A comparative evaluation of immediate dental implant with autogenous versus synthetic guided bone regeneration. *Oral Surg Oral Med Oral Pathol Oral Radiol Endod* 106:e8-e15
- Hassan KS. (2009). Autogenous bone graft combined with polylactic polyglycolic acid polymer for treatment of dehiscence around immediate dental implants. *Oral Surg Oral Med Oral Pathol Oral Radiol Endod* 108:e19-e25
- Hoexter D. (2002). Bone regeneration graft materials. *J Oral Implant* 26: 290-294 Knapp CI, Feuillev, Cochran D & Melloning JT. (2003). Clinical and histological evaluation of bone replacement grafts in the treatment of localized alveolar ridge defects. Part II: bioactive glass particulates. *Int J Periodontics Rest Dent* 23: (2) 129-137

- Levine RA, Rose L & Salama H. (1998). Immediate loading of root-shaped implants: Two clinical case reports three years after loading. *Int J Periodontics Restorative Dent* 18: 307-317
- Mayfield LJ. (1999). Immediate, delayed and late submerged and transmucosal implants. In: Lang NP, Karring T, Lindhe J, editors. *Proceedings of the 3<sup>rd</sup> European Workshop on Periodontology: Implant Dentistry*. Berlin: Quintessenz, p. 520-34
- Michael S, Israel F, & Robert L. (2002). Human mineralized bone in extraction sites before implant placement Preliminary results. *J Am Dent Assoc* 133:1631-1638
- Mish CE & Judy KWM. (2000). Classification of partially edentulous arches for implant dentistry. *Int J Oral Implantol* 26: 127-128
- Misch CE. (1999). *Contemporary Implant Dentistry*. 2nd ed. St Louis: Mosby Inc: 455-464
- Paulino Castellon D, Raymond A & Yukna DMD. (2004). Immediate dental implant placement in sockets augmented with HTR synthetic bone. *Implant Dent* 13: 42-48
- Peñarrocha M, Uribe R, & Balaguer J. (2004). Immediate implants after extraction. a review of the current situation *Med Oral* 9:234-42
- Piatteli A, Paolantonio M, Corigliano M & Scarano A. (1997). Immediate loading of titanium plasma-sprayed screw-shaped implants in man: A clinical and histological report of two cases. *J Periodontol* 68: 591-597
- Piattelli A, Corigliano M, Costigliola G & Paolantonio M. (1998). Immediate loading of titanium plasma-sprayed implants: An histologic analysis in monkeys. *J Periodontol* 69: 321-327
- Sagara M, Akagawa Y, Nikai H & Tsuru H. (1993). The effects of early occlusal loading on one-stage titanium alloy implants in beagle dogs. *J Prosthet Dent* 69: 281-288
- Scahallhorn RG. (1972). Human allografts of iliac cancellous bone and marrow in periodontal osseous defects II. Clinical observation. *J Periodontol* 43: 67-81
- Schwartz ZA., Gulayev N & Choushu G. (2000). Immediate versus non-immediate implantation for full arch fixed reconstruction following extraction of all residual teeth. A retrospective comparative study. *J Periodontol* 71: 923-9
- Schwartz-Arad D, & Chaushu G. (1997). The ways and wherefores of immediate placement of implants into fresh extraction sites: a literature review. *J Periodontol* 68:915-23
- Scott DG & Maurice V. (2002). Predictable synthetic bone grafting procedures for implant reconstruction: Part two. *J Oral Implant* 8 (4): 178-183
- Scott D. Ganz, DMD. (1997). Mandibular Tori as a Source for Onlay Bone Graft Augmentation: A Surgical Procedure. *The Implant Report* 9:973-982.
- Stanley HR, Mathew BH, Clark AE, King CJ & Hench L. (1997). Using 4555 bioglass cones as endosseous ridge maintenance implants prevent alveolar ridge resorption: A 5-year evaluation. *Int J Oral Maxillofac Implants* 12: 95-105
- Wohrle Ps, Schnitman PA, DaSilva JD, Wang NH, & Koch GG. (1992). Branemark implants palced into immediate function: 5-year results. *J Oral Implantol* 18: 382



## **Implant Dentistry - The Most Promising Discipline of Dentistry**

Edited by Prof. Iser Turkyilmaz

ISBN 978-953-307-481-8

Hard cover, 476 pages

**Publisher** InTech

**Published online** 30, September, 2011

**Published in print edition** September, 2011

Since Dr. Branemark presented the osseointegration concept with dental implants, implant dentistry has changed and improved dramatically. The use of dental implants has skyrocketed in the past thirty years. As the benefits of therapy became apparent, implant treatment earned a widespread acceptance. The need for dental implants has resulted in a rapid expansion of the market worldwide. To date, general dentists and a variety of specialists offer implants as a solution to partial and complete edentulism. Implant dentistry continues to advance with the development of new surgical and prosthodontic techniques. The purpose of *Implant Dentistry - The Most Promising Discipline of Dentistry* is to present a contemporary resource for dentists who want to replace missing teeth with dental implants. It is a text that integrates common threads among basic science, clinical experience and future concepts. This book consists of twenty-one chapters divided into four sections.

### **How to reference**

In order to correctly reference this scholarly work, feel free to copy and paste the following:

Khalid S. Hassan and Adel S. Alagl (2011). Immediate Dental Implants and Bone Graft, *Implant Dentistry - The Most Promising Discipline of Dentistry*, Prof. Iser Turkyilmaz (Ed.), ISBN: 978-953-307-481-8, InTech, Available from: <http://www.intechopen.com/books/implant-dentistry-the-most-promising-discipline-of-dentistry/immediate-dental-implants-and-bone-graft>

**INTECH**  
open science | open minds

### **InTech Europe**

University Campus STeP Ri  
Slavka Krautzeka 83/A  
51000 Rijeka, Croatia  
Phone: +385 (51) 770 447  
Fax: +385 (51) 686 166  
[www.intechopen.com](http://www.intechopen.com)

### **InTech China**

Unit 405, Office Block, Hotel Equatorial Shanghai  
No.65, Yan An Road (West), Shanghai, 200040, China  
中国上海市延安西路65号上海国际贵都大饭店办公楼405单元  
Phone: +86-21-62489820  
Fax: +86-21-62489821

© 2011 The Author(s). Licensee IntechOpen. This chapter is distributed under the terms of the [Creative Commons Attribution-NonCommercial-ShareAlike-3.0 License](#), which permits use, distribution and reproduction for non-commercial purposes, provided the original is properly cited and derivative works building on this content are distributed under the same license.