

# Malignant Brain Tumors in Childhood

Giovanni Scarzello, Maria S. Buzzaccarini and Guido Sotti  
*Department of Radiotherapy, IOV - IRCCS, Padova  
Italy*

## 1. Introduction

Twenty percent of all neoplasms in children arise in the central nervous system (CNS) and the incidence of these tumors has increased in the last years. The World Health Organization (WHO) classification of CNS tumors is shown in Tab. 1 (1).

## 2. Etiology

Although most brain tumors are sporadic, a number of pediatric brain tumor presentations are associated with recognized genetic syndromes. About 15–20% of children with neurofibromatosis (NF1) present with CNS neoplasms, usually gliomas of the optic pathways or low-grade tumors of the diencephalon, cerebral hemispheres, or posterior fossa (2). Low-grade gliomas associated with NF1 may be less aggressive than similar gliomas in the general population. The indolent subependymal giant cell astrocytoma occurs in children with tuberous sclerosis. Childhood brain tumors are frequently noted in families with the Li-Fraumeni syndrome and children with the syndrome are also at high risk for secondary, treatment related tumors (5). Radiation-induced meningiomas have long been recognized.

## 3. Supratentorial brain tumors

### 3.1 Clinical presentation

Supratentorial tumors generally present with localizing neurologic symptoms; symptoms and signs may develop over extended time intervals and are often protean. Seizures are the most common symptom in cerebral hemispheric lesions, especially with tumors arising in the temporal lobe. Lateralizing neurologic signs occur in thalamic region tumors, often associated with symptoms of increased intracranial pressure. Also suprasellar tumors may occlude the foramen of Monro, raising elevated intracranial pressure. Visual field deficits and or decreased acuity and endocrine abnormalities like diminished growth hormone, cortisol or thyroid production, diabetes insipidus, delayed or precocious puberty, are often apparent with midline suprasellar lesions. Children with suprasellar tumors may show the diencephalic syndrome with hyperactivity and asthenia despite normal or high food intake (4). Pineal region tumors produce hydrocephalus by compressing the aqueduct of Sylvius; specific ocular signs like the Parinaud syndrome (decreased upward gaze, near-light dissociation of the papillary response and convergence nystagmus) are classically noted.

**TUMORS OF NEUROEPITHELIAL TISSUE****Astrocytic tumors**

- astrocytoma
- anaplastic astrocytoma
- glioblastoma
- pilocytic astrocytoma
- pleomorphic xanthoastrocytoma
- subependymal giant cell astrocytoma

**Oligodendroglial tumors**

- oligodendroglioma
- anaplastic oligodendroglioma

**Ependymal tumors**

- ependymoma
- anaplastic ependymoma
- myxopapillary ependymoma

**Mixed gliomas**

- oligodendroglioma
- others

**Choroids plexus tumors****Neuronal tumors**

- gangliocytoma
- gaglioglioma
- desmoplastic infantile neuroepithelioma
- dysembryoplastic neuroepithelial tumor
- central neurocytoma

**PINEAL PARENCHYMAL TUMORS**

- pineocytoma
- pineoblastoma

**EMBRYONAL TUMORS****Medulloepithelioma****Neuroblastoma****Ependyblastoma****Primitive neuroectodermal tumors****Medulloblastoma****Cerebral (supratentorial), spinal PNET****TUMORS OF MENINGOTHELIAL CELLS****Meningioma****Malignant meningiomas****TUMORS OF THE UNCERTAIN HISTOGENESIS****Hemangioblastoma****GCTs****Germinoma****Embryonal carcinoma****Endodermal sinus tumor****Choriocarcinoma****Teratoma****Mixed GCTs****TUMORS OF THE SELLAR REGION****Pituitary adenoma****Craniopharyngioma**

Table 1. Histopathologic Classification of CNS Tumors – WHO Classification 2007

### 3.2 Low-grade supratentorial astrocytomas

Low-grade astrocytomas (LGA) represent the most common category of pediatric brain tumors. The most frequent site of origin is the cerebellum, followed by the midline diencephalon and the cerebral hemispheres. In about 3% of cases LGA, mostly if located in the diencephalon, present with subarachnoid dissemination; an uncommon subgroup of diffuse LGA encroaches more than one lobe often with no clear mass: this diffuse pattern of growth is classified as gliomatosis cerebri (5).

Imaging commonly shows a isointense lesion on computed tomography and T1 MRI sequences and hyperintense on T2, with variable enhancement with gadolinium. Small or large cysts and calcifications may be present. LGA histological findings are low cellularity, little nuclear atypia, and few or no mitosis. Although the term "low grade" applies to all pediatric gliomas that are not anaplastic, the various histotypes differ in the degree of infiltration, relative aggressiveness, and prognosis. Juvenile pilocytic astrocytomas (JPAs) and diffuse fibrillary astrocytomas (DFA) comprise the majority of pediatric low-grade gliomas. Less common LGAs include gemistocytic astrocytomas, pleomorphic xanthoastrocytomas, desmoplastic infantile astrocytomas, protoplasmic astrocytomas, and subependymal giant cell astrocytomas. Management depends on tumor location, patient age, presence of a genetic mutation, the goal of treatment is long term disease control or cure with function preservation. Outcome is largely favorable.

#### 3.2.1 Therapy

##### 3.2.1.1 Surgery

For resectable LGA surgery (S) is the first and sole intervention providing excellent control of disease. Low recurrence rates are reported after total resection: with a 5-year progression-free survival (PFS) ranging from 95 to 100% for JPAs and gangliogliomas to 80% for grade II DFA (6). Resection of tumors involving the dominant medial temporal lobe, motor strip region, or the Broca speech cortex may not be possible without inducing severe neurologic deficits. Partial resection may provide initial intervention for decompression and histopathologic diagnosis. LGA of the diencephalon are technically challenging because of the deep location and eloquent area.

##### 3.2.1.2 Radiation Therapy

Radiation Therapy (RT) is an established, effective treatment for pediatric LGA, achieving tumor response and durable control in a significant proportion of cases (7). An analysis from Pollack et al. showed improved disease control at 10 years after irradiation following incomplete resection of cerebral hemispheric astrocytomas: 82% PFS with RT versus 42% after S alone. The same study showed no significant benefit in overall survival (OS)(8). A recent phase II prospective study published by Merchant et al. showed excellent event-free survival (EFS) (87% and 74% at 5 and 10 years, respectively) and OS over 90% at 10 years for children treated with three-dimensional (3D) conformal irradiation to the MRI-defined tumor volume (9). These results have been associated with excellent functional outcomes (10). The decreased volume of normal brain exposed to moderate or high radiation doses using conformal techniques with small margins may significantly decrease some of the serious radiation-induced side effects (11). There are no contemporary data suggesting a benefit of postoperative irradiation for completely resected LGA. For incompletely resected LGA, early administration of irradiation may not benefit the patient. Current indications for

RT after a near total resection (with imaging evidence of disease residual) include symptoms or signs that might improve with RT or post surgical progression in a location not amenable to safe, definitive second resection. Other factors considered are histological subtype or biology.

### 3.2.1.3 Chemotherapy

Chemotherapy (CT) has been used with increasing frequency for LGA as a strategy to delay or avoid RT; less data regarding CT response for progressive disease following irradiation are available. CT can provide disease control for months to years, more often achieving stable disease or partial response than complete remission; most tumors progress within 3–4 years, requiring RT at that time. The age below which CT is more appropriate is controversial and dependent on factors such as tumor size and location, presence of NF mutation, or developmental or neurocognitive delays. Packer et al. reported age to be the only significant prognostic factor, with 3-year PFS rate of 74% for children 5 year old versus 39% for older children (12). In COG, the age of 10 years has been chosen for trial eligibility in studies evaluating CT as initial treatment (13). Individual centers have used thresholds of 3 or 5 years of age. Favorable control rates and relative absence of serious toxicity have established carboplatin and vincristine as the “standard” first line CT in younger children (14). Temozolomide, an alkylating agent with modest responsiveness in recurrent LGA, is currently in trial with carboplatin-vincristine to try to prolong drug tolerance (15). The five-drug University of California at San Francisco (UCSF) regimen (6-thioguanine, procarbazine, dibromodulcitol, lomustine, and vincristine) has been reported to be similarly efficacious; a randomized trial comparing carboplatin-vincristine to this regimen has been completed in COG, suggesting equal or greater efficacy with the five-drug regimen (13). Bevacizumab in combination with irinotecan has been investigated for recurrent LGA with promising response rates for heavily pretreated patients (16). The decision to proceed with CT or RT relates to patient age and clinical presentation; factors beyond age alone include symptoms and signs, potential for additional neurocognitive deficits, the likelihood of durable benefit from respective chemotherapeutic regimens, and the radiation volume required in weighing relative potential toxicities. Although not proven to be problematic, there is no confirmation that the response rate and durability of disease control following RT are independent on prior failure on CT.

### 3.3 Optic pathway tumors

Optic pathway tumors (OPTs) represent 5% of childhood brain tumors and may involve one or more anatomic sections of the optic system: optic nerves, optic chiasm, optic tracts, optic radiations. They can be small and localized or extensive and infiltrative. Tumors involving the chiasm are difficult to distinguish from tumors originating in the hypothalamus, therefore they are commonly grouped with hypothalamic gliomas as one entity. OPTs occur predominantly in young children: 25% present before 18 months of age and 50% present before 5 years. Up to 25% of childhood OPTs occur in children with NF1 and 10–20% of children with NF1 are found to have OPTs on MRI. Clinical presentation is most often with diminished vision. In young children, increased intracranial pressure endocrinopathies and diencephalic syndrome may predominate. Histologically, more than 90% of OPTs are LGA, most often JPAs, with infrequent gangliogliomas or hamartomas; malignant gliomas are uncommon (17). While acknowledging the sometimes indolent nature of OPTs, serial observations in major pediatric neuro-oncology clinics indicate progression in 75–85% of

children, typically within 2 years of initial presentation. Tumors confined to the optic nerves may behave in a more hamartomatous fashion. Children with NF1 have a more indolent course with lower rates of progression and longer latency intervals (17). Other signs of the neoplastic behavior of OPTs include extension to or invasion of the adjacent hypothalamus and posterior extension to the optic tracts and optic radiations. Infrequently, optic chiasmatic and hypothalamic tumors demonstrate diffuse leptomeningeal disease (18). Mortality within 10 years of diagnosis is uncommon, although ultimate disease-related mortality has been documented in up to 40% of cases (19). The rare but documented occurrence of spontaneous regression of OPTs (20) is also to be noted. Several series identify chiasmatic OPTs as optic pathway-hypothalamic gliomas, acknowledging the difficulty in identifying the origin of tumors that intimately involve both the chiasm and the hypothalamus (14). Although lesions extending to or originating in the hypothalamus may be somewhat more aggressive than lesions confined to the visual pathways, up to 50% of selected, asymptomatic children have been free of progression for 5 years or longer without therapeutic intervention. Preliminary data suggest adequate retrieval with secondary therapy at the time of progression during observation (17).

### **3.3.1 Therapy**

#### **3.3.1.1 Surgery**

S has been the preferred treatment for unilateral tumors of the optic nerve (21,22), but care should be taken to avoid visual compromise or other surgical complications as alternative therapies are quite successful. Observation may be selected, especially if there is residual vision associated with a lesion confined to the intraorbital optic nerve. Alvord and Lofton (21) reported progression in 70% of children with untreated lesions within 6 years of diagnosis, although it was rarely associated with tumor-related mortality. Most series indicate more indolent behavior in children with neurofibromatosis (22). For lesions involving the optic chiasm, there are limited data suggesting a role for surgical resection. Decompression or limited resection may be successful in restoring vision. Typical chiasmatic lesions that involve components of the visual pathways beyond the optic chiasm and hypothalamic region may be managed without biopsy confirmation. Most of these tumors are LGA and often can be managed according to the clinical and imaging diagnosis. Globular tumors that involve the chiasm and hypothalamus are best biopsied if this can be performed safely; a small percentage of these lesions may be more aggressive malignant gliomas (23).

#### **3.3.1.2 Radiation Therapy**

Irradiation is indicated for significant visual or neurologic deficits at presentation or documented progression by clinical evaluation or neuroimaging after observation, S or CT (12,21,24). RT is highly effective for OPTs: 10-year PFS rates exceed 80% (25,31). Although OS at 10 years is unaffected by the initial therapeutic approach, PFS rates at 5 and 10 years are substantially higher after RT (26). Serial imaging studies document significant tumor response in more than 50% of children after irradiation (25). Transient post irradiation tumor enlargement, often in the setting of central cystic degeneration, has been well documented (19). Close observation and medical management rather than aggressive intervention for presumed tumor progression is advised, particularly for lesions that may appear to progress within 6–12 months after RT. Visual improvement has been reported in

25–35% of children after irradiation (19,27). Visual deterioration is reported in 10–20% of children after RT, largely related to cystic degeneration and consequent increased mass effect at the chiasm or unrecognized elevated intracranial pressure (19,26). Vision should be monitored closely during RT and in the months following completion. OPTs are associated with unique late radiation-related sequelae. The young age at diagnosis, central location, and often extensive anatomic involvement challenge the ability to deliver adequate RT while preserving neurocognitive function; the problem is further accentuated in children with NF1, itself associated with cognitive delays (25,28). There is also concern about late vascular events: the incidence of occlusive vasculopathy at the circle of Willis in children with brain tumors is highest among those with OPTs, especially in younger children (29). There is also a heightened concern regarding the risk of second malignancy in patients with NF1 (30). The Toronto group has uniquely reported a 10% incidence of second malignant neoplasms after irradiation for OPTs; of interest, a series from Children's Hospital of Los Angeles showed the same rate of anaplastic degeneration in JPA after surgery alone (31, 32).

### 3.3.1.3 Chemotherapy

Because of the radiation associated morbidities in young children with OPT, Packer et al. explored primary CT in children younger than 5 years. Initial experience with actinomycin D and vincristine resulted in stabilization in a majority of children and objective tumor reduction in approximately 25%. Although more than 60% of children needed RT by 5 years after diagnosis, the approach resulted in a substantial delay in RT, with a median time to progression of 3 years (33). Subsequent experience with an 18 month regimen of carboplatin and vincristine for LGA including those of the hypothalamic region and OPTs has shown a significant rate of objective tumor reduction, early progression in only 10%, and 3 year PFS that ranges from 75% for children younger than 5 years to 39% for those older than 5 years (12). Similar results have been reported with the UCSF five drug regimen (34). Early experience suggests favorable outcome with secondary RT after progression during or after CT; recent observations related to the timing of initiating RT suggest that long term disease control and function are not diminished with prolonged preirradiation intervals (12,24). Toxicity with carboplatin and vincristine has been limited, and early data suggest continued intellectual development during CT (35). There is a balance between duration of disease control, clearly superior with RT and less durable control with CT apparently without the serious morbidities associated with RT in the younger age group (17,26). In current practice, most children below 5–10 years receive CT as initial intervention, with some centers extending this to all prepubertal children. It is important not to avoid RT even in younger children when despite CT, progressive visual loss is apparent.

## 3.4 Oligodendroglioma

Oligodendrogliomas represent 1–2% of supratentorial tumors in children. The generally circumscribed tumors occur most often in the cerebral hemispheres. Treatment recommendations are based largely on adult experience with S and RT (36). Adults show excellent response to procarbazine, lomustine, and vincristine (PCV) or to temozolomide CT, particularly in anaplastic oligodendrogliomas with isochromosome 1p or p53 mutations (37). Given differences in biology, it is unclear whether chemosensitivity can be extrapolated to children. Gross total resection (GTR) is the treatment of choice for accessible lesions. GTR has been documented in 20–25% of all cases, apparently more often in children and adolescents (30). The OS rate at 10 years after total excision is reported to be about 60% (38). For

incompletely resected oligodendrogliomas, a short-term benefit for RT has been documented reported 5 year OS rate of 25% after subtotal resection, compared with 62% with the addition of irradiation to doses greater than 50 Gy; by 10 years, the OS rates were 31% with RT and 25% without RT (39). Adjuvant RT is typically withheld for differentiated oligodendrogliomas in children, even with incomplete resection. Histologic grade has been cited as a prognostic indicator in oligodendrogliomas. Anaplastic oligodendrogliomas are managed similarly to other malignant supratentorial gliomas, although the outcome tends to be superior to those with anaplastic astrocytoma and glioblastoma. Limited CT has been associated with sufficient tumor reduction to permit delayed S in tumors initially unresectable (40).

### 3.5 Ganglioglioma

Gangliogliomas are uncommon neoplasms comprised of neuronal and glial elements, occurring primarily in children and young adults. Gangliogliomas present most often in the mesial aspect of the temporal lobes, with seizures as the dominant symptom (41,42). Pediatric tumors uncommonly present in the posterior fossa. The lesions are typically well circumscribed and resectable (41,43). Gangliogliomas are classically coded as WHO grade I, well differentiated histologically with no atypia or anaplasia (42). S alone is the standard initial intervention; 10 year DFS has been reported in 97% of pediatric cases after S (42). Malignant transformation at progression or recurrence is rare; almost 10% of cases show nuclear atypia or anaplastic components (grade II or III, respectively) (43). Malignant degeneration to glioblastoma (grade IV) is decidedly uncommon in children and adolescents (44). Prolonged PFS survival has been noted in small series with RT following incomplete resection or recurrence; the efficacy following malignant degeneration is less apparent (44).

### 3.6 Rare low-grade neoplasms

Neurocytomas are clinically indolent tumors that present as intraventricular lesions, usually in the lateral ventricles with attachment to the midline septum pellucidum; most are diagnosed in adolescents and young adults. Neurocytomas are composed of small neuronal cells thought to represent a benign neoplasm derived from cells midway in the maturation process of neuronal differentiation (41). These tumors are genetically distinct from the oligodendrogliomas and dysembryoplastic neuroepithelial tumors (DNETs), with which they can be confused both clinically and histologically (42). The lesion is generally resectable; prognosis has been related to the rate of proliferation (43). These tumors respond to RT; small series have suggested improved outcome in cases with less than total resection when followed by RT. DNETs are biologically indolent, often large cerebral cortical tumors typically presenting with a long standing seizure history (45). Symptoms typically arise in children younger than 12 years; the mean age at diagnosis is 14. The tumors may be considered hamartomatous, classically are well demarcated, and show no contrast on MRI; uncommonly, DNETs present as complex solid and cystic lesions with enhancement, calcification, and intralesional hemorrhage (46). These tumors may be followed, but S is needed for seizure control; although they appear to be responsive to RT, there is no documented role for postoperative therapy (45).

### 3.7 Malignant gliomas

Supratentorial malignant gliomas represent approximately 6% of brain tumors in children. Histologic grading divides high grade gliomas (HGG) into anaplastic astrocytoma, WHO

Grade III and glioblastoma, WHO Grade IV (1). Children have a higher proportion of anaplastic astrocytomas among the malignant gliomas and have longer survival intervals (47). Adult primary malignant gliomas appear to arise *denovo* and are associated with amplification of the epidermal growth factor receptor (EGFR) gene and PTEN; less common secondary malignant gliomas evolve from low grade tumors and typically have TP53 mutations (48). Supratentorial malignant gliomas arise primarily as cerebral hemispheric tumors; 20–30% present centrally in the thalamus or basal ganglia. Imaging characteristics are similar to those in adults, with often poorly marginated, peripherally enhancing lesions on MRI or computed tomography associated with surrounding white matter changes due to edema; the enhancing components correlate with the cellular, vascularized periphery of the tumor complex. The infiltrative characteristics of HGG necessitate some caution in aggressive S and high-dose local RT; interest in functional imaging for both stereotactic surgical planning and RT reflects the acknowledged heterogeneity of the tumors and invasiveness beyond areas identified by anatomic imaging (49). Even with acknowledged infiltration at a distance from the overt tumor, clinical data show both a direct relationship between the degree of resection and duration of tumor control as well as a pattern of failure that is overwhelmingly at the primary target volume even after high dose focal RT (50,51). Leptomeningeal dissemination had been reported in up to 15% of children at diagnosis; however, a large prospective CCG trial showed disease beyond the primary site only anecdotally (52). The diagnosis of HGG in children has often been challenging to the neuropathologist. Central review of pathology in the CCG-945 trial showed that 36% of cases entered, based on an institutional diagnosis of anaplastic astrocytomas or glioblastoma, were felt to have a discordant diagnosis, primarily LGA, based on the reviewers' interpretation (53).

### **3.7.1 Therapy**

#### **3.7.1.1 Surgery**

Surgical resection often has been limited in extent by the poorly circumscribed nature of the tumor and the attendant lack of aggressive neurosurgical intent. The large CCG series indicated that more than GTR and near total resection was achieved in only 37% of cases: 49% of lesions arising in the superficial cerebral hemispheres, 45% of lesions arising in the cerebellum, and 8% of those arising in the central structures (50). There is a significant relationship between degree of resection and outcome. Five year PFS in the initially reported CCG-945 experience was 44% and 26% for anaplastic astrocytomas and glioblastoma, after more than 90% removal, compared with 22% and 4%, respectively, after less aggressive resection (50).

#### **3.7.1.2 Radiation Therapy**

RT is a primary component of initial management of pediatric malignant gliomas. Adult studies have documented the impact of adequate RT on OS, although survival beyond 2 years occurs almost entirely among those with anaplastic astrocytoma rather than glioblastoma. Treatment has evolved to local RT, with margins reflecting the known pattern of microscopic extension and functional imaging to guide evolving therapeutic approaches. A series of dose escalating trials have yet to demonstrate a convincing impact on disease control (51,56). Current trials use 3D conformal RT or IMRT to dosage levels, similar to those used in adults (51,57).



### 3.8 Embryonal CNS tumors: Primitive neuroectodermal tumors and pineoblastoma

Primitive neuroectodermal tumors (PNETs) are aggressive cerebral tumors occurring predominantly in young children comprising 2–3% of pediatric CNS neoplasms. The tumor consists of undifferentiated neuroepithelial cells with areas of divergent differentiation toward glial, neuronal, and mesenchymal lines (1). Embryonal tumors typically present as solid or partially cystic lesions. Although PNETs and cerebral neuroblastoma may present as well demarcated lesions, most embryonal tumors are generally invasive (58). Leptomeningeal dissemination is apparent at the time of diagnosis or at the time of initial tumor recurrence or progression in approximately one third of children; there is some controversy regarding the frequency of CSF failure in initially localized cerebral neuroblastoma, but most reports indicate CNS dissemination at a rate similar to that of the other embryonal tumor types (59). Medulloepithelioma is the most primitive embryonal tumor, histologically showing features of primitive medullary epithelium and primitive tubular structures; focal differentiation toward glial, neuronal, or mesenchymal lines is often present. Primitive polar spongioblastoma is a rare cerebral tumor thought to be derived from migrating glial precursor cells and characterized by immature unipolar glial cells. Ependymblastoma is a poorly differentiated embryonal tumor with ependymal differentiation marked by multilayered rosettes similar to those seen in retinoblastoma (1). The tumor is felt to be a specific embryonal neoplasm, different from the differentiated and anaplastic ependymomas that occur both in the posterior fossa and supratentorially. Cerebral neuroblastoma ranges histologically from an undifferentiated tumor similar to the extra-CNS childhood neuroblastoma, often including unilayered Homer-Wright rosettes, to lesions demonstrating ganglionic differentiation (60). The tumor most often confused with medulloblastoma histologically and by contiguous anatomic location is the pineoblastoma. The tumor is believed to arise from pineal parenchymal cells, histologically signified by undifferentiated small round cells, usually including scattered Homer-Wright rosettes. (61).

#### 3.8.1 Therapy

The basic principle of S is often limited by disease site and extent. The PNETs may be resectable in up to 50% of cases, especially when cystic (58,59). Pineoblastomas are generally approached for stereotactic biopsy or limited resection (61,62). Postoperative RT is indicated for the embryonal CNS tumors. Classic studies indicate disease control in fewer than 25% of cases with sPNET and pineoblastoma (58,63). A review of the SIOP/UKCCSG experience showed high rates of disease control with cranio spinal irradiation (CSI) for pineoblastomas with or without CT. The use of immediate postoperative RT and subsequent CT in CCG resulted in a 60% survival rate in children over 1.5–3 years with pineoblastomas (61). Overall results in other more recent series highlight interest in high-dose CT (e.g., high-dose methotrexate in the HIT regimens from the German studies or high-dose therapy with peripheral stem cell rescue) following irradiation (64).

### 3.9 Intracranial germ cell tumors

Intracranial GCTs are rare in North America and Europe, representing less than 2–4% of pediatric CNS neoplasms; in Japan and Taiwan they are reported to represent up to 11% of childhood brain tumors. The full range of germ cell histotypes presents as primary CNS tumors: pure germinomas (60–70% of intracranial GCTs), “malignant” germ cell types (embryonal carcinomas, endodermal sinus tumors, and choriocarcinomas, collectively 15–

20% of CNS GCTs), and teratomas (benign, immature, and malignant types, 15–20%) (1). Malignant teratomas are admixtures of benign teratomatous lesions with one or more malignant germ cell lines such as embryonal carcinoma, endodermal sinus tumor, or choriocarcinoma or with malignant elements of rhabdomyosarcoma, neuroblastoma, or epithelial carcinoma (65,66,67). GCTs are conventionally categorized into two highly prognostic histological subgroups: pure germinomas and non germinomatous (or “malignant”) germ cell tumors (NGGCTs). NGGCTs include GCTs with any malignant germ cell component and or any tumor that secretes AFP or high levels of  $\beta$ -HCG. Some international trials have classified these tumors simply as “secreting” and “non secreting” based on the high likelihood of secretion from malignant germ cell components and lack germinomas (68). Pure germinomas carry a much more favorable prognosis, and therefore are generally treated less aggressively than NGGCTs. CNS GCTs usually occur as midline third ventricular lesions. These tumors most often arise in the pineal region (50–60%) or from the infundibulum-pituitary stalk in the suprasellar region (30–35%). Less common locations for primary intracranial GCTs include the basal ganglia or thalamic nuclei (67,68). Involvement of multiple tumor sites around the third ventricle is common, most often the pineal and suprasellar regions concurrently; such tumors are referred to as “multiple midline germinomas” and appear to represent multicentric tumor development or subependymal infiltration around the ventricle rather than subarachnoid or CSF pathway metastasis. Up to 20% of intracranial germinomas present as multiple midline tumors, especially noted in adolescent males; this phenomenon is much more frequently encountered with pure germinomas, but has been reported with NGGCTs (69). Leptomeningeal spread through the cerebrospinal axis may be seen, but is much less common. Pineal germinomas occur with a higher prevalence in adolescent males. Suprasellar germinomas occur throughout the first two decades; there is no gender predilection for this location. Teratomas tend to occur in younger children, and other malignant histiotypes (e.g., embryonal carcinoma, endodermal sinus tumor) generally present in older children, adolescents, and young adults. A unique spectrum of neoplasms presents a broad differential diagnosis for tumors arising in the posterior third ventricular region. Approximately 80% of the pineal region tumors in children and adolescents are GCTs (60–70%) or pineal parenchymal tumors (10–20%). In very young children, the most common tumor type is the pineoblastoma. Less common histiotypes include glial tumors (astrocytomas, ependymomas) and arachnoid cysts. Pinealoblastomas are embryonal CNS tumors described earlier. Pineocytomas are “mature” parenchymal cell neoplasms, which are rare in children, clinically benign in adolescents but potentially malignant in younger children (70). The differential diagnosis for suprasellar tumors is also rather broad, including astrocytomas and craniopharyngiomas (together, more than 80% of lesions in this location) as well as GCTs. Pineal GCTs present most often with increased intracranial pressure caused by compression of the adjacent Sylvian aqueduct. Ocular signs are classically noted as the Parinaud syndrome: a triad of decreased upward gaze, abnormal pupillary responses described as near-light dissociation (limited constriction to light but retained pupillary response to accommodation; otherwise known as the Argyll–Robertson pupil), and convergence nystagmus (71). Findings occur as a result of pressure from the pineal tumor on the superior colliculus of the tectum. In suprasellar GCTs, the classic triad of presenting symptoms is diabetes insipidus, precocious or delayed puberty and visual deficits. Diabetes insipidus or other symptoms of suprasellar disease in conjunction with an apparently isolated pineal tumor are virtually diagnostic of a multiple midline germinoma

and should be treated as such. Conversely, care should be taken in evaluating the pineal region with suprasellar tumors (72). Evaluation for GCT should include MRI of the brain with and without gadolinium with thin cuts through the suprasellar and pineal regions. A screening MRI of the spine should be obtained with axial images through any regions suspicious for disease. Lumbar puncture with CSF cytology and CSF AFP and  $\beta$ -HCG should be obtained with caution, especially in children with large pineal tumors or potentially persistent increased intracranial pressure. Serum AFP and  $\beta$ -HCG should also be measured. AFP is usually present in serum and CSF in embryonal carcinoma, endodermal sinus tumor, or malignant teratoma.  $\beta$ -HCG is elevated in a subset of germinomas (10–20% of pure germinomas show levels above 10 IU, up to 70–100 IU; levels above 100–200 IU are found in germinomas with syncytiotrophoblastic giant cells); significant elevation (typically more than 1000IU) is diagnostic of choriocarcinoma (67,73). If there is any detectable elevation of AFP above institutional norm (generally, serum 5–10 ng/dL; CSF 2–5 ng/dL), this is diagnostic of malignant germ cell histiotypes; the tumor is classified as an NGGCT.  $\beta$ -HCG elevation may be seen in pure germinomas; the appropriate cut-off for categorization as a NGGCT is controversial. The COG ultimately recognized values 75 to 100 IU/L; this may be a conservative number (74). Additional baseline studies should include a full evaluation of hypothalamic and pituitary function, ophthalmological examination, and baseline neuropsychological testing.

### 3.9.1 Therapy

Treatment of CNS GCTs is controversial, from the decision to establish histology to the role of S, radiation parameters, and CT. Although excellent disease control has been reported in series based on clinical and imaging diagnosis without histological confirmation, specific RT, CT, and S are best guided by a histologic diagnosis. At present, clinicians routinely recommend confirmation of pathology for all GCTs, regardless of location. When there is a significant elevation of tumor markers in serum or CSF, clinicians may consider the diagnosis of an NGGCT without a biopsy. Similarly, a classical imaging presentation with  $\beta$ -HCG above normal is sometimes considered pathognomonic of germinomas. Others advocate for histological verification in all settings, as some studies indicate important prognostic implications based on histological subtypes (67,75). Historically, the non operative approach for pineal region tumors had been to assume the relative dominance of germinoma, especially among adolescent males with pineal region tumors, and initiate local irradiation as a “histologic test.” Prompt tumor reduction after 20–25 Gy was interpreted to be diagnostic of germinoma, and subsequent therapy used modified radiation parameters based on institutional use of local, cranial, or CSI fields (76). If a tumor showed limited early response to the “test” dosage, then S was entertained, or subsequent therapy was based on the presumption of a benign or malignant tumor. Major improvements in neurosurgical techniques have markedly decreased rates of morbidity and mortality and in modern practice, the “radiation dose test” is not a recommended approach. RT has long been the standard sole treatment or an essential element of treatment for pure germinomas; it is an important component of multimodality therapy for NGGCTs. Intracranial pure germinomas are quite chemoresponsive; the use of combined CT and limited-volume and or limited-dose irradiation has been an alternative approach in treating these tumors (77). The use of CT alone has been associated with unacceptable recurrence and mortality rates for GCTs (83). For NGGCTs, RT alone has achieved disease control in only 20–45% of tumors, and combined modality therapy, also including CT and potential surgical resection, is standard (75,76,78).

### 3.9.2 Surgery

The goal of surgical resection or biopsy is to provide accurate diagnosis, and in some cases, improve disease control. For patients with suspected GCT without elevation of tumor markers, biopsy is considered mandatory to confirm diagnosis of germinoma and to attempt to rule out malignant germ cell components. Contemporary surgical techniques permit stereotactic or open biopsy for both suprasellar and pineal region tumors with low rates of morbidity and mortality (79). Although it is clear that limited tissue sampling may lead to misdiagnosis for some patients, particularly in the setting of a mixed histology tumor, aggressive up front resection is not advocated by the majority of institutions in Europe and North America as higher rates of morbidity and mortality have been encountered; delayed S for persistent disease after CT is preferred (80). There is no known advantage to achieving a GTR for pure germinomas. However, a benefit of surgical resection for NGGCT has been suggested even if it is somewhat controversial (78,81,82). Some series have shown a trend toward improved control with more aggressive resection for malignant histiotypes. As stated above, others advocate initial CT with consideration of second-look S for tumors or components of tumors that do not respond. Often, teratoma components of these tumors do not respond to CT and may even grow, for these cases, surgical resection is therapeutic and provides local control. For patients with pineal region tumors that present with hydrocephalus, decompression of the ventricles is required, often urgently. The placement of a ventriculoperitoneal shunt or external ventricular drain can provide relief of hydrocephalus. Endoscopic third ventriculostomy is a particularly attractive, alternative method of treating hydrocephalus by diverting CSF flow and obtaining a biopsy under direct visualization. This procedure is more sensitive than MRI for detection of metastatic deposits

### 3.9.3 Radiation Therapy

For pure germinomas, RT has been the major curative modality. Long-term disease control rates range from 80% to more than 90–95% with the use of irradiation alone (76,83,84). There is ongoing controversy regarding the appropriate RT volume (local tumor with or without wider volumes that have included third ventricular, full ventricular, full cranial or CSI) and dose (40–50 Gy for primary RT). Whether primary RT is the best course of treatment, is often a complex decision based on tumor site and extent, the child's age, and the child's functional status at presentation, presenting a choice between RT alone or a combination of CT and reduced-dose, limited-volume irradiation (85). The recently closed COG trial, ACNS 0232, attempted to determine the better treatment; RT alone or CT and response based reduced volume and dose irradiation. Unfortunately, this trial closed due to poor accrual leaving this important question unanswered. For NGGCTs, combined CT and RT is the standard, again with some uncertainty regarding the appropriate radiation volume: local, whole ventricle, whole brain, or CSI (78,79). The use of stereotactic radiosurgery to boost local disease visible on imaging after and persistent after CT and fractionated RT is rational, but investigational for children with persistent NGGCT that cannot be safely removed by S (88).

### 3.9.4 Chemotherapy

Intracranial GCTs are chemosensitive, with excellent objective response rates documented for cyclophosphamide; carboplatin; cisplatin and etoposide; ifosfamide, carboplatin, and etoposide; cisplatin, etoposide, and bleomycin (73,81,86). Objective response rates approach 100% for germinomas (89,90). Several series using pre irradiation CT and limited-volume,

“response-adjusted” attenuation of radiation doses has shown excellent disease control rates. Initially explored in the United States by Allen with the use of cyclophosphamide and, later, platinating agents, this treatment has resulted in a large proportion of complete or substantial responses, with long-term disease control after local irradiation to reduced dose levels of 24–36 Gy (78,86,89). Carboplatin, most often in combination with etoposide, has replaced cisplatin for germinomas because the drug is associated with fewer long-term sequelae (90). The major short-term morbidity has been difficulties handling fluid and electrolyte balance in children with suprasellar tumors, often associated with diabetes insipidus and/or salt-wasting syndromes. This has been associated with early mortality during CT. The aim of combined CT and RT has not been to improve disease control, but to potentially improve long-term functional outcomes by decreasing radiation doses and/or volumes (85,91). The recently abandoned Phase III COG study had randomized patients with local disease to whole ventricular RT followed by a boost to the primary tumor bed or pre irradiation CT (two cycles of carboplatin and etoposide) followed by involved field, reduced dose RT if complete response was documented; if not, two cycles of cisplatin and cyclophosphamide were administered. Radiation dose depended upon response at the completion of the additional CT. For patients with disseminated disease, CSI was required, doses depend upon response to CT. The use of CT alone for intracranial germinomas has been tested in the international protocols coordinated by Balmaceda and colleagues (74). This trial included pure germinomas and NGGCTs. The first drug regimen tested (carboplatin, etoposide, bleomycin, cyclophosphamide) achieved high initial response rates, but disease progression or recurrence occurred in 50% of patients (both pure germinomas and NGGCTs); unacceptable CT-related mortality approximated 10% (83). Failures occurred primarily in the primary site at the ventricular system, with 5% in the spine. Although Merchant et al. (94) reported systematic salvage following CT-alone failure with high-dose cyclophosphamide and craniospinal irradiation, the more aggressive combined therapy regimen is excessive in a significant cohort of children who would enjoy favorable outcome with less intensive initial RT. For NGGCTs, prognosis with irradiation alone is inadequate; overall long-term survival rates approximate 20–40%. The addition of platinum-based CT has markedly improved outcome, with short-term OS rates in excess of 70%. CT has become a standard component of therapy for these tumors prior to RT. CT on both the French Society of Pediatric Oncology (SFOP) and recently completed COG study used alternating cycles of carboplatin-etoposide and ifosfamide-etoposide (93). The regimen has been both efficacious and well tolerated. High-dose CT with stem cell rescue has shown promise for relapsed GCTs (94). For the subgroup of patients who do not experience a CR to all other modalities of treatment, this approach has been considered and was recommended for patients who did not undergo CR to CT and could not safely undergo a second look S.

### 3.10 Posterior fossa brain tumors

Nearly one half of all childhood brain tumors arise in the posterior fossa. The most common types are medulloblastoma, LGA of the cerebellum, brainstem gliomas, and ependymomas.

### 3.11 Medulloblastoma

Medulloblastoma (MB) is a primitive cerebellar tumor of neuroectodermal origin. The tumor is the most common malignant brain tumor in children and adolescents, accounting for 20% of pediatric brain tumors. The classic description defined MB an embryonal tumor of the

cerebellum, derived from undifferentiated progenitor medulloblasts located in the cerebellar external granular layer. The WHO classification of CNS neoplasms identifies embryonal tumors as a subset of the neuroepithelial neoplasms that are particularly prominent among pediatric brain tumors (1). Histologically, MB is a densely cellular neoplasm composed predominantly of undifferentiated small, round, blue cells. Differentiation may be toward neuronal or glial lines in the more common "classic variant" (1,95). Differentiation along mesenchymal lines defines a variant called medulloblastoma. Approximately, 10% to 20% of MBs can be categorized as desmoplastic type, marked by relatively hypocellular areas of prominent nodularity in reticulin-free zones, occurring most often in the cerebellar hemispheres. Desmoplastic MB is associated with mutations within the sonic hedgehog (SHH)-patched (PTCH) pathway and overexpression of IGF-2 (96,97). There is considerable excitement about the SHH pathway as a target for newly developing molecular-targeted therapies (98). Anaplastic tumors are marked by nuclear pleomorphism and high mitotic rate; these tumors overlap with large cell MB and are marked by chromosomal loss 17p, MYC amplification, and poor prognosis (97). Over expression of ERBB2 may also be related to anaplastic large cell tumors and is a similarly negative prognosticator. The histologic grade of MB has only recently been linked to prognosis. Extensive nodularity has been correlated with favorable outcome; desmoplastic variant is similarly a marker of more favorable diseases (99). The degree of anaplasia has been associated with inferior survival rates (100). Tumors with extra neural metastasis, either at diagnosis or as a pattern of failure, are more often associated with markedly anaplastic histology. From the clinical genetics standpoint, MB is the CNS tumor most often associated with germ line mutations and familial diseases. The most frequent association is between Gorlin syndrome (nevroid basal cell carcinoma syndrome) and desmoplastic MB, both related to the tumor suppressor gene PTCH and the SHH receptor. In addition, mutations of the SHH-PTCH pathway are found in 10% to 20% of "sporadic" MB. TP53 mutations mark the Li-Fraumeni syndrome, associated with a small percentage of MB. Mutations of the APC gene define Turcot syndrome of colonic polyposis, also seen in conjunction with MB. Mutations of the WNT pathway, developmentally linked to proliferation of stem cells in the sub ventricular zone, were first noted in children with Turcot syndrome. The pathway is activated in 5% to 10% of sporadic MB with classic histopathology, manifest by accumulation of intranuclear  $\beta$ -catenin and associated with quite favorable prognosis; Wnt/Wg-active tumors are associated with iso -chromosome 16 (98,100). Notch 2 over expression has also been noted in MB, interesting as hypoxia appears to promote neural stem cell proliferation through Notch. Other molecular correlations important in understanding the current directions in MB include TrkC expression, directly proportional to survival and ErbB2 expression. The latter factor is biologically related to cerebellar granular cell proliferation, migration, and invasion; elevated levels of ErbB2 are associated with poor outcome. The median age at diagnosis is 5 to 6 years. Approximately 20% of MB present in infants younger than 2 years and 10% occur in young adults. Boys are affected more often than girls. Presenting symptoms are those classically associated with posterior fossa lesions in children: symptoms related to elevated intracranial pressure and ataxia. Elevated intracranial pressure results from the tumor obstructing CSF flow through the sylvian aqueduct and the fourth ventricle. Approximately 75% of MB present in the midline cerebellar vermis. The tumor characteristically grows into and fills the fourth ventricle. Infiltration around the fourth ventricle is common, often involving the brachium pontis and extending onto the ventricular floor. Nearly one in four tumors arises within the cerebellar hemispheres, more commonly with desmoplastic

histology. On MRI, MB is well-defined, solid lesions with uniform or, less often, no homogeneous contrast enhancement. Correlation between MR spectroscopic findings and metastasis at diagnosis has been reported (101). By computed tomography, the tumor often is hyperdense, reflecting high cellularity. MB is the classic CNS tumor associated with CSF seeding or metastasis. The standard of care requires postoperative staging, based on imaging of the brain to assess degree of resection and potential subarachnoid metastasis, spinal MRI and lumbar CSF cytology. Subarachnoid dissemination has been reported at diagnosis in 20% to 35% of children (102). Neuraxis disease typically involves the spinal subarachnoid space; intracranial metastasis is less common. The Chang (103) clinical staging system was developed in the pre-CT era and is based on the size and invasiveness of the primary tumor at surgery ("T stage") and evidence of spread outside the posterior fossa ("M stage"). Progressive tumor size and invasion of the brainstem defined increasing local tumor burden and aggressive behavior, classified as T 1–4. With the advent of computed tomography and MRI, it became apparent that imaging identification of brainstem invasion is not as reliable as surgical observation. There are no modern data to substantiate a role for T stage as an independent parameter predicting outcome or defining therapy (104,105). Comparisons in otherwise early MB (defined as M0 with complete or near total resection) and in series addressing advanced MB have shown equivalent outcome among those with brainstem invasion (T3b) and those without such (T1–3a). M stage is based on subarachnoid metastasis, coding abnormal CSF cytology (M1) or imaging evidence of non contiguous tumor in the cranium (M2) or spine (M3). Extraneural disease is present in fewer than 2% of cases at presentation, coded as M4. M stage remains a highly significant prognostic factor; intensity of therapy in current protocols and outcome are strongly related to the presence or absence of metastatic disease (106). Current clinical trials and standard management in North America define clinical risk categories for MB as average risk (children older than 3 years with no metastatic disease after near total or total resection, with less than 1.5 cm<sup>2</sup> residual on early postoperative imaging) or high risk (overt metastatic disease based on CSF cytology or neuroimaging, or the presence of more than 1.5 cm<sup>2</sup> residual on early postoperative imaging; more recently, all children younger than 3 years of age typically have been classified as high risk. With appropriately aggressive surgical intent in most centers in the United States and Europe, more than 65% to 75% of children above 3 years of age are staged as average risk. Of the 25% to 35% staged as high risk, more than 85% present with metastatic disease at diagnosis: primarily M3 (60%), but also M1 (30%), and M2 (10%); significant residual tumor at the primary site is present in ≥15% of cases (101).

### 3.11.1 Therapy

#### 3.11.1.1 Surgery

In 1930 Harvey Cushing demonstrated the inability of S alone to cure MB; only 1 of 61 patients survived 3 years after S with or without limited RT (107). Maximal judicious surgical resection underlies most contemporary series. GTR (no evidence of residual tumor seen at S and negative post-operative imaging) and near total resection (more than 90% resection estimated by the surgeon and less than 1.5 cm<sup>2</sup> residual on postoperative imaging) have resulted in superior outcome in comparison to subtotal or partial resection and biopsy only. Data from the Children's Cancer Group (CCG) indicate gross total or near total resection in approximately 90% of children (104). In an earlier CCG trial, 5-year EFS was 78% for children with M0 disease and less than 1.5 cm<sup>2</sup> residual,

compared with 54% for those with larger residual volumes. For tumors adherent to or invading the brainstem, a report from St. Jude Children's Research Hospital showed no advantage to pursuing GTR compared with near total removal, with none of the cases exhibiting more than 1.5 cm<sup>2</sup> residual; morbidity appeared to be greater with the more aggressive surgical approach. With maximal safe resection a principle of therapy, the impact of minimal residual is difficult to discern; key is the distinct advantage of treatment on an average-risk regimen whenever possible, assuming such is a M0 disease (106). Operative mortality has been reduced to 2% or less in pediatric neurosurgical centers. However, aggressive S may be associated with significant morbidity (107,108). The posterior fossa syndrome has been described in 15% to 25% of children after posterior fossa craniotomy (109). The syndrome is signified by difficulty swallowing, truncal ataxia, mutism, and, less often, respiratory failure; recent imaging data suggest the etiology may be a cerebello cerebral diaschisis (110). The routine use of ventriculoperitoneal shunts to reduce intracranial pressure before posterior fossa craniotomy resulted in significant improvement in morbidity and mortality, when introduced 40 years ago. Children with ventriculoperitoneal shunts typically become shunt dependent. Shunt failure or infection may complicate long-term survival, necessitating revision or replacement in nearly 25% of children measured 5 years after insertion. In many academic pediatric neurosurgical centers, it is a standard procedure to place a ventricular drain, as needed, at the time of S. The surgeon often can document reestablishment of CSF flow after fourth ventricular tumor resection. Later shunt insertion may be needed in 20% to 25% of children (111,112). A delayed shunt insertion approach provides physiologic CSF dynamics for the majority of children, avoiding potential late events related to a ventriculoperitoneal shunt.

### 3.11.1.2 Radiation Therapy

The efficacy of RT in MB was reported within a decade of Cushing's initial description of the tumor. Cutler et al. (113) reported the radiation responsiveness of MB and the value of preventive RT of the entire neuraxis based on Cushing's clinical series. The seminal report documenting cure of MB with CSI was published by Bloom et al. in 1969: they reported 32% survival at 5 years and 25% DFS at 10 years (114). Numerous reports have subsequently confirmed increasing rates of disease control with modern radiation techniques; at standard CSI dose levels, RT alone achieves durable disease control in 65% to 75% of patients with average-risk disease (115). Modifications of radiation volume, dosage, and fractionation have been explored. The outcome following postoperative irradiation alone in average-risk MB using conventional radiation parameters (POG-CCG trial, one arm of which used CSI to 36 Gy, posterior fossa boost to 54 Gy resulting in 65% 7 year EFS) has been used as a basis for non randomized comparisons in establishing current standards for combined modality therapy in North America. The result is systematic reduction in CSI dosage to 23.4 Gy; with well documented efficacy now in average-risk disease when combined with contemporary cisplatin based CT (116,117). Agreement on combined chemo radiation is based on disease control rates that appear to be superior to those achieved with irradiation alone for both average-risk and high-risk presentations, a randomized European trial demonstrating improved outcome with chemo radiation compared to contemporary RT alone and several studies suggesting improvement in the risk: benefit ratio based on dose-volume modeling and evolving clinical data (118,119,120,121).



### 3.11.1.3 Chemotherapy

Phase II trials have documented the chemo responsiveness of MB to alkylating agents: platinum compounds, etoposide, antimetabolites, and camptothecins (122,123). The trial documenting the efficacy of adjuvant CT was reported by CCG, combining the attenuated CSI dose in average risk patients that had shown only 55% EFS at 5 years in the POG-CCG trial referenced in the prior section with concurrent vincristine and post irradiation cisplatin, vincristine, and CCNU; the 79% PFS at 5 years confirmed earlier institutional experience to show among the best disease control rates then documented in this (124). The International Society for Pediatric Oncology (SIOP)-United Kingdom Children's Cancer Study Group (UKCCSG) PNET-3 trial showed improved EFS with limited pre irradiation CT and full-dose irradiation versus equivalent irradiation alone: 78% EFS at 5 years with pre irradiation vincristine, etoposide, carboplatin and cyclophosphamide compared to 65% with irradiation alone (118). A large randomized trial assessing reduced-dose CSI followed by cisplatin and vincristine with "standard" CCNU versus cyclophosphamide confirmed overall EFS more than 80% with no difference in disease control on either CT arm; early analysis suggests that a larger number of secondary neoplasm may be apparent in the cyclophosphamide arm (117). St. Jude reported a prospective trial using post irradiation cyclophosphamide, vincristine and cisplatin; 83% EFS was obtained without sometimes toxic vincristine during RT and with a marked reduction in oto toxicity attending post irradiation cisplatin when the latter was given with amifostine (125). The standard of care for children with average risk MB throughout North America has been accepted as reduced dose CSI (23.4 Gy) followed by CT including an alkylating agent, vincristine and cisplatin. For patients with high risk disease, studies through the 1990s typically showed 5-year EFS at the 40% to 50% level following full dose irradiation and CT (126,127). St. Jude's SJMB 96 study has shown 70% 5-year EFS following the same CT, preceded by full-dose CSI. Randomized trials have shown somewhat conflicting results regarding the sequence of postoperative therapy: POG showed 60% 5 year EFS in high-risk MB regardless of postoperative preirradiation CT (cyclophosphamide, vincristine, cisplatin) or the opposite sequence, both using full-dose CSI. The German HIT'91 trial showed superior results with post operative RT followed by CCNU, vincristine and cisplatin compared to postoperative ifosfamide, etoposide, high-dose methotrexate, cisplatin and cytosine arabinoside followed by irradiation: 83% 5-year EFS compared to 53%, respectively for M0 patients; no difference was noted in the M2-3 cohort, both at 40% EFS (127). CCG 9931 documented a 17% PD rate during a prolonged, 5 month preirradiation regimen, again showing only 43% EFS in high-risk disease (121). Similar trials have noted that outcome in average-risk patients receiving preirradiation CT correlates with response to CT; in the Milan trial, those with CR-PR to preirradiation CT enjoyed 94% PFS compared to 61% if only SD or PD attended CT (128). Several studies note that the time to initiating irradiation is related to disease control. For disease recurrent after RT with or without CT, numerous studies demonstrate chemo responsiveness to single agents, multiagent combinations, and high-dose therapy with hematologic stem cell rescue. Except in the infant setting, durable secondary disease control following initial CSI has only rarely been achieved despite aggressive, high-dose CT and further irradiation (129,130,131). Local irradiation can provide further control at the primary site (132). Trials of intrathecal CT in this setting are of interest, but to date with only limited phases I and II data (133).

### 3.12 Embryonal and malignant glial tumors in infants and young children

Children younger than 3 years account for 15% to 25% of pediatric CNS neoplasms (134,135). Symptoms in this age group usually include enlarged head, lethargy, and vomiting. Tumors are predominantly supratentorial; in comparison to older children, infant tumors are more often malignant and may be more frequently metastatic at diagnosis. The most common types include astroglial tumors primarily low grade; among infants less than 1 year old, up to 25% are high-grade malignant gliomas, embryonal neoplasms and ependymomas. Atypical teratoid rhabdoid tumors (ATRTs) occur predominantly in this age group (1,136,137). A significant proportion of intracranial teratomas and choroid plexus tumors present in young children below 12 to 18 months of age. Infantile desmoplastic neuroepithelial tumors also arise predominantly in the very young. These lesions often are quite large, are peripherally located, and appear aggressive histologically, but typically display rather "benign," low-grade behavior, rarely recurring after primary resection (1). OS rates for the embryonal brain tumors presenting in children younger than 3 to 4 years are lower than for older children (138,139). Tumor type, pattern of growth, and the therapeutic ratio for both S and RT are unfavorable when compared to older children. Operative morbidity and mortality rates are higher in infants; after RT, cognitive dysfunction, somatic alterations, endocrine deficits, and neurotoxicity are more pronounced than in older children (140). For malignant gliomas, there is actually suggestion that outcome exceeds that of older children and adults, based on apparent differences in biology and disease response to CT (141).

#### 3.12.1 Therapy

For embryonal tumors with long-established chemosensitivity, a number of trials between 1985 and 2000 explored the use of prolonged primary postoperative CT using delayed, diminished, or no irradiation. Several large series documented a high rate of chemoresponsiveness to a "standard" four-drug regimen (including cyclophosphamide, cisplatin, vincristine, etoposide) or to systemic methotrexate; durable disease control without RT was limited to 25-35% of cases in most trials, typically in those with localized disease amenable to complete resection at diagnosis (135,140,142,143). Successive trials from the German POG tested progressively more intense systemic and intrathecal methotrexate with an alternating drug program incorporating the agents noted above. While overall PFS in the HIT SKK 87 trial (1987 to 1993) was 53% in the favorable resected, M0 cohort, the study showed youngsters with desmoplastic MB enjoyed nearly 90% PFS. The SKK 92 study (1992 to 1997) intensified methotrexate and noted overall 5 year PFS of 58%; among the resected M0 group, 5 year PFS was 82%, with 14 of 17 survivors treated with S and CT only, absent RT which was used only for residual progressive disease. Once again, the results with desmoplastic histology were exceptional: 85% PFS compared to 34% PFS in those with classic MB (144). The second direction was suggested by Khalifa and the French group, where primary CT showed only 29% PFS at 5 years even among the most favorable, resected M0 cohort. Notable was the OS rate of 73%, reflecting excellent "salvage" therapy with high-dose CT, busulfan-thiotepa, and local RT; among 39 patients treated, 5-year postsecondary treatment survival was 77% for those with M0 disease initially and at failure (143,145). Although the St. Jude group had also documented excellent salvage with CSI alone, the functional consequences of more limited RT in this age group seem self evident (140,142). Both POG and the Pediatric Brain Tumor Consortium (PBTCC) initiated trials in the late 1990s

testing CT with planned, localized irradiation after the initial 4 months of CT. Results are yet in analysis, recognizing that among the M0 group that proceeded to consolidative local RT on PBTC 001, 5-year PFS is 85% and OS, 95%. All infant trials to date have shown poor outcome for the 20% of patients presenting with neuraxis dissemination, OS rates rarely exceeding 10% to 25% (143,145). Although CSI is curative in a significant proportion of children, the consequences of CSI at effective dose levels are not considered acceptable (141). Alternative use of aggressive, high-dose CT alone has been fraught with otherwise unseen toxicity, including toxic deaths and EFS for favorable presentations approximating 50%; outcome in the M+ cohort has been essentially zero. Separate from MB is the immature, highly aggressive ATRT (1,146). ATRTs occur predominantly in young children, presenting in the posterior fossa; those occurring in children older than 3 years are more often supra-tentorial lesions. The lesions are histologically distinctive, and diagnosis by light microscopy and immuno-histochemistry is often definitive. The tumor is associated with monosomy of chromosome 22, a finding in common with extraneural primary rhabdoid tumors. Genetically, the tumor is associated with loss of the tumor suppressor gene hSNF5/INI1 in more than 75% of cases; absence of INI1 by FISH is diagnostic (139,146,147). Up to 15% to 25% of cases show leptomeningeal dissemination at diagnosis (148). Although ATRTs often respond to CT (especially carboplatin-containing regimens), the disease course has been marked by rapid recurrence and neuraxis dissemination. There is an increasing evidence that the outcome is related to post operative RT; recent trials incorporate early local RT for children as young as 12 to 18 months old, ideally limiting postoperative CT to 4 to 6 weeks (137,139,146,148). For children older than 3 years of age, use of post-operative CSI followed by CT has resulted in 78% 2-year EFS compared to 11% for younger children in whom irradiation was delayed or avoided (148).

### 3.12.2 Surgery

As in older children, complete resection is often the primary predictor of disease control; for infant MB, the differences in outcome strongly favor attempted GTR in every major series regardless of the type and intensity of postoperative management. In the initial Baby POG study, OS for MB was 40%, compared with 60% for the one third of children who had undergone GTR and 69% for those with GTR and localized disease (135). In the latest published GHOP trial, PFS among all M0 cases falls from 82% to 50% based on the absence or presence of residual tumor post S, respectively (144). Delayed definitive S has been utilized for sizable MB or supratentorial PNETs in this age group. After initial CT, tumors may be reduced in size and vascularity, resulting in more successful tumor resection. Choroid plexus tumors are often malignant carcinomas in this age group. The tumors typically arise in the lateral ventricles; histology can be uncertain in predicting benign or malignant behavior, with carcinomas marked largely by brain invasiveness and atypia. Complete resection alone appears to be adequate, with few recurrent tumors following imaging confirmed removal even without added CT or RT (149).

### 3.12.3 Radiation Therapy

Evolving combinations of systematic or selected consolidative RT, RT for disease progression, or multimodality salvage regimens incorporating low or high-dose RT have resulted in RT as a component of therapy for nearly half of all surviving children in this age group. Important in the context of current strategies is identification of those cases most

likely to benefit from local irradiation, with consensus developing toward noting those with classic histology and localized MB or those with incompletely resected M0 desmoplastic MB. Using planned RT, typically within the first 4 months of postoperative CT, is key to avoiding the scenario of requiring more aggressive irradiation and CT for those who progress during or after more prolonged CT. Although salvage CSI has been successful in controlling more than 40% of recurrent MB, the ultimate 40% to 60% disease control was balanced by a median IQ of only 62 at 7 years (149). The latter finding has dampened enthusiasm for salvage CSI, at least at dosage levels greater than 24 Gy, in this age group.

#### **3.12.4 Chemotherapy**

The initial van Eys study of primary mechlorethamine vincristine, procarbazine, and prednisone (MOPP) CT at M.D. Anderson Cancer Center showed long term survival in 8 of 11 infants with MB; 6 had not received RT (150). In the first POG trial with initial postoperative CT, the regimen included cycles of cyclophosphamide with vincristine and cisplatin with etoposide; response rates varied between MB, 48% partial and complete response rate among those with imaging residual, and malignant gliomas, 60% (110). PFS and OS rates at 5 years were 32% and 40% for MB, 43% and 50% for malignant gliomas, and 0% and 0% for pineoblastomas; overall 5 year survival was 27% for supratentorial PNETs (107). As in subsequent infant trials, failures beyond 2 years have been uncommon except with ependymomas (140, 142,145,146). Most of the subsequent infant studies have used variations of the four drug regimens noted in the first POG trial; more intensive regimens have shown benefit in specific subsets of infant malignant tumors (143). The Head Start series of intensive CT have evolved to similar four drug induction with second S for residual local tumor, followed by myeloablative doses of thiotepa, etoposide, and carboplatin. In the selected M0 resected medulloblastoma cohort, EFS at 5 years was 52%; OS of 70% those requiring irradiation for disease progression; toxicity has remained a problem with this approach.

#### **3.13 Ependymomas**

Intracranial ependymomas represent 5% to 8% of intracranial neoplasms in children. More than 90% of pediatric ependymomas occur as intracranial tumors; primary spinal cord tumors are relatively uncommon in children, where ependymomas represent 25% of primary spinal tumors. Two-thirds ependymomas in children present as posterior fossa lesions, arising along the inner surface of the fourth ventricle or at the cerebellopontine angle (CPA). It is quite common for such tumors to grow into the foramina of Luschka, on either side of the brainstem, toward and to the CPA (151,152). Presentation in the CPA is noted less commonly, occurring particularly in very young children. Fourth ventricular tumors also extend caudally beyond foramen magnum and into the upper cervical spine; extension is either from caudal growth from foramen of Luschka or, more commonly, through the foramen of Magendie and then posteriorly from the cervicomedullary junction caudally (153). Growth below the foramen magnum marks nearly 50% of fourth ventricular lesions. Supratentorial ependymomas account for one third of childhood presentations, occurring predominantly as extra ventricular cerebral hemispheric tumors; growth is commonly adjacent to the third or lateral ventricular regions (153). Ependymomas consist histologically of polygonal cells with large vesicular nuclei and cytoplasmic granules. Characteristic are ependymal rosettes, formed by tumor cells oriented radially around a

central lumen; cells also have a tendency to orient themselves around blood vessels, forming perivascular pseudorosettes (1,154). Molecular genetic analyses highlight the origin of ependymomas from populations of neural progenitor cells that are genetically distinct in the supratentorial, posterior fossa, and spinal regions anatomically related patterns of gene expression and regions of chromosomal loss or gain mark the three sites independently (154).

The WHO classification defines ependymomas as grade 1 (subependymomas or myxopapillary spinal ependymomas), grade 2 (classical ependymomas, including cellular, papillary, clear cell, and tancytic types), and grade 3 (anaplastic) (1,154). Subependymomas are benign neoplasms most often arising under the fourth ventricle, but also similarly adjacent to the lateral ventricles. Myxopapillary tumors are indolent lesions occurring primarily in young adults, specifically in the region of the cauda equina. Cellular tumors occur in extraventricular regions with a relatively low mitotic rate. Papillary ependymomas present along the ventricular surfaces. Clear cell tumors mimic oligodendrogliomas histologically, occurring primarily as supratentorial lesions; there is a suggestion that this variant is somewhat aggressive. Tancytic tumors grow as fascicles, usually within the spinal cord. Anaplastic ependymomas are marked by high mitotic rate, microvascular proliferation, and pseudopalisading necrosis. Ependymoblastoma are extremely rare, highly malignant primitive embryonal tumors occurring in infants as supratentorial lesions with features of an ependymal neoplasm; they are not considered in the classification of ependymomas, but rather as embryonal tumors. There have been conflicting reports regarding the correlation between tumor grade and survival. Some prominent neuropathologists in the 1980s reported no correlation between anaplasia or grade and clinical behavior (155). More recent series identify histology as one of the dominant features related to disease control after aggressive S and RT (156). Merchant et al. (157) reviewed the St. Jude historical experience, noting 3 year PFS of 84% among the 70% of children with differentiated ependymomas and 28% for the 30% of cases with anaplastic features. Late follow-up of Merchant's expanded series confirms the impact of tumor grade on outcome. Multi-institutional reviews reflecting independent experience at 11 major US centers and that within the former POG document histopathology as a significant factor, with higher rates of 5-year EFS associated with differentiated histology but no statistical difference in OS for those with anaplastic tumors; the latter report includes a review of 1444 cases in the English literature between 1900 and 2005 substantiating such findings (158). Earlier data suggested a correlation between anaplasia and the frequency of neuraxis dissemination, particularly among fourth ventricular lesions. Merchant's recent report detailing the largest prospective trial similarly documents a significant correlation between anaplastic histology and a higher rate of distant failure (159). Chromosomal abnormalities are present in approximately 50% of tumors, most commonly loss of the long arm of chromosome 22 or 6 or gain in chromosome 1q. Alterations in the Wnt/ $\beta$ -catenin signaling pathway have been related to tumorigenesis in anaplastic ependymomas (160). The p53 pathway appears to be intact in ependymomas, although p53 induced G1 growth arrest is apparent in ependymomas, potentially implicated in radiation resistance (161). The tumors show expression of the ErbB receptors. Ependymomas are somewhat more common in boys, although young children show equal sex distribution or even a slight female predominance. The median age at diagnosis is 4 to 5 years; one third occur in children younger than 3 years, with typically inferior likelihood of disease control (151, 152,157,162). Ependymomas represent a somewhat higher proportion of CNS tumors in infants and young children.

Symptoms usually are non specific and related to fourth ventricular obstruction with headaches, vomiting and ataxia. Children with disease involving the CPA often show torticollis or cranial nerve signs. MRI often shows a non homogeneously enhancing lesion, diagnostic when there is characteristic involvement through the foramen of Luschka. Computed tomography often shows stippled calcification.

### **3.13.1 Therapy**

#### **3.13.1.1 Surgery**

Extent of resection is the dominant factor influencing outcome. Fourth ventricular lesions usually are adherent along the brainstem, especially at the level of the obex, where surgical damage can result in significant cardiorespiratory compromise. Total or near total resection has classically been realized in 50% to 75% of cases (151,156,162,163,164). Current image guided neurosurgical techniques and recognition of the importance of GTR have allowed major referral centers to achieve GTR in 80% to 90% of instances, sometimes requiring a second procedure to complete S before adjuvant RT (157). Even in very young children, complete or near complete resection is often feasible prior to initiating further therapy. The relationship between extent of resection and disease control has been apparent for several decades, with EFS averaging 50% to 75% after GTR compared with 30% to 45% with incomplete removal (165,166). With optimal postoperative RT in the prospective St. Jude trial, degree of resection is the single most significant correlate with outcome: 7-year EFS falls from 77% after GTR to 34% with near total or subtotal resection. Even in cases with metastatic disease at diagnosis, the impact of GTR on both 5-year EFS and OS is impressive, with 35% and 59% reported in a retrospective multinstitutional review. Total resection is associated with a low rate of operative mortality, 2.5% or less, and morbidity, 10% to 25% incidence of new neurologic deficits (167,168). Postoperative cranial nerve deficits are common, including components of the posterior fossa syndrome (164). The proximity of vital centers makes GTR in the fourth ventricle rather challenging, particularly for those arising in or extending to the CPA (164,166). Total resection of supratentorial ependymomas is more readily achieved (184). The St. Jude experience with GTR in 96% of tumors originating in the CPA is marked by a 30% major complication rate, including need for tracheostomy, gastrostomy feeding tube, or major cranial nerve palsies. The rationale, continued improvement in neurologic function over time, and overall functional status of often young children has encouraged the neurosurgical team to continue aggressive resection for primary presentations, second S before irradiation, or for local recurrence (175). In young children with moderate disease residual, the option of initial CT with delayed S prior to RT has been noted for some time and is still under exploration (167,168).

#### **3.13.1.2 Radiation Therapy**

RT has been a routine component of therapy for ependymomas since the 1950s. The favorable results summarized above, following GTR, are based on the addition of postoperative RT in almost all instances (151,163,164). Earlier, two classic retrospective series confirmed the contribution of RT: Pollack et al. (162) recorded overall 5-year survival of 45% with surgery and irradiation, compared with 13% with Surgery alone, while Rousseau et al. (163) noted 63% survival at 5 years after RT and 23% without. Although there are limited data from Epstein's New York University experience suggesting disease control for differentiated supratentorial ependymomas following S alone, there are very

little data documenting favorable disease control rates absent irradiation for posterior fossa presentations, patients with anaplastic histology, or those with any degree of residual disease (166). The prospective Italian Association for Pediatric Hematology and Oncology protocol reports inferior outcome when RT is deferred following S alone, with both inferior disease control and greater morbidity attendant to requisite second S. The excellent results with complete resection and postoperative RT, even in children as young as 12 to 18 months of age, are best demonstrated by Merchant's series from St. Jude, where assiduously contoured target volumes for 3D CRT to relatively high-dose levels resulted in 74% EFS at 5 years, with 87% local tumor control and 85% OS; the rate of local failure is 16% at 7 years (157). The series shows little decrement in outcome at 7 years, recognizing that longer term data reporting results from Children's Hospital of Philadelphia (CHOP), University of Pennsylvania, and Washington University, St. Louis, both show a 10% or greater decline in EFS and OS between 5 and 10 years postirradiation (169). The coordination of aggressive surgical resection and prompt postoperative RT, even in the younger age cohort, resulted in an excellent rate of tumor control and OS with noted but relatively low rates of acute and subacute morbidities from S and RT; prospective data suggest relatively limited functional morbidities to date (170). Disease control rates and local tumor control are equivalent in cohorts younger or older than 3 years in the St. Jude data, based largely on S and RT (157). The recently completed COG trial ACNS0121 studied children more than 12 months of age with postoperative RT for those with complete or near total resection except supratentorial differentiated ependymomas, the latter to be observed after confirmed GTR; children with significant local residual had the option of initial CT followed by second look S prior to RT. There is a modest literature regarding retreatment for ependymomas recurrent following prior S and RT, with or without CT. Resection and full dose local reirradiation to 50 to 54 Gy resulted in secondary disease control for 10 of 13 children following local recurrence; among 12 children with metastatic recurrence retreated with CSI, the 4 year secondary EFS was 53% (170). Tolerance has been surprisingly good, as reported in more eclectic series with stereotactic radiosurgery used for reirradiation in children and adults (171).

### 3.13.1.3 Chemotherapy

Ependymomas are only modestly chemosensitive tumors, with objective responses most apparent after exposure to cisplatin and oral etoposide (152,157,172). The only prospective, randomized trial that tested adjuvant CT (CCNU, vincristine, prednisone) after S and irradiation was completed by CCG in the early 1980's (173). The trial was small, but there was no suggestion of improved disease control with CT; a subsequent randomized trial of adjuvant CCNU-vincristine-prednisone versus the "8-in-1" regimen showed no improvement in either arm of the trial; the group concluded that local tumor control was the dominant issue, inadequately addressed systemically. Needle reported a limited institution pilot study in children 3 to 14 year old where moderately aggressive carboplatin-vincristine alternating with ifosfamide-etoposide resulted in a 74% 5 year PFS rate, noting half the cohort had incomplete resection; the data reflect a combination intentionally derived from infant protocols, and it is in the latter setting that further assessment of dose intensive CT is ongoing. Gilbertson's documentation of ERBB2 and ERBB4 coexpression in more than 75% of ependymomas specimens has prompted studies in the PBTC testing lapatinib, a molecular targeting agent active in preclinical models against ERBB expressing xenografts (174). Preliminary reports have not been encouraging with this approach, but trials of molecular agents are ongoing. Infant studies may be interpreted positively in documenting

that approximately 20% to 25% of children with ependymomas can be controlled with S and CT, absent RT; the more recent UKCCSG/SIOP study alone shows radiation free EFS at 5 years of 42% (157,158,175). The CCG 9921 experience resulted in 5 year EFS of 32% with OS of 59% (142). The multidrug regimens have included the traditional four drug combination (cisplatin, etoposide, vincristine, and cyclophosphamide) or, more recently, the UKCCSG/SIOP dose intensive regime including sequential carboplatin and vincristine, high-dose methotrexate and vincristine, cyclophosphamide, and cisplatin (157,158). The St. Jude experience with a carboplatin based regimen showed 33% 5 year PFS and 62% OS in a series utilizing post CT irradiation with any imaging evidence of residual (141). The impact of RT on disease control in young children had been suggested in the first POG infant brain tumor study: children less than 3 year old received RT after 1 year of CT and those younger than 2 years were scheduled to receive irradiation after 2 years of CT. Long-term disease control was significantly higher in the older cohort, interpreted as likely to be related to earlier RT (157). Part of the rationale for continuing primary CT in this age group is the potential ability for post CT S and RT to achieve ultimate disease control: the 5 year OS in the SFOP series was 59% despite the 22% rate of PFS. Timmermann et al. concluded that the 27% EFS at 3 years following HIT SKK 87 and 92 CT (high-dose methotrexate based, both systemic and intrathecal) is inadequate, resulting in local failures in 75% of cases prior to irradiation and a 3 year OS rate of 56% (176).

### 3.14 Brainstem glioma

The brainstem is the connecting structure that joins the long tracts from the cerebral hemispheres and midline diencephalic nuclei with the cerebellar tracts. Brainstem tumors are a heterogeneous group of tumors that share common astrocytic histologies but evidence divergent neoplastic behavior and degrees of differentiation, related to the anatomic region of involvement. Brainstem tumors are classified by the anatomic area involved and the macroscopic appearance or pattern of growth: focal lesions are tumors that are discrete or distinctly marginated on imaging, without apparent infiltration beyond the primary lesion, relatively limited in volume, and histology which is low grade, usually JPA, less often fibrillary astrocytoma (177,178). Focal tumors occur most often in the tectal plate and adjacent to pontine nuclei, sharing low grade histology with the largely exophytic tumors arising dorsally exophytic at the ponto medullary junction or in other locations of the brainstem (179). The more common diffusely infiltrating brainstem gliomas (DIBSG) arise in the pons, diffusely expanding the pons and extending rostrally to the cerebral peduncles of the midbrain and sometimes through the internal capsule of the thalamic region, or growing caudally to the medulla or upper spinal cord, less often through the peduncles into the cerebellum. DIBSG account for 75% to 85% of brainstem neoplasms in children and adolescents; focal and exophytic tumors represent 15% to 25% of cases (177,178,180,181). The duration of symptoms correlates with the type of brainstem glioma. Children with DIBSG report a brief history of neurologic symptoms, typically measured in weeks and certainly less than 6 months. Neurologic signs associated with the pontine DIBSGs include cranial nerve deficits, long tract signs, and ataxia; dyspraxia and dysphagia are also rather common (180,181). Elevated intracranial pressure secondary to obstructive hydrocephalus is often present in midbrain tumors or in the expansile dorsally exophytic tumors that fill the fourth ventricle, but noted in fewer than 15% of children with pontine DIBSGs. The focal brainstem



tumors are often associated with prolonged, more limited symptoms, findings confined to deficits in one or two cranial nerves alone, ataxia, or dyspraxia, typically with minor long tract signs and a history measured in months or years (177,179,181,182). MRI is the definitive test for diagnosis and delineation of tumor extent and type. The typical diffusely infiltrating pontine glioma is homogeneous and hypointense on T1 imaging but readily appreciated on T2 sequence. DIBSGs expand the pons, often showing exophytic growth in the ventral, dorsal, and/or lateral directions as infiltrating lesions with indistinct margins; gadolinium enhancement is usually absent or minimal. Diffusion tensor imaging and tractography often show sparing of the dorsal columns of the pons with infiltration splaying the longitudinal tracts. Focal brainstem tumors by definition show distinct margins, typically enhancing briskly. 18FDG PET is hypermetabolic in DIBSG; imaging histologic correlations show hyperactivity only among grade 4 or glioblastoma cases; anaplastic astrocytomas were isometabolic with normal brain or hypometabolic, while low-grade fibrillary gliomas were isometabolic (183). As a group, brainstem tumors constitute approximately 10% of intracranial tumors in children. The peak incidence occurs between the ages of 5 and 9 years; boys are affected more commonly than girls. The most common presenting symptoms for DIBSGs include diplopia, lateralizing motor weakness, and difficulty with speech, swallowing, and walking. Neurologic signs include ataxia, cranial nerve palsies and long tract signs. Tumors of the midbrain and medulla may be diffuse or focal; even diffuse tumors typically show much less infiltration and expansion of the brainstem than seen with the pontine gliomas. Focal intrinsic tumors do occur in the pons, often as localized tumors of a cranial nerve nucleus or along the cerebellopontine peduncle. Biopsy of the classic, diffusely infiltrating pontine glioma is generally unnecessary (178,181,182,184). Following trials in the 1980s of systematic open biopsy that yielded some of the basic knowledge correlating imaging and histopathology, biopsy related neurologic compromise has led most US and European centers to biopsy only the 15% to 20% of atypical brainstem tumors, often demonstrating JPA or fibrillary astrocytoma (183). Stereotactic guidance has resulted in a rather safe approach to the brainstem tumors, with series from Paris, Germany, and Brussels showing current histopathology and clinic imaging correlations while reporting only minor, typically transient new neurologic deficits in approximately 10% of instances (183,185). The more recent biopsy series shows rather divergent histopathology, clearly dependent on the selection criteria for biopsy: 22 of 24 children showed anaplastic astrocytoma or glioblastoma, with 1 PNET and 1 JPA reported from Hospital Necker-Enfants, compared to 10 of 20 in a more selected series from Brussels, the remainder showing fibrillary astrocytoma, JPA, PNET, or germ cell tumor (185). There is no consistent correlation between histology and outcome; all diffusely infiltrating pontine tumors show extremely poor duration of response to RT and median survival of less than 1 year (182, 186). Brainstem tumors have recently been shown to express ERBB1, with the degree of overexpression or less common amplification proportional to increasing histologic grade (187). The finding suggests that ErbB or EGFR inhibitors may be worth studying in these tumors, allowing selected therapeutic interventions. A protocol considered by the PBTC would select patients for temozolomide based on MGMT expression and erlotinib if EGFR is positive. A small subset of DIBSG may show CNS dissemination. Gururangan et al. described neuraxis metastasis in 17% of 96 patients at a median of 15 months after diagnosis, presenting as parenchymal dissemination, leptomeningeal metastasis, or subependymal spread (188). The dorsally exophytic "benign" brainstem tumor

characteristically fills the fourth ventricle, presenting with symptoms and signs of elevated intracranial pressure. In most cases, the tumor enhances briskly with gadolinium. The origin from the floor of the fourth ventricle may be suggested by MRI but is usually apparent only at the time of S. These tumors are almost always JPA; the prognosis has been quite favorable (184,189). Focal tumors of the pons are uncommon. One specific presentation includes isolated facial nerve palsy or similar, limited neurologic dysfunction associated with a small, enhancing intrapontine lesion. Such tumors are JPAs and enjoy a favorable prognosis (190). Tumors of the midbrain may involve the tegmentum or the tectal plate. Tegmental tumors usually are fibrillary astrocytomas. The tumors may involve the tegmentum focally or may infiltrate through much of the midbrain. Lesions may show uniform enhancement or little contrast enhancement. Presenting signs include extra ocular muscle palsy or long track involvement. Biopsy is preferred, especially for lesions contiguous with the pineal region. Tectal plate tumors usually are quite small and well demarcated, confined to the tectal plate. MRI shows the focal nature of tectal lesions, most often signified by brisk enhancement; biopsy generally confirms JPA. These tumors are typically indolent; observation alone is usually the treatment of choice (179,180). If the tumor is anatomically confined to the tectum and stable over an initial 3 to 6 month period of observation, biopsy may be deferred unless there is evidence of tumor progression necessitating therapy (180,190). When lesions are atypical, larger than 10 cc in volume, or when there is some question whether the lesion originated in the adjacent pineal region, biopsy may be needed at diagnosis. If it is confirmed as a LGA, observation is appropriate.

### **3.15 Therapy**

#### **3.15.1 Surgery**

The role of S in classic pontine gliomas is limited. Interest in biopsy in the current era is largely to define the biology of the more common DIBSG and to document diagnosis for the atypical brainstem tumors, both intrinsic and exophytic (191,192). For dorsally exophytic tumors, judicious incomplete resection will establish the diagnosis and reduce the obstructing mass in the fourth ventricular region. Although there is no documented advantage to aggressive S, it may be advantageous to remove the bulk of the lesion posteriorly, establishing CSF flow and reducing the bulk of tumor when it can be reasonably separated from the underlying margin of normal, functioning brainstem. Aggressive S as a primary intervention is often associated with unnecessary morbidity. Partial resection alone is associated with 50% to 70% EFS at 5 to 10 years (189). Small focal lesions intrinsic to the pons may be biopsied if safely approachable; one cannot insist on biopsy if the differential diagnosis is limited and the biopsy-associated morbidity is high. Lesions in the tegmentum should be biopsied, although the potential morbidity of stereotactic biopsy is recognized because of the proximity of the central veins. Occasional resection has been reported for midbrain tumors (192). Tumors of the lower medulla or cervicomedullary region are similar to low grade astrocytomas of the spinal cord. Biopsy and attempted GTR have been reported; results after S alone have been impressive but limited to a small number of neurosurgical centers. Histology usually is LGA; malignant gliomas have been reported (191).

#### **3.15.2 Radiation Therapy**

Children with diffusely infiltrating pontine gliomas often respond impressively to RT. Up to 70% show improvement in neurologic symptoms and signs over the course of irradiation;

objective reduction in tumor on MRI is apparent within 8 to 12 weeks of initiating RT. Unfortunately, signs of progressive disease are apparent systematically within 6 to 12 months (193). Clinical response has also been noted in tegmental midbrain lesions and tumors of the medulla, where RT is more likely to achieve long term disease control. For tectal plate or dorsally exophytic pontomedullary astrocytomas, RT is typically deferred until signs of disease progression are apparent on imaging (189). Once progression has been documented on serial imaging, there has been almost uniform disease control measured out to more than 5 years after local irradiation. Intrinsic focal pontine lesions often require RT at diagnosis to control attendant neurologic signs. With the availability of precision volume techniques, the risk benefit ratio may favor earlier RT in localized, low grade brainstem lesions (194).

### 3.15.3 Chemotherapy

Despite documented transient response, there is little evidence of efficacy for CT in brainstem tumors. An earlier prospective, randomized trial of CCNU, vincristine, and prednisone showed no benefit in these tumors despite purported efficacy in supratentorial high grade gliomas (195). Adjuvant studies with concurrent or sequential CT or, more recently, trials incorporating molecular targeting agents have failed to alter the PFS or OS data in this disease (196,197). Despite efficacy in adults with hemispheric malignant gliomas, temozolomide has shown no advantage in DIBSG in children (198). Preirradiation CT regimens have shown some responsiveness, but early disease progression during CT and a lack of objective benefit in postRT intervals to progression have largely dampened enthusiasm for this approach, although a limited recent French trial testing preRT BCNU, cisplatin, and high-dose methotrexate continues to generate interest (199). Cross-study analyses of serial POG brainstem glioma trials actually suggested a detrimental effect when cisplatin was added to high dose hyperfractionated RT (200). Trials of non cytotoxic radiosensitizers have also been conducted in phases I and II settings for DIBSG; more recent experience with motexafin gadolinium has revealed little benefit (201). Demonstration that large molecules can be perfused directly through the brainstem using an intraaxial catheter for convection enhanced delivery raises the possibility of direct infusion of biologic agents for brainstem gliomas, a concept now being addressed in a phase I trial at the U.S. National Institutes of Health (202). For focal, LGA, the use of CT before RT is an extrapolation from diencephalic low grade tumors, which may be rational in selected settings (203). For the majority of children, even those younger than 4 years, symptomatic or progressive dorsally exophytic or focal pontine lesions can be treated effectively with focal radiation techniques. It is difficult to anticipate any significant advantage in delaying definitive therapy with intervening CT.

### 3.16 Cerebellar astrocytomas

Cerebellar astrocytomas (CA) make up 10% to 15% of childhood brain tumors and 25% of posterior fossa neoplasms. These tumors are typically low grade, well circumscribed, and slowly growing with prominent cyst formation (204,205). The classic cystic CA presents as a unilocular cyst with a single prominent mural nodule. The cerebellum is one of the most common sites of origin for LGA in children, JPAs comprise 80% to 95% of cases and DFA account for 5% to 15% (206). DFAs tend to be less circumscribed, more infiltrative and expansile, with a less favorable prognosis relative to JPA; the diffuse tumors arise specified,

or as oligoastrocytomas. Malignant gliomas are quite uncommon in the childhood cerebellum. The median age at diagnosis is 5 to 6 years, with 20% of cases younger than 3 years; astrocytomas of this location are rarely found in infants (206,207). Presenting symptoms often are confined to those associated with elevated intracranial pressure, with less frequent altered cerebellar function; cranial nerve deficits are uncommon. The majority of tumors arise in the cerebellar hemispheres; approximately one third are primary vermis lesions. Most tumors are confined to the cerebellum; a minority extend to the cerebellopontine peduncle or the posterior aspect of the brainstem. The most characteristic appearance on computed tomography or MRI is a large, well circumscribed tumor with prominent cysts. The nodular or solid portion of the tumor characteristically enhances briskly; the cyst wall may or may not demonstrate contrast enhancement. The nodular and cystic components are considered part of the tumor; both components should be addressed at the time of S (206,207). Cerebellar JPAs have uncommonly been associated with multifocal CNS involvement, representing either neuraxis dissemination or concurrent multifocal presentation (208).

### **3.16.1 Therapy**

#### **3.16.1.1 Surgery**

S is the treatment of choice for CA and the amount of resection has been found to be the most important prognostic factor for outcome. For classic cystic CA, GTR has been reported in 70% to 90% of cases (209). PFS for these children is in excess of 90%. Even in the setting of documented residual, many tumors remain indolent. After imaging confirmed GTR, recurrence is uncommon, noted at 5% to 10% in major series (206,207,208). After incomplete resection, disease progression has been reported in 30% to 60% of cases at 5 years or more, long term survival remains above 65% (205,206,209). Infiltrative tumors and DFA are less likely to be amenable to GTR and are associated with a higher rate of disease progression or recurrence. Despite the indolent nature of these tumors, the median time to recurrence is about 2 years (205,206). Children who experience tumor recurrence amenable to resection may benefit from a second S.

#### **3.16.1.2 Radiation Therapy**

There is no established role for RT in the primary management of CA amenable to GTR and prognostic factors that may predict relapse after initial S alone be considered. Most series indicate greater risk of later disease progression in recurrent tumors, infiltrative tumors, astrocytomas that cannot be completely resected, and tumors with diffuse fibrillary histology or more aggressive histologic subtypes (206,207,208,209). Indications for RT include progression of incompletely resected tumors not amenable to second S and incomplete resection following recurrence. This is an uncommon situation for JPA, but is seen more frequently in tumors with diffuse fibrillary histology. Given recent data showing the efficacy of CT in delaying disease progression, CT may be the preferred initial adjuvant treatment for these more aggressive presentations in very young children (210). There are no data substantiating improvement in disease control with postoperative RT following a complete resection (207,209,211). Lesions with an infiltrative pattern involving the peduncle or brainstem may require early RT when symptomatic or progressive. The treatment of high-grade CA generally includes multiple modalities and postoperative RT is recognized

as the standard of care. CSF dissemination is a recognized pattern of failure; CSI is typically considered only when overt CNS metastasis is documented (206,208,211).

### 3.16.1.3 Chemotherapy

Because most LGA located in the cerebellum are amenable to S and do not require adjuvant therapy, it is relatively rare to use CT for this specific tumor site. Multiple chemotherapeutic agents have been shown to delay progression (210,212). The most commonly administered regimen is the combination of carboplatin and vincristine.

## 4. References

- [1] Louis DN, Ohgaki H, Wiestler OD, et al. WHO Classification of Tumours of the Central Nervous System. 4th ed. World Health Organization; 2007.
- [2] Lewis RA, Gerson LP, Axelson KA, et al. von Recklinghausen neurofibromatosis. II. Incidence of optic gliomata. *Ophthalmology*. 1984;91:929-935.
- [3] Li FP, Fraumeni JF Jr. Soft-tissue sarcomas, breast cancer, and other neoplasms. A familial syndrome? *Ann Intern Med*. 1969;71:747-752.
- [4] Relling MV, Rubnitz JE, Rivera GK, et al. High incidence of secondary brain tumours after radiotherapy and antimetabolites. *Lancet*. 1999;354:34-39.
- [5] Perry A. Pathology of low-grade gliomas: an update of emerging concepts. *Neuro-Oncol*. 2003;5:168-178.
- [6] Wisoff JH, Sanford RA, Heier LA, et al. Primary neurosurgery for pediatric low-grade astrocytomas: a prospective multi-institutional study. *Neurosurgery*. 2009.
- [7] Shaw EG, Wisoff JH. Prospective clinical trials of intracranial low-grade glioma in adults and children. *Neuro-Oncol*. 2003;5:153-160.
- [8] Pollack IF, Claassen D, al-Shboul Q, et al. Low-grade gliomas of the cerebral hemispheres in children: an analysis of 71 cases. *J Neurosurg*. 1995;82:536-547.
- [9] Merchant TE, Kun LE, Wu S, et al. Phase II trial of conformal radiation therapy for pediatric low-grade glioma. *J Clin Oncol*. 2009;27:3598-3604.
- [10] Merchant TE, Conklin HM, Wu S, et al. Late effects of conformal radiation therapy for pediatric patients with low-grade glioma: prospective evaluation of cognitive, endocrine, and hearing deficits. *J Clin Oncol*. 2009;27:3691-3697.
- [11] Marcus KJ, Goumnerova L, Billett AL, et al. Stereotactic radiotherapy for localized low-grade gliomas in children: final results of a prospective trial. *Int J Radiat Oncol Biol Phys*. 2005;61:374-379.
- [12] Packer RJ, Ater J, Allen J, et al. Carboplatin and vincristine chemotherapy for children with newly diagnosed progressive low-grade gliomas. *J Neurosurg*. 1997;86:747-754.
- [13] Chemotherapy for progressive low grade astrocytoma in children less than 10 years old: a Phase III Intergroup COG Study. Internet; 2009.
- [14] Packer RJ. Chemotherapy: low-grade gliomas of the hypothalamus and thalamus. *Pediatr Neurosurg*. 2000;32:259-263.
- [15] Khaw SL, Coleman LT, Downie PA, et al. Temozolomide in pediatric low-grade glioma. *Pediatr Blood Cancer*. 2007;49:808-811.
- [16] Packer RJ, Jakacki R, Horn M, et al. Objective response of multiply recurrent low-grade gliomas to bevacizumab and irinotecan. *Pediatr Blood Cancer*. 2009;52:791-795.
- [17] Janss AJ, Grundy R, Cnaan A, et al. Optic pathway and hypothalamic/chiasmatic gliomas in children younger than age 5 years with a 6 year follow-up. *Cancer*. 1995;75:1051-1059.

- [18] Pollack IF, Hurtt M, Pang D, et al. Dissemination of low grade intracranial astrocytomas in children. *Cancer*. 1994;73:2869-2878.
- [19] Tao ML, Barnes PD, Billett AL, et al. Childhood optic chiasm gliomas: radiographic response following radiotherapy and long-term clinical outcome. *Int J Radiat Oncol Biol Phys* . 1997;39:579-587.
- [20] Schmandt SM, Packer RJ, Vezina LG, et al. Spontaneous regression of low-grade astrocytomas in childhood. *Pediatr Neurosurg*.2000;32:132-136.
- [21] Alvord EC Jr, Lofton S. Gliomas of the optic nerve or chiasm. Outcome by patients' age, tumor site, and treatment. *J Neurosurg* .1988;68:85-98.
- [22] Hoffman HJ, Humphreys RP, Drake JM, et al. Optic pathway/hypothalamic gliomas: a dilemma in management. *Pediatr Neurosurg*. 1993;19:186-195.
- [23] Medlock MD, Scott RM. Optic chiasm astrocytomas of childhood. Surgical management. *Pediatr Neurosurg*. 1997;27:129-136.
- [24] Listernick R, Louis DN, Packer RJ, et al. Optic pathway gliomas in children with neurofibromatosis 1: consensus statement from the NF1 Optic Pathway Glioma Task Force. *Ann Neurol*. 1997;41:143-149.
- [25] Bataini JP, Delanian S, Ponvert D. Chiasmal gliomas: results of irradiation management in 57 patients and review of literature. *Int J Radiat Oncol Biol Phys*. 1991;21: 615-623.
- [26] Jenkin D, Angyalfi S, Becker L, et al. Optic glioma in children: surveillance, resection, or irradiation? *Int J Radiat Oncol Biol Phys*. 1993;25:215-225.
- [27] Bataini JP, Delanian S, Ponvert D. Chiasmal gliomas: results of irradiation management in 57 patients and review of literature. *IntJ Radiat Oncol Biol Phys*. 1991;21: 615-623.
- [28] Packer RJ. Chemotherapy: low-grade gliomas of the hypothalamus and thalamus. *Pediatr Neurosurg*. 2000;32:259-263.
- [29] Rudoltz MS, Regine WF, Langston JW, et al. Multiple causes of cerebrovascular events in children with tumors of the parasellar region. *J Neurooncol* . 1998;37:251-261.
- [30] Sharif S, Ferner R, Birch JM, et al. Second primary tumors in neurofibromatosis patients treated for optic glioma: substantial risks after radiotherapy. *J Clin Oncol*. 2006;24:2570-2575.
- [31] Krieger MD, Gonzalez-Gomez I, Levy ML, et al. Recurrence patterns and anaplastic change in a long-term study of pilocytic astrocytomas. *Pediatr Neurosurg*. 1997;27:1-11.
- [32] Dirks PB, Jay V, Becker LE, et al. Development of anaplastic changes in low-grade astrocytomas of childhood. *Neurosurgery*. 1994;34:68-78.
- [33] Packer RJ, Sutton LN, Bilaniuk LT, et al. Treatment of chiasmatic/hypothalamic gliomas of childhood with chemotherapy: an update. *Ann Neurol*. 1988;23:79-85.
- [34] Prados MD, Edwards MS, Rabbitt J, et al. Treatment of pediatric low-grade gliomas with a nitrosourea-based multiagent chemotherapy regimen. *J Neuro-Oncol*. 1997;32:235-241.
- [35] Friedman HS, Krischer JP, Burger P, et al. Treatment of children with progressive or recurrent brain tumors with carboplatin or iproplatin: a Pediatric Oncology Group randomized phase II study. *J Clin Oncol* 1992;10:249-256.
- [36] Razack N, Baumgartner J, Bruner J. Pediatric oligodendrogliomas. *Pediatr Neurosurg*. 1998;28:121-129.
- [37] Ino Y, Betensky RA, Zlatescu MC, et al. Molecular subtypes of anaplastic oligodendroglioma: implications for patient management at diagnosis. *Clin Cancer Res*. 2001;7:839-845.

- [38] Shaw EG, Scheithauer BW, O'Fallon JR, et al. Oligodendrogliomas: the Mayo Clinic experience. *J Neurosurg.* 1992;76:428-434.
- [39] Shaw EG, Scheithauer BW, O'Fallon JR. Management of supratentorial low-grade gliomas. *Oncology.* 1993;7:97-104,107.
- [40] Gajjar A, Heideman RL, Kovnar EH, et al. Response of pediatric low grade gliomas to chemotherapy. *Pediatr Neurosurg.*1993;19:113-118.
- [41] Leenstra JL, Rodriguez FJ, Frechette CM, et al. Central neurocytoma: management recommendations based on a 35-year experience. *Int J Radiat Oncol Biol Phys.* 2007;67:1145-1154
- [42] Fujisawa H, Marukawa K, Hasegawa M, et al. Genetic differences between neurocytoma and dysembryoplastic neuroepithelial tumor and oligodendroglial tumors. *J Neurosurg.*2002;97:1350-1355.
- [43] Yasargil MG, von Ammon K, von Deimling A, et al. Central neurocytoma: histopathological variants and therapeutic approaches. *J Neurosurg.* 1992;76:32-37.
- [44] Kim DG, Paek SH, Kim IH, et al. Central neurocytoma: the role of radiation therapy and long term outcome. *Cancer.*1997;79:1995-2002.
- [45] Daumas-Duport C, Scheithauer BW, Chodkiewicz JP, et al. Dysembryoplastic neuroepithelial tumor: a surgically curable tumor of young patients with intractable partial seizures. Report of thirty-nine cases. *Neurosurgery.* 1988;23:545-556.
- [46] Daumas-Duport C. Dysembryoplastic neuroepithelial tumours. *Brain Pathology.* 1993;3:283-295
- [47] Broniscer A, Gajjar A. Supratentorial high-grade astrocytoma and diffuse brainstem glioma: two challenges for the pediatric oncologist. *Oncologist.* 2004;9:197-206.
- [48] Louis DN, Holland EC, Cairncross JG. Glioma classification: a molecular reappraisal. *Am J Pathol.* 2001;159:779-786.
- [49] Heideman RL, Kuttesch J Jr, Gajjar AJ, et al. Supratentorial malignant gliomas in childhood: a single institution perspective. *Cancer.* 1997;80:497-504.
- [50] Nagashima G, Suzuki R, Hokaku H, et al. Graphic analysis of microscopic tumor cell infiltration, proliferative potential, and vascular endothelial growth factor expression in an autopsy brain with glioblastoma. *Surg Neurol.* 1999;51:292-299.
- [51] Pirotte BJ, Levivier M, Goldman S, et al. Positron emission tomography-guided volumetric resection of supratentorial high-grade gliomas: a survival analysis in 66 consecutive patients. *Neurosurgery.* 2009;64:471-481.
- [52] Wisoff JH, Boyett JM, Berger MS, et al. Current neurosurgical management and the impact of the extent of resection in the treatment of malignant gliomas of childhood: a report of the Children's Cancer Group trial no. CCG-945. *J Neurosurg.*1998;89:52-59.
- [53] Chan JL, Lee SW, Fraass BA, et al. Survival and failure patterns of high-grade gliomas after three-dimensional conformal radiotherapy. *J Clin Oncol.* 2002;20:1635-1642.
- [54] Wagner S, Benesch M, Berthold F, et al. Secondary dissemination in children with high-grade malignant gliomas and diffuse intrinsic pontine gliomas. *Br J Cancer.* 2006;95:991-997.
- [55] Narayana A, Yamada J, Berry S, et al. Intensity-modulated radiotherapy in high-grade gliomas: clinical and dosimetric results. *Int J Radiat Oncol Biol Phys.* 2006;64:892-897.
- [56] Park I, Tamai G, Lee MC, et al. Patterns of recurrence analysis in newly diagnosed glioblastoma multiforme after three-dimensional conformal radiation therapy with

- respect to preradiation therapy magnetic resonance spectroscopic findings. *Int J Radiat Oncol Biol Phys.* 2007;69:381–389.
- [57] Lee IH, Piert M, Gomez-Hassan D, et al. Association of 11C-methionine PET uptake with site of failure after concurrent temozolomide and radiation for primary glioblastoma multiforme. *Int J Radiat Oncol Biol Phys.* 2009;73: 479–485.
- [58] Pigott TJ, Punt JA, Lowe JS, et al. The clinical, radiological and histopathological features of cerebral primitive neuroectodermaltumours. *Br J Neurosurg.* 1990;4:287–297.
- [59] Albright AL, Wisoff JH, Zeltzer P, et al. Prognostic factors in chil-dren with supratentorial (non pineal) primitive neuroectodermaltumours. A neurosurgical perspective from the Children’s CancerGroup. *Pediatr Neurosurg.* 1995;22:1–7.
- [60] Rubinstein LJ. Embryonal central neuroepithelial tumors and their differentiating potential. A cytogenetic view of a complex neuro-oncological problem. *J Neurosurg.* 1985;62: 795–805.
- [61] Jakacki RI, Zeltzer PM, Boyett JM, et al. Survival and prognosticfactors following radiation and/or chemotherapy for primitive neuroectodermal tumors of the pineal region in infants and children: a report of the Children’s Cancer Group. *J Clin Oncol.*1995;13:1377–1383.
- [62] Pizer BL, Weston CL, Robinson KJ, et al. Analysis of patients with supratentorial primitive neuro-ectodermal tumours entered intothe SIOP/UKCCSG PNET 3 study. *Eur J Cancer.* 2006;42:1120–1128.
- [63] Gaffney CC, Sloane JP, Bradley NJ, et al. Primitive neuroectodermal tumours of the cerebrum. Pathology and treatment. *J Neurooncol.* 1985;3:23–33.
- [64] Chintagumpala M, Hassall T, Palmer S, et al. A pilot study of risk-adapted radiotherapy and chemotherapy in patients with supratentorial PNET. *Neuro-Oncol.* 2009;11:33–40.
- [65] Burger PC, Scheithauer BW, Vogel FS. *Surgical Pathology of theNervous System and its Coverings.* 4th ed. New York: Churchill Livingstone; 2002.
- [66] McLendon RE, Rosenblum MC, Bigner DD. *Russell & Rubinstein’s Pathology of Tumors of the Nervous System (Contemporary Neurology).* 7th ed. London: A Hodder Arnold; 2006.
- [67] Glenn OA, Barkovich AJ. Intracranial germ cell tumors: a compre-hensive review of proposed embryologic derivation. *Pediatr Neurosurg.* 1996;24:242–251.
- [68] Sawamura Y, Ikeda J, Shirato H, et al. Germ cell tumours of thecentral nervous system: treatment consideration based on 111cases and their long-term clinical outcomes. *Eur J Cancer.*1998;34:104–110.
- [69] Cunliffe CH, Fischer I, Karajannis M, et al. Synchronous mixedgerm cell tumor of the pineal gland and suprasellar region with apredominant angiomatous component: a diagnostic challenge. *J Neurooncol.* 2009;93:269–274.
- [70] Schild SE, Scheithauer BW, Schomberg PJ, et al. Pineal parenchymal tumors. Clinical, pathologic, and therapeutic aspects. *Cancer.*1993;72:870–880.
- [71] Erlich SS, Apuzzo ML. The pineal gland: anatomy, physiology, and clinical significance. *J Neurosurg.* 1985;63:321–341.
- [72] Maghnie M, Cosi G, Genovese E, et al. Central diabetes insipidusin children and young adults. *N Engl J Med.* 2000; 343:998–1007.
- [73] MacDonald SM, Desai N, Heller G, et al. MRI changes in the “normal” pineal gland following chemotherapy for suprasellar germ celltumors. *Pediatr Hematol Oncol.* 2008;25:5–15.



- [74] Balmaceda C, Heller G, Rosenblum M, et al. Chemotherapy without irradiation a novel approach for newly diagnosed CNS germcell tumors: results of an international cooperative trial. The First International Central Nervous System Germ Cell Tumor Study. *J Clin Oncol.* 1996;14:2908–2915.
- [75] Finlay J, da Silva NS, Lavey R, et al. The management of patients with primary central nervous system (CNS) germinoma: current controversies requiring resolution. *Pediatr Blood Cancer.* 2008;51:313–316.
- [76] Matsutani M, Sano K, Takakura K, et al. Primary intracranial germcell tumors: a clinical analysis of 153 histologically verified cases. *J Neurosurg.* 1997;86:446–455.
- [77] Dearnaley DP, A'Hern RP, Whittaker S, et al. Pineal and CNS germcell tumors: Royal Marsden Hospital experience 1962–1987. *Int J Radiat Oncol Biol Phys.* 1990;18:773–781.
- [78] Kretschmar C, Kleinberg L, Greenberg M, et al. Preradiation chemotherapy with response-based radiation therapy in children with central nervous system germ cell tumors: a report from the Children's Oncology Group. *Pediatr Blood Cancer.* 2007;48:285–291.
- [79] Calaminus G, Bamberg M, Baranzelli MC, et al. Intracranial germcell tumors: a comprehensive update of the European data. *Neuropediatrics.* 1994;25:26–32.
- [80] Regis J, Bouillot P, Rouby-Volot F, et al. Pineal region tumors and the role of stereotactic biopsy: review of the mortality, morbidity, and diagnostic rates in 370 cases. *Neurosurgery.* 1996;39:907–912.
- [81] Calaminus G, Bamberg M, Harms D, et al. AFP/beta-HCG secreting CNS germ cell tumors: long-term outcome with respect to initial symptoms and primary tumor resection. Results of the cooperative trial MAKEI 89. *Neuropediatrics.* 2005;36:71–77.
- [82] Allen JC, Kim JH, Packer RJ. Neoadjuvant chemotherapy for newly diagnosed germ-cell tumors of the central nervous system. *J Neurosurg.* 1987;67:65–70.
- [83] Robertson PL, DaRosso RC, Allen JC. Improved prognosis of in-tracranial non-germinoma germ cell tumors with multimodality therapy. *J Neurooncol.* 1997;32:71–80.
- [84] Shibamoto Y, Takahashi M, Sasai K. Prognosis of intracranial germinoma with syncytiotrophoblastic giant cells treated by radiation therapy. *Int J Radiat Oncol Biol Phys.* 1997;37:505–510.
- [85] Haas-Kogan DA, Missett BT, Wara WM, et al. Radiation therapy for intracranial germ cell tumors. *Int J Radiat Oncol Biol Phys.* 2003;56:511–518.
- [86] Paulino AC. Induction chemotherapy and involved-field radiotherapy for intracranial germinoma. *J Clin Oncol.* 2002;20:2911–2912.
- [87] Sawamura Y, Shirato H, Ikeda J, et al. Induction chemotherapy followed by reduced volume radiation therapy for newly diagnosed central nervous system germinoma. *J Neurosurg.* 1998;88:66–72.
- [88] Lafay-Cousin L, Millar BA, Mabbott D, et al. Limited field radiation for bifocal germinoma. *Int J Radiat Oncol Biol Phys.* 2006;65:486–492.
- [89] Kondziolka D, Hadjipanayis CG, Flickinger JC, et al. The role of radiosurgery for the treatment of pineal parenchymal tumors. *Neurosurgery.* 2002;51:880–889.
- [90] Kitamura K, Shirato H, Sawamura Y, et al. Preirradiation evaluation and technical assessment of involved-field radiotherapy using computed tomographic (CT) simulation and neoadjuvant chemotherapy for intracranial germinoma. *Int J Radiat Oncol Biol Phys.* 1999;43:783–788.

- [91] Paulino AC, Wen BC, Mohideen MN. Controversies in the management of intracranial germinomas. *Oncology*. 1999;13:513-521.
- [92] Merchant TE, Davis BJ, Sheldon JM, et al. Radiation therapy for relapsed CNS germinoma after primary chemotherapy. *J Clin Oncol*. 1998;16:204-209.
- [93] A phase II study to assess the ability of neoadjuvant chemotherapy and second look surgery to eliminate all measurable disease prior to radiotherapy for NGGCT. Internet; 2009.
- [94] Modak S, Gardner S, Dunkel IJ, et al. Thiotepa-based high-dose chemotherapy with autologous stem-cell rescue in patients with recurrent or progressive CNS germ cell tumors. *J Clin Oncol*. 2004;22:1934-1943.
- [95] Burger PC, Grahmann FC, Bliestle A, et al. Differentiation in the medulloblastoma. A histological and immunohistochemical study. *Acta Neuropathol*. 1987;73:115-123.
- [96] Rubin JB, Rowitch DH. Medulloblastoma: a problem of developmental biology. *Cancer Cell*. 2002;2:7-8.
- [97] Gilbertson RJ. Medulloblastoma: signalling a change in treatment. *Lancet Oncol*. 2004;5:209-218.
- [98] de Bont JM, Packer RJ, Michiels EM, et al. Biological background of pediatric medulloblastoma and ependymoma: a review from a translational research perspective. *Neuro Oncol*. 2008;10:1040-1060.
- [99] Berman DM, Karhadkar SS, Hallahan AR, et al. Medulloblastoma growth inhibition by hedgehog pathway blockade. *Science*. 2002;297:1559-1561.
- [100] Brown HG, Kepner JL, Perlman EJ, et al. "Large cell-anaplastic" medulloblastomas: a Pediatric Oncology Group study. *J Neuropathol Exp Neurol*. 2000;59:857-865.
- [101] Pomeroy SL, Tamayo P, Gaasenbeek M, et al. Prediction of central nervous system embryonal tumour outcome based on gene expression. *Nature*. 2002;415:436-442.
- [102] Kortmann RD, Kuhl J, Timmermann B, et al. Postoperative neoadjuvant chemotherapy before radiotherapy as compared to immediate radiotherapy followed by maintenance chemotherapy in the treatment of medulloblastoma in childhood: results of the German prospective randomized trial HIT'91. *Int J Radiat Oncol Biol Phys*. 2000;46:269-279.
- [103] Chang CH, Housepian EM, Herbert C Jr. An operative staging system and a megavoltage radiotherapeutic technic for cerebellar medulloblastomas. *Radiology*. 1969;93:1351-1359.
- [104] Zeltzer PM, Boyett JM, Finlay JL, et al. Metastasis stage, adjuvant treatment and residual tumor are prognostic factors for medulloblastoma in children: conclusions from the Children's Cancer Group 921 randomized phase III study. *J Clin Oncol*. 1999;17:832-845.
- [105] Bailey CC, Gnekow A, Wellek S, et al. Prospective randomised trial of chemotherapy given before radiotherapy in childhood medulloblastoma. International Society of Paediatric Oncology (SIOP) and the (German) Society of Paediatric Oncology (GPO): SIOP II. *Med Pediatr Oncol*. 1995;25:166-178.
- [106] Packer RJ, Rood BR, MacDonald TJ. Medulloblastoma: present concepts of stratification into risk groups. *Pediatr Neurosurg*. 2003;39:60-67.
- [107] Cushing H. Experiences with the cerebellar medulloblastomas: a critical review. *Acta Pathol Microbiol Scand*. 1930; 1:1-86.
- [108] Douglas JG, Barker JL, Ellenbogen RG, et al. Concurrent chemotherapy and reduced dose cranial spinal irradiation followed by conformal posterior fossa tumor bed boost for average-risk medulloblastoma: efficacy and patterns of failure. *Int J Radiat Oncol Biol Phys*. 2004;58:1161-1164.

- [109] Miller NG, Reddick WE, Kocak M, et al. Cerebellocerebral diaschisis is the likely mechanism of postsurgical posterior fossa syndrome in pediatric patients with midline cerebellar tumors. *Am J Neuroradiol.* 2010;31:288-294.
- [110] Miller NG, Reddick WE, Kocak M, et al. Cerebellocerebral diaschisis is the likely mechanism of postsurgical posterior fossa syndrome in pediatric patients with midline cerebellar tumors. *Am J Neuroradiol.* 2010;31:288-294.
- [111] Oyharcabal-Bourden V, Kalifa C, Gentet JC, et al. Standard risk medulloblastoma treated by adjuvant chemotherapy followed by reduced dose craniospinal radiation therapy: a French Society of Pediatric Oncology Study. *J Clin Oncol.* 2005;23:4726-4734.
- [112] Grill J, Lellouch-Tubiana A, Elouahdani S, et al. Preoperative chemotherapy in children with high-risk medulloblastomas: a feasibility study. *J Neurosurg.* 2005;103:312-318.
- [113] Cutler EC, Sosman MC, Vaughan WW. Place of radiation in treatment of cerebellar medulloblastoma: report of 20 cases. *Am J Roentgenol Radium Ther Nucl Med.* 1936;35:429-453.
- [114] Bloom HJG, Glees J, Bell J. The treatment and prognosis of medulloblastoma in children. *AJR Am J Roentgenol.* 1969; 105:43-62.
- [115] Carrie C, Grill J, Figarella-Branger D, et al. Online quality control, hyperfractionated radiotherapy alone and reduced boost volume for standard risk medulloblastoma: long-term results of MSFOP 98. *J Clin Oncol.* 2009;27: 1879-1883.
- [116] Merchant TE, Kun LE, Krasin MJ, et al. Multi institution prospective trial of reduced dose craniospinal irradiation (23.4 Gy) followed by conformal posterior fossa (36 Gy) and primary site irradiation (55.8 Gy) and dose-intensive chemotherapy for average-risk medulloblastoma. *Int J Radiat Oncol Biol Phys.* 2008;70:782-787.
- [117] Packer RJ, Gajjar A, Vezina G, et al. Phase III study of cranio spinal radiation therapy followed by adjuvant chemotherapy for newly diagnosed average-risk medulloblastoma. *J Clin Oncol.* 2006;24:4202-4208.
- [118] Taylor RE, Bailey CC, Robinson KJ, et al. Impact of radiotherapy parameters on outcome in the International Society of Paediatric Oncology-United Kingdom Children's Cancer Study Group PNET-3 study of preradiotherapy chemotherapy for M0-M1 medulloblastoma. *Int J Radiat Oncol Biol Phys.* 2004;58:1184-1193.
- [119] Mulhern RK, Merchant TE, Gajjar A, et al. Late neurocognitive sequelae in survivors of brain tumours in childhood. *Lancet Oncol.* 2004;5:399-408.
- [120] Merchant TE, Kiehna EN, Li C, et al. Modeling radiation dosimetry to predict cognitive outcomes in pediatric patients with CNS embryonal tumors including medulloblastoma. *Int J Radiat Oncol Biol Phys.* 2006;65:210-221.
- [121] Allen J, Donahue B, Mehta M, et al. A phase II study of preradiotherapy chemotherapy followed by hyperfractionated radiotherapy for newly diagnosed high-risk medulloblastoma-primitive neuroectodermal tumor: a report from the Children's Oncology Group (CCG 9931). *Int J Radiat Oncol Biol Phys.* 2009;74:1006-1011.
- [122] Heideman RL, Kovnar EH, Kellie SJ, et al. Preirradiation chemotherapy with carboplatin and etoposide in newly diagnosed embryonal pediatric CNS tumors. *J Clin Oncol.* 1995;13:2247-2254.
- [123] Stewart CF, Iacono LC, Chintagumpala M, et al. Results of a phase II upfront window of pharmacokinetically guided topotecan in high-risk medulloblastoma and supratentorial primitive neuroectodermal tumor. *J Clin Oncol.* 2004;22: 3357-3365.

- [124] Packer RJ, Goldwein J, Nicholson HS, et al. Treatment of children with medulloblastomas with reduced-dose craniospinal radiation therapy and adjuvant chemotherapy: a Children's Cancer Group Study. *J Clin Oncol.* 1999;17:2127-2136.
- [125] Fouladi M, Chintagumpala M, Ashley D, et al. Amifostine protects against cisplatin-induced ototoxicity in children with average-risk medulloblastoma. *J Clin Oncol.* 2008; 26: 3749-3755.
- [126] Taylor RE, Bailey CC, Robinson KJ, et al. Outcome for patients with metastatic (M2-3) medulloblastoma treated with SIOP-UKCCSGPNET-3 chemotherapy. *Eur J Cancer.* 2005; 41:727-734.
- [127] von HK, Hinkes B, Gerber NU, et al. Long-term outcome and clinical prognostic factors in children with medulloblastoma treated in the prospective randomised multicentre trial HIT'91. *Eur J Cancer.* 2009;45:1209-1217.
- [128] Gandola L, Massimino M, Cefalo G, et al. Hyperfractionated accelerated radiotherapy in the Milan strategy for metastatic medulloblastoma. *J Clin Oncol.* 2009;27:566-571.
- [129] Shih CS, Hale GA, Gronewold L, et al. High-dose chemotherapy with autologous stem cell rescue for children with recurrent malignant brain tumors. *Cancer.* 2008; 112: 1345-1353.
- [130] Massimino M, Gandola L, Spreafico F, et al. No salvage using high-dose chemotherapy plus-minus reirradiation for relapsing previously irradiated medulloblastoma. *Int J Radiat Oncol Biol Phys.* 2009;73:1358-1363.
- [131] Gururangan S, Krauser J, Watral MA, et al. Efficacy of high-dose chemotherapy or standard salvage therapy in patients with recurrent medulloblastoma. *Neuro Oncol.* 2008;10:745-751.aaaaaaa
- [132] Saran F, Baumert BG, Creak AL, et al. Hypofractionated stereotactic radiotherapy in the management of recurrent or residual medulloblastoma-PNET. *Pediatr Blood Cancer.* 2008;50:554-560.
- [133] Kramer K, Humm JL, Souweidane MM, et al. Phase I study of targeted radioimmunotherapy for leptomeningeal cancers using intra-Ommaya 131-I-3F8. *J Clin Oncol.* 2007;25:5465-5470.
- [134] Childhood Brain Tumor Consortium. Supplement Report: Primary Brain Tumors in the United States, 2004. Hinsdale, IL: Central Brain Tumor Registry of the United States, 2008.
- [135] Larouche V, Huang A, Bartels U, et al. Tumors of the central nervous system in the first year of life. *Pediatr Blood Cancer.* 2007;49:1074-1082.
- [136] Meyers SP, Khademian ZP, Biegel JA, et al. Primary intracranial atypical teratoid-rhabdoid tumors of infancy and childhood: MRI features and patient outcomes. *AJNR Am J Neuroradiol.* 2006;27:962-971.
- [137] Packer RJ, Biegel JA, Blaney S, et al. Atypical teratoid-rhabdoid tumor of the central nervous system: report on workshop. *J Pediatr Hematol Oncol.* 2002;24:337-342.
- [138] Cohen BH, Packer RJ, Siegel KR, et al. Brain tumors in children under 2 years: treatment, survival and long-term prognosis. *Pediatr Neurosurg.* 1993;19:171-179.
- [139] Tekautz TM, Fuller CE, Blaney S, et al. Atypical teratoid- rhabdoid tumors (ATRT): improved survival in children 3 years of age and older with radiation therapy and high-dose alkylator-based chemotherapy. *J Clin Oncol.* 2005;23: 1491-1499.
- [140] Walter AW, Mulhern RK, Gajjar A, et al. Survival and neurodevelopmental outcome of young children with medulloblastoma at St. Jude Children's Research Hospital. *J Clin Oncol.* 1999;17:3720-3728.

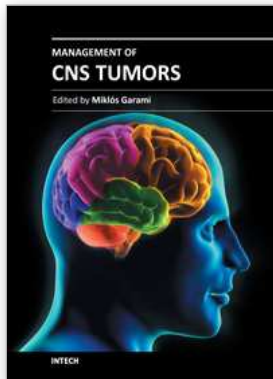
- [141] Sanders RP, Kocak M, Burger PC, et al. High-grade astrocytoma in very young children. *Pediatr Blood Cancer*. 2007; 49:888–893.
- [142] Fouladi M, Gururangan S, Moghrabi A, et al. Carboplatin-based primary chemotherapy for infants and young children with CNS tumors. *Cancer*. 2009;115:3243–3253.
- [143] Geyer JR, Sposto R, Jennings M, et al. Multiagent chemotherapy and deferred radiotherapy in infants with malignant brain tumors: a report from the Children's Cancer Group. *J Clin Oncol*. 2005;23:7621–7231.
- [144] Grill J, Sainte-Rose C, Jouvet A, et al. Treatment of medulloblastoma with postoperative chemotherapy alone: an SFOP prospective trial in young children. *Lancet Oncol*. 2005;6:573–580.
- [145] Rutkowski S, Bode U, Deinlein F, et al. Treatment of early childhood medulloblastoma by postoperative chemotherapy alone. *N Engl J Med*. 2005;352:978–986.
- [146] Ridola V, Grill J, Doz F, et al. High-dose chemotherapy with autologous stem cell rescue followed by posterior fossa irradiation for local medulloblastoma recurrence or progression after conventional chemotherapy. *Cancer*. 2007;110: 156–163.
- [147] Squire SE, Chan MD, Marcus KJ. Atypical teratoid-rhabdoid tumor: the controversy behind radiation therapy. *J Neurooncol*. 2007;81:97–111.
- [148] Biegel JA, Kalpana G, Knudsen ES, et al. The role of INI1 and the SWI/SNF complex in the development of rhabdoid tumors: meet-ing summary from the workshop on childhood atypical teratoid-rhabdoid tumors. *Cancer Res*. 2002; 62:323–328.
- [149] Chi SN, Zimmerman MA, Yao X, et al. Intensive multimodality treatment for children with newly diagnosed CNS atypical teratoid rhabdoid tumor. *J Clin Oncol*. 2009;27: 385–389.
- [150] Krishnan S, Brown PD, Scheithauer BW, et al. Choroid plexus papillomas: a single institutional experience. *J Neurooncol*. 2004;68:49–55.
- [151] Ater JL, van Eys J, Woo SY, et al. MOPP chemotherapy without ir-radiation as primary postsurgical therapy for brain tumors in infants and young children. *J Neurooncol*. 1997;32:243–252.
- [152] Nazar GB, Hoffman HJ, Becker LE, et al. Infratentorial ependymomas in childhood: prognostic factors and treatment. *J Neurosurg*. 1990;72:408–417.
- [153] Veelen-Vincent ML, Pierre-Kahn A, Kalifa C, et al. Ependymoma in childhood: prognostic factors, extent of surgery, and adjuvant therapy. *J Neurosurg*. 2002;97:827–835.
- [154] Yuh EL, Barkovich AJ, Gupta N. Imaging of ependymomas: MRI and CT. *Childs Nerv Syst*. 2009;25:1203–1213.
- [155] Taylor MD, Poppleton H, Fuller C, et al. Radial glia cells are candidate stem cells of ependymoma. *Cancer Cell*. 2005;8: 323–335.
- [156] Ross GW, Rubinstein LJ. Lack of histopathological correlation of malignant ependymomas with postoperative survival. *J Neurosurg*. 1989;70:31–36.
- [157] Merchant TE, Jenkins JJ, Burger PC, et al. Influence of tumor grade on time to progression after irradiation for localized ependymoma in children. *Int J Radiat Oncol Biol Phys*. 2002;53:52–57.
- [158] Merchant TE, Li C, Xiong X, et al. Conformal radiotherapy after surgery for paediatric ependymoma: a prospective study. *Lancet Oncol*. 2009;10:258–266.
- [159] Tihan T, Zhou T, Holmes E, et al. The prognostic value of histological grading of posterior fossa ependymomas in children: a Children's Oncology Group study and a review of prognostic factors. *Mod Pathol*. 2008;21:165–177.

- [160] Palm T, Figarella-Branger D, Chapon F, et al. Expression profiling of ependymomas unravels localization and tumor grade specific tumorigenesis. *Cancer*. 2009;115:3955-3968.
- [161] Gaspar N, Grill J, Geoerger B, et al. p53 Pathway dysfunction in primary childhood ependymomas. *Pediatr Blood Cancer*. 2006;46:604-613.
- [162] Pollack IF, Gerszten PC, Martinez AJ, et al. Intracranial ependymomas of childhood: long-term outcome and prognostic factors. *Neurosurgery* 1995;37:655-666.
- [163] Rousseau P, Habrand JL, Sarrazin D, et al. Treatment of intracranial ependymomas of children: review of a 15-year experience. *Int J Radiat Oncol Biol Phys*. 1994;28:381-386.
- [164] Shim KW, Kim DS, Choi JU. The history of ependymoma management. *Childs Nerv Syst*. 2009;25:1167-1183.
- [165] Zacharoulis S, Ji L, Pollack IF, et al. Metastatic ependymoma: a multiinstitutional retrospective analysis of prognostic factors. *Pediatr Blood Cancer*. 2008;50:231-235.
- [166] Hukin J, Epstein F, Lefton D, et al. Treatment of intracranial ependymoma by surgery alone. *Pediatr Neurosurg*. 1998; 29:40-45.
- [167] Duffner PK, Krischer JP, Sanford RA, et al. Prognostic factors in infants and very young children with intracranial ependymomas. *Pediatr Neurosurg*. 1998;28:215-222.
- [168] Grundy RG, Wilne SA, Weston CL, et al. Primary postoperative chemotherapy without radiotherapy for intracranial ependymoma in children: the UKCCSG/SIOP prospective study. *Lancet Oncol*. 2007;8:696-705.
- [169] Mansour DB, Perry A, Rajaram V, et al. Postoperative radiation therapy for grade II and III intracranial ependymoma. *Int J Radiat Oncol Biol Phys*. 2005;61:387-391.
- [170] Merchant TE, Kiehna EN, Li C, et al. Radiation dosimetry predicts IQ after conformal radiation therapy in pediatric patients with localized ependymoma. *Int J Radiat Oncol Biol Phys*. 2005;63:1546-1554.
- [171] Merchant TE, Boop FA, Kun LE, et al. A retrospective study of surgery and reirradiation for recurrent ependymoma. *Int J Radiat Oncol Biol Phys*. 2008;71:87-97.
- [172] Robertson PL, Zeltzer PM, Boyett JM, et al. Survival and prognostic factors following radiation therapy and chemotherapy for ependymomas in children: a report of the Children's Cancer Group. *J Neurosurg*. 1998;88:695-703.
- [173] Evans AE, Anderson JR, Lefkowitz-Boudreaux IB, et al. Adjuvant chemotherapy of childhood posterior fossa ependymoma: cranio-spinal irradiation with or without adjuvant CCNU, vincristine, and prednisone: a Children's Cancer Group study. *Med Pediatr Oncol*. 1996;27:8-14.
- [174] Gilbertson RJ, Bentley L, Hernan R, et al. ERBB receptor signaling promotes ependymoma cell proliferation and represents a potential novel therapeutic target for this disease. *Clin Cancer Res*. 2002;8:3054-3064.
- [175] Bouffet E, Tabori U, Bartels U. Paediatric ependymomas: should we avoid radiotherapy? *Lancet Oncol*. 2007;8:665-666.
- [176] Timmermann B, Kortmann RD, Kuhl J, et al. Role of radiotherapy in anaplastic ependymoma in children under age of 3 years: results of the prospective German brain tumor trials HIT-SKK 87 and 92. *Radiother Oncol*. 2005;77:278-285.
- [177] Barkovich AJ, Krischer J, Kun LE, et al. Brain stem gliomas: a classification system based on magnetic resonance imaging. *Pediatr Neurosurg*. 1990;16:73-83.
- [178] Albright AL, Price RA, Guthkelch AN. Brain stem gliomas of children. A clinicopathological study. *Cancer*. 1983;52: 2313-2319.

- [179] Ternier J, Wray A, Puget S, et al. Tectal plate lesions in children. *J Neurosurg.* 2006;104:369-376.
- [180] Freeman CR, Farmer JP. Pediatric brain stem gliomas: a review. *Int J Radiat Oncol Biol Phys.* 1998;40:265-271.
- [181] Donaldson SS, Laningham F, Fisher PG. Advances toward an understanding of brainstem gliomas. *J Clin Oncol.* 2006; 24:1266-1272.
- [182] Freeman CR, Bourgouin PM, Sanford RA, et al. Long term survivors of childhood brain stem gliomas treated with hyperfractionated radiotherapy. Clinical characteristics and treatment related toxicities. The Pediatric Oncology Group. *Cancer.* 1996;77:555-562.
- [183] Schumacher M, Schulte-Monting J, Stoeter P, et al. Magnetic resonance imaging compared with biopsy in the diagnosis of brainstem diseases of childhood: a multicenter review. *J Neurosurg.* 2007;106:111-119.
- [184] Pierre-Kahn A, Hirsch JF, Vinchon M, et al. Surgical management of brain-stem tumors in children: results and statistical analysis of 75 cases. *J Neurosurg.* 1993;79:845-852.
- [185] Roujeau T, Machado G, Garnett MR, et al. Stereotactic biopsy of diffuse pontine lesions in children. *J Neurosurg.* 2007;107:1-4.
- [186] Shrieve DC, Wara WM, Edwards MS, et al. Hyperfractionated radiation therapy for gliomas of the brainstem in children and in adults. *Int J Radiat Oncol Biol Phys.* 1992;24: 599-610.
- [187] Gilbertson RJ, Hill DA, Hernan R, et al. ERBB1 is amplified and over-expressed in high-grade diffusely infiltrative pediatric brain stem glioma. *Clin Cancer Res.* 2003;9:3620-3624.
- [188] Gururangan S, McLaughlin CA, Brashears J, et al. Incidence and patterns of neuraxis metastases in children with diffuse pontine glioma. *J Neurooncol.* 2006;77:207-212.
- [189] Pollack IF, Hoffman HJ, Humphreys RP, et al. The long-term outcome after surgical treatment of dorsally exophytic brainstem gliomas. *J Neurosurg.* 1993;78:859-863.
- [190] Farmer JP, Montes JL, Freeman CR, et al. Brainstem gliomas. A 10-year institutional review. *Pediatr Neurosurg.* 2001;34:206-214.
- [191] Epstein F, McCleary EL. Intrinsic brainstem tumors of childhood: surgical indications. *J Neurosurg.* 1986;64:11-15.
- [192] Lesniak MS, Klem JM, Weingart J, et al. Surgical outcome following resection of contrast-enhanced pediatric brainstem gliomas. *Pediatr Neurosurg.* 2003;39:314-322.
- [193] Freeman CR, Krischer JP, Sanford RA, et al. Final results of a study of escalating doses of hyperfractionated radiotherapy in brain stem tumors in children: a Pediatric Oncology Group study. *Int J Radiat Oncol Biol Phys.* 1993;27:197-206.
- [194] Combs SE, Steck I, Schulz-Ertner D, et al. Long-term outcome of high precision radiotherapy in patients with brain stem gliomas: results from a difficult to treat patient population using fractionated stereotactic radiotherapy. *Radiother Oncol.* 2009;91:60-66.
- [195] Jenkin RD, Boesel C, Ertel I, et al. Brainstem tumors in childhood: a prospective randomized trial of irradiation with and without adjuvant CCNU, VCR, and prednisone. A report of the Children's Cancer Study Group. *J Neurosurg.* 1987;66:227-233.
- [196] Allen J, Siffert J, Donahue B, et al. A phase I/II study of carboplatin combined with hyperfractionated radiotherapy for brainstem gliomas. *Cancer.* 1999;86:1064-1069.

- [197] Korones DN, Fisher PG, Kretschmar C, et al. Treatment of children with diffuse intrinsic brain stem glioma with radiotherapy, vincristine and oral VP-16: a Children's Oncology Group phase II study. *Pediatr Blood Cancer*. 2008;50:227-230.
- [198] Broniscer A, Iacono L, Chintagumpala M, et al. Role of temozolomide after radiotherapy for newly diagnosed diffuse brainstem glioma in children: results of a multi institutional study (SJHG-98). *Cancer*. 2005;103:133-139.
- [199] Frappaz D, Schell M, Thiess P, et al. Preradiation chemotherapy may improve survival in pediatric diffuse intrinsic brainstem gliomas: final results of BSG 98 prospective trial. *Neuro Oncol*. 2008;10:599-607.
- [200] Freeman CR, Kepner J, Kun LE, et al. A detrimental effect of a combined chemotherapy radiotherapy approach in children with diffuse intrinsic brain stem gliomas? *Int J Radiat Oncol Biol Phys*. 2000;47:561-564.
- [201] Bradley KA, Pollack IF, Reid JM, et al. Moxetaxin gadolinium and involved field radiation therapy for intrinsic pontine glioma of childhood: a Children's Oncology Group phase I study. *Neurooncol*. 2008;10:752-758.
- [202] Lonser RR, Walbridge S, Garmestani K, et al. Successful and safe perfusion of the primate brainstem: in vivo magnetic resonance imaging of macromolecular distribution during infusion. *J Neurosurg*. 2002;97:905-913.
- [203] Allen JC, Siffert J. Contemporary chemotherapy issues for children with brainstem gliomas. *Pediatr Neurosurg*. 1996;24:98-102.
- [204] Ilgren EB, Stiller CA. Cerebellar astrocytomas. Clinical characteristics and prognostic indices. *J Neurooncol*. 1987; 4:293-308.
- [205] Schneider JH Jr, Raffel C, McComb JG. Benign cerebellar astrocytomas of childhood. *Neurosurgery*. 1992;30:58-62.
- [206] Pencalet P, Maixner W, Sainte-Rose C, et al. Benign cerebellar astrocytomas in children. *J Neurosurg*. 1999;90:265-273.
- [207] Sgouros S, Fineron PW, Hockley AD. Cerebellar astrocytoma of childhood: long-term follow-up. *Childs Nerv Syst*. 1995;11:89-96.
- [208] Prados M, Mamelak AN. Metastasizing low grade gliomas in children. Redefining an old disease. *Cancer*. 1994;73: 2671-2673.
- [209] Garcia DM, Marks JE, Latifi HR, et al. Childhood cerebellar astrocytomas: is there a role for postoperative irradiation? *Int J Radiat Oncol Biol Phys*. 1990;18:815-818.
- [210] Packer RJ, Ater J, Allen J, et al. Carboplatin and vincristine chemotherapy for children with newly diagnosed progressive low-grade gliomas. *J Neurosurg*. 1997;86:747-754.
- [211] Larson DA, Wara WM, Edwards MS. Management of childhood cerebellar astrocytoma. *Int J Radiat Oncol Biol Phys*. 1990;18:971-973.
- [212] Packer RJ, Jakacki R, Horn M, et al. Objective response of multiply recurrent low-grade gliomas to bevacizumab and irinotecan. *Pediatr Blood Cancer*. 2009;52:791-795.





## **Management of CNS Tumors**

Edited by Dr. Miklos Garami

ISBN 978-953-307-646-1

Hard cover, 464 pages

**Publisher** InTech

**Published online** 22, September, 2011

**Published in print edition** September, 2011

Management of CNS Tumors is a selected review of Central Nervous System (CNS) tumors with particular emphasis on pathological classification and complex treatment algorithms for each common tumor type. Additional detailed information is provided on selected CNS tumor associated disorders.

### **How to reference**

In order to correctly reference this scholarly work, feel free to copy and paste the following:

Giovanni Scarzello, Maria S. Buzzaccarini and Guido Sotti (2011). Malignant Brain Tumors in Childhood, Management of CNS Tumors, Dr. Miklos Garami (Ed.), ISBN: 978-953-307-646-1, InTech, Available from: <http://www.intechopen.com/books/management-of-cns-tumors/malignant-brain-tumors-in-childhood>

# **INTECH**

open science | open minds

### **InTech Europe**

University Campus STeP Ri  
Slavka Krautzeka 83/A  
51000 Rijeka, Croatia  
Phone: +385 (51) 770 447  
Fax: +385 (51) 686 166  
[www.intechopen.com](http://www.intechopen.com)

### **InTech China**

Unit 405, Office Block, Hotel Equatorial Shanghai  
No.65, Yan An Road (West), Shanghai, 200040, China  
中国上海市延安西路65号上海国际贵都大饭店办公楼405单元  
Phone: +86-21-62489820  
Fax: +86-21-62489821

© 2011 The Author(s). Licensee IntechOpen. This chapter is distributed under the terms of the [Creative Commons Attribution-NonCommercial-ShareAlike-3.0 License](#), which permits use, distribution and reproduction for non-commercial purposes, provided the original is properly cited and derivative works building on this content are distributed under the same license.