

Surgical Technique for Metastatic Brain Tumors

Takeshi Okuda and Amami Kato

*Department of Neurosurgery, Kinki University School of Medicine, Osaka,
Japan*

1. Introduction

In recent years, more effective therapies for cancer, especially systemic chemotherapy regimens, have been developed, and there has been striking improvement in the life expectancy of patients with advanced cancer. However, the benefit from systemic chemotherapy is limited in the case of brain metastases and, conversely, the recent prolongation of the life expectancy of many patients with advanced cancer has translated into a trend for an increase in brain metastases. It can thus be anticipated that there will be an even further increase in the importance of cancer therapy for brain metastases. The main treatment approaches for brain metastases are radiotherapy and surgical resection. Postoperative whole-brain irradiation is a standard therapeutic procedure for metastatic brain tumors. However, local recurrence rates of 10% to 30% have been reported even with concomitant whole-brain irradiation (Patchell et al. 1990; Schackert et al. 2001; Shinoura et al. 2002). In addition, late complications of whole-brain irradiation can greatly affect quality of life in patients (DeAngelis et al. 1989). On the other hand, with regard to surgical resection, the development of surgical devices, such as neuro-navigation systems and intraoperative monitoring, has resulted in dramatic improvements in safety and reliability (Black and Johnson 2004). However, with regard to improvement in the surgical technique itself, there has only been the recommendation for performance of “en bloc resection including a surgical margin of about 5 mm” (Modha et al. 2005), and there have been hardly any innovations, even when compared with the case of malignant glioma surgery. Thus, at first glance, it would seem that metastatic brain tumor surgery has been established. However, in fact, the local recurrence rate is high in the case of surgical resection alone, and attempts are being made to improve the local recurrence rate by performing follow-up treatments such as whole-brain irradiation, stereotactic radiosurgery on the resection cavity, or local chemotherapy (Sills 2005; Kim et al. 2006; Mathieu et al. 2006; Ewend et al. 2007; Ranasinghe and Sheehan 2007). The high local recurrence rate following surgical resection alone clearly implies the presence of residual tumor tissue (Patchell et al. 1998). On the basis of this background, we have been trying various modifications of the surgical technique for surgical resection of metastatic brain tumors to improve the resection rate and the local recurrence rate. Our modifications are explained below.

2. Surgical technique

2.1 Metastatic brain tumor surgery using fluorescein sodium

Fluorescein sodium (Alcon Japan Co., Ltd., Tokyo, Japan) is a tracer of blood-brain barrier disruption, and enhanceable tumors are stained yellow. Fluorescein sodium is extensively

used in ophthalmology, and its safety has been established. The operative technique of using fluorescein sodium has a long history of use during brain tumor surgery, as reported by Moore and Murray (Moore et al. 1948; Murray 1982). A special type of filter must be provided to observe the fluorescence, but Shinoda et al. reported that observation via a normal microscope under white light without using a special type of filter was also possible by intravenously injecting a double dose (20 mg/kg) in glioma surgery (Shinoda et al. 2003). We applied this technique to metastatic brain tumor surgery (Okuda et al. 2007). After induction of general anesthesia, and the dura is opened, fluorescein sodium (20 mg/kg) is injected intravenously. Tumor resection is performed >10 minutes after injection of fluorescein sodium. A yellow-stained tumor is visible under the white light of a normal microscope without a filter. The resected tumor using fluorescein sodium and the schematic diagram are shown in Figure 1.

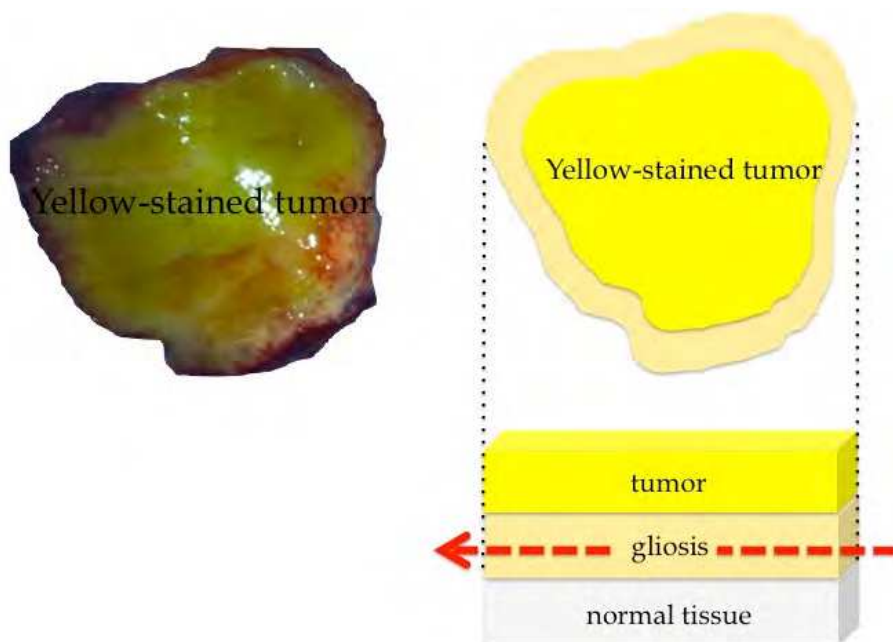


Fig. 1. Cut surface of the resected metastatic brain tumor from primary breast cancer and the schematic diagram.

The tumor parenchyma is stained, and the gliosis portion remains around the tumor. As shown in the diagram, the surrounding gliosis portion is aspirated and resected while carefully confirming the stained tumor. The edematous portion surrounding the tumor is also slightly stained, but it is easy to identify the boundary, and ideal en bloc resection can be achieved while confirming the stained tumor.

Two cases are presented below.

Case 1 was a patient with left frontal lobe metastasis from primary lung cancer (Fig. 2A). Prior to injection of fluorescein sodium (Fig. 3A), the tumor could not be distinguished from the brain surface. After injection (Fig. 3B), the yellow-stained tumor could be distinguished from

the brain surface. Under magnification, the border was clearly discernable (Fig. 3C). The border of the white-colored gliosis could also be discerned (Fig. 3D), and en bloc resection was performed while performing suction and dissection (Fig. 3E). The resection cavity is shown (Fig. 3F). Postoperative MRI shows that complete resection was achieved (Fig. 2B).

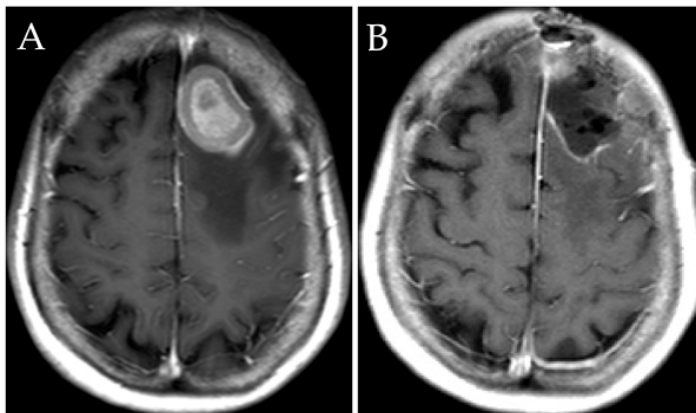


Fig. 2. MRI findings for Case 1 (A)Preoperative enhanced T1-weighted image showing a metastatic brain tumor in the left frontal lobe. (B) Enhanced T1-weighted image 1 day after surgery showing no residual tumor.

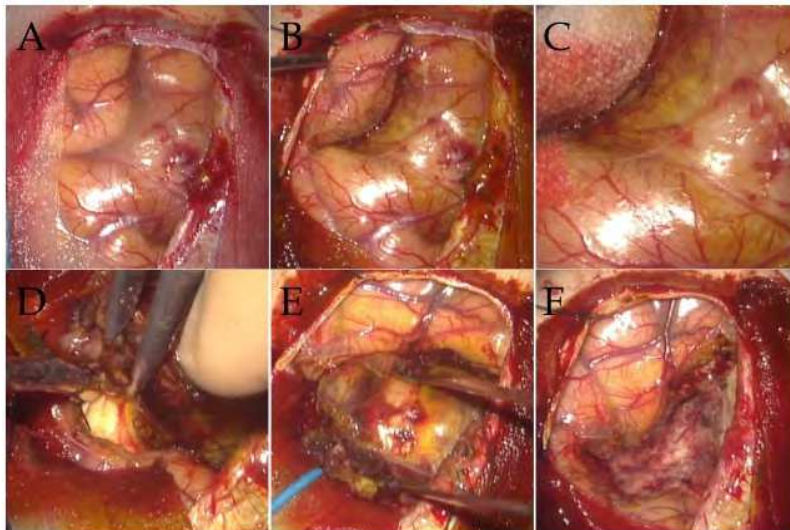


Fig. 3. Intraoperative photographs of Case 1 (A) The brain surface prior to fluorescein sodium injection. (B) The brain surface following fluorescein sodium injection. The yellow-stained tumor can be seen. (C) Magnification of B. (D) The border with the surrounding gliosis portion. (E) En bloc resection. (F) Resection cavity.

Case 2 was a patient with left frontal lobe metastasis from primary renal cell carcinoma (Fig. 4A). The tumor was located in the speech area. Fluorescein sodium was injected intravenously, the tumor was approached through minimal corticotomy, and the yellow-stained tumor surface was confirmed (Fig. 5A, B). En bloc resection was performed (Fig. 5C). Postoperatively, the aphasia symptoms improved, and MRI confirmed that complete resection had been achieved (Fig. 4B). Accordingly, even in cases of brain tumors located in eloquent areas, such as not only the speech area but also the motor area, use of fluorescein sodium makes it possible to carry out resection safely, without any special intraoperative monitoring.

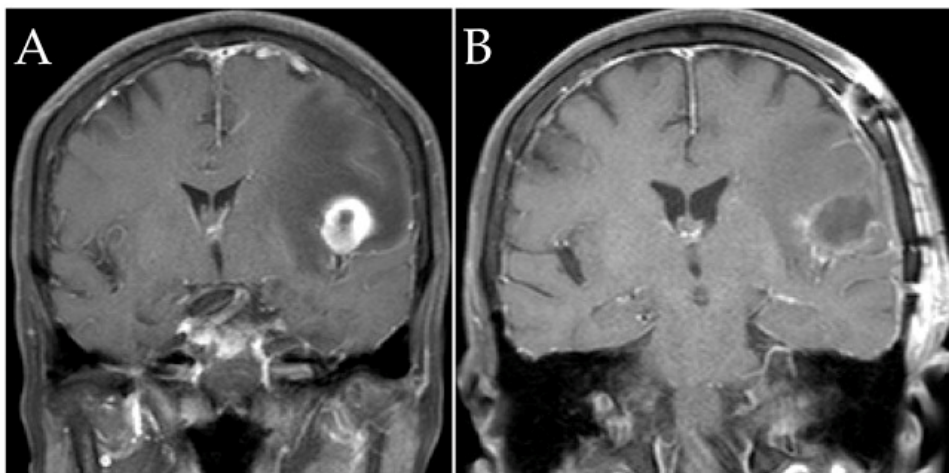


Fig. 4. MRI findings for Case 2 (A) Preoperative enhanced T1-weighted image showing a metastatic brain tumor in the left temporal lobe. (B) Enhanced T1-weighted image 1 day after surgery showing no residual tumor.

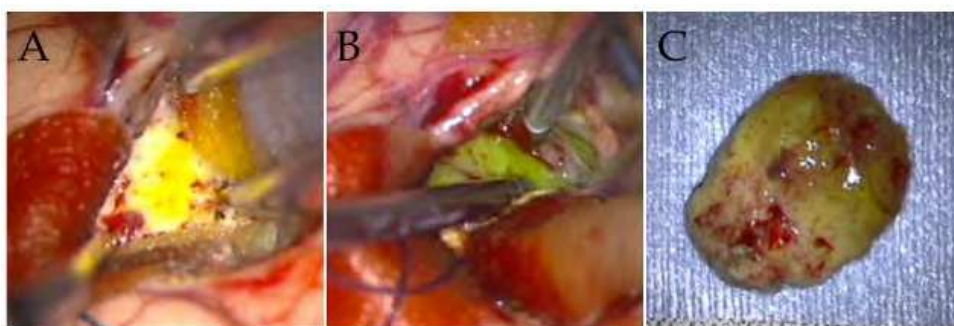


Fig. 5. Intraoperative photographs of Case 2 (A) The tumor surface has been approached, and yellow staining of the tumor by the injected fluorescein sodium is evident. (B) Dissection of the tumor. (C) The tumor was removed by en bloc resection.

To date, we have used fluorescein sodium in more than 100 patients to facilitate surgical resection of metastatic brain tumors, and there have been absolutely no instances of permanent adverse reactions. Anaphylactic shock has been reported as a serious side effect, but it is rare (Tanahashi et al. 2006) and was not observed in our study. As transient adverse events, we have seen yellow staining of the skin, mucosa, and urine, but all cases resolved within 24 hours. This technique will contribute to increasing the resection rate in metastatic brain tumor surgery. Our data also showed statistically significant improvement in the local recurrence rate. Our fluorescence-guided surgery achieved successful local control rates of metastatic brain tumors in 80% of patients without whole-brain irradiation (Okuda et al. 2010). Conversely, previous reports of conventional surgery have yielded successful local control rates of only 54% to 64% under similar conditions (Patchell et al. 1998; Schackert et al. 2001). Although these results are only a guide, based on results from very few patients, fluorescence-guided surgery might enable avoidance or postponement of subsequent whole-brain irradiation, which will not only increase quality of life for patients, but also keeps whole-brain irradiation as a therapeutic option for subsequent brain metastases. This may help to prolong survival and decrease the rate of central nervous system death. This technique is simple, inexpensive, and does not require any special equipment. We are confident that it will be recognized as an important surgical innovation for application to the field of metastatic brain tumor surgery.

2.2 Surgical technique for a cystic-type metastatic brain tumor: transformation to a solid-type tumor using hydrofiber dressing

Cystic-type metastatic brain tumors may have injury to the wall during surgery, which can in some cases result in incomplete tumor resection and dissemination of cancer cells in cyst fluid (Nakagawa et al. 1992). By transforming cystic-type tumors to solid-type tumors, we developed a surgical technique that makes it possible to carry out an ideal en bloc resection (Okuda et al. 2009). In this method, we insert a hydrofiber dressing (Aquacel; Convatec, London, UK) into a cyst, thereby transforming it to a solid-type tumor. Hydrofiber dressing is a coating agent with a high fluid-absorptive capacity that was originally used as a dressing for exudative wounds (Armstrong and Ruckley 1997). Hydrofiber dressing is a sodium carboxymethylcellulose hydrocolloid polymer with fluid-absorptive capacity equal to 25 times its own weight. This material also has a high capacity to retain absorbed water (Fig. 6).




Fig. 6. Images of hydrofiber dressing (A) Hydrofiber dressing can be cut into various sizes. (B) The dotted line shows hydrofiber dressing filled with physiologic saline.

The hydrofiber dressing converts into a gel upon absorption of water, and it integrates with the tumor. As a result, the tumor becomes a soft, solid-type tumor. A flow diagram of the method for using the hydrofiber dressing during the surgical procedure is shown in Figure 7.

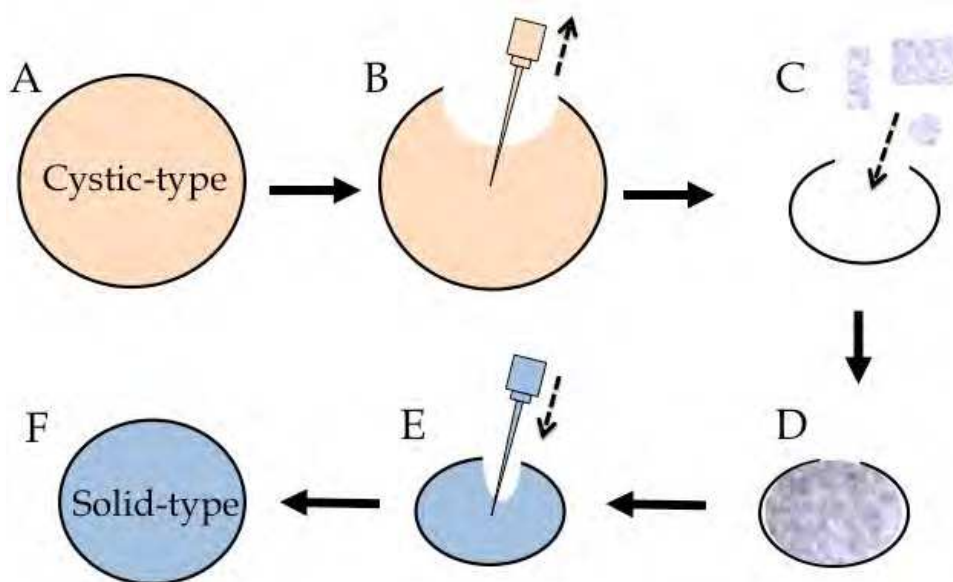


Fig. 7. Schema of cystic-type metastatic brain tumor surgery using hydrofiber dressing(A) Cystic-type tumor before use of hydrofiber dressing. (B) Suctioning of fluid in the cyst. (C, D) Hydrofiber dressing was inserted in the cyst cavity. (E) Injection of physiologic saline. F: The hydrofiber dressing absorbs the fluid in the cyst cavity and fills the cyst, thereby, transforming the tumor into a small solid-type, tumor.

This method converted the cystic-type tumor into a solid-type, small-size tumor, and ideal en bloc resection could be performed. In addition, the hydrofiber dressing absorbs the fluid contents remaining inside the cyst, and by retaining that fluid, it helps prevent tumor cell dissemination during the operation.

A case is presented below.

The patient had a right occipital lobe metastasis of a squamous cell carcinoma (Fig. 8A). First, the cyst was opened for aspiration of fluid (Fig. 9A, B). A small cut was made on the tumor surface to aspirate the fluid contents of the cyst (Fig. 9C), and then hydrofiber dressing was inserted into the cyst (Fig. 9D). Physiologic saline was then injected to fill the cyst (Fig. 9E). En bloc resection was performed (Fig. 9F), and postoperative MRI revealed no residual tumor (Fig. 8B). The tumor that was actually removed by en bloc resection is shown in Figure 10.

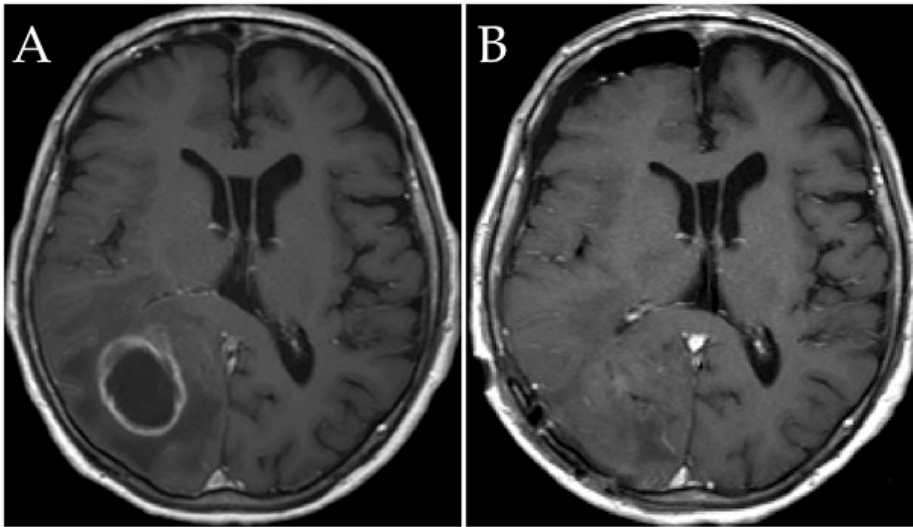


Fig. 8. MRI findings for representative case using hydrofiber dressing (A) Preoperative enhanced T1-weighted image showing a metastatic brain tumor in the right occipital lobe. (B) Enhanced T1-weighted image 1 day after surgery showing no residual tumor.

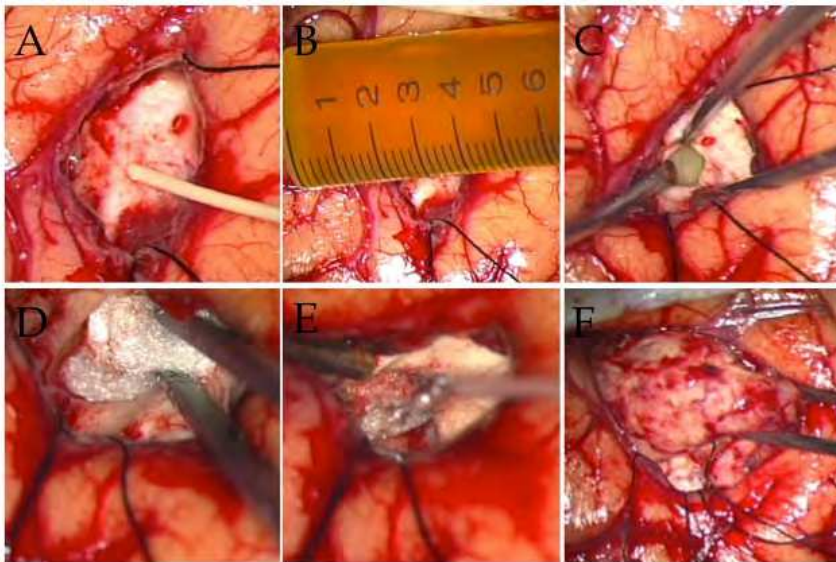


Fig. 9. Intraoperative photographs of representative case using hydrofiber dressing (A) Aspirating of the fluid contents of the cyst. (B) Fluid contents of the cyst. (C) Cyst cavity. (D) Insertion of the hydrofiber dressing. (E) Injection of physiological saline. (F) En bloc resection.

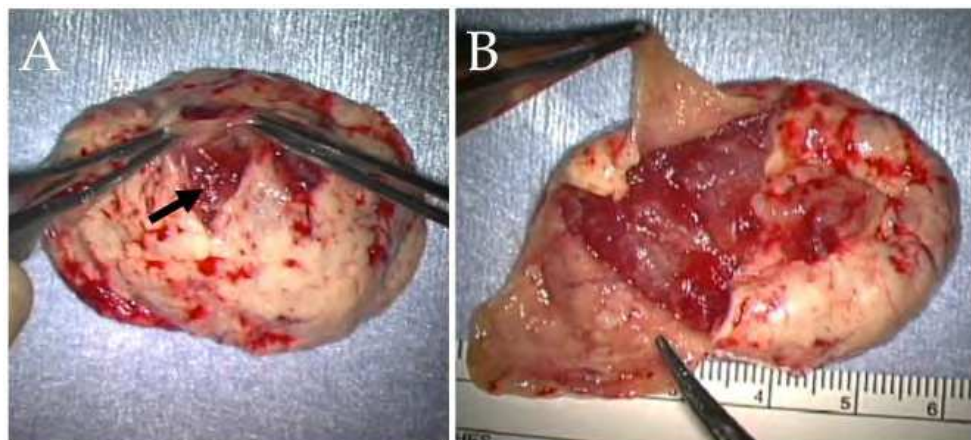


Fig. 10. The resected tumor using hydrofiber dressing (A) The black arrow indicates the opening through which the hydrofiber dressing was inserted. (B) When the cyst wall was incised, it could be seen that the hydrofiber dressing had become a gel inside the cyst.

Hydrofiber dressing is available in a blister pack that has been sterilized by irradiation. Numerous clinical trials for human wounds have confirmed the safety of hydrofiber dressing, and Hoekstra et al. observed few histologic reactions in rats in an examination of the biologic effects of hydrofiber dressing (Hoekstra et al. 2002). There were no adverse events in the 12 patients in our study, and the safety of the method we used is likely to be high, because hydrofiber dressing is used in the cyst without direct contact with brain tissue. Application of this technique to cases of cystic-type metastatic brain tumors makes it possible to perform ideal en bloc resection of the tumor. In addition, it is easy to perform and inexpensive, and we believe that it will prove similarly useful in surgical resection of other cystic brain tumors.

3. Conclusion

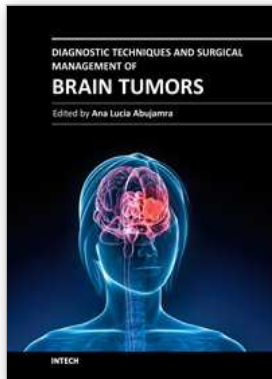
We have described two surgical innovations for metastatic brain tumors. Brain metastases cause serious problems in terms of the quality of life and prognosis of cancer patients. Surgery for metastatic brain tumors can have both good and bad sequelae. The surgical techniques we have described are both easy and safe, and they increase the resection rate while improving the local recurrence rate. As a result, we think that these methods will have great benefit to patients by helping avoid and/or delay radiotherapy, while also improving the clinical symptoms.

4. References

- Armstrong SH, Ruckley CV. Use of a fibrous dressing in exuding leg ulcers. *J Wound Care* 6: 322-4, 1997.
- Black PM, Johnson MD. Surgical resection for patients with solid brain metastases: current status. *J Neurooncol* 69: 119-24, 2004.

- DeAngelis LM, Delattre JY, Posner JB. Radiation-induced dementia in patients cured of brain metastases. *Neurology* 39: 789-96, 1989.
- Ewend MG, Brem S, Gilbert M, Goodkin R, Penar PL, Varia M, Cush S, Carey LA. Treatment of single brain metastasis with resection, intracavity carmustine polymer wafers, and radiation therapy is safe and provides excellent local control. *Clin Cancer Res* 13: 3637-41, 2007.
- Hoekstra MJ, Hermans MH, Richters CD, Dutrieux RP. A histological comparison of acute inflammatory responses with a hydrofibre or tulle gauze dressing. *J Wound Care* 11: 113-7, 2002.
- Kim PK, Ellis TL, Stieber VW, McMullen KP, Shaw EG, McCoy TP, D'Agostino RB, Bourland JD, DeGuzman AF, Ekstrand KE, Raber MR, Tatter SB. Gamma knife surgery targeting the resection cavity of brain metastasis that has progressed after whole-brain radiotherapy. *J Neurosurg* 105: 75-8, 2006.
- Mathieu D, Kondziolka D, Flickinger JC, Fortin D, Kenny B, Michaud K, Mongia S, Niranjan A, Lunsford LD. Tumor bed radiosurgery after resection of cerebral metastases. *Neurosurgery* 62: 817-24, 2008.
- Modha A, Shepard SR, Gutin PH. Surgery of brain metastases- Is there still a place for it? *J Neurooncol* 75: 21-9, 2005.
- Moore GE, Peyton WT, French LA, Walker WW. The clinical use of fluorescein in neurosurgery. The localization of brain tumors. *J Neurosurg* 5: 392-398, 1948.
- Murray KJ. Improved surgical resection of human brain tumors: Part 1. A preliminary study. *Surg Neurol* 17: 316-9, 1982.
- Nakagawa H, Kimura S, Kubo S, Fujita T, Tsuruzono K, Hayakawa T. Prognostic factors in patients surviving for more than 1 or 5 years after removal of metastatic brain tumors. *Neurol Med Chir (Tokyo)* 32: 947-51, 1992.
- Okuda T, Kataoka K, Taneda M. Metastatic brain tumor surgery using fluorescein sodium: technical note. *Minim Invas Neurosurg* 50: 382-4, 2007.
- Okuda T, Teramoto Y, Yugami H, Kataoka K, Kato A. Surgical technique for a cystic-type metastatic Brain tumor: transformation to a solid-type tumor using hydrofiber dressing. *Surg Neurol* 72: 703-6, 2009.
- Okuda T, Kataoka K, Yabuuchi T, Yugami H, Kato A. Fluorescence-guided surgery of metastatic brain tumors using fluorescein sodium. *J Clin Neurosci* 17: 118-21, 2010.
- Patchell RA, Tibbs PA, Walsh JW, Dempsey RJ, Maruyama Y, Kryscio RJ, Markesbery WR, Macdonald JS, Young B. A randomized trial of surgery in the treatment of single metastases to the brain. *N Engl J Med* 322: 494-500, 1990.
- Patchell RA, Tibbs PA, Regine WF, Dempsey RJ, Mohiuddin M, Kryscio RJ, Markesbery WR, Foon KA, Young B. Postoperative radiotherapy in the treatment of single metastases to the brain: a randomized trial. *JAMA* 280(17): 1485-9, 1998.
- Ranasinghe MG, Sheehan JM. Surgical management of brain metastases. *Neurosurg Focus* 22: E2, 2007.
- Schackert G, Steinmetz A, Meier U, Sobottka SB. Surgical management of single and multiple brain metastases: results of a retrospective study. *Onkologie* 24: 246-55, 2001.
- Shinoda J, Yano H, Yoshimura S, Okumura A, Kaku Y, Iwama T, Sakai N. Fluorescence-guided resection of glioblastoma multiforme by using high-dose fluorescein sodium. *J Neurosurg* 99: 597-603, 2003.

- Shinoura N, Yamada R, Okamoto K, Nakamura O, Shitara N. Local recurrence of metastatic brain tumor after stereotactic radiosurgery or surgery plus radiation. *J Neurooncol* 60: 71-7, 2002.
- Sills AK. Current treatment approaches to surgery for brain metastases. *Neurosurgery* 57(Suppl.): S24-32, 2005.
- Tanahashi S, Lida H, Dohi S. An anaphylactoid reaction after administration of fluorescein sodium during neurosurgery. *Anesth Analg* 103: 503, 2006.



Diagnostic Techniques and Surgical Management of Brain Tumors

Edited by Dr. Ana Lucia Abujamra

ISBN 978-953-307-589-1

Hard cover, 544 pages

Publisher InTech

Published online 22, September, 2011

Published in print edition September, 2011

The focus of the book *Diagnostic Techniques and Surgical Management of Brain Tumors* is on describing the established and newly-arising techniques to diagnose central nervous system tumors, with a special focus on neuroimaging, followed by a discussion on the neurosurgical guidelines and techniques to manage and treat this disease. Each chapter in the *Diagnostic Techniques and Surgical Management of Brain Tumors* is authored by international experts with extensive experience in the areas covered.

How to reference

In order to correctly reference this scholarly work, feel free to copy and paste the following:

Takeshi Okuda and Amami Kato (2011). Surgical Technique for Metastatic Brain Tumors, *Diagnostic Techniques and Surgical Management of Brain Tumors*, Dr. Ana Lucia Abujamra (Ed.), ISBN: 978-953-307-589-1, InTech, Available from: <http://www.intechopen.com/books/diagnostic-techniques-and-surgical-management-of-brain-tumors/surgical-technique-for-metastatic-brain-tumors>

INTECH

open science | open minds

InTech Europe

University Campus STeP Ri
Slavka Krautzeka 83/A
51000 Rijeka, Croatia
Phone: +385 (51) 770 447
Fax: +385 (51) 686 166
www.intechopen.com

InTech China

Unit 405, Office Block, Hotel Equatorial Shanghai
No.65, Yan An Road (West), Shanghai, 200040, China
中国上海市延安西路65号上海国际贵都大饭店办公楼405单元
Phone: +86-21-62489820
Fax: +86-21-62489821

© 2011 The Author(s). Licensee IntechOpen. This chapter is distributed under the terms of the [Creative Commons Attribution-NonCommercial-ShareAlike-3.0 License](#), which permits use, distribution and reproduction for non-commercial purposes, provided the original is properly cited and derivative works building on this content are distributed under the same license.