

Management of Congenital Aortic Stenosis by Catheter Techniques

Mehnaz Atiq
*Aga Khan University Hospital, Karachi,
Pakistan*

1. Introduction

Aortic valve stenosis constitutes 3-6% of congenital heart diseases with an incidence of 1-4 per 10,000 live births (Khalid et al, 2006). The prevalence of aortic stenosis at birth is 0.03% (Mahle et al, 2010). If left untreated, it can lead to considerable morbidity and mortality in neonates, infants, children and adults.

Until three decades ago, the only treatment that could be offered to children with aortic stenosis was surgical valvotomy and valve replacement in adults. In 1983 balloon valvuloplasty was introduced as the initial palliation of choice for aortic valve stenosis in children and adolescents. Later in 1985, the procedure was extended to infants with critical aortic stenosis (Pass & Hellenbrand, 2002). Over the past 25 years advancement in technique and equipment has radically improved the safety and outcome of balloon valvuloplasty of aortic valve.

Pathologically the stenosed aortic valve may be tricuspid (trileaflet), bicuspid or unicuspid (Fernandes et al, 2007). The latter is the result of failure of separation of the three leaflets with stenosis being centrally located. Rarely the annulus may be hypoplastic or secondary calcification may develop in children and adolescents.

Bicuspid aortic valve is seen on 1-2% of general population (Bermudez, 2007). Natural history of bicuspid aortic valve is not well defined in children but has a spectrum ranging from critical stenosis to no stenosis or regurgitation (Han et al, 2007). After the fourth decade it can progress to aortic stenosis and regurgitation due to thickening, fibrosis and calcification, imparting rigidity to the fused cusps or due to infective endocarditis. There is associated aortopathy with bicuspid aortic valves, in adults as well as children, in which dilatation of ascending aorta is seen increasing the incidence of aortic dissection. Factors related to aortic dilatation are severity of aortic stenosis and regurgitation and jet angle of left ventricular ejection (Mahle et al, 2010).

2. Evaluation of aortic stenosis for intervention

Neonates with critical aortic stenosis present with a low cardiac output syndrome or cardiogenic shock. The stenosis in neonates is considered "severe" if there is no arterial duct dependent systemic circulation in which case it is "critical" (Magee et al, 1997). In older children, pertinent clinical evaluation of severity of aortic stenosis includes presence of symptoms and signs of congestive cardiac failure, pulsus alternans, carotid shudder, reversed splitting of second heart sound and intensity of the ejection systolic murmur. Electrocardiogram is useful in noting the degree of left ventricular hypertrophy and strain.

Echocardiography offers the most reliable way of assessing suitability for catheter intervention and also to predict its outcome. Aortic valve morphology can be identified as tricuspid, bicuspid or unicuspid. In evaluating bicuspid aortic valve, echocardiographic appearance of vertical or horizontal commissural orientation is noted in parasternal short axis view in diastole which makes the cusps either left-right or anterior-posterior in location respectively. It would be worthwhile noting the raphe which denotes fusion of two leaflets in bicuspid aortic valve (Bermudez et al, 2007). The fusion is categorized as right-left fusion, right-non coronary fusion or left-non coronary fusion. Fusion of right and non-coronary cusp has a two fold increase in the probability of requiring intervention.

Thick leaflets are characteristic of dysplastic aortic valve. 2-D measurements include left ventricular size in length, diameter, systole and diastole, functional assessment of left ventricle and aortic annulus diameter. The latter is measured at the hinge point in the parasternal long axis view. It is important to note the presence and severity of aortic regurgitation before patient selection for balloon valvuloplasty. Aortic regurgitation can be graded as mild, moderate or severe according to criteria mentioned elsewhere (Bonow et al, 2008). Mitral valve disease and incompetence should be assessed. Doppler gradients across aortic valve, peak and mean, have to be measured. Previously exercise testing was used to grade severity of aortic valve stenosis. But the accuracy of echocardiography in evaluating severity has limited its use (Khalid et al, 2006).

3. Indications for intervention

According to AHA/ACC guidelines, aortic stenosis is graded as mild, moderate and severe on basis of hemodynamic and natural history data using basis of aortic jet velocity, mean pressure gradient and valve area (in adolescents and adults). Severe aortic stenosis is when the area is $<1 \text{ cm}^2$, MPG is $> 40 \text{ mmHg}$ and jet velocity is greater than 4 m/sec . Intervention should be done if the peak to peak gradient is 50 mmHg in symptomatic and 60 mmHg in the asymptomatic patients (Bonow et al, 2008). Additional indications include strain on electrocardiogram, presence of symptoms or LV dysfunction irrespective of gradients. Moderate or severe aortic regurgitation is a contraindication to valvuloplasty.

4. Pre-catheterization stabilization

In critically sick neonates and infants, stabilization should begin in the intensive care unit. All neonates, infants and children should be mechanically ventilated, controlled on temperature with warming mattress, optimized on acid-base and electrolyte balance, calcium and magnesium status, blood pressures and cardiac output. The latter is done with intravenous inotrope and prostaglandin infusion to maintain ductal patency in neonates. An arterial blood gas should be analyzed prior to the procedure. Blood products should be made available in case of complications. Antiarrhythmic drugs and defibrillator should be ready in case ventricular arrhythmias occur, as these patients are at a high risk for such complications due to catheter and wire manipulation particularly in a failing left ventricle (Pass & Hellenbrand, 2002).

5. Balloon aortic valvuloplasty

In neonates and children, balloon aortic valvuloplasty has become the palliative procedure of choice, preferred over open aortic valvotomy (Weber et al, 2006; Egito et al, 1997; Knirsch

et al, 2008). The aim of balloon valvuloplasty is to relieve left ventricular outflow tract obstruction thereby improving cardiac output, myocardial hypertrophy and function (Bonow et al, 2008). Monitoring during the procedure includes hemodynamic non-invasive pulse oximetry, blood pressures and many clinicians advocate transesophageal echocardiography for guidance as well as hemodynamic monitoring. This would avoid over dilation of aortic valve and also provide a reliable noninvasive way of assessing aortic insufficiency without having to perform frequent ascending aortogram.

5.1 Approach for valvuloplasty

Historically, over the last 25 years, various approaches have been used for balloon valvuloplasty. These different catheter techniques have their own advantages and disadvantages and there is no consensus as to which is the optimal approach, particularly in neonates with critical aortic stenosis. Some of these have historical importance only.

5.1.1 Retrograde umbilical artery approach

Umbilical arterial approach was advocated by Beekman in 1991 in neonates with critical aortic stenosis. They found this method technically easier than transvenous antegrade approach particularly in cases with hypertrophied small left ventricle. This route also avoided injury to the femoral artery by large catheters available in those days (Beekman et al, 1988).

The procedure involves cannulating both the umbilical arteries with 4 or 5 French catheters and a transvenous catheter for gaining antegrade access to the left ventricle. The umbilical arteries were used for balloon dilation through one and monitor aortic pressure with the other. The transvenous catheter was used to perform left ventriculogram and monitor left ventricular pressures during the procedure. Egito et al reported their series of 33 cases with a 91% success with this route (Egito et al, 1997). Despite these successful studies, no recent reports are found with this technique presumably due to availability of better alternatives.

5.1.2 Right scapular artery approach

Reported in 1995 by Alekyan et al in a cohort of 21 infants, this procedure involves surgical exposure of the right axillary and subscapular artery with introduction of sheaths and balloon catheters. This route can accommodate larger catheters. Post procedure the incision is closed with sutures. Success rate was reported to be 68% by these authors with failures attributed to aberrant right subclavian artery or to technical difficulties caused by anatomy in small infants (Alekyan et al, 1995).

5.1.3 Transcarotid approach

This approach was introduced by Fischer et al in 1990 as an alternate to retrograde femoral approach in critically ill neonates (Fischer et al, 1990; Maeno et al, 1997). The right carotid was surgically cut down and balloon catheter introduced. An 80-97% success rate was reported with complications occurring in 10% of patients (Weber et al). These included significant blood loss, ventricular fibrillation and ventricular perforation. The carotid artery on follow up was found occluded in 3%, stenotic in 8% and patent in the remaining 89%. The approach has the advantage of ease of crossing the aortic valve and avoiding injury to femoral artery.

5.1.4 Transvenous antegrade approach

This is favored by many clinicians because of the sparing effect on femoral artery and avoiding inadvertent perforation of aortic valve cusp. It was first introduced by Hausdorf in 1993 (Hausdorf et al, 1993) and then endorsed by several workers (Magee et al, 1997; Han et al 2007). The approach involves crossing of foramen ovale and entering the left ventricle. A loop is then formed using balloon tipped catheter to avoid mitral valve apparatus. The aortic valve is crossed antegradely over a wire thus avoiding injury to its cusps. This approach also ensures a relative stable position of the balloon during inflation without being forced out due to contractions. Risks involved include jeopardy of mitral valve apparatus producing mitral regurgitation, inherent risks of trans-septal puncture in a small infant or neonate if it has to be done, difficulty in directing the flow guided catheter towards the aortic valve in a small and hypertrophied left ventricle, and the threat of ventricular arrhythmias and perforation.

5.1.5 Transfemoral retrograde approach

This is the most commonly used method having the obvious advantage of easy access and straight catheter course. Balloons used initially were of high profile requiring large sheaths. There was a high risk of cusp perforation with the use of stiffer guide wires to cross the aortic valve (Weber et al, 2006). However with the improvement in technology, low profile balloons have significantly reduced the frequency of femoral arterial injury. The incidence of cusps perforation has also diminished with the use of floppy tipped guide wires.

5.1.6 Double balloon technique:

Use of double balloon is a modification of single balloon, originally proposed by Beekman et al in 1988. It is applicable when balloon valvuloplasty is performed in older children and young adults where the big size of single balloon would endanger the femoral artery. Both the femoral arteries are accessed and aortic valve is crossed twice from both sides in a retrograde fashion. Two balloons of the same size are chosen, the sum of their diameters amounting to 1.3 times the size of the aortic annulus. The two balloons are inflated simultaneously. The advantages are not only less injury to the two femoral arteries but also the crevice between two balloons avoids complete left ventricular outflow obstruction during balloon inflation. (Beekman et al, 1988) .

5.2 Technical considerations

Percutaneous technique for retrograde balloon aortic valvuloplasty involves femoral arterial and venous access. The bottleneck is access in neonates with critical aortic stenosis. Ultrasound guided percutaneous access is a good way to deal with such difficulties. The other option is to expose the artery through a surgical cut down. The femoral venous access is for insertion of a temporary pacemaker. A 3-4 Fr sheath initially for the artery and a 5Fr sheath for the vein are inserted using the modified Seldinger technique (Randolph et al). A temporary pacemaker is inserted in the right ventricle and the rate, output and sensitivities are determined before commencing the procedure for balloon dilation. The desired paced heart rate is the one that would reduce the systemic blood pressure by half. The concept of pacing to achieve tachycardia is to temporarily reduce the cardiac output in order to stabilize the balloon position during inflation (Leon et al, 2010; Marshall et al, 2005; Gupta et al, 2010). Another method of reducing cardiac output, very popular a decade ago, was to

inject intravenous adenosine rapidly to produce cardiac standstill (by inducing sinoatrial and atrioventricular block) to allow unproblematic balloon inflation (Karago et al, 2008). Many clinicians would not pace neonates particularly if the left ventricular function is decreased.

With a pigtail catheter, an ascending aortogram is done. This helps in identifying and grading aortic regurgitation as well as measuring the aortic valve annulus diameter and jet width and direction. The thickness of valve leaflet is measured and classified on anteroposterior or lateral cineangiograms as thin (< 2mm) or thick (>2mm) (Egito et al, 1997). The major impediment is crossing the stenosed, invariably eccentric orifice of the aortic valve. The catheter used for this purpose is usually pediatric right Judkin's catheter or any other suitable catheter that would align itself to the jet direction. The aortic valve orifice is traversed with a floppy tipped guide wire. This would avoid valve perforation and crossing through the valve leaflet which was a problem encountered in early years. The initial guide wire to cross the aortic valve could either be a 0.014-in. coronary wire (C.R. Bard Inc.), a 0.035-in. flexible tipped wire (Wholey, Mallinckrodt Medical), a 0.035- or 0.018-in. hydrophilic wire (Terumo Corp., Tokyo, Japan) or a 0.025-in. Teflon-coated wire (Cook Inc.) (Magee, 1997).

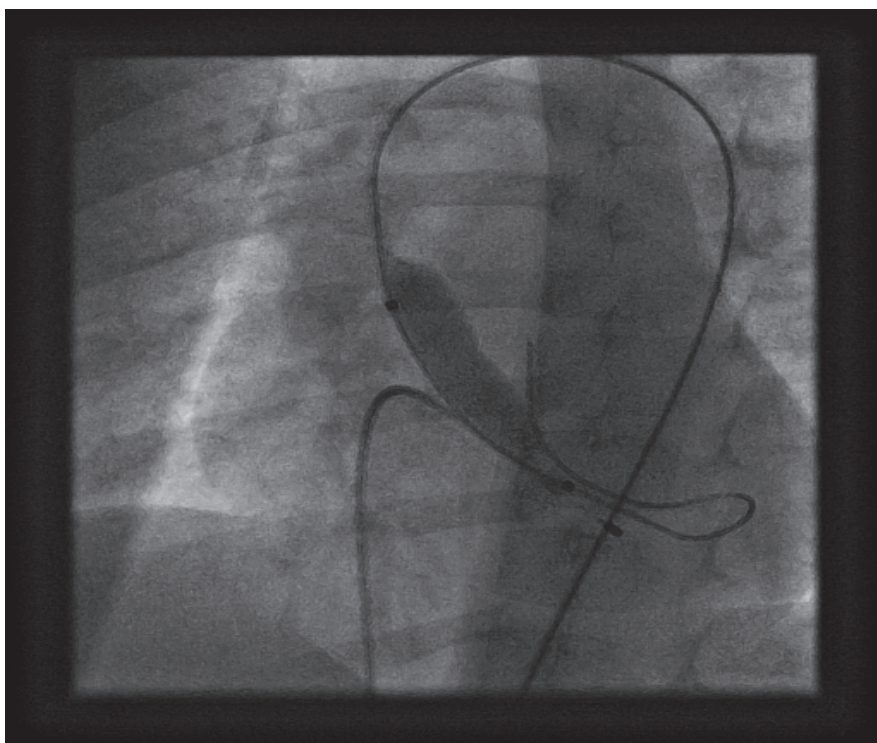


Fig. 1. Retrograde balloon aortic valvuloplasty in an infant with a temporary pacemaker wire in place

Once across, depending upon the severity of stenosis and patient stability, the floppy guide wire is exchanged for a stiffer wire whose end has been shaped manually to make it curl inside the left ventricle. A left ventriculogram is done which would further define the aortic valve anatomy, degree of mitral regurgitation and left ventricular function. A low profile balloon whose size should be 80-90% of the aortic valve annulus diameter and 2-3 cm in length is selected and advanced across the aortic valve annulus. Rapid pacing is ensued and balloon inflated using 1/3rd to 1/4th diluted contrast, preferably with the help of an inflation device. This is a crucial part in which a controlled inflation is aimed at, looking for the appearance and disappearance of the waist, to avoid over dilation and producing aortic valve regurgitation (Figure 1). Some newer balloons have been designed with a double step dilation (example first 15mm and then 20 mm) (Berland et al, 1989) and may be of use in adolescents.

Post dilation, catheters are changed and pressures measured again in the left ventricle and aorta, preferably with a multi-track catheter. If the left ventricular pressures are unacceptably high, re-dilation is done with the same balloon or sometimes with another balloon 1mm larger in size. A left ventriculogram is performed to relook at the aortic valve mobility, mitral regurgitation and left ventricular function (Magee et al, 1997). A post dilation aortogram is done to look at aortic regurgitation and jet width.

5.3 Difficulties and complications

Balloon aortic valvuloplasty like most interventional procedures is semi-blind. The major hindrance is crossing the aortic valve, particularly to be anticipated in neonates with critical or severe aortic stenosis. At times the guide wire crosses but the catheter or balloon catheter may not cross. In such a situation, pre-dilation with a small coronary balloon catheter is done.

There is a risk of ventricular tachycardia and fibrillation due to irritation produced by guide wires and catheters placed in an ischemic left ventricle. Cardiac perforation can occur particularly if soft wires are not used. Femoral artery access, particularly in neonates, carries the risk of damage to the vessel, resulting in thrombosis and potential limb complications up to 39% (Pass & Hellenrand,2002; Magee et al, 1997; Egito et al 1997). Aortic arch dissection flaps are seen during or post procedure and are related to use of stiffer wires or balloons with larger internal diameter lumen than the wire. This problem can be overcome to some extent by pre-shaping the guide wire.

Mitral regurgitation is a complication after balloon valvuloplasty particularly with the antegrade approach, less commonly with the retrograde approach. This is mainly due to the catheter, guide wire and/or balloon catching on the mitral valve. In many patients the myomatous nature of the mitral valve and the small left ventricular cavity are compounding factors for this complication. Mitral and acute aortic regurgitation can lead to acute pulmonary edema.

5.4 Poor outcome

The results of balloon aortic valvuloplasty are considered suboptimal if the valve fails to dilate and there are residual Doppler gradients of more than 50 mmHg, moderate or severe aortic valve regurgitation, moderate or severe mitral valve regurgitation and worsening left ventricular function (Rao et al, 1989).

Risk factors for poor results (residual gradients of >50mmHg) include older or neonatal age group, symptomatic patient (Knirsch et al. 2008), dysplastic aortic valves and left ventricular

dysfunction. The procedure is contraindicated in patients with associated moderate aortic regurgitation or hypoplastic left ventricle. Additional risk factors for poor outcome in a neonate include ductal dependency, mitral valve disease, notably stenosis, non-apex forming left ventricle, and hypoplastic aortic valve annulus (<6mm in diameter)(Knirsch et al, 2008).

Mortality related to the procedure has been reported to be around 12% mainly due to cusp perforation and avulsion producing severe regurgitation, and left ventricular perforation with guide wire. One study reported 46% mortality due to ventricular fibrillation, avulsion of aortic valve cusp and severe aortic regurgitation (Magee et al, 1997). This would lead to a sudden volume overload, together with reduced coronary perfusion of a poorly functioning or hypertrophied left ventricle can rapidly lead to hypotension and acidosis which can prove fatal.

5.5 Aortic regurgitation

The single complication to be avoided during balloon valvuloplasty is development or worsening of aortic regurgitation. Aortic regurgitation was caused by a combination of commissural avulsion, cusp dehiscence with retraction, cusp tear, central incompetence, perforated cusp, cusp prolapse, or cusp adhesion to the aortic wall (Bacha et al, 2001; Balmer et al, 2004). There is a relationship of this complication to the use of oversized balloons. The dilemma faced in the catheterization laboratory is the decision on when to upsize (or not to upsize) the balloon, if residual gradients of 30 to 40 mm Hg are found. In older patients if residual gradients are high and the degree of aortic regurgitation is only mild or trivial, one can afford to upsize the balloon. However if residual gradients are <30 mm Hg, there is very little to be gained in upsizing the balloon as aortic regurgitation would be produced. Furthermore, balloons usually are only available in 1- to 2-mm increments, making upsizing very risky. Holzer et al found that freedom from aortic valve replacement was not any worse (and potentially better) in patients with residual gradients of <35 mm Hg and moderate or severe aortic regurgitation compared with patients with residual gradients of >35 mm Hg and mild aortic regurgitation. This report should help in persuading operators to upsize the balloon if the gradient is 35 to 40 mm Hg with just mild aortic regurgitation, rather than a more conservative approach for fear of creating more aortic regurgitation (Holzer et al, 2010).

It should be noted that even if the degree of aortic regurgitation is minimal immediately after balloon valvuloplasty, it does not remain so in the medium and long term follow up, it is usually progressive. Explanation for this phenomenon is that blood flow through the aortic valve leads to constant hemodynamic trauma to the valve tissue resulting in progressive tearing, scarring, retraction, and calcification of the valve (Balmer et al, 2004).

5.6 Balloon aortic valvuloplasty in adults

In symptomatic adolescents and adults with aortic stenosis, the procedure of choice is surgical therapy with either valve replacement or Ross procedure. Balloon aortic valvuloplasty may be offered to pregnant females to reduce the risks of pregnancy. It can also be offered to young adults with pliable valves who are not considered candidates for surgical therapy. Another group is adults who need stabilization before undergoing valve replacement. These are patients with severe aortic stenosis and poor left ventricular function who have symptoms of congestive heart failure. If not operated upon, they have a mortality

rate of 60% at 1 year. Although the exact place of the valvuloplasty procedure in the treatment of aortic stenosis in adults is yet to be determined, there is immediate clinical improvement in most of the patients with poor left ventricular function for whom surgery is not definitely contraindicated. It is therefore to be considered as a bridge to surgery in hemodynamically unstable patients to improve their operative risks (Berland et al, 1989; Singh et al, 2008).

5.7 Balloon aortic valvuloplasty in special circumstances

Balloon aortic valvuloplasty is done in all patients undergoing percutaneous valve implantation to allow the balloon-valve assembly to cross the aortic valve (Leon et al, 2010). Balloon aortic valvuloplasty has been attempted in stenosed surgical bioprostheses with mixed results in literature. Majority admit it has limited application with great caution in some instances and disappointment in others (Kirwan et al, 2004; Waller et al, 1991). The reason is that the bioprosthetic valve leaflets are at relatively high risk of tearing resulting in dehiscence, regurgitation or embolism. Lasting significant benefit has not been documented because of high incidence of restenosis (Webb J, 2011). Therefore repeat surgery or supportive medical therapy is advocated in such patients. It may be possible that the growing experience with percutaneous valve implantation may make the future of patients with failed bioprosthetic valves bright by “valve in valve” implantation.

Balloon valvuloplasty can be done as a hybrid procedure with a trans-apical access in premature infants in whom peripheral vascular access may not be possible (Maschietto et al, 2011).

5.8 Balloon valvuloplasty for aortic stenosis in the fetus

This is an evolving field with successful reports from several workers. The main idea is to improve left ventricular growth in cases of suspected hypoplasia of left ventricle (Marshall et al, 2005). Aortic stenosis is identified by fetal echocardiography. Noted are the thickness of the aortic valve leaflets, marked turbulence across the aortic valve and left ventricular dysfunction. Mothers undergo general anesthesia and are placed in an optimal position to obtain good ultrasound images. This position may be supine with required uterine displacement with external manipulation. Poor position may result in technical failure. In that case sometimes a mini laprotomy may be helpful and ultrasound being done directly per-uterine. The fetus is then given intramuscular anesthetic agent and muscle relaxant.

Balloon size is determined by the aortic valve annulus and a balloon size can go up to 120%. A low profile coronary balloon catheter is chosen and mounted over a floppy tipped guide wire. The introducer is advanced through the fetal chest into the left ventricular cavity. The trocar is removed and intra ventricular position confirmed by the back flow of blood.

The wire catheter assembly is passed through the canula until the wire is identified in the ascending aorta. The balloon is advanced and inflation done gently with an inflation device to achieve the required pressure. One or more inflations can be done, each not being for more than 5 seconds. The whole wire and catheter assembly is then withdrawn.

The results are usually good with relief of gradient. It is difficult to determine the ideal balloon size. There is no way to measure decrease in gradient. Waist produced during inflation is not seen. One can appreciate improved flow across the aortic valve and appearance of new aortic regurgitation. In experimental animals, fetal aortic regurgitation occurring post balloon valvuloplasty led to hydrops fetalis. This complication has not been reported in human subjects. In fact aortic regurgitation can improve due to the remodeling

capacity of fetal aortic valve leaflets. Thus fetal aortic valvuloplasty has promising future for severe aortic stenosis.

6. Clinical outcome of balloon aortic valvuloplasty at intermediate and long term follow up

Intermediate and long term results of aortic valvuloplasty of congenital aortic valve stenosis in preventing or postponing aortic valve surgery are very good (Fratz et al, 2008). Survival after successful balloon valvuloplasty without significant residual stenosis or regurgitation has been reported to be 86% at 1 year and continues to remain the same until 10 years (Han et al, 2007). Left ventricular dysfunction improved in 87% on follow up (Egito et al, 1997). Incidence of re-intervention is variable and depends on the age of intervention and conservative interventional strategy used at the time of dilation. Pass et al reported a 64% freedom from re-intervention at 8 years follow up. A second re-dilation is usually required in neonates 1 month to 6 years after the initial procedure. Criteria for re-dilation would be the same as stated previously. Presence moderate or severe aortic regurgitation should preclude further balloon valvuloplasty (Khalid et al, 2006)¹.

Special reference must be made to neonatal severe or critical aortic stenosis which may be a different disease from congenital aortic stenosis treated later in life (Brown et al, 2010). The risk for both mortality and re-dilatation is higher in newborns with symptomatic aortic stenosis than in older infants, children, and adolescents or adults. Prime aim of dilating these frail neonates is to provide some relief of obstruction to allow the left ventricle to recover and at the same time avoid regurgitation. Therefore acceptable residual gradients may be higher in this group with an understanding that they may have recurrent aortic stenosis much earlier due to their rapid growth phase.

Surgical intervention is required as a subsequent procedure when the aortic regurgitation is moderate to severe, or the valve is dysplastic and could not be dilated. In neonates and young children, surgical valvotomy for stenosis and repair for regurgitation are standard procedure. Aortic regurgitation is a complication of aortic valvotomy as well. Other surgical options are Ross operation or aortic valve replacement in older children. A significant number of patients after both aortic valvuloplasty and aortic valve surgery may require aortic valve replacement for progressive aortic regurgitation. Many non randomized comparisons have been made between results of aortic valvuloplasty and aortic valve surgery. The two were found comparable in terms of gradient relief, procedural mortality and long term survival. Therefore both procedures are essentially palliative. Consequently proponents of aortic valvuloplasty as an initial procedure can argue that with it the patient can benefit from one less surgery in their life (Knirsch et al, 2008). In one follow up data the freedom from aortic valve replacement was 79% at 10 years and 55% at 20 years (Brown et al, 2010 a). This becomes an important part of patient counseling while committing to care of patients with aortic valve stenosis. Those with severe left ventricular dysfunction and endocardial fibrosis may be candidates for cardiac transplant.

The risk for late sudden cardiovascular death after balloon aortic valvuloplasty is not associated with acute post-procedural hemodynamic status. However, there are some significant predictors for the same, notably the presence of multiple left-heart obstructive lesions. Patients undergoing balloon valvuloplasty in the neonatal period also have a higher risk for sudden cardiovascular death after balloon valvuloplasty, which may be a marker of more severe or progressive disease (Brown et al, 2010 b).

7. Percutaneous aortic valve implantation

Calcific aortic stenosis is the most common valvular heart disease, affecting 2% to 4% of adults over age 65 in the United States. The prevalence of degenerative aortic stenosis increases with advancing age. It has a long asymptomatic phase, but when symptoms finally occur, clinical deterioration can be rapid with 50% mortality within two years of developing symptoms (Leon et al, 2010). Surgical aortic valve replacement is the gold standard therapy for adult patients with symptomatic severe aortic stenosis, be it congenital or degenerative in etiology.

The steady increase in the number of patients requiring aortic valve replacement and the high surgical risk in patients with multiple co-morbidities have been driving the development of percutaneous techniques for the treatment of aortic stenosis. Other perceived advantages include less trauma, often faster recovery and fewer hospital days. There is a reluctance of some patients to undergo the trauma and pain associated with open heart surgery via sternotomy.

It is estimated that for each two patients with severe symptomatic aortic stenosis undergoing surgical valve replacement, there is at least one patient who will never undergo surgery because of the perceived high risk. A recent study showed that 33% of patients over age 75 were deemed too high-risk for open heart surgery and thus were left untreated (Spargias et al, 2008).

In 2002, Cribier et al reported the first successful human percutaneous aortic valve implantation done antegradely via femoral vein. The approach had an inherent risk of mitral valve damage, ventricular perforation and tamponade. Thereafter the retrograde approach has become popular. Indications for percutaneous valve implantation are severe aortic stenosis with an aortic valve area of <0.8 cm², MPG of >49 mmHg or a peak flow velocity of >4 m/s (28). Pertinent exclusion criteria are bicuspid aortic valve, acute myocardial infarction, significant coronary artery disease, left ventricular ejection fraction less than 20%, diameter of aortic valve annulus less than 18mm or more than 25mm, severe aortic or mitral regurgitation and severe renal failure (Leon et al, 2008).

Details of the technique and its application are described elsewhere.

8. Conclusion


Transcatheter treatment of congenital aortic valve stenosis is the intervention of choice in neonates, infants, children and also adolescents with good results. Valvuloplasty has a limited role in adults. Percutaneous aortic valve replacement has emerged as a therapeutic option in the elderly who are not candidates for surgical aortic valve replacement.

9. References

- Alekyan BG, Petrosyan YS, Coulson JD, Danilov YY, Vinokurov AV. Right scapular artery catheterization for balloon valvuloplasty for critical aortic stenosis in infants. *Am L Cardiol* 1995; 76: 1049-52.
- Bacha EA, Satou GM, Moran AM, et al. Valve-sparing operation for balloon induced aortic regurgitation in congenital aortic stenosis. *J Thorac Cardiovasc Surg* 2001; 122:162-8.

- Balmer C, Beghetti M, Fasnacht M, Friedli B, Arbenz U. Balloon aortic valvuloplasty in paediatric patients: progressive aortic regurgitation is common. *Heart* 2004; 90(1): 77-81.
- Beekman RH, Rocchini AP, Crowley DC, Snider AR, Serwer GA, Dick M, Rosenthal A. Comparison of single and double balloon valvuloplasty in children with aortic stenosis. *J Am Coll Cardiol* 1988; 12:480-5.
- Berland J, Cribier A, Savin T, Lefebvre E, Koning R, Letac B. Percutaneous balloon aortic valvuloplasty in patients with severe aortic stenosis and low ejection fraction: Immediate results and intermediate follow up. *Circulation* 1989; 79: 1189-96.
- Bermudez EA. Echocardiographic assessment of aortic stenosis, Chapter 11 in *Contemporary Cardiology: Essential Echocardiography: A practical handbook*. Editor Solomon SD. Humana Press, Totowa, NJ. 1st Edition, 2007, 209-21.
- Bonow RO, Carabello AB, Chatterjee K, de Leon AC et al. AHA/ACC 2008 Guidelines for the management of patients with valvular heart disease. *Circulation* 2008; 118: 523-661.
- Brown DW, Dipilato AE, Chong EC, Lock JE, McElhinney DB. Aortic valve reintervention after balloon aortic valvuloplasty for congenital aortic stenosis: Intermediate and late follow up. *J Am Coll Cardiol* 2010; 56 (21): 1740-9.
- Brown DW, Dipilato AE, Chong EC, Gauvreau K, McElhinney DB, Colan SD, Lock JE. Sudden unexpected death after balloon valvuloplasty for congenital aortic stenosis. *J Am Coll Cardiol*. 2010; 56(23):1939-46.
- Egito EST et al. Transvascular balloon dilation for neonatal critical aortic stenosis: Early and midterm results. *J Am Coll Cardiol* 1997; 29 (2): 442-7.
- Fernandes SM, Khairy P, Sanders SP, Colan SD. Bicuspid aortic valve: morphology and interventions in the young. *J Am Coll Cardiol* 2007; 49 (22):2211-4.
- Fischer DR, Ettetgui JA, Park SC, Siewers RD, Del Nido PJ. Carotid artery approach for balloon dilation of aortic valve stenosis in the neonate: A preliminary report. *J Am Coll Cardiol* 1990; 15:1633-36.
- Fratz S, Gildein P, Balling G, Sebening W, Genz T, Eicken A, Hess J. Aortic valvuloplasty in pediatric patients substantially postpones the need for aortic valve surgery. *Circulation* 2008; 117:1201-6.
- Gupta SD, Das S, Ghose T, Sarkar A, Goswami A, Kundu S. Controlled transient respiratory arrest along with rapid right ventricular pacing for improving balloon stability during balloon valvuloplasty in pediatric patients with congenital aortic stenosis--a retrospective case series analysis. *Ann Card Anaesth* 2010; 13 (3): 236-40.
- Han RK, Gurofsky RC, Lee KJ, Dipchand AI, Williams WG, Smallhorn JF, et al. Outcome and growth potential of left heart structures after neonatal intervention for aortic valve stenosis. *J Am Coll Cardiol* 2007; 50: 2406-14.
- Hausdorf G, Schneider M, Schirmer KR, Schulze-Neick I, Lange PE, antegrade balloon valvuloplasty of aortic stenosis in children. *Am J Cardiol* 1993; 71: 460-3.
- Holzer RJ, Cheatham JP. Shifting the balance between aortic insufficiency and residual gradients after balloon aortic valvuloplasty. *J Am Coll Cardiol* 2010; 56 (21): 1750-1.
- Karago T, Aypar E, Erdog I, Sahin M, Ozer S, Celiker A. Congenital aortic stenosis: A novel technique for ventricular pacing during valvuloplasty. *Catheter Cardiovasc Interv* 2008; 72:527-530.
- Khalid O, Luxenberg DM, Sable C, Benavidex O, Geva T, Hanna B, Abdulla R. Aortic stenosis: The spectrum of practice. *Pediatr Cardiol* 2006; 27 (6): 661-9.

- Kirwan C, Richardson G, Rothman MT. Is there a role for balloon valvuloplasty in patients with stenotic aortic bioprosthetic valves? *Catheter Cardiovasc Interv*. 2004 Oct; 63(2): 251-3.
- Knirsch W, Berger F, Harpes P, Kretschmar O. Balloon valvuloplasty of aortic valve stenosis in childhood: early and medium term results. *Clin Res Cardiol* 2008; 97 (9): 587-93
- Leon MB et al. Transcatheter aortic-valve implantation for aortic stenosis in patients who cannot undergo surgery. *N Eng J Med* 2010; 363: 1597-1607.
- Maeno Y, Agaki T, Hashino K, Ishi M, Sugimura T, Takagi J, Suzuki K, Kato H. Carotid artery approach to balloon aortic valvuloplasty in infants with critical aortic stenosis. *Pediatr Cardiol* 1997; 18:288-91.
- Magee AG. Balloon dilation of severe aortic stenosis in the neonate: Comparison of antegrade and retrograde catheter approaches. *J Am Coll Cardiol* 1997; 30: 1061-6.
- Mahle WT, Sutherland JL, Frias PA. Outcome of isolated bicuspid aortic valve in childhood. *J Pediatr* 2010; 157: 445-9.
- Marshall Ac et al. Aortic Valvuloplasty in the fetus: Technical characteristics of successful balloon dilation. *J Pediatr* 2005; 147: 535-9.
- Maschiettom N, Vidam V, Milanese O. Transapical aortic balloon valvuloplasty in a 890 gram infany: hybrid is better! *Catheter Cariovasc nterv* 2011; 77(1): 112-4.doi 10.1002/ccd.22754.
- Mehta C, Desai T, Shebani S, Stickley J, DE Giovanni J. Rapid ventricular pacing for catheter interventions in congenital aortic stenosis and coarctation: effectiveness, safety, and rate titration for optimal results. *J Interv Cardiol*. 2010; 23 (1):7-13.
- Pass RH, Hellenbrand WE. Catheter Intervention for critical aortic stenosis in the neonate. *Cath Cardiovasc Interv* 2002; 55: 88-92.
- Randolph AD, Cook DJ, Gonzales CA, et al: Ultrasound guidance for placement of central venous catheters: A meta-analysis of the literature. *Crit Care Med* 1996; 24:2053-2058.
- Rao PS, Thapar MK, Wilson AD, Levy JM, Chopra PS. Intermediate term follow-up results of balloon aortic valvuloplasty in infants and children with special reference to causes of restenosis. *Am J Cardiol* 1989; 64:1356–60.
- Singh IM, Shishehbor MH, Christofferson RD, Tuzcu EM, Kapadia SR. Percutaneous treatment of aortic valve stenosis. *Cleve Clin J Med*. 2008 Nov; 75(11):805-12.
- Spargias K, Manginas A, Pavlides G, et al. Transcatheter aortic valve implantation: first Greek experience. *Hellenic J Cardiol* 2008; 49:397-407.
- Waller BF, Mckay C, Van Tassel J, Allen M. Catheter balloon valvuloplasty of stenotic porcine bioprosthetic valves: Part II: Mechanisms, complications and recommendation for clinical use. *Clin Cardiol* 1991; 14 (9): 764-72.
- Webb J. Balloon valvuloplasty for stenotic bioprosthetic aortic valves. *Catheter Cardiovasc Interv* 2011; 77(4):593. doi: 10.1002/ccd.22986.



Aortic Stenosis - Etiology, Pathophysiology and Treatment

Edited by Dr. Masanori Hirota

ISBN 978-953-307-660-7

Hard cover, 254 pages

Publisher InTech

Published online 10, October, 2011

Published in print edition October, 2011

Currently, aortic stenosis (AS) is the most prevalent valvular disease in developed countries. Pathological and molecular mechanisms of AS have been investigated in many aspects. And new therapeutic devices such as transcatheter aortic valve implantation have been developed as a less invasive treatment for high-risk patients. Due to advanced prevalent age of AS, further discovery and technology are required to treat elderly patients for longer life expectancy. This book is an effort to present an up-to-date account of existing knowledge, involving recent development in this field. Various opinion leaders described details of established knowledge or newly recognized advances associated with diagnosis, treatment and mechanism. Thus, this book will enable close intercommunication to another field and collaboration technology for new devices. We hope that it will be an important source, not only for clinicians, but also for general practitioners, contributing to development of better therapeutic adjuncts in the future.

How to reference

In order to correctly reference this scholarly work, feel free to copy and paste the following:

Mehnaz Atiq (2011). Management of Congenital Aortic Stenosis by Catheter Techniques, Aortic Stenosis - Etiology, Pathophysiology and Treatment, Dr. Masanori Hirota (Ed.), ISBN: 978-953-307-660-7, InTech, Available from: <http://www.intechopen.com/books/aortic-stenosis-etiology-pathophysiology-and-treatment/management-of-congenital-aortic-stenosis-by-catheter-techniques>

INTECH
open science | open minds

InTech Europe

University Campus STeP Ri
Slavka Krautzeka 83/A
51000 Rijeka, Croatia
Phone: +385 (51) 770 447
Fax: +385 (51) 686 166
www.intechopen.com

InTech China

Unit 405, Office Block, Hotel Equatorial Shanghai
No.65, Yan An Road (West), Shanghai, 200040, China
中国上海市延安西路65号上海国际贵都大饭店办公楼405单元
Phone: +86-21-62489820
Fax: +86-21-62489821

© 2011 The Author(s). Licensee IntechOpen. This is an open access article distributed under the terms of the [Creative Commons Attribution 3.0 License](#), which permits unrestricted use, distribution, and reproduction in any medium, provided the original work is properly cited.