

The Optic Nerve in Glaucoma

Ivan Marjanovic
*University Eye clinic, Clinical Centre of Serbia
Belgrade*

1. Introduction

To recognize and to assess glaucomatous changes at the optic nerve, it is important to know the characteristics of the normal optic disc. As in the other biological variables, the appearance of the optic disc varies widely among healthy individuals. This fact is complicate the recognition of the pathological changes.

'Optic Disc' is frequently used to describe the portion of the optic nerve clinically visible on examination. This, however, may be slightly inaccurate as 'disc' implies a flat, 2 dimensional structure without depth, when in fact the 'optic nerve head' is very much a 3 dimensional structure which should ideally be viewed stereoscopically.

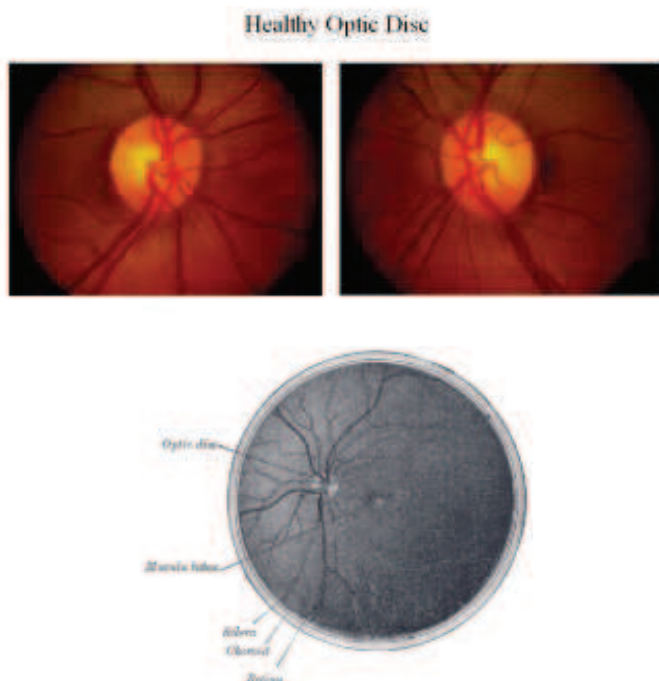


Fig. 1. Posterior part of the left eye. The veins are darker in appearance than the arteries.

The optic nerve itself is a cylindrical structure of approximately 50mm in length, between the retina and the optic chiasm. This can be divided into 4 main parts:

1. Intraocular (the optic nerve head)
2. Intraorbital (between globe and optic canal)
3. Intracanalicular (within the optic canal)
4. Intracranial (between optic canal and chiasm)

The optic nerve head, or disc, is defined as the distal portion of the optic nerve extending from the myelinated portion of nerve that begins just behind the sclera, to the retinal surface. Typically, it is slightly oval with the vertical diameter being about 9% greater than the horizontal. On average the vertical disc diameter is approximately 1500 micrometers, although this may be greater in a myopic eye and less in a hypermetropic eye.

This can also be divided into 4 component parts:

1. Superficial nerve fibre layer - contiguous with the nerve fibre layer of the retina
2. Prelaminar area - consists of nerve fibre bundles and astroglia, which form sheaths around each bundle
3. Lamina (Scleral) portion - contains a modification of sclera called the Lamina Cribrosa. This is made up of sheets of connective and elastic tissue, and contains fenestrations which give passage to the nerve fibre bundles and retinal blood vessels. It also serves to maintain intra-ocular pressure (IOP) against a gradient between the intra-ocular and extra-ocular spaces.
4. Retrolaminar portion - myelinated nerve fibres, circumscribed by leptomeninges of the CNS.¹

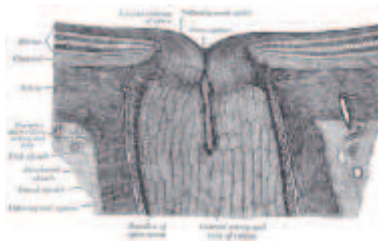


Fig. 2. The terminal portion of the optic nerve and its entrance into the eyeball, in horizontal section.

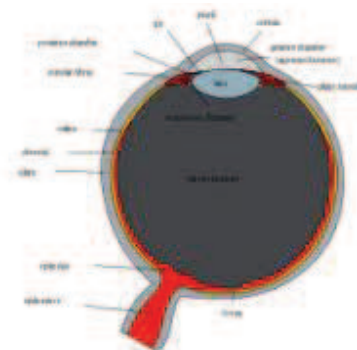


Fig. 3. Schematic diagram of the human eye, with the optical disc, or blind spot, at the bottom.

Optic Disc Basic Examination

When assessing a disc for glaucoma there are many subtle characteristics which should be examined. There are also various ways to examine the optic disc.

For an assessment of the optic disc, there is “the 3 Cs” rule- the cup, colour and contour.

The Contour

The borders of the optic disc should be clear and well defined. If not one becomes concerned that the disc may be swollen such as in the case of papilloedema - disc swelling secondary to raised intracranial pressure. Alternatively, the disc margins may appear blurred due to presence of optic disc drusen.

The Colour

Typically the optic disc looks like an orange-pink donut with a pale centre. The orange-pink appearance represents healthy, well perfused neuro-retinal tissue. There are many pathological reasons why a disc may lose this orange-pink colour and appear pale ie optic atrophy. These include advanced glaucoma, optic neuritis, arteritic or non-arteritic ischaemic optic neuropathy or a compressive lesion.

The causes of an optic neuropathy can be remembered by **NIGHT TIC**:

Neuritis

Ischaemic

Granulomatous

Hereditary

Traumatic

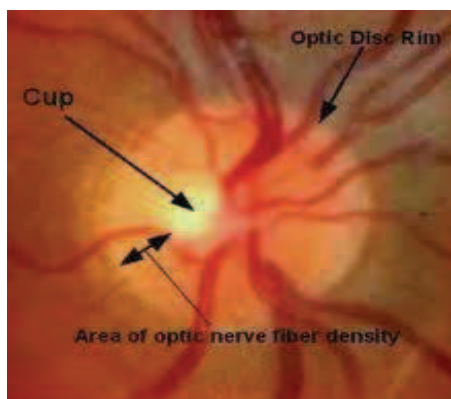
Toxic

Irradiation

Compression

The Cup

The disc has an orange-pink rim with a pale centre. This pale centre is devoid of neuroretinal tissue and is called the cup. The vertical size of this cup can be estimated in relation to the disc as a whole and presented as a “cup to disc ratio”. A cup to disc ratio of 0.3 (i.e. the cup occupies 1/3 of the height of the entire disc) is generally considered normal, and an increased cup to disc ratio may indicate a decrease in the quantity of healthy neuro-retinal tissue and hence, glaucomatous change.



The optic disc (or optic disk optic nerve head, optic papilla or blind spot) is the location where ganglion cell axons exit the eye to form the optic nerve. There are no light sensitive rods or cones to respond to a light stimulus at this point thus it is also known as "the blind spot". A blind spot, also known as a scotoma, is an obscuration of the visual field. A particular blind spot known as the blind spot, or physiological blind spot, is the specific scotoma in the visual field that corresponds to the lack of light-detecting photoreceptor cells on the optic disc. Since there are no cells to detect light on the optic disc, a part of the field of vision is not perceived. The brain fills in with surrounding detail and with information from the other eye, so the blind spot is not normally perceived.²

2. The glaucomatous optic disc and glaucomatous cupping

Considering that the axons of the retinal ganglion cells are lost, changes occur in the structural appearance of the retinal nerve fiber layer and optic nerve head that often precede the development of visual field defects. The most important characteristics of the glaucomatous process are changes that occur in the optic nerve. Therefore, it is important for the ophthalmologist to be familiar with the characteristic signs of glaucoma in the optic disc.

The optic disc cupping has been recognized as an important characteristic of the glaucomatous process since the 19th Century. Quantification of the size of the cup and its relationship to the size of the optic disc, i.e the cup/disc (C/D) ratio, has been widely used in the differentiation of glaucomatous from normal eyes. Vertical elongation of the cup is a characteristic feature of glaucomatous optic neuropathy and the vertical C/D ratio is a simple indicator of neuroretinal rim loss that can be assessed in clinical practice without the use of sophisticated techniques or devices.¹

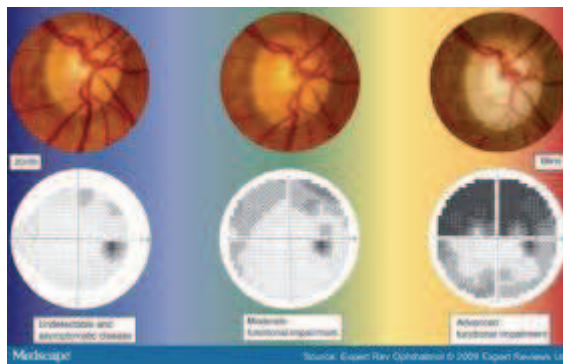


Fig. 4. Glaucomatous disc progression and corresponding VF defects.

The diagnosis of primary open angle glaucoma (POAG) is traditionally based on the triad of increased intraocular pressure (IOP), visual field changes and optic nerve head changes. It is well established that IOP is only a risk factor, albeit, the only risk factor that can be therapeutically manipulated. The fact that upto 50% of POAG patients can present with normal IOP² makes it imperative that the diagnosis of POAG be made independent of IOP increase. Occurance of arcuate nerve fibre bundle visual field defects has been taken as the sine qua non for the diagnosis of POAG. Studies by Quigley et al have shown that upto 40%

of the axons could be lost before a visual field defect develops on Goldmann perimetry and that 20% of axons are lost before a 5 db loss is detected on standard automated perimetry.³ The current research efforts in the early "preperimetric glaucoma" diagnosis are aimed either at psychological tests or alterations in the optic nerve head morphology as assessed by scanning laser ophthalmoscope, digital image processing of optic nerve head images or optical coherence tomography.^{4,5} While these advanced technologies are relevant in glaucoma diagnosis and research, they are not practical in routine clinical practice. With some training it is possible to clinically evaluate the optic nerve head stereoscopically and detect early glaucomatous disc damage.

Features of glaucomatous disc damage

Cup-disc ratio

Cup to disc ratio greater than 0.5:1 is the most often reported sign of glaucomatous disc damage. In a given disc with a cup-disc ratio of more than 0.5:1, it is important to establish if the cup-disc ratio has been large from the onset (large physiological cup) or if it increased over a period of time. Increase in the cup-disc ratio (or enlargement of the cup) over a period of time is diagnostic of glaucomatous disc damage even in the absence of visual field defect. This definitive sign has practical limitation because one time diagnosis is not possible and followup over a period of time is necessary. The physiological variability of the cup-disc ratio occurs because of the large variation in the normal optic nerve head size.¹ Though the normal optic nerve head size is reported to be 1.5 mm in diameter it can vary from 0.96 mm to 2.91 mm.⁶ As a result, the physiological cup can be as small as 0.1:1 or as large as 0.8:1.

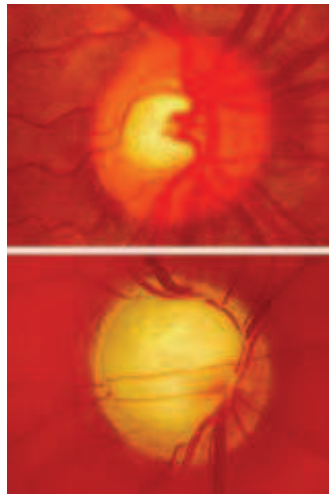


Fig. 5. Glaucomatous optic disc progression.

Neuroretinal Rim Evaluation

Loss of axons in glaucoma is reflected as abnormalities of the neuroretinal rim. Normally the rim is widest in the inferior temporal sector, followed by the superior temporal sector, the nasal and the temporal horizontal sector.⁷ Since localised field defects restricted to one

hemisphere are an early sign of glaucoma, stereoscopic examination of the neuroretinal rim in the superior and inferior poles comparing carefully their thickness, pallor and notching can aid in the diagnosis of very early glaucomatous damage.

Contour Cupping vs Colour Cupping

To assess the width of the neuroretinal rim, the edge of the cup has to be clearly delineated, the usual temptation is to equate the central pallor of the disc with cup, but at least in some glaucomatous discs there is a discrepancy between the extent of central pallor (colour cup) and the site at which the vessels change their contour (contour cup). In the evaluation of glaucomatous disc damage it is the contour cup that is of relevance and not the colour cup.¹

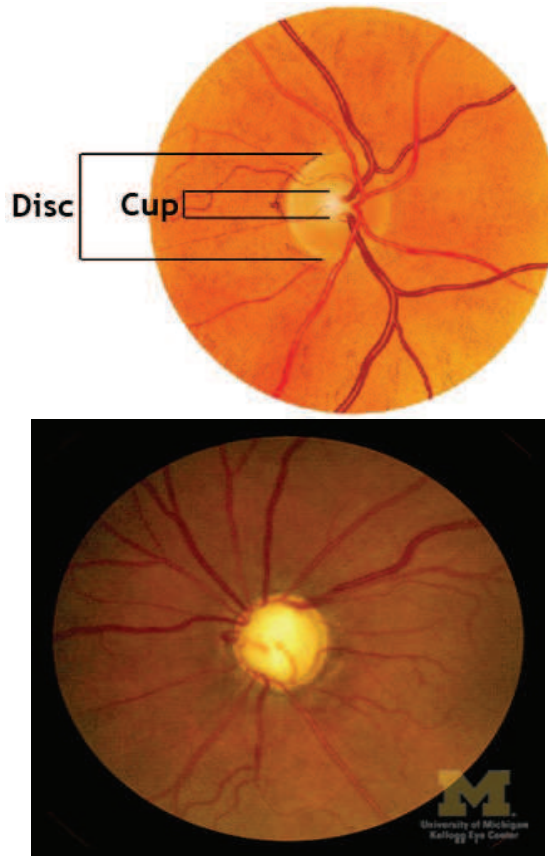


Fig. 6. Right: Cup/Disc ratio; Left: Glaucomatous cupping, change of colour and contour.

Myopic Changes vs Glaucoma

Myopic disc can cause difficulties in glaucomatous disc evaluation either because of the oblique entry resulting in tilted disc or because of the peripapillary changes. A myopic disc the glaucomatous damage is not obvious. The inferior peripapillary atrophy results in a wrong estimation of the extent of the cup as this is mistaken for a part of the disc.

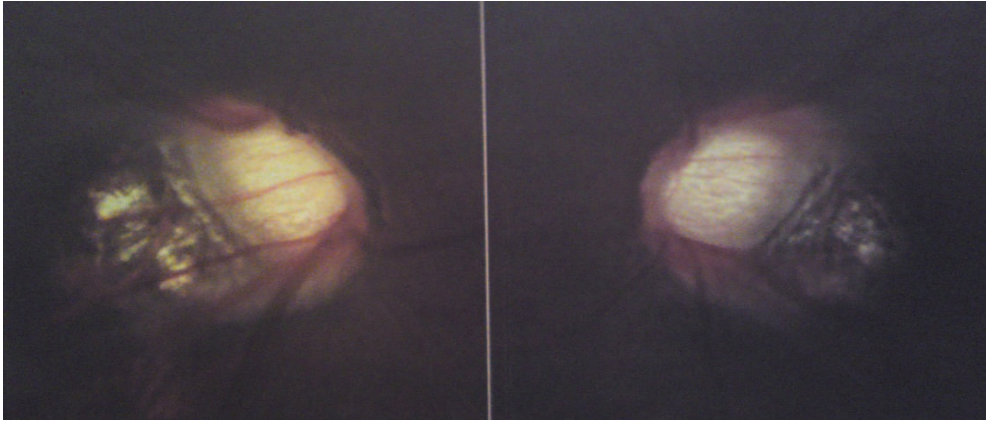


Fig. 7. Degenerative myopic changes of the optic disc.

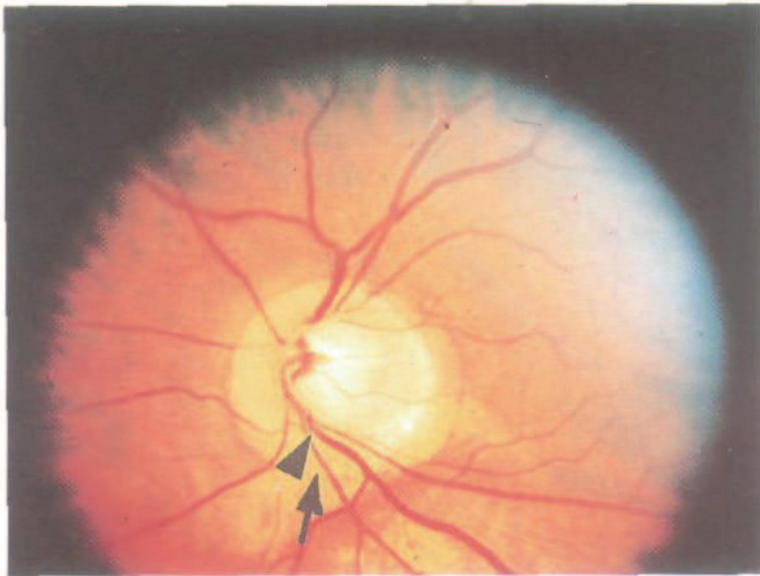

Fig. 8. A myopic disc with peripapillary atrophy (arrow) which can be confused as a part of the disc, resulting in missing of the inferior notch (arrowhead) which shows the edge of the disc where the vessel is changing contour.

Careful evaluation reveals the edge of the disc to be more central with a change in vessel contour at the edge of the disc revealing the inferior notch. The corresponding superior field defect.




Fig. 9. Superior paracentral scotoma corresponding to the disc shown on previous photo.

Peripapillary Changes

Acquired peripapillary atrophy has been described to be secondary to glaucomatous disc damage. Some authorities feel such changes may predispose to glaucomatous damage.

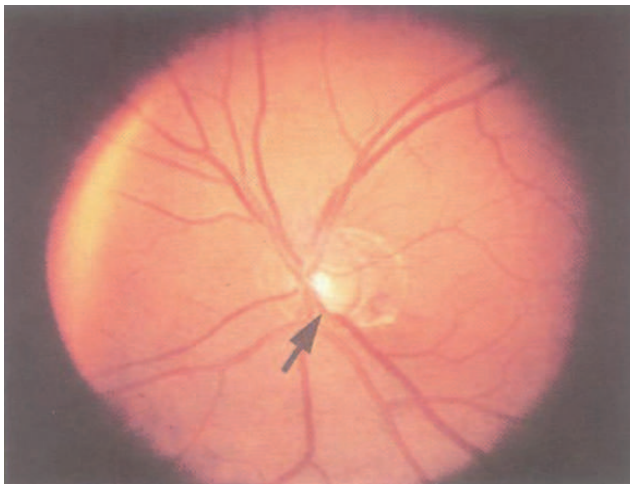


Fig. 10. Glaucomatous cupping in a small disc. Cup size is small but the inferior notch (arrow) indicated by the change in contour of the infero-temporal vessel is typical.

The zone closer to the optic nerve head with retinal pigment epithelial (RPE) and choroidal atrophy with sclera showing through is called zone- β . The more peripheral zone with only RPE atrophy is called zone- α . Since these changes could be seen in myopia also appearance of these changes de-novo or their occurrence in small discs or non myopic eyes is more suggestive of glaucomatous disc damage. A correlation between the location of disc haemorrhage and location of peripapillary atrophy has been reported. If this is so, peripapillary atrophy could be a more reliable and permanent marker for progression than disc hemorrhages.⁸

Nerve Fibre Layer (NFL) Changes

NFL atrophy is associated with a high risk for field loss. Localised defects are the easiest to detect and may be very specific to differentiate early glaucoma from normal eyes. While they occur in 10 to 20% of ocular hypertensive eyes they must be looked for in every glaucoma suspect as the high specificity is clinically useful in identifying patients with impending or established perimetric loss.

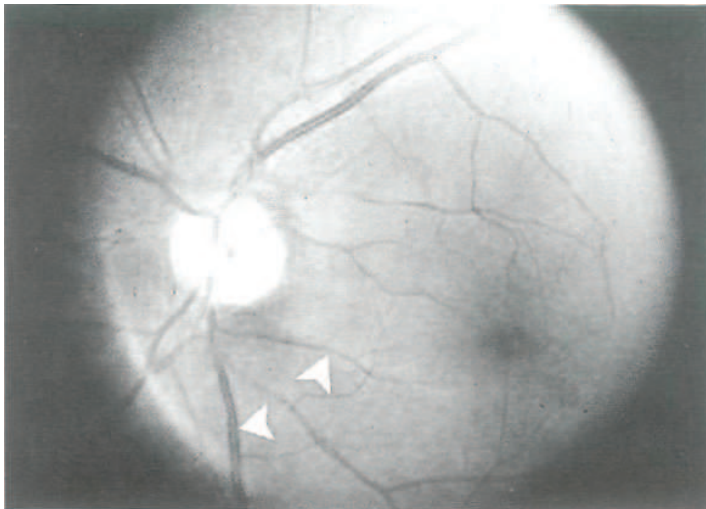


Fig. 11. Red free disc photo showing NFL loss in the inferior arcuate area (arrowheads).

Differential diagnosis

A large physiological cup. If one takes care to assess the neuroretinal rim carefully and measures the optic nerve head size, one can be reasonably sure of a large physiological cup in a large disc.

Congenital colobomas of the optic nerve head are some times easy to diagnose because of the morning glory appearance or other associated colobomas. Optic nerve pit and conus of the disc can some times cause diagnostic difficulties.

Pallor disproportionate to cupping, normal intraocular pressure or unusual history of onset, progression and age should arouse suspicion of a neurological cause for the disc changes and appropriate investigations should be carried out. Photo shows cupping and pallor secondary to pituitary tumour which was mistaken for glaucoma. Also the corresponding temporal hemianopia is shown.

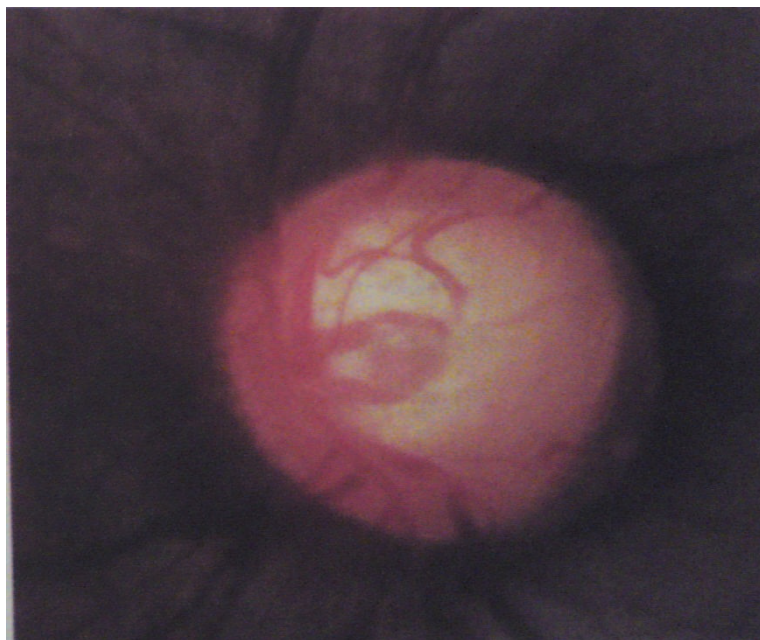


Fig. 12. A Large left optic disc.

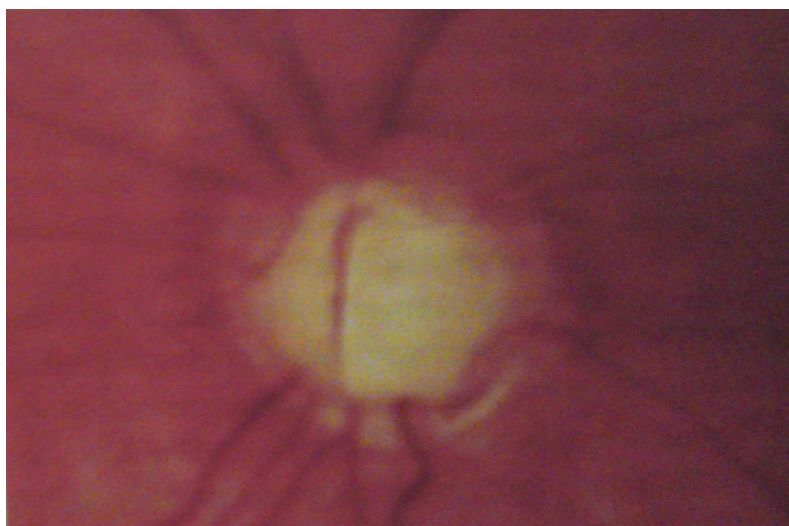


Fig. 13. An Optic disc coloboma.

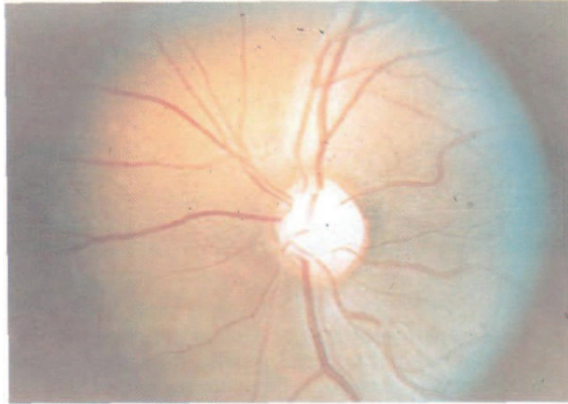


Fig. 14. Cupping of the optic disc and pallor secondary to pituitary tumor.

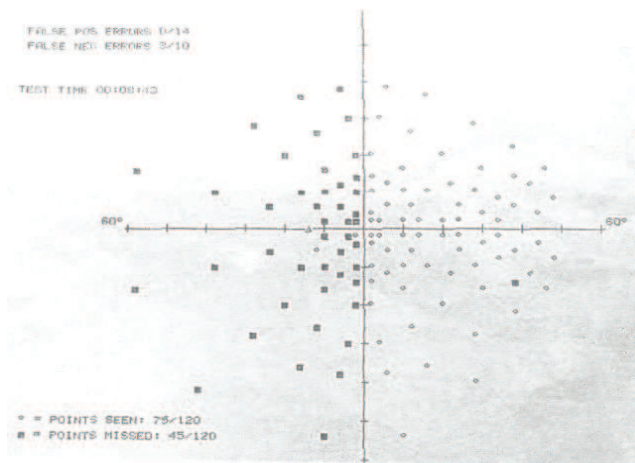


Fig. 15. Temporal hemianopia corresponding to the disc changes shown in previous photo.

Evaluation techniques

The most important points in clinical evaluation of the Optic nerve head are a stereoscopic view with magnification for proper evaluation of the neuroretinal rim changes and an estimation of the optic nerve head size.

Stereoscopic view of the optic nerve head is possible by indirect ophthalmoscopy, central part of gonioscopes, Hruby lens and Volk 90, 78 and 60 D lenses. Indirect ophthalmoscopy is inappropriate for assessment of the optic disc in glaucoma. I prefer the Volk lens systems. While the 78D lens provides a good balance between the field of view and magnification, the 60D lens can make measurement of optic nerve head size simple.

With one of these lenses and slitlamp with redfree light source, it is possible to assess the NFL abnormalities also, though specialised NFL photography systems are more sensitive. Use of direct ophthalmoscope in serious glaucomatous disc evaluation is to be discouraged.

Clinical estimation of optic nerve head size is possible with a Welsch Allen Ophthalmoscope or with Volk 60D lens. The smallest white round spot of the Welsch Allen ophthalmoscope usually illuminates a cone angle of 5° and casts a light of 1.5 mm in diameter on the retina.⁹ This retinal spot size remains constant in phakic eyes with refractive errors between -5.00 D and +4.00 D.

The location of the originating point of the light cone does not significantly affect the retinal spot size as long as it is ± 3 mm from the anterior focal point of the patient's eye. Since 1.5 mm is the usual size of the optic nerve head, this can be used as a yard stick for measuring disc size. Simplistically, in eyes with large physiological cups due to large discs the area illuminated is less than the area occupied by the cup.

Disc diameter can be measured by adjusting the slitlamp beam height to the edges of the disc while viewing the disc with a 60 D lens.⁷ This measurement is roughly equal to the measurement obtained by planimetry of disc photos with Littmann's correction.

A similar measurement of the vertical and horizontal disc diameter can be obtained with other lenses by multiplying the measured value with the appropriate magnification factor: Goldmann contact lens (1.26) and Volk superfield lens (1.5).⁷

It is useful to get habituated to a routine pattern of examination of the disc and look sequentially for findings as follows:

1. Overall impression of the disc
2. Size and shape of the disc
3. Evaluation of the neuroretinal rim keeping in mind the variability of its thickness in various zones mentioned in the text and also look for notch and neuroretinal rim haemorrhage.
4. Peripapillary atrophy
5. Nerve fibre layer abnormalities
6. Vertical cup-disc ratio and asymmetry.

Stereoscopic evaluation of the optic nerve head with emphasis on changes of the neuroretinal rim and not estimation of cup-disc ratio will aid in early diagnosis of glaucoma.

3. Neuroretinal rim loss and retinal nerve fiber layer (RNFL) defects

Examination of the neuroretinal rim is therefore of fundamental importance for the identification of glaucomatous damage to the optic nerve, and its changes are closely related to those occurring in the optic disc cup.¹

The neuroretinal rim is the intrapapillary equivalent of the retinal nerve fiber layer, and qualitative and quantitative changes in this structure reflect the nerve fiber loss that occurs in glaucoma.

Glaucoma is a progressive optic neuropathy that is accompanied by typical changes in the visual field.² Progressive neuroretinal rim thinning, increased excavation, and diffuse and localized loss of the retinal nerve fiber layer are all recognizable features of structural damage in the disease.³ However, their precise relationship with functional deterioration in patients with glaucoma remains largely unclear.⁴⁻⁸

Regulatory agencies throughout the world generally have not approved structural assessment of the optic nerve as a primary end point in clinical trials of glaucoma drugs and devices.⁹ The Food and Drug Administration has suggested the need to demonstrate that structural measures are predictive of clinically relevant functional outcomes in patients with glaucoma before they can reliably be used as end points in clinical trials. Currently

acceptable end points according to the Food and Drug Administration include only intraocular pressure (IOP) and methods for assessment of visual function, such as standard automated perimetry (SAP). However, IOP is only a surrogate for clinically relevant outcomes in glaucoma and its relationship with disease progression is certainly imperfect.¹⁰⁻¹² Also, although assessment of visual function is critically important for all patients with glaucoma, there is evidence to suggest that many patients may show evidence of progressive optic disc damage before functional loss is detected by SAP. Both the Ocular Hypertension Treatment Study¹³ and the European Glaucoma Prevention Study¹⁴ demonstrated that a substantial proportion of patients with ocular hypertension who developed glaucoma showed a change first in optic disc photographs. However, despite being included as end points for glaucoma conversion in these studies, progressive optic disc damage has not yet been demonstrated to translate into worse clinically relevant outcomes for these patients.

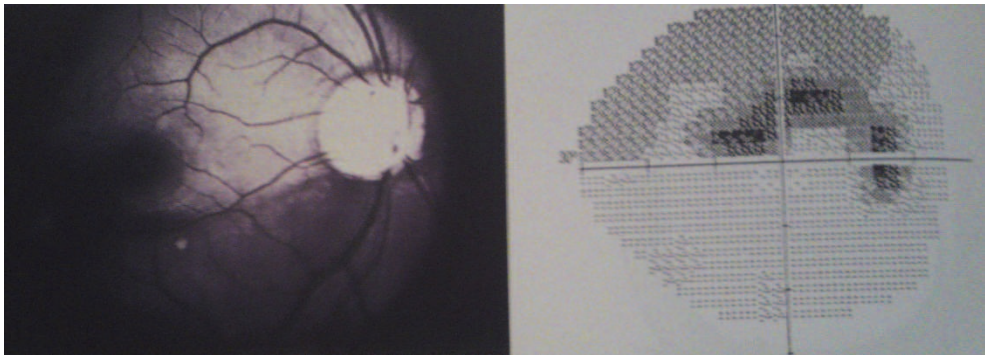


Fig. 16. NFL defect in glaucoma. Left: inferior NFL wedge defect; Right: corresponding superior visual field defect.

Previous investigations have shown that cross-sectional baseline structural measurements, either by expert assessment of stereophotographs or objective imaging methods, are predictive of future development of visual field loss in those with suspected glaucoma, suggesting a potential role for these measurements in early detection of disease.¹⁵⁻²¹ However, measures of predictive ability reported in these studies have generally indicated a low accuracy of cross-sectional structural measures for predicting individual functional outcomes. This is likely due to the wide variation in the appearance of the optic nerve, which makes it difficult to identify early signs of disease at one time. Although detection of progressive optic disc change over time is likely to be a more specific indicator of the presence of structural damage from glaucoma and to correlate better with functional outcomes, the ability of progressive optic disc change in predicting functional outcomes in patients with glaucoma has not been elucidated. The purpose of this study was to evaluate the value of progressive optic disc damage detected by expert assessment of longitudinal stereophotographs in predicting future development of visual field loss in suspected glaucoma.

At times when pre-perimetric diagnosis of glaucoma is the goal, the search for the subtle signs of damage in the NFL is of utmost importance. Retinal nerve fiber layer defects have been shown to be among the earliest signs of glaucomatous damage, and they can indeed precede

visual field defects.^{22,23} They are especially helpful for early glaucoma diagnosis and in eyes with small optic disks. The localized wedge-shaped defect of the NFL is usually seen in association with notching of the neuroretinal rim, vertical enlargement of the cup, or following disk hemorrhages. Nevertheless, in early glaucoma, bundle defects in the NFL may not be associated with neuroretinal rim thinning because the initial damaged NFL is located in the deep retinal layers. Hence, typical wedge-shaped defects can be found in disks with normal appearance.^{24–26} Since NFL defects are not present in normal eyes, they always indicate an abnormality. Although typically occurring in about 20% of all eyes with glaucoma, they are not pathognomonic and can also be found in other ocular diseases, such as optic disk drusen, ischemic retinopathies with cotton-wool spots, toxoplasmotic retinochoroidal scars, long-standing papilledema, or optic neuritis due to multiple sclerosis. The incidence is higher in normal-tension glaucoma than in the other forms, which makes the differential diagnosis somewhat difficult. Some authors have shown that NFL defects may be a common finding in diabetic patients with early diabetic retinopathy, and one of the risk factors is concomitant high blood pressure.²⁷ Retinal nerve fiber layer thickness has been found to decrease with the development of diabetic retinopathy and with impairment of metabolic regulation.²⁸ Cotton-wool spots are frequently a feature of systemic arteriolar disease, most commonly hypertension, diabetes, and collagen vascular disease; they represent infarcts at the nerve fiber layer. Cotton-wool spots have been described to be followed in some patients by localized NFL defects, with and without associated visual field defect.^{29,30}

4. Peripapillary atrophy and optic disc haemorrhage

Glaucoma structural diagnosis has been focused on the optic disc and the peripapillary retinal nerve fiber layer (RNFL). Objective and quantitative assessment of the optic disc and the peripapillary RNFL is useful both in glaucoma diagnosis and monitoring of disease progression.^{1–3}

Evaluation of the glaucoma optic neuropathy may be done by direct or indirect ophthalmoscopy of the optic nerve, optic nerve photography, or computerized imaging technologies. Clinical features of glaucomatous optic neuropathy include atrophy of the retinal nerve fiber layer, focal or diffuse narrowing of the neuroretinal rim, optic disc splinter haemorrhage (DH) and para papillary atrophy (PPA).^{4–6}

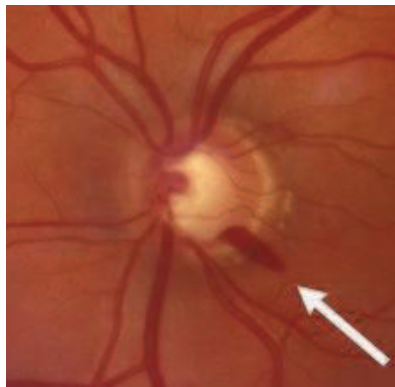

Fig. 17. Optic disc splinter haemorrhage (arrow).

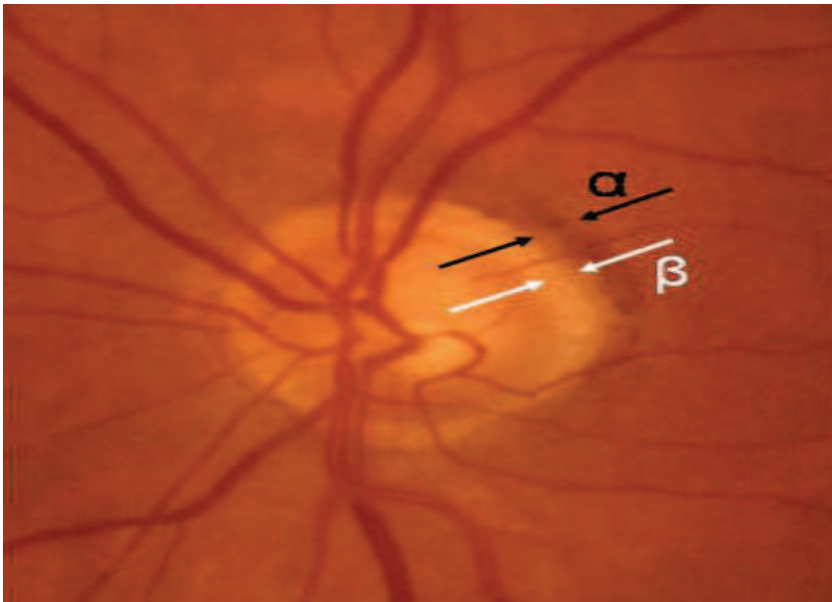
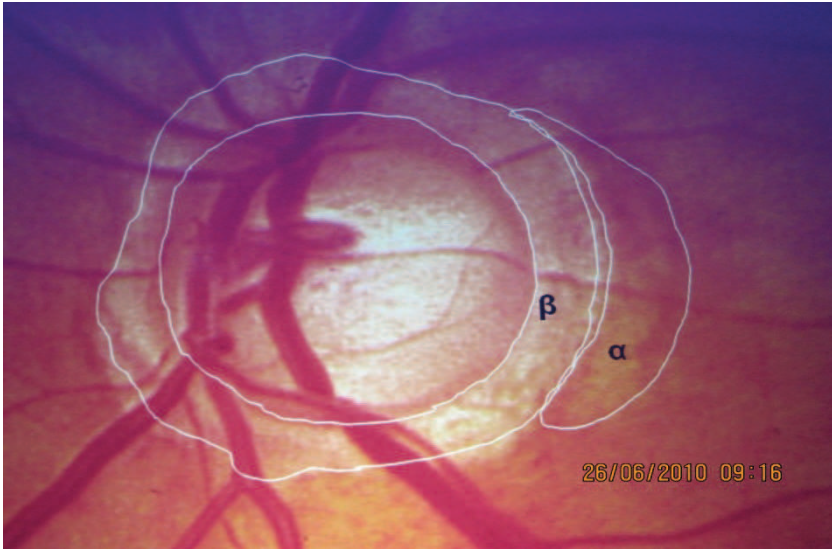


Fig. 18. α and β zones of peripapillary atrophy.

Para papillar atrophy (PPA) is a form of outer retinal atrophy that abuts the optic disc and can be divided into alpha(α) and beta(β) zones.⁷⁻⁹ Because this atrophy most often lies adjacent to but does not completely surround the nerve, the term parapapillary may be preferable to peripapillary atrophy, though they are used interchangeably in the literature.

In β PPA the sclera and large choroidal vessels are visible, as the retinal pigment epithelium (RPE) and most of the photoreceptors are absent.^{7,8} In α PPA, there is an irregular arrangement of RPE cells that can result clinically in both hypo- and hyperpigmentation. The α zone is more peripheral than the β zone when both are present.

However, there are no imaging devices to provide automated assessment of DH or PPA, which at the present time are assessed either by patient examination or by photographic interpretation. Interestingly, several studies addressing the topic have found that PPA and DH tend to occur together in eyes and, additionally, tend to occur in the same regions of the eye, leading to the possibility that PPA may be useful as an indicator of increased likelihood of prior, present, or future disc hemorrhage.¹⁰⁻¹⁵ Because β PPA is present in 15%-20% of normal eyes, its presence is less specific for glaucoma than DH, which occurs only in 0.6% of healthy eyes.^{14,16} Given that DH is transient, lasting weeks to months, and that PPA is stable and progressive, it may be advantageous to rely on PPA parameters for glaucoma diagnosis and monitoring.^{11,15}

α PPA and β PPA have been evaluated in glaucoma using quantitative analysis of optic nerve photographs (morphometry) typically by manually outlining and measuring the area of PPA using a slide projector, imaging processing software, or with confocal scanning laser ophthalmoscopy.^{8-10,17-23} Both α PPA and β PPA are larger and occur more frequently in eyes with glaucoma than in normal eyes, though β PPA is more specific for glaucoma.^{8,9,17,18} Using these morphometric techniques, PPA has been reported to be helpful in differentiating between normal and glaucomatous eyes.^{8,9,17,18,24-27}

While many morphometric investigations of PPA in glaucomatous and normal eyes have reported significant differences between these 2 groups, there is a paucity of information on how clinical evaluation of PPA may guide the clinician in the diagnosis of open-angle glaucoma (OAG). Additionally, it is difficult clinically to estimate quantitative PPA parameters, such as area of PPA, due to its heterogenous shape. Despite this, in a clinical assessment using direct ophthalmoscopy alone, information including the PPA circumferential extent and amount of neuroretinal rim narrowing increased the sensitivity and specificity for detection of glaucomatous visual field loss.⁴

Disc hemorrhages seem to mean different things to different clinicians. Many see them as a sign of glaucomatous progression. Some consider disc hemorrhages by themselves to represent a diagnosis of normal-tension glaucoma. Others view the hemorrhages as an indication of inadequate therapy. The development of these hemorrhages often is followed by amplification in glaucoma therapy, either adding medications or performing surgery.

Hemorrhages occur in patients with glaucoma and ocular hypertension and, rarely, in seemingly normal eyes. True glaucomatous disc hemorrhages typically occur at the superior, superior-temporal, inferior, or inferior-temporal aspect of the disc. They typically are small and reside in the retinal nerve fiber layer (RNFL), and they are contiguous with the neuroretinal rim of the optic disc. They often occur in association with notching of the neuroretinal rim or RNFL defects.

Hemorrhages that do not fit this clinical pattern are more likely caused by vascular occlusion, posterior vitreous detachment, other optic neuropathy, or blood dyscrasia such as anemia. Disc hemorrhages typically recur and in the same location on the disc. The etiology

and pathogenesis of these hemorrhages remains unknown. It has been theorized that they are the result of a microvascular occlusion of the disc blood supply.

Several well-known glaucoma studies have looked at the implication of optic disc hemorrhages and virtually all indicate that the presence of one in a patient with glaucoma is a risk factor for progression. These findings themselves are not without controversy, however. For example, in the Ocular Hypertension Treatment Study (OHTS), patients with ocular hypertension who developed a disc hemorrhage during the course of the study had a nearly four-fold increased risk of progression to glaucoma compared with those who did not. The increased risk of conversion to glaucoma was about 87% of eyes that demonstrated a disc hemorrhage. That hemorrhages easily can be missed on clinical examination.

The Collaborative Normal Tension Glaucoma Study (CNTGS) found disc hemorrhages in normal-tension glaucoma to indicate the greatest risk of progression of the disease. It also discovered that reduction of IOP did not affect the outcome. Lowering IOP in patients with normal-tension glaucoma manifesting a hemorrhage did nothing to halt disease progression.

In the Early Manifest Glaucoma Treatment (EMGT) Study, disc hemorrhages, likewise, were seen as a major risk factor for disease progression. As with the CNTGS, however, IOP reduction was seen to have little benefit in altering the course of disease in eyes demonstrating disc hemorrhages. Although the hemorrhages were predictive of progression, IOP-reducing treatment was unrelated to the presence or frequency of hemorrhages. These were equally common in both the treated and untreated groups of patients in this study.

The EMGT seems to suggest that disc hemorrhages cannot be considered an indication of insufficient IOP-lowering treatment and that glaucoma progression in eyes with disc hemorrhages cannot be totally halted by IOP reduction.

It should be noted that none of the major glaucoma studies considered the development of a hemorrhage to be a clinical study endpoint for glaucoma progression or conversion to glaucoma from ocular hypertension.

Disc hemorrhages themselves are not progression but are a significant risk factor for progression

5. Progression of the glaucomatous optic disc damage

Insight of progressive glaucomatous damage to the optic disc is one of the most important aspects of glaucoma management, yet it remains largely subjective and imprecise. Progressive change in the appearance of the optic disc or retinal nerve fiber layer (RNFL) often precedes the development of visual field defects in glaucoma. Because visual field defects on standard automated perimetry may only be detected after a substantial number of nerve fibers has been lost, assessment of the optic disc and RNFL is essential for monitoring the initial stages of the disease. Before the development of visual field defects, structural changes in the optic disc or RNFL may be the only evidence for the ophthalmologist that the glaucoma is progressing and treatment needs to be intensified. Even in the presence of visual field defects, progression of optic disc damage may occur without any detectable evidence of functional deterioration.

Disc Damage Likelihood Score (DDLS)

Glaucoma is defined as a process wherein there is progressive loss of retinal ganglion cells manifest clinically as loss of neuroretinal rim tissue from the optic nerve. In order to detect

this, a clinician must have a method to identify these changes and distinguish them from normal. There is also a need for a system to document any change in optic nerve appearance with time in order to determine progression. The concept of cup:disc ratio(CDR) was developed by Armaly in 1967¹ as a standardised way of documenting disc appearance in order to address these issues. Whilst an enlarging cup:disc ratio is undoubtedly linked with glaucomatous loss, this system does not take into consideration the influence of optic disc size nor yet the focal changes seen in glaucomatous optic neuropathy. It is also well recognised that there is significant intra and inter observer error with this method.

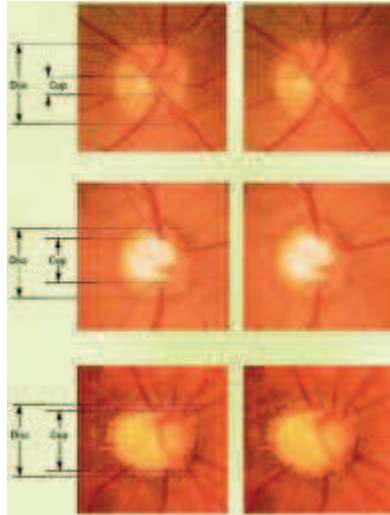


Fig. 19. Cup/Disc ratio progression in glaucoma.

The disc damage likelihood scale (DDLS) was devised by Spaeth et al in 2002 to incorporate the effect of disc size and focal rim width into a clinical grading scale.² It is highly reproducible and does correlate strongly with the degree of field loss.³ The system categorises the disc as small (<1.5mm), medium(1.5-2.0mm) or large(>2.0mm). This ensures that the disc size is measured thereby reducing misclassification bias based on disc size. Disc size can be measured using a fundus lens at the slit-lamp. A slit beam is directed onto the disc and the graticule at the top used to reduce the height of the beam until it corresponds in size to the disc. The lens used will determine the correction factor. A 66D gives the exact measure from the graticule.⁴

Correction factors for the other lenses are -

Volk

60D-0.88

78D-1.2

90D-1.33

Nikon

60D-1.03

90D-1.63

The next stage is to measure the width of the thinnest part of the rim. This forces the examiner to evaluate the rim throughout its entire circumference in order to identify the area of greatest thinning. The measurement is expressed in rim:disc. Where there is no rim present at the thinnest point the value is 0. The circumferential extent of rim absence is then measured in degrees. Care must be taken when evaluating a sloping rim because a sloping rim is not an absent rim.

Whilst simply documenting a CDR is quick, in the main it is of little use in either the diagnosis or longitudinal monitoring of glaucoma. The DDLS not only forces the clinician to determine the size of the disc, which by itself already is alerting the observer to which discs are big and which are small but it also formalises the evaluation of the neuroretinal rim. Because each grade is assigned a numerical value the system can then be used in research settings to determine severity or degree of progression.

Optic nerve heads come in many shapes and forms. No method of classification will fit all of these different patterns and forms. The DDLS cannot be used to evaluate certain types of discs, such as those that are congenitally anomalous. Myopic discs may be difficult to grade. Probably one of the first mental steps one takes when considering the nature of the optic disc is, "Is this an anomalous disc? Is there any system that can be used to stage or characterize this disc?" There will be those situations which the answer to that question is, "No." It is unwise in such situations to use any of the standard systems, such as cup/disc ratio, HRT evaluations, OCT evaluations, or the DDLS.^{4,5}

Another problem with the DDLS is that a disc may show progressive damage by having a continuing generalized narrowing of the neuroretinal rim, but not have an increase in the circumferential extent of rim absence. In such a situation the disc would unquestionably have become worse, but the DDLS score will not change. Fortunately this seems to be a rare occurrence.⁵

It takes some effort to learn it and initially a copy of the table should always be to hand. However, given practice and used accordingly the DDLS is an excellent tool for classifying and monitoring the optic nerve in glaucoma.

6. References

- [1] Ahn JK, Kang JH, Park KH. Correlation between a disc hemorrhage and peripapillary atrophy in glaucoma patients with a unilateral disc hemorrhage. *J Glaucoma*. 2004;13(1):9-14.
- [2] Alencar LM, Bowd C, Weinreb RN, Zangwill LM, Sample PA, Medeiros FA. Comparison of HRT-3 glaucoma probability score and subjective stereophotograph assessment for prediction of progression in glaucoma. *Invest Ophthalmol Vis Sci*. 2008;49(5):1898-1906.
- [3] Anderson DR., Normal Tension Glaucoma Study Collaborative normal tension glaucoma study. *Curr Opin Ophthalmol*. 2003;14(2):86-90.
- [4] Armaly M. Genetic determination of cup/disc ratio of the optic nerve. *Arch Ophthalmol* 1967;78:35-43
- [5] Bayer A, Harasymowycz P, Henderer JD, et al. Validity of a new disc grading scale for estimating glaucomatous damage: correlation with visual field damage. *Am J Ophthalmol* 2002;133:758-763

- [6] Bochmann F, Howell JP, Meier C, et al. The disc damage likelihood scale (DDLS): interobserver agreement of a new grading system to assess glaucomatous optic disc damage. *Klin Monatsbl Augenheilkd* 2009;226:280-3.
- [7] Budenz DL, Anderson DR, Feuer WJ, et al. Detection and prognostic significance of optic disc hemorrhages during the Ocular Hypertension Treatment Study. *Ophthalmology*. 2006;113(12):2137-2143.
- [8] Chaum E, Drewry RD, Ware GT, Charles S. Nerve fiber bundle visual field defect resulting from a giant peripapillary cotton-wool spot. *J Neuroophthalmol*. 2001;21:276-7.
- [9] Chihara E, Honda Y. Topographic changes in the optic disc in eyes with cotton-wool spots and primary open-angle glaucoma. *Graefes Arch Clin Exp Ophthalmol*. 1991;229:13-8
- [10] Chihara E, Matsuoka T, Ogura Y and Matsumura M, Retinal nerve fiber layer defect as an early manifestation of diabetic retinopathy, *Ophthalmology*. 1993;100:1147-51
- [11] Danesh-Meyer H, et al, Regional Correlation of Structure and Function in Glaucoma, Using the Disc Damage Likelihood Scale, Heidelberg Retina Tomograph, and Visual Fields, *Ophthalmology* 2006;113:603-611 © by the American Academy of Ophthalmology.
- [12] Fingeret M, Medeiros FA, Susanna R, Jr, Weinreb RN. Five rules to evaluate the optic disc and retinal nerve fibre layer for glaucoma. *Optometry*. 2005 Nov;76(11):661-8.
- [13] Gardiner SK, Johnson CA, Cioffi GA. Evaluation of the structure-function relationship in glaucoma. *Invest Ophthalmol Vis Sci*. 2005;46(10):3712-3717.
- [14] Garway-Heath DF, Wollstein G, Hitchings RA. Aging changes of the optic nerve head in relation to open angle glaucoma. *Br J Ophthalmol*, 1998; 81:840-5.
- [15] Geijssen HC, Greve EL. Disc haemorrhages and peripapillary atrophy. *Invest Ophthalmol Vis Sci* 32:1017, 1991.
- [16] Gonzalez-Hernandez M, Pablo LE, Armas-Domingue K, Rodriguez de la Vega R, Ferreras A, Gonzalez de la Rosa M. Structure-function relationship depends on glaucoma severity. *Br J Ophthalmol*. 2009
- [17] Gordon MO, Beiser JA, Brandt JD, et al. The Ocular Hypertension Treatment Study: baseline factors that predict the onset of primary open-angle glaucoma. *Arch Ophthalmol*. 2002;120(6):714-720. discussion 829-830.
- [18] Gordon MO, Torri V, Miglior S, et al. Ocular Hypertension Treatment Study Group. European Glaucoma Prevention Study Group Validated prediction model for the development of primary open-angle glaucoma in individuals with ocular hypertension. *Ophthalmology*. 2007;114(1):10-19.
- [19] Gross PG, Drance SM. Comparison of a simple ophthalmoscopic and planimetric measurement of glaucomatous neuroretinal rim areas. *J Glaucoma* 4:314-316, 1995.
- [20] Harper R, Reeves B. The sensitivity and specificity of direct ophthalmoscopic optic disc assessment in screening for glaucoma: a multivariate analysis. *Graefes Arch Clin Exp Ophthalmol*. 2000;238(12):949-955.
- [21] Harwerth RS, Carter-Dawson L, Smith EL, III, Crawford ML. Scaling the structure-function relationship for clinical perimetry. *Acta Ophthalmol Scand*. 2005;83(4):448-455.

- [22] Hayakawa T, Sugiyama K, Tomita G, et al. Correlation of the peripapillary atrophy area with optic disc cupping and disc hemorrhage. *J Glaucoma*. 1998;7(5):306-311.
- [23] Henderer JD, Liu C, Kesen M, et al. Reliability of the disc damage likelihood scale. *Am J Ophthalmol* 2003;135:44-8
- [24] Johnson CA, Cioffi GA, Liebmann JR, Sample PA, Zangwill LM, Weinreb RN. The relationship between structural and functional alterations in glaucoma: a review. *Semin Ophthalmol*. 2000;15(4):221-233.
- [25] Jonas JB, Budde WM, Panda-Jonas S. Ophthalmoscopic evaluation of the parapapillary region of the optic nerve head. *Klin Oczna*. 2004; 106 Suppl 1-2:279-289.
- [26] Jonas JB, Naumann GO. Parapapillary chorioretinal atrophy in normal and glaucoma eyes. II. Correlations. *Invest Ophthalmol Vis Sci*.1989;30(5):919-926.
- [27] Jonas JB, Nguyen XN, Gusek GC, Naumann GO. Parapapillary chorioretinal atrophy in normal and glaucoma eyes. I. Morphometric data. *Invest Ophthalmol Vis Sci*. 1989;30 (5):908-918.
- [28] Jonas JB, Martus P, Budde WM. Inter-eye differences in chronic open-angle glaucoma patients with unilateral disc hemorrhages. *Ophthalmology*.2002;109(11):2078-2083.
- [29] Jonas JB. Predictive factors of the optic nerve head for development or progression of glaucomatous visual field loss. *Invest Ophthalmol Vis Sci*. 2004;45(8):2613-2618.
- [30] Jonas JB, Martus P, Budde WM, Jünemann A, Hayler J. Small neuroretinal rim and large parapapillary atrophy as predictive factors for progression of glaucomatous optic neuropathy. *Ophthalmology*. 2002;109(8):1561-1567.
- [31] Jonas JB, Bergua A, Schmitz-Valckenberg P, Papastathopoulos KI, Budde WM. Ranking of optic disc variables for detection of glaucomatous optic nerve damage. *Invest Ophthalmol Vis Sci*. 2000;41(7):1764-1773.
- [32] Jonas JB. Clinical implications of peripapillary atrophy in glaucoma. *Curr Opin Ophthalmol*. 2005;16(2):84-88.
- [33] Jonas JB, Budde WM, Panda-Jonas S. Ophthalmoscopic evaluation of the optic nerve head. *Surv Ophthalmol*. 1999;43(4):293-320.
- [34] Jonas JB, Dichtl A. Evaluation of the retinal nerve fiber layer. *Surv Ophthalmol*. 1996;40:369-78.
- [35] Jonas JB, Fernandez MC, Sturmer J. Pattern of glaucomatous neuroretinal rim loss. *Ophthalmology*. 1993;100:63-8.
- [36] Jonas JB, Schiro D. Localised wedge shaped defects of the retinal nerve fibre layer in glaucoma. *Br J Ophthalmol*. 1994;78:285-90.
- [37] Jonas JB, Gusek GC, Naumann GOH. Optic disc, cup and neuroretinal rim size, configuration and correlations in normal eyes. *Invest Ophthalmol Vis Sci* 29:1151-1158, 1988.
- [38] Jonas JB, Dichtl A. Advances in assessment of the optic disc changes in early glaucoma. *Cur Opi Ophthalmol* 6:61-66, 1995.
- [39] Jonas JB, Budde WM, Panda-Jonas S. Ophthalmoscopic evaluation of the optic nerve head. *Surv Ophthalmol*. 1999;43(4):293-320.
- [40] Kanamori A, Nagai-Kusuhara A, Escaño MF, et al. Comparison of confocal scanning laser ophthalmoscopy, scanning laser polarimetry and optical coherence tomography to

- discriminate ocular hypertension and glaucoma at an early stage. *Graefes Arch Clin Exp Ophthalmol* 2006;244:58–68.
- [41] Kass MA, Heuer DK, Higginbotham EJ, et al. The Ocular Hypertension Treatment Study: a randomized trial determines that topical ocular hypotensive medication delays or prevents the onset of primary open-angle glaucoma. *Arch Ophthalmol*. 2002;120(6):701–713. discussion 829–830.
- [42] Kwon YH, Kim YI, Pereira MLM, et al. Rate of optic disc cup progression in treated primary open-angle glaucoma. *J Glaucoma*. 2003;12(5):409–416.
- [43] Kubota T, Jonas JB, Naumann GO. Direct clinico-histological correlation of parapapillary chorioretinal atrophy. *Br J Ophthalmol*.1993;77(2):103–106.
- [44] Lalezary M, Medeiros FA, Weinreb RN, et al. Baseline optical coherence tomography predicts the development of glaucomatous change in glaucoma suspects. *Am J Ophthalmol*. 2006;142(4):576–582.
- [45] Law SK, Choe R, Caprioli J. Optic disk characteristics before the occurrence of disk hemorrhage in glaucoma patients. *Am J Ophthalmol*. 2001;132(3):411–413.
- [46] Leibowitz HM, Kruger DE, Maunder LR, et al. The Framingham Eye Study monograph: An ophthalmological and epidemiological study of cataract, glaucoma, diabetic retinopathy, macular degeneration and visual acuity in general population. *Surv Ophthalmol* 24 (suppl):335–610, 1980.
- [47] Lester M, Garway-Heath D, Lemij H. Optic Nerve Head and Retinal Nerve Fibre Analysis. European Glaucoma Society. 2005.
- [48] Leung CK, Chan WM, Chong KK, et al. Comparative study of retinal nerve fiber layer measurement by Stratus OCT and GDx VCC. I: correlation analysis in glaucoma. *Invest Ophthalmol Vis Sci* 2005;46:3214–3220.
- [49] Medeiros FA, Alencar LM, Zangwill LM, et al. The relationship between intraocular pressure and progressive retinal nerve fiber layer loss in glaucoma. *Ophthalmology*. 2009;116(6):1125.e1–3–1133.e1–3.
- [50] Medeiros FA, Zangwill LM, Bowd C, Weinreb RN. Comparison of the GDx VCC scanning laser polarimeter, HRT II confocal scanning laser ophthalmoscope, and stratus OCT optical coherence tomograph for the detection of glaucoma. *Arch Ophthalmol* 2004;122:827–837.
- [51] Medeiros FA, Weinreb RN, Sample PA, et al. Validation of a predictive model to estimate the risk of conversion from ocular hypertension to glaucoma. *Arch Ophthalmol*. 2005;123(10):1351–1360.
- [52] Medeiros FA, Zangwill LM, Bowd C, Vasile C, Sample PA, Weinreb RN. Agreement between stereophotographic and confocal scanning laser ophthalmoscopy measurements of cup/disc ratio: effect on a predictive model for glaucoma development. *J Glaucoma*. 2007;16(2):209–214.
- [53] Miglior S, Zeyen T, Pfeiffer N, Cunha-Vaz J, Torri V, Adamsons I, European Glaucoma Prevention Study (EGPS) Group Results of the European Glaucoma Prevention Study. *Ophthalmology*. 2005;112(3):366–375.
- [54] Mohammadi K, Bowd C, Weinreb RN, Medeiros FA, Sample PA, Zangwill LM. Retinal nerve fiber layer thickness measurements with scanning laser polarimetry predict glaucomatous visual field loss. *Am J Ophthalmol*. 2004;138(4):592–601.

- [55] Ozdek S, Lonneville YH, Onol M, Yetkin I, Hasanreisoglu B. Assessment of nerve fiber layer in diabetic patients with scanning laser polarimetry. *Eye*. 2002;16:761-5.
- [56] Park KH, Park SJ, Lee YJ, Kim JY, Caprioli J. Ability of peripapillary atrophy parameters to differentiate normal-tension glaucoma from glaucomalike disk. *J Glaucoma*. 2001;10(2):95-101. Armaly M. Genetic determination of cup/disc ratio of the optic nerve. *Arch Ophthalmol* 1967;78:35-43.
- [57] Quigley HA, Dunkelbarger GR, Green WR. Retinal ganglion cell atrophy correlated with automated perimetry in human eyes with glaucoma. *Am J Ophthalmol* 107: 453-464, 1989.
- [58] Racette L, Medeiros FA, Bowd C, Zangwill LM, Weinreb RN, Sample PA. The impact of the perimetric measurement scale, sample composition, and statistical method on the structure-function relationship in glaucoma. *J Glaucoma*. 2007;16(8):676-684.
- [59] Radcliffe NM, Liebmann JM, Rozenbaum I, et al. Anatomic relationships between disc hemorrhage and parapapillary atrophy. *Am J Ophthalmol*. 2008;146(5):735-740.
- [60] Rockwood EJ, Anderson DR. Acquired peripapillary changes and progression in glaucoma. *Graefes Arch Clin Exp Ophthalmol*. 1988;226(6):510-515.
- [61] Schuman JS, Hee MR, Puliafito CA, et al. Quantification of nerve fibre layer thickness in normal and glaucomatous eyes using optical coherence tomography. *Arch Ophthalmol* 113:586-596, 1995.
- [62] Sommer A, Quigley HA, Robin AL, Miller NR, Katz J, Arkel S. Evaluation of nerve fiber layer assessment. *Arch Ophthalmol*. 1984;102:1766-71.
- [63] Sommer A, Katz J, Quigley HA, Miller NR, Robin AL, Richter RC, et al. Clinically detectable nerve fiber atrophy precedes the onset of glaucomatous field loss. *Arch Ophthalmol*. 1991;109:77-83.
- [64] Sugiyama K, Tomita G, Kawase K, et al. Disc hemorrhage and peripapillary atrophy in apparently healthy subjects. *Acta Ophthalmol Scand*. 1999;77(2):139-142.
- [65] Theodossiades J, Murdoch I. What optic disc parameters are most accurately assessed using the direct ophthalmoscope? *Eye (Lond)*. 2001;15(Pt 3):283-287.
- [66] Uchida H. Increasing peripapillary atrophy is associated with progressive glaucoma. *Ophthalmology*. 1998;105(8):1541-1545.
- [67] Uhm KB, Lee DY, Kim JT, Hong C. Peripapillary atrophy in normal and primary open-angle glaucoma. *Korean J Ophthalmol*. 1998;12(1): 37-50.
- [68] Weinreb RN, Khaw PT. Primary open-angle glaucoma. *Lancet*. 2004;363(9422):1711-1720.
- [69] Weinreb RN, Kaufman PL. The glaucoma research community and FDA look to the future: a report from the NEI/FDA CDER Glaucoma Clinical Trial Design and Endpoints Symposium. *Invest Ophthalmol Vis Sci*. 2009;50(4):1497-1505.
- [70] Weinreb RN. Diagnosing and monitoring glaucoma with confocal scanning laser ophthalmoscopy. *J Glaucoma* 4:225-227, 1995.
- [71] Wilensky JT, Kolker AE. Peripapillary changes in glaucoma. *Am J Ophthalmol*. 1976;81(3):341-345.
- [72] Xu L, Wang Y, Yang H, Jonas JB. Differences in parapapillary atrophy between glaucomatous and normal eyes: the Beijing Eye Study. *Am J Ophthalmol*. 2007;144(4):541-546.

- [73] Zangwill LM, Weinreb RN, Beiser JA, et al. Baseline topographic optic disc measurements are associated with the development of primary open-angle glaucoma: the Confocal Scanning Laser Ophthalmoscopy Ancillary Study to the Ocular Hypertension Treatment Study. *Arch Ophthalmol.* 2005;123(9):1188-1197.



The Mystery of Glaucoma

Edited by Dr. Tomas Kubena

ISBN 978-953-307-567-9

Hard cover, 352 pages

Publisher InTech

Published online 06, September, 2011

Published in print edition September, 2011

Since long ago scientists have been trying hard to show up the core of glaucoma. To its understanding we needed to penetrate gradually to its molecular level. The newest pieces of knowledge about the molecular biology of glaucoma are presented in the first section. The second section deals with the clinical problems of glaucoma. Ophthalmologists and other medical staff may find here more important understandings for doing their work. What would our investigation be for, if not owing to the people's benefit? The third section is full of new perspectives on glaucoma. After all, everybody believes and relies – more or less – on bits of hopes of a better future. Just let us engage in the mystery of glaucoma, to learn how to cure it even to prevent suffering from it. Each information in this book is an item of great importance as a precious stone behind which genuine, through and honest piece of work should be observed.

How to reference

In order to correctly reference this scholarly work, feel free to copy and paste the following:

Ivan Marjanovic (2011). The Optic Nerve in Glaucoma, The Mystery of Glaucoma, Dr. Tomas Kubena (Ed.), ISBN: 978-953-307-567-9, InTech, Available from: <http://www.intechopen.com/books/the-mystery-of-glaucoma/the-optic-nerve-in-glaucoma>

INTECH
open science | open minds

InTech Europe

University Campus STeP Ri
Slavka Krautzeka 83/A
51000 Rijeka, Croatia
Phone: +385 (51) 770 447
Fax: +385 (51) 686 166
www.intechopen.com

InTech China

Unit 405, Office Block, Hotel Equatorial Shanghai
No.65, Yan An Road (West), Shanghai, 200040, China
中国上海市延安西路65号上海国际贵都大饭店办公楼405单元
Phone: +86-21-62489820
Fax: +86-21-62489821

© 2011 The Author(s). Licensee IntechOpen. This chapter is distributed under the terms of the [Creative Commons Attribution-NonCommercial-ShareAlike-3.0 License](#), which permits use, distribution and reproduction for non-commercial purposes, provided the original is properly cited and derivative works building on this content are distributed under the same license.