

Chemotherapy of Medulloblastoma in Children

Dezsó Schuler, Péter Hauser and Miklós Garami
*2nd Department of Paediatrics, Faculty of Medicine
Semmelweis University, Budapest
Hungary*

1. Introduction

Medulloblastoma is one of the most common childhood tumour of the central nervous system. During the past years several researchers dealt with its aetiology, pathology and therapy: surgical-, radio- and chemotherapy. The objective of the present chapter is to review the chemotherapy and we shall present our results and the few clinical data about the targeted therapy.

2. Incidence

Tumours of the central nervous system (CNS) are the second most common childhood malignant diseases after hematological malignancies. The incidence is similar in the different developed countries: in Europe is 29.9/million (1978-1997), in USA 30.7/million (1992-2006). However, the highest incidence is registered in Hungary and the Scandinavian countries. In Hungary the incidence was 37.41/million between 1999 and 2008 and 43.9/million in 2009. The cause of this high incidence in Hungary is unknown (Gupta & Banerjee et al, 2004; Hauser et al., 2003; Kaderali et al., 2009; McNeil et al., 2002; Peris-Bonet et al., 2006; Pizzo & Poplack, 2011). Astrocytomas and medulloblastoma are the most frequent among childhood CNS tumours.

3. Prognostic factors

The prognostic factors are especially important in risk group assignment of brain tumours, because the increased intensity of treatment in high risk cases has much more side effects, than the therapy of the average risk patients.

The most frequently used prognostic factors in the past were: the size of the tumour, the metastases including the tumour cells in the spinal fluid 2 weeks after the surgery (Chang (T₁₋₄; M₀₋₃) (Laurent et al., 1985) and the extent of the surgical intervention (Albright et al., 1996). Later the age and the histology of tumour were also introduced (Ellison, 2010; Giangaspero et al., 2006; Packer et al., 1994). According to several publications residual tumour mass greater than 1.5 cm² after the surgical intervention, the presence of metastases, age younger than 3 years are unfavourable prognostic factors (Albright et al., 1996; Chang et al., 1969; Eberhart et al., 2002; Jenkin et al., 2000; Klesse & Bowers, 2010) The histology of the tumours (desmoplastic/nodular, classic, large cell/anaplastic) is an important, independent prognostic factor too, which was proved by Rutkowski et al. in a study of 260 young children (Rutkowski et al, 2010).

Several biological factors have prognostic value (ERBB2, TP53, PDGFRA, TRKC, CDK6, α and β -catenin). The prognostic role of the aberrantly expressed miRNAs is yet under investigation (Birks et al., 2011). However, the most reliable and independent prognostic factor is microarray gene expression profile (Aihara et al., 2010; Fernandez-T et al., 2004; Pizzo & Poplack, 2010; Rutkowski et al., 2010; Tabori et al., 2010). Four distinct groups were established by Northcott (Northcott et al., 2010): Wnt, Shh, C and D. Wnt and Shh was previously described as the wingless type and sonic hedgehog pathway involvement in the tumor proliferation (Wechsler-Reya & Scott, 2001). In Group C and D a clear molecular pathway involvement could not be clearly identified. The new classification does not follow the classical pathological classification (as classic, desmoplastic, large cell/anaplastic subtypes) and it shows some association with age and metastasis production. The separation of these groups by immunohistochemical analysis only was a great step toward the everyday practice in using this classification as prognostic factor. Group Wnt, Shh, C, D are characterized by the presence of CTNNB1, GLI1, NPR3 and KCNA1 proteins. Wnt and Shh groups seem to need less intensive therapy with outstanding survival and less side effects. Most centres use the following prognostic factors: the young age (<3 years) residual tumour after surgery, the metastases, the histology and in some centres the MYCC/MYCN amplification and the expression of ERBB2 (Pizzo & Poplack, 2010; Rutkowski et al., 2010; Takei et al., 2009).

4. Therapy

The therapy of the malignant tumours is surgical, radio- and chemotherapy, similarly to other childhood tumours. In brain tumours the most important is the surgical therapy and is curative if it is radical ablation and no metastases are found. However, the surgical therapy is hindered by the localisation of the tumour and the difficulty in differentiating the tumour from the normal tissues.

The radiotherapy of medulloblastoma is an important and effective part of therapy. However its use is limited by the irreversible damage caused in children, which is specially serious in young children and infants causing serious neurocognitive damage (Fouladi et al., 2005; Mulhern et al., 2004). Hence it should be avoided in children less than 3 years old in spite of their lower survival rate (Johnston et al., 2009). It is remarkable, that the increased intensity of the chemotherapy enabled the decrease of the craniospinal radiation dose in the average risk cases without the worsening the survival to 23.4Gy along an unchanged focus-dose (55.8Gy) which decreased significantly the late side-effects (Mulhern et al., 1998; Packer et al., 1999, 2006).

4.1 Chemotherapy

It is difficult to compare the different studies to select the optimal treatment protocol due to the non-uniform prognostic factors, the lack of reliable - centrally checked - pathological and molecular diagnostics and the often low number of patients and duration of observation. Hoff (von Hoff et al., 2009) and collaborators published the results of a 10 years long follow up. In their patient-group 12% of relapse occurred five years or more after the end of therapy.

An important obstacle of the chemotherapy is the blood-brain barrier despite the fact that the tumour breaks through the barrier when growing. There were several trials for increasing the possibility of passing the barrier but without any provable result. (Kobrinisky et al., 1999; Prados et al., 2003)

The additive curative effect of chemotherapy after surgery and radiotherapy was proved by a prospective, multicentric, randomised trial in 1990 (Evans et al., 1990; Tait et al., 1990). In the beginning vincristine and the nitrosoureas were applied, which are still used in several protocols for the treatment of medulloblastoma. However, the usefulness of vincristine was recently challenged because vincristine could not be detected in the spinal fluid in measurable concentration after 1,5 mg/m² i.v. bolus injection. Later more and more chemotherapeutic drug combinations have been used. The key agents are the nitrosoureas (lomustine, carmustine), cyclophosphamide, vincristine and the later used cisplatin, carboplatin, and etoposide (Mueller & Chang, 2009). Some protocols apply ifosfamide alternating with cyclophosphamide (Park et al., 2010). The application of methotrexate is limited not only because of its potential side effects, but also because it can be used only before radiotherapy, however, some protocols described rather good results in cases when no irradiation was done (Bleyer, 1981; Chi et al., 2004; Fossati-Bellani et al., 1990; Rutkowski et al., 2005). The alkylating oral drug dibromdulcitol was an excellent substance for the treatment of medulloblastomas because its favourable pharmacokinetic properties in the spinal fluid and its tolerable toxicity (Paál et al., 1994; Schuler et al., 1988, 1992). Later in spite of the good clinical results the drug became unavailable. However, this may be partially substituted by temozolomide, but there is no study yet, which proves its efficacy in medulloblastoma.

The increased arsenal of the chemotherapeutics and the higher intensity of the treatment resulted in improved survival. In cases with favourable prognosis the survival rate is already over 80%, and around 70% in cases with unfavourable prognosis (Gottardo & Gajjar, 2008). However, the toxicity of the treatment increased, too. Therefore, besides improving survival rates reducing early and late toxicity are also important. In the future a less toxic treatment is expected thanks to the development of the targeted molecular therapy based on tumour-biological knowledge.

The most important criteria are:

1. the optimal timing of the chemotherapy
2. the most effective combination of cytostatics
3. sufficient intensity and length of the chemotherapy
4. a tolerable toxicity of the drugs used in the protocol.

Some trials proved that the chemotherapy given before and after the irradiation (sandwich therapy) is disadvantageous; the survival is shorter if the radiotherapy is longer than 50 days (von Hoff et al., 2009; Taylor et al., 2003). Hence the radiotherapy should be given as early after the surgery as it is possible (Bailey et al., 1995; Kortmann et al., 2000). During the radiotherapy several protocols contain the administration of vincristine (von Hoff et al., 2009; Packer et al., 1994, 1999) or in one protocol carboplatin (Jakacki et al., 2007). A preoperative chemotherapy is applied in several paediatric tumours, because it decreases the size of the tumour and facilitate the tumour removal. Hence it would be reasonable to introduce it in huge chemosensitive brain tumours, too (Schuler et al., 1993). The preoperative chemotherapy is feasible and safe in children with high risk medulloblastoma according to some pilot trials (Di Rocco et al., 1995; Grill et al., 2005; Schuler et al., 1993). However, it is not applied in the practice up to now.

In most protocols a combination of vincristine, a nitrosourea (lomustine or camustine) and a platinum compound (cisplatin or carboplatin) is used. In several protocols cyclophosphamide is used instead of nitrosourea because of the good antitumour effect and

shorter bone marrow toxicity of cyclophosphamide, (von Hoff et al., 2009; Mueller & Chang, 2009; Packer et al., 1994) and in some treatment protocols etoposide is also added to this combination (Chi et al., 2004; Dhall et al., 2008; Hauser et al., 2009).

Our protocol for average risk cases begins with three intrathecal triplet (methotrexate, ara-C, prednisolone) and VECp-block (vincristine, cyclophosphamide, etoposide) after the surgery. This is followed by radiotherapy (5th - 11th week). During the radiotherapy the patients get weekly vincristine. 2 weeks after the radiotherapy chemotherapy is continued by vincristine – etoposide – cyclophosphamide/ carboplatin; vincristine – cisplatin – etoposide / BCNU blocks until the 73rd postoperative week.

In high risk cases autologous stem cell transplantation is made after the 40th postoperative week instead of maintenance therapy. If a residual tumour is present it is removed by a “second look” surgery before the transplantation.

In children less than 3 years old the therapy is similar to that in high risk cases, except that no radiotherapy is given and the stem cell transplantation is made as soon as no tumour is seen by MRI. Radiotherapy is given only, if the tumour is still present after the age of three years.

The toxicity of our protocol was tolerable; and there was no therapy related mortality. After 31 months the overall survival was 79% in the average risk patients and 63% in high risk patients.

The best therapeutic results in average risk cases were achieved by the multicentre trial HIT'91 (von Hoff et al., 2009). The overall survival in patients without metastasis was 91% after 10 years. After the removal of tumour a combination of radiotherapy and vincristine was applied, which was followed 6 weeks later by 8 cycles with lomustine (CCNU), vincristine and cisplatin. Packer et al., described a 86% survival after 3 years follow up by a similar regime (Packer et al., 1999). A 93% survival was published by Strother et al. (2001) (Strother et al., 2001) with a more aggressive therapy. They administered 4 cycles of high dose chemotherapy after surgery and radiotherapy (cyclophosphamide, cisplatin, and vincristine) followed by auto-transplantation after each cycle.

The results in high risk cases are more consistent ranging from 34 to 40% across studies (Mueller & Chang, 2009). However, Chi et al. achieved 60% overall survival after 3 years by 5 cycles of vincristine, cisplatin, etoposide, cyclophosphamide and methotrexate given after surgery followed by myeloablative chemotherapy with autologous stem cell rescue (Chi et al., 2004). The results of Gajjar et al. (Gajjar et al., 2006) was similar: 83% event free survival in average risk patients and 70% in high risk cases after 5 years.

Good survival was achieved by the COG99701 study (Jakacki et al., 2007). They administered vincristine and carboplatin during the radiotherapy in patients with metastatic medulloblastoma. 6 weeks later the patients received 6 courses of monthly cyclophosphamide and vincristine. The overall survival after 4 years was 81%.

The increased intensity of therapy resulting a longer survival has more late side effect. Hence the stratification of the tumours according to prognostic factors into average or high risk group is important.

In cases of medulloblastomas of children less than 3 years old radiotherapy should avoid. The most favourable approach after surgery is the myeloablative consolidation chemotherapy after conventional induction therapy which may result 60% overall survival after 3 years (Chi et al., 2004). The result of the intensive chemotherapy depends both on the histologic type and the presence of the residual tumour (Dhall et al., 2008). Those trials

which combine the systematic and intraventricular chemotherapy had better results only among children without metastases and residual tumour (Zeltzer et al., 1999)

The survival of relapsed patients is very poor, especially in patients who had already received radiotherapy and/or auto-transplantation (Butturini et al., 2009). However, there are several trials by intensive chemotherapy and transplantations. (Park et al., 2010). The prolongation of the survival with metronomic therapy was possible in some studies. The metronomic therapy is referred to as low-dose chemotherapy or antiangiogenic chemotherapy (Kieran et al., 2005; Privitera et al., 2009; Sterba et al., 2010). Recently, the combination of the alkylating agent temozolomide with etoposide, which is a topoisomerase II inhibitor was found to be efficacious in prolonging the survival in relapsed medulloblastoma. (Wang CH et al., 2009; Ruggiero A et al., 2010). However, the study of the application of the metronomic therapy for a longer time after the about 6 months long intensive and maintenance therapy in the primordial therapy of high risk cases may be justified too due to the occurrence of late relapses.

The toxicity of the previously described chemotherapeutic modalities depends on their intensity independent from the well known side effects of the radiotherapy. The most common and most serious ones are the acute myelotoxic effect and infections. Some authors describe yet anorexia, nausea, diarrhoea, pain and hypokalemia.

Better comparability of the different therapeutic modalities, improvement of results and the decrease of side effects are expected from the application of the molecular biologic procedures in the stratification and tailored therapy.

4.2 Targeted treatment

There is still not any new, successful, widely accepted therapeutic approach which can substitute or at least complement the standard treatment of medulloblastoma.

Presently, targeted treatment exists only in SHH group among the four groups described by Northcott et al. (2010). In this group tumor proliferation is attributed to the lack of inhibition of SMO protein by loss of function of inhibitory Patched protein (Ptc1) or activating mutation of SMO. SMO inhibitors, as cyclopamin, IPI-926 and the orally available GDC-0449 inhibit hedgehog pathway. The latter went through a Phase 1 study, resulting in a 3-month long transient well-defined remission achieved in one 26-year old patient with proven Ptc1 mutation (Rudin et al., 2009).

Before the establishment of the new subgroups of medulloblastoma, there were also other molecularly targeted treatments. In some cases they were administered to some individual patients. Common feature of these treatments was the transient success, which finally turned into progression. The background of the progression could be the mutation of the targeted receptor or other involved proteins.

One of these targets were somatostatin receptors (SSTR), which were recognized in medulloblastoma cell surface in late nineties of the last century (Fruhwald et al., 2004; Guyotat et al., 2001;). Several attempts were to bind radioactive isotope to its agonist octreotide or its derivatives, providing localized, targeted radiotherapy, which did not show extra survival advantage above conventional irradiation, (Beutler et al., 2005). Somatostatin analogues themselves through SSTR receptors may inhibit cell proliferation. Medulloblastoma express high amount of SSTR based on Octreoscan examination (Muller et al., 1998). Only one patient was described who received only octreotide without radioactive isotope, and was a long term survivor (Glas et al., 2008).

Receptor tyrosine kinases another possible target group. There are several drugs targeting these receptors which are also expressed in a certain part of medulloblastoma (ErbB2, PDGFR). Their increased expression usually results in worse survival and increased metastatic ability (Gilbertson et al., 1995; Gilbertson & Clifford, 2003). The most experience is reported with imatinib, which proved to be effective *in vitro*, however, *in vivo* successful human experiences are still missing (Abouantoun & MacDonald, 2009). This may be partially caused by their hindered penetration through blood brain barrier.

Another possible therapeutic approach is the inhibition of histone deacetylases (HDAC). Acetylation of histones' amino terminal tails by histone acetyltransferase relaxes the chromatin for transcription, and removal of acetyl groups by HDAC repress transcription (Roth et al., 2001; de Ruijter et al., 2003). Histone hypoacetylation and inappropriate transcriptional repression are hypothesized to be a key contributor to the development of human cancers (Marks et al., 2001; Marks & Dokmanovic, 2005). HDAC inhibitors have been shown to cause pleiotropic effect on human cancer cells, including apoptosis, cell cycle arrest and differentiation (Su et al., 2011). Valproic acid (VPA), an anticonvulsive drug is one of the recently discovered HDAC inhibitors. There is one published Phase 1 study in pediatric CNS tumors, 2 patients with medulloblastoma were included (Su et al., 2011). The treatment was well-tolerated, however response was not observed among this little cohort of patients with medulloblastoma.

Another promising area in the treatment of medulloblastoma could be the administration of retinoic acid (RA). RA has been shown to have anticancer efficacy in a variety of cancers. Retinoic acid is commonly used in the treatment of certain childhood cancers. It is a drug with protean effects including cytodifferentiation, apoptosis, and inhibition of angiogenesis to name a few (Miller, 1998). RA has been shown in preclinical models to cause apoptotic cell death in medulloblastoma by promoting BMP-2 transcription (Hallahan et al., 2003). This results in production of soluble BMP-2 protein that induces p38 MAP kinase phosphorylation and ultimately apoptosis (Spiller et al., 2008). Recently a phase 3 trial has been opened to treat medulloblastoma with RA.

There are several different approaches to try to kill medulloblastoma cells by means of immunotherapy. Only some of them were introduced in small series of pediatric patients with limited success. In the last decades of the twentieth century application of lymphokine activated killer (LAK) cells directly administered intrathecally with co-administration of human recombinant IL-2 for patients with recurrent disseminated medulloblastoma was published. Some of the limited number of patients showed long term survival (Okamoto et al., 1988; Silvani et al., 1994).

Another method is the adoptive transfer of tumor-specific cytolytic T cells to the tumor bed and cerebrospinal fluid. This is an attractive strategy, but limited in its clinical application owing to the paucity of defined antigens consistently expressed by medulloblastoma. So far only two *in vitro* animal medulloblastoma xenograft models have been published. One is targeting IL13Receptor-alpha2 by genetically modified CD8+ cytotoxic T-cells expressing an IL13-zetakine chimeric immunoreceptor (Stastny et al., 2007). The other model is targeting HER2 expression, which is a feature of the malignant phenotype of medulloblastoma (Gilbertson et al., 1995). Recruiting the cellular arm of the immune response to HER2 positive tumor cells, genetically engineered HER2-specific T-cell with antigen binding property and lytic capacity were created. Adoptive transferred HER2-specific T-cells were administered in SCID mouse orthotopic medulloblastoma xenograft, which resulted in sustained regression of HER2 positive medulloblastoma, which might have resulted in a

promising immunotherapeutic approach (Ahmed et al., 2007). Phase 1 study of adoptive transfer of tumor-specific cytolytic T cells exists in patients with recurrent glioblastoma multiforme and neuroblastoma.

Another immunotherapeutic method which is already investigated in human patients with recurrent medulloblastoma is based on dendritic cell-based tumor vaccination. Dendritic cells are the antigen presenting cells, which are present in central nervous system exclusively. Autologous mature dendritic cells loaded with tumor lysates derived from autologous, resected medulloblastomas were injected subcutaneously in 5 patients with medulloblastoma. Although the treatment was safe, no response was observed in any patient (Ardon et al., 2010).

Natural killer (NK) cells display the highest cytolytic activity against tumor cells, and are considered suitable candidates for adoptive immunotherapy to treat cancer patients. Castriconi et al showed that in vitro medulloblastoma cell lines express ligands for activating NK-receptors, which makes medulloblastoma highly susceptible to NK-mediated cytotoxicity (Castriconi et al., 2007). However, human studies using NK-cells in medulloblastoma are lacking at this moment.

5. Conclusions

The therapy of medulloblastoma has changed during the last few decades which resulted in the improvement of the long-term survival up to almost 80%. This is due to the complex chemotherapy beyond the improved surgical and radiotherapeutical techniques. After cyclophosphamide, nitrosoureas and methotrexate more effective drugs would be applied in the treatment of medulloblastoma: carboplatin, cisplatin, etoposide and ifosfamide. In resistant or relapsed cases several other drugs are used, too, as Temozolomide. The preoperative therapy in spite of the encouraging pilot studies could not become a general practice. The high dose chemotherapy with autologous stem cell rescue seems to be effective to eradicate the remained tumour cells in high risk cases. The prolongation of the chemotherapy with cytostatic drugs in low doses and/or antiproliferative agents (retinoic acid, valproic acid, antiangiogenic agents) seems to be effective to prolong the remission in incurable cases. The chemotherapy is especially important in very young children (less than 3 years old) because of the serious late side effects of radiotherapy. The targeted molecular therapy is promising, however, in spite of the several clinical studies the effectivity of molecular therapy is not proved yet in phase III. studies.

6. References

- Abouantoun, T.J., & MacDonald, T.J. (2009). Imatinib blocks migration and invasion of medulloblastoma cells by concurrently inhibiting activation of platelet-derived growth factor receptor and transactivation of epidermal growth factor receptor. *Mol Cancer Ther*, 8, 5, (May 2009), 1137-47.
- Ahmed, N., Ratnayake, M., Savoldo, B., Perlaky, L., Dotti, G., Wels, WS., Bhattacharjee, MB., Gilbertson, RJ., Shine, HD., Weiss, HL., Rooney, CM., Heslop, HE., & Gottschalk, S. (2007). Regression of experimental medulloblastoma following transfer of HER2-specific T cells. *Cancer Res*, 67, 12, (Jun 2007), 5957-64.
- Aihara, Y., Tsuruta, T., Kawamata, T., Kanno, H., Maebayashi, K., Sakauchi, M., Wada, E., Osawa, M., Fujii, H., Kubo, O., & Hori, T. (2010). Double high-dose chemotherapy

- followed by autologous peripheral blood stem cell transplantation for primary disseminated medulloblastoma: a report of 3 cases. *J Pediatr Hematol Oncol*, 32, 2, (Mar 2010), e70-4.
- Albright, AL., Wisoff, JH., Zeltzer, PM., Boyett, JM., Rorke, LB., & Stanley, P. (1996). Effects of medulloblastoma resections on outcome in children: a report from the Children's Cancer Group. *Neurosurgery*, 38, 2, (Feb 1996), 265-71.
- Ardon, H., De Vleeschouwer, S., Van Calenbergh, F., Claes, L., Kramm, CM., Rutkowski, S., Wolff, JE., & Van Gool, SW. (2010). Adjuvant dendritic cell-based tumour vaccination for children with malignant brain tumours. *Pediatr Blood Cancer*, 54, 4, (Apr 2010), 519-25.
- Bailey, CC., Gnekow, A., Wellek, S., Jones, M., Round, C., Brown, J., Phillips, A., & Neidhardt, MK. (1995). Prospective randomised trial of chemotherapy given before radiotherapy in childhood medulloblastoma. International Society of Paediatric Oncology (SIOP) and the (German) Society of Paediatric Oncology (GPO): SIOP II. *Med Pediatr Oncol*, 25, 3, (Sep 1995), 166-78.
- Beutler, D., Avoledo, P., Reubi, JC., Macke, HR., Muller-Brand, J., Merlo, A., & Kühne, T. (2005). Three-year recurrence-free survival in a patient with recurrent medulloblastoma after resection, high-dose chemotherapy, and intrathecal Yttrium-90-labeled DOTA0-D-Phe1-Tyr3-octreotide radiopeptide brachytherapy. *Cancer*, 103, 4, (Feb 2005), 869-73.
- Birks, DK., Barton, VN., Donson, AM., Handler, MH., Vibhakar, R., & Foreman, NK. (2011). Survey of MicroRNA expression in pediatric brain tumors. *Pediatr Blood Cancer*, 56, 2, (2011), 211-6.
- Bleyer, WA. (1981). Neurologic sequelae of methotrexate and ionizing radiation: a new classification. *Cancer Treat Rep*, 65 Suppl 1, (1981), 89-98.
- Butturini, AM., Jacob, M., Aguajo, J., Vander-Walde, NA., Villablanca, J., Jubran, R., Erdreich-Epstein, A., Marachelian, A., Dhall, G., & Finlay, JL. (2009). High-dose chemotherapy and autologous hematopoietic progenitor cell rescue in children with recurrent medulloblastoma and supratentorial primitive neuroectodermal tumors: the impact of prior radiotherapy on outcome. *Cancer*, 115, 13, (Jul 2009), 2956-63.
- Castriconi, R., Dondero, A., Negri, F., Bellora, F., Nozza, P., Carnemolla, B., Raso, A., Moretta, L., Moretta, A., & Bottino, C. (2007). Both CD133+ and CD133- medulloblastoma cell lines express ligands for triggering NK receptors and are susceptible to NK-mediated cytotoxicity. *Eur J Immunol*, 37, 11, (Nov 2007), 3190-6.
- Chang, CH., Housepian, EM., & Herbert, C. Jr. (1969). An operative staging system and a megavoltage radiotherapeutic technic for cerebellar medulloblastomas. *Radiology*, 93, 6, (Dec 1969), 1351-9.
- Chi, SN., Gardner, SL., Levy, AS., Knopp, EA., Miller, DC., Wisoff, JH., Weiner, HL., & Finlay, JL. (2004). Feasibility and response to induction chemotherapy intensified with high-dose methotrexate for young children with newly diagnosed high-risk disseminated medulloblastoma. *J Clin Oncol*, 22, 24, (Dec 2004), 4881-7.
- Dhall, G., Grodman, H., Ji, L., Sands, S., Gardner, S., Dunkel, IJ., McCowage, GB., Diez, B., Allen, JC., Gopalan, A., Cornelius, AS., Termuhlen, A., Abromowitch, M., Sposto, R., & Finlay, JL. (2008). Outcome of children less than three years old at diagnosis with non-metastatic medulloblastoma treated with chemotherapy on the "Head Start" I and II protocols. *Pediatr Blood Cancer*, 50, 6, (Jun 2008), 1169-75.

- Eberhart, CG., Kepner, JL., Goldthwaite, PT., Kun, LE., Duffner, PK., Friedman, HS., Strother, DR., & Burger, PC. (2002). Histopathologic grading of medulloblastomas: a Pediatric Oncology Group study. *Cancer*, 94, 2, (Jan 2002), 552-60.
- Ellison, DW. (2010). Childhood medulloblastoma: novel approaches to the classification of a heterogeneous disease. *Acta Neuropathol*, 120, 3, (2010), 305-16.
- Evans, AE., Jenkin, RD., Sposto, R., Ortega, JA., Wilson, CB., Wara, W., Ertel, IJ., Kramer, S., Chang, CH., Leikin, SL., & Hammond, GD. (1990). The treatment of medulloblastoma. Results of a prospective randomized trial of radiation therapy with and without CCNU, vincristine, and prednisone. *J Neurosurg*, 72, 4, (Apr 1990), 572-82.
- Fernandez-Teijeiro, A., Betensky, RA., Sturla, LM., Kim, JY., Tamayo, P., & Pomeroy, SL. (2004). Combining gene expression profiles and clinical parameters for risk stratification in medulloblastomas. *J Clin Oncol*, 22, 6, (Mar 2004), 994-8.
- Fouladi, M., Gilger, E., Kocak, M., Wallace, D., Buchanan, G., Reeves, C., Robbins, N., Merchant, T., Kun, LE., Khan, R., Gajjar, A., & Mulhern, R. (2005). Intellectual and functional outcome of children 3 years old or younger who have CNS malignancies. *J Clin Oncol*, 23, 28, (Oct 2005), 7152-60.
- Fruhwald, MC., Rickert, CH., O'Dorisio, MS., Madsen, M., Warmuth-Metz, M., Khanna, G., Paulus, W., Kühl, J., Jürgens, H., Schneider, P., & Müller, HL. (2004). Somatostatin receptor subtype 2 is expressed by supratentorial primitive neuroectodermal tumors of childhood and can be targeted for somatostatin receptor imaging. *Clin Cancer Res*, 10, 9, (May 2004), 2997-3006.
- Gajjar, A., Chintagumpala, M., Ashley, D., Kellie, S., Kun, LE., Merchant, TE., Woo, S., Wheeler, G., Ahern, V., Krasin, MJ., Fouladi, M., Broniscer, A., Krance, R., Hale, GA., Stewart, CF., Dauser, R., Sanford, RA., Fuller, C., Lau, C., Boyett, JM., Wallace, D., & Gilbertson, RJ. (2006). Risk-adapted craniospinal radiotherapy followed by high-dose chemotherapy and stem-cell rescue in children with newly diagnosed medulloblastoma (St Jude Medulloblastoma-96): long-term results from a prospective, multicentre trial. *Lancet Oncol*, 7, 10, (Oct 2006), 813-20.
- Giangaspero, F., Wellek, S., Masuoka, J., Gessi, M., Kleihues, P., & Ohgaki, H. (2006). Stratification of medulloblastoma on the basis of histopathological grading. *Acta Neuropathol*, 112, 1, (Jul 2006), 5-12.
- Gilbertson, RJ., Pearson, AD., Perry, RH., Jaros, E., & Kelly, PJ. (1995). Prognostic significance of the c-erbB-2 oncogene product in childhood medulloblastoma. *Br J Cancer*, 71, 3, (Mar 1995), 473-7.
- Gilbertson, RJ., & Clifford, SC. (2003). PDGFRB is overexpressed in metastatic medulloblastoma. *Nat Genet*, 35, 3, (Nov 2003), 197-8.
- Glas, M., Hennemann, B., Hirschmann, B., Marienhagen, J., Schmidt-Wolf, I., Herrlinger, U., Bogdahn, U., & Hau, P. (2008). Complete response after treatment with a somatostatin analogue in an adult patient with recurrent medulloblastoma. *Acta Oncol*, 47, 3, (2008), 479-80.
- Gottardo, NG., & Gajjar, A. (2008). Chemotherapy for malignant brain tumors of childhood. *J Child Neurol*, 23, 10, (Oct 2008), 1149-59.
- Grill, J., Lellouch-Tubiana, A., Elouahdani, S., Pierre-Kahn, A., Zerah, M., Renier, D., Valteau-Couanet, D., Hartmann, O., Kalifa, C., & Sainte-Rose, C. (2005). Preoperative chemotherapy in children with high-risk medulloblastomas: a feasibility study. *J Neurosurg*, 103, 4 Suppl, (Oct 2005), 312-8.

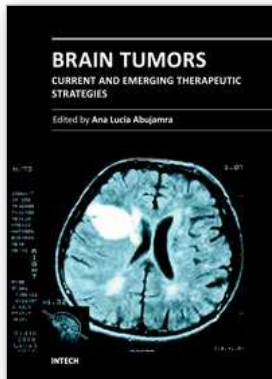
- Gupta, N., Banerjee, A., & Haas-Kogan, D. (19 March 2004). *Pediatric CNS Tumors*. (First ed.), Springer, ISBN: 3-540-00294-4, Berlin, Heidelberg, New York, Hong Kong, London, Milan, Paris, Tokyo
- Guyotat, J., Champier, J., Pierre, GS., Jouvét, A., Bret, P., Brisson, C., Belin, MF., Signorelli, F., & Montange, MF. (2001). Differential expression of somatostatin receptors in medulloblastoma. *J Neurooncol*, 51, 2, (Jan 2001), 93-103.
- Hallahan, AR., Pritchard, JL., Chandraratna, RA., Ellenbogen, RG., Geyer, JR., Overland, RP., Strand, AD., Tapscott, SJ., & Olson, JM. (2003). BMP-2 mediates retinoid-induced apoptosis in medulloblastoma cells through a paracrine effect. *Nat Med*, 9, (Aug 2003), 1033-1038.
- Hauser, P., Jakab, Zs., Láng, O., Kondás, O., Török, S., Garami, M., Bognár, L., & Schuler, D. (2003). High incidence of brain tumors of childhood in Hungary between 1989 and 2001. *Med Pediatr Oncol*, 41, 6, (2003), 590-1.
- Hauser, P., Jakab, Zs., Kiss, Cs., Szegedi, I., Bárdi, E., Bartyik, K., Ottóffy, G., Kajtár, P., Szűcs, R., Nagy, K., Cservenák, J., Masát, P., Bálint, K., Kordás, M., Bognár, L., Kocsis, B., Vízkeleti, J., Kriván, G., Kállay, K., Benyó, G., Schuler, D., & Garami, M. (2009). Előzetes eredmények a medulloblastoma/PNET kezelésében a magyar MBL2004 kezelési sémával. *Magy Belorv Arch*, 62, (2009), 196-201.
- von Hoff, K., Hinkes, B., Gerber, NU., Deinlein, F., Mittler, U., Urban, C., Benesch, M., Warmuth-Metz, M., Soerensen, N., Zwiener, I., Goette, H., Schlegel, PG., Pietsch, T., Kortmann, RD., Kuehl, J., & Rutkowski, S. (2009). Long-term outcome and clinical prognostic factors in children with medulloblastoma treated in the prospective randomised multicentre trial HIT'91. *Eur J Cancer*, 45, 7, (2009), 1209-17.
- Jakacki, R., Burger, P., Zhou, T., Holmes, E., Packer, R., Goldwein, J., Mehta, M., & Pollack, I. (2007.) Outcome for metastatic (M+) medulloblastoma (MB) treated with carboplatin during craniospinal radiotherapy (CSRT) followed by cyclophosphamide (CPM) and vincristine (VCR): Preliminary results of COG 99701. *J Clin Oncol*, 25, 18S, (Jun 2007), 2017.
- Jenkin, D., Shabanah, MA., Shail, EA., Gray, A., Hassounah, M., Khafaga, Y., Kofide, A., Mustafa, M., & Schultz, H. (2000). Prognostic factors for medulloblastoma. *Int J Radiat Oncol Biol Phys*, 47, 3, (Jun 2000), 573-84.
- Johnston, DL., Keene, D., Bartels, U., Carret, AS., Crooks, B., Eisenstat, DD., Fryer, C., Lafay-Cousin, L., Larouche, V., Moghrabi, A., Wilson, B., Zelcer, S., Silva, M., Brossard, J., & Bouffet, E. (2009). Medulloblastoma in children under the age of three years: a retrospective Canadian review. *J Neurooncol*, 94, 1, (Aug 2009), 51-6.
- Kaderali, Z., Lamberti-Pasculli, M., & Rutka, JT. (2009). The changing epidemiology of paediatric brain tumours: a review from the Hospital for Sick Children. *Childs Nerv Syst*, 25, 7, (Jul 2009), 787-93.
- Kieran, MW., Turner, CD., Rubin, JB., Chi, SN., Zimmerman, MA., Chordas, C., Klement, G., Laforme, A., Gordon, A., Thomas, A., Neuberg, D., Browder, T., & Folkman, J. (2005). A feasibility trial of antiangiogenic (metronomic) chemotherapy in pediatric patients with recurrent or progressive cancer. *J Pediatr Hematol Oncol*. 27, 11, (Nov 2005), 573-81.
- Klesse, LJ., & Bowers, DC. (2010). Childhood medulloblastoma: current status of biology and treatment. *CNS Drugs*, 24, 4, (2010), 285-301.
- Kobrinisky, NL., Packer, RJ., Boyett, JM., Stanley, P., Shiminski-Maher, T., Allen, JC., Garvin, JH., Stewart, DJ., & Finlay, JL. (1999). Etoposide with or without mannitol for the

- treatment of recurrent or primarily unresponsive brain tumors: a Children's Cancer Group Study, CCG-9881. *J Neurooncol*, 45, 1, (1999), 47-54.
- Kortmann, RD., Kühl, J., Timmermann, B., Mittler, U., Urban, C., Budach, V., Richter, E., Willich, N., Flentje, M., Berthold, F., Slavc, I., Wolff, J., Meisner, C., Wiestler, O., Sörensen, N., Warmuth-Metz, M., & Bamberg, M. (2000). Postoperative neoadjuvant chemotherapy before radiotherapy as compared to immediate radiotherapy followed by maintenance chemotherapy in the treatment of medulloblastoma in childhood: results of the German prospective randomized trial HIT '91. *Int J Radiat Oncol Biol Phys*, 46, 2, (Jan 2000), 269-79.
- Laurent, JP., Chang, CH., & Cohen, ME. (1985). A classification system for primitive neuroectodermal tumors (medulloblastoma) of the posterior fossa. *Cancer*, 1, 56, (Oct 1985), 1807-9.
- Marks, P., Rifkind, RA., Richon, VM., Breslow, R., Miller, T., & Kelly, WK. (2001). Histone deacetylases and cancer: causes and therapies. *Nat Rev Cancer*, 1, (Dec 2001), 194-202.
- Marks, PA., & Dokmanovic, M. (2005). Histone deacetylase inhibitors: discovery and development as anticancer agents. *Expert Opin Investig Drugs*, 14, (Dec 2005), 1497-511.
- McNeil, DE., Coté, TR., Clegg, L., & Rorke, LB. (2002). Incidence and trends in pediatric malignancies medulloblastoma/primitive neuroectodermal tumor: a SEER update. *Surveillance Epidemiology and End Results. Med Pediatr Oncol*, 39, 3, (Sep 2002), 190-4.
- Miller, WH. (1998). The emerging role of retinoids and retinoic acid metabolism blocking agents in the treatment of cancer. *Cancer*, 83, (Oct 1998), 1471-1482.
- Mueller, S., & Chang, S. (2009). Pediatric brain tumors: current treatment strategies and future therapeutic approaches. *Neurotherapeutics*, 6, 3, (Jul 2009), 570-86.
- Mulhern, RK., Kepner, JL., Thomas, PR., Armstrong, FD., Friedman, HS., & Kun, LE. (1998). Neuropsychologic functioning of survivors of childhood medulloblastoma randomized to receive conventional or reduced-dose craniospinal irradiation: a Pediatric Oncology Group study. *J Clin Oncol*, 16, 5, (May 1998), 1723-8.
- Mulhern, RK., Merchant, TE., Gajjar, A., Reddick, WE., & Kun, LE. (2004). Late neurocognitive sequelae in survivors of brain tumours in childhood. *Lancet Oncol*, 5, 7, (Jul 2004), 399-408.
- Muller, HL., Fruhwald, MC., Scheubeck, M., Rendl, J., Warmuth-Metz, M., Sörensen, N., Kühl, J., & Reubi, JC. (1998). A possible role for somatostatin receptor scintigraphy in the diagnosis and follow-up of children with medulloblastoma. *J Neurooncol*, 38, 1, (May 1998), 27-40.
- Northcott, PA., Korshunov, A., Witt, H., Hielscher, T., Eberhart, CG., Mack, S., Bouffet, E., Clifford, SC., Hawkins, CE., French, P., Rutka, JT., Pfister, S., & Taylor, MD. (2010). Medulloblastoma Comprises Four Distinct Molecular Variants. *J Clin Oncol*. 2010 Dec 6. [Epub ahead of print]
- Okamoto, Y., Shimizu, K., Tamura, K., Miyao, Y., Yamada, M., Matsui, Y., Tsuda, N., Takimoto, H., Hayakawa, T., & Mogami, H. (1988). An adoptive immunotherapy of patients with medulloblastoma by lymphokine-activated killer cells (LAK). *Acta Neurochir (Wien)*, 94, 1-2, (1988), 47-52.

- Paál, C., Erdélyi-Tóth, V., Pap, E., Csáki, C., Ferencz, T., Schuler, D., & Borsi, JD. (1994). Pharmacokinetic studies on Elobromol in children with brain tumors. *Anticancer Drugs*, 5, 5, (Oct 1994), 539-47.
- Packer, RJ., Sutton, LN., Elterman, R., Lange, B., Goldwein, J., Nicholson, HS., Mulne, L., Boyett, J., D'Angio, G., Wechsler-Jentzsch, K., Reaman, G., Cohen, BH., Bruce, DA., Rorke, LB., Molloy, P., Ryan, J., LaFond, D., Evans, AE., & Schut, L. (1994). Outcome for children with medulloblastoma treated with radiation and cisplatin, CCNU, and vincristine chemotherapy. *J Neurosurg*, 81, 5, (Nov 1994), 690-8.
- Packer, RJ., Goldwein, J., Nicholson, HS., Vezina, LG., Allen, JC., Ris, MD., Muraszko, K., Rorke, LB., Wara, WM., Cohen, BH., & Boyett, JM. (1999). Treatment of children with medulloblastomas with reduced-dose craniospinal radiation therapy and adjuvant chemotherapy: A Children's Cancer Group Study. *J Clin Oncol*, 17, 7, (Jul 1999), 2127-36.
- Packer, RJ., Gajjar, A., Vezina, G., Rorke-Adams, L., Burger, PC., Robertson, PL., Bayer, L., LaFond, D., Donahue, BR., Marymont, MH., Muraszko, K., Langston, J., & Sposto, R. (2006). Phase III study of craniospinal radiation therapy followed by adjuvant chemotherapy for newly diagnosed average-risk medulloblastoma. *J Clin Oncol*, 24, 25, (Sep 2006), 4202-8.
- Park, JE., Kang, J., Yoo, KH., Sung, KW., Koo, HH., Lim do, H., Shin, HJ., Kang, HJ., Park, KD., Shin, HY., Kim, IH., Cho, BK., Im, HJ., Seo, JJ., Park, HJ., Park, BK., & Ahn, HS. (2010). Efficacy of high-dose chemotherapy and autologous stem cell transplantation in patients with relapsed medulloblastoma: a report on the Korean Society for Pediatric Neuro-Oncology (KSPNO)-S-053 study. *J Korean Med Sci*, 25, 8, (2010), 1160-6.
- Peris-Bonet, R., Martinez-Garcia, C., Lacour, B., Petrovich, S., Giner-Ripoll, B., Navajas, A., & Steliarov-Foucher, E. (2006). Childhood central nervous system tumours--incidence and survival in Europe (1978-1997): report from Automated Childhood Cancer Information System project. *European Journal of Cancer*, 42, 13, (Sept 2006), 1064-80.
- Pizzo, PA., & Poplack, DG. (11 October 2010). *Principles and Practice of Pediatric Oncology* (Sixth ed.), 2011 Lippincott Williams & Wilkins, ISBN: 978-1-60547-682-7, Philadelphia, Baltimore, New York, London, Buenos Aires, Hong Kong, Sydney, Tokyo
- Prados, MD., Schold, SC. Jr, Fine, HA., Jaeckle, K., Hochberg, F., Mechtler, L., Fetell, MR., Phuphanich, S., Feun, L., Janus, TJ., Ford, K., & Graney, W. (2003). A randomized, double-blind, placebo-controlled, phase 2 study of RMP-7 in combination with carboplatin administered intravenously for the treatment of recurrent malignant glioma. *Neuro Oncol*, 5, 2, (Apr 2003), 96-103.
- Privitera, G., Acquaviva, G., Ettorre, GC., & Spatola, C. (2009). Antiangiogenic therapy in the treatment of recurrent medulloblastoma in the adult: case report and review of the literature. *J Oncol*, 2009, (Epub Dec 2009), 247873.
- Di Rocco, C., Iannelli, A., La Marca, F., Tornesello, A., Mastrangelo, S., & Riccardi, R. (1995). Preoperative chemotherapy with carboplatin alone in high risk medulloblastoma. *Childs Nerv Syst*, 11, 10, (Oct 1995), 574-8.
- Roth, SY., Denu, JM., & Allis, CD. (2001). Histone acetyltransferases. *Annu Rev Biochem*, 70, (2001), 81-120.
- Rudin, CM., Hann, CL., Lattera, J., Yauch, RL., Callahan, CA., Fu, L., Holcomb, T., Stinson, J., Gould, SE., Coleman, B., LoRusso, PM., Von Hoff, DD., de Sauvage, FJ., & Low, JA.

- (2009). Treatment of medulloblastoma with hedgehog pathway inhibitor GDC-0449. *N Engl J Med*, 361, 12, (Sep 2009), 1173-8.
- Ruggiero, A., Rizzo, D., Attinà, G., Lazzareschi, I., Mastrangelo, S., Maurizi, P., Migliorati, R., Bertolini, P., Pastore, M., Colosimo, C., & Riccardi, R. (2010). Phase I study of temozolomide combined with oral etoposide in children with recurrent or progressive medulloblastoma. *Eur J Cancer*, 46, 16, (Nov 2010), 2943-9.
- de Ruijter, A.J., van Gennip, A.H., Caron, H.N., Kemp, S., & van Kuilenburg, A.B. (2003). Histone deacetylases (HDACs): characterization of the classical HDAC family. *Biochem J*, 370, Pt 3, (Mar 2003), 737-49.
- Rutkowski, S., Bode, U., Deinlein, F., Ottensmeier, H., Warmuth-Metz, M., Soerensen, N., Graf, N., Emser, A., Pietsch, T., Wolff, J.E., Kortmann, R.D., & Kuehl, J. (2005). Treatment of early childhood medulloblastoma by postoperative chemotherapy alone. *N Engl J Med*, 352, 10, (Mar 2005), 978-86.
- Rutkowski, S., Cohen, B., Finlay, J., Luksch, R., Ridola, V., Valteau-Couanet, D., Hara, J., Garre, M.L., & Grill, J. (2010). Medulloblastoma in young children. *Pediatr Blood Cancer*, 54, 4, (Apr 2010), 635-7.
- Rutkowski, S., von Hoff, K., Emser, A., Zwiener, I., Pietsch, T., Figarella-Branger, D., Giangaspero, F., Ellison, D.W., Garre, M.L., Biassoni, V., Grundy, R.G., Finlay, J.L., Dhall, G., Raquin, M.A., & Grill, J. (2010). Survival and prognostic factors of early childhood medulloblastoma: an international meta-analysis. *J Clin Oncol*, 28, 33, (Nov 2010), 4961-8.
- Schuler, D., Somló, P., Borsi, J., Paraicz, E., Révész, T., Kardos, G., & Koós, R. (1988). New drug combination for the treatment of relapsed brain tumors in children. *Pediatr Hematol Oncol*, 5, 2, (1988), 153-6.
- Schuler, D., Somló, P., Koós, R., Kálmánchey, R., & Paraicz, E. (1992). Treatment of malignant scala posterior brain tumors in children: the chemotherapy of relapsed medulloblastoma with a dibromdulcitol containing drug regime and pharmacokinetic studies of dibromdulcitol in children. *Med Pediatr Oncol*, 20, 4, (1992), 312-4.
- Schuler, D., Somló, P., Koós, R., Kálmánchey, R., & Paraicz, E. (1993). The treatment of malignant scala posterior tumors in children: II. Preliminary result of the pre- and postoperative adjuvant chemotherapy of scala posterior tumors. *Med Pediatr Oncol*, 21, 4, (1993), 274-9.
- Silvani, A., Salmaggi, A., Parmiani, G., & Boiardi, A. (1994). Successful adoptive immunotherapy with lymphokine-activated killer cells in the treatment of medulloblastoma disseminated via cerebrospinal fluid: case report. *Neurosurgery*, 34, 6, (Jun 1994), 1078-80.
- Spiller, S.E., Ditzler, S.H., Pullar, B.J., & Olson, J.M. (2008). Response of preclinical medulloblastoma models to combination therapy with 13-cis retinoic acid and suberoylanilide hydroxamic acid (SAHA). *J Neurooncol*, 87, 2, (Apr 2008), 133-41.
- Stastny, M.J., Brown, C.E., Ruel, C., & Jensen, M.C. (2007). Medulloblastomas expressing IL13Ralpha2 are targets for IL13-zetakine+ cytolytic T cells. *J Pediatr Hematol Oncol*, 29, 10, (Oct 2007), 669-77.
- Sterba, J., Pavelka, Z., Andre, N., Ventrubá, J., Skotakova, J., Bajciova, V., Bronisova, D., Dubska, L., & Valik, D. (2010). Second complete remission of relapsed medulloblastoma induced by metronomic chemotherapy. *Pediatr Blood Cancer*, 54, 4, (Apr 2010), 616-7.

- Strother, D., Ashley, D., Kellie, S.J., Patel, A., Jones-Wallace, D., Thompson, S., Heideman, R., Benaim, E., Krance, R., Bowman, L., & Gajjar, A. (2001). Feasibility of four consecutive high-dose chemotherapy cycles with stem-cell rescue for patients with newly diagnosed medulloblastoma or supratentorial primitive neuroectodermal tumor after craniospinal radiotherapy: results of a collaborative study. *J Clin Oncol*, 19, 10, (May 2001), 2696-704.
- Su, J.M., Li, X.N., Thompson, P., Ou, C.N., Ingle, A.M., Russell, H., Lau, C.C., Adamson, P.C., & Blaney, S.M. (2011). Phase 1 study of valproic acid in pediatric patients with refractory solid or CNS tumors: a children's oncology group report. *Clin Cancer Res*, 17, 3, (Feb 2011), 589-97.
- Tabori, U., Baskin, B., Shago, M., Alon, N., Taylor, M.D., Ray, P.N., Bouffet, E., Malkin, D., & Hawkins, C. (2010). Universal poor survival in children with medulloblastoma harboring somatic TP53 mutations. *J Clin Oncol*, 28, 8, (Mar 2010), 1345-50.
- Tait, D.M., Thornton-Jones, H., Bloom, H.J., Lemerle, J., & Morris-Jones, P. (1990). Adjuvant chemotherapy for medulloblastoma: the first multi-centre control trial of the International Society of Paediatric Oncology (SIOP I). *Eur J Cancer*, 26, 4, (Apr 1990), 464-9.
- Takei, H., Nguyen, Y., Mehta, V., Chintagumpala, M., Dauser, R.C., & Adesina, A.M. (2009). Low-level copy gain versus amplification of myc oncogenes in medulloblastoma: utility in predicting prognosis and survival. Laboratory investigation. *J Neurosurg Pediatr*, 3, 1, (Jan 2009), 61-5.
- Taylor, R.E., Bailey, C.C., Robinson, K., Weston, C.L., Ellison, D., Ironside, J., Lucreft, H., Gilbertson, R., Tait, D.M., Walker, D.A., Pizer, B.L., Imeson, J., Lashford, L.S., & International Society of Paediatric Oncology, United Kingdom Children's Cancer Study Group. (2003). Results of a randomized study of preradiation chemotherapy versus radiotherapy alone for nonmetastatic medulloblastoma: The International Society of Paediatric Oncology/United Kingdom Children's Cancer Study Group PNET-3 Study. *J Clin Oncol*, 21, 8, (Apr 2003), 1581-91.
- Wang, C.H., Hsu, T.R., Wong, T.T., & Chang, K.P. (2009). Efficacy of temozolomide for recurrent embryonal brain tumors in children. *Childs Nerv Syst*, 25, 5, (May 2009), 535-41.
- Wechsler-Reya, R., & Scott, M.P. (2001). The developmental biology of brain tumors. *Annu Rev Neurosci*, 24, (2001), 385-428.
- Zeltzer, P.M., Boyett, J.M., Finlay, J.L., Albright, A.L., Rorke, L.B., Milstein, J.M., Allen, J.C., Stevens, K.R., Stanley, P., Li, H., Wisoff, J.H., Geyer, J.R., McGuire-Cullen, P., Stehbens, J.A., Shurin, S.B., & Packer, R.J. (1999). Metastasis stage, adjuvant treatment, and residual tumor are prognostic factors for medulloblastoma in children: conclusions from the Children's Cancer Group 921 randomized phase III study. *J Clin Oncol*, 17, 3, (Mar 1999), 832-45.



Brain Tumors - Current and Emerging Therapeutic Strategies

Edited by Dr. Ana Lucia Abujamra

ISBN 978-953-307-588-4

Hard cover, 422 pages

Publisher InTech

Published online 23, August, 2011

Published in print edition August, 2011

Brain Tumors: Current and Emerging Therapeutic Strategies focuses on tumor models, the molecular mechanisms involved in the pathogenesis of this disease, and on the new diagnostic and treatment strategies utilized to stage and treat this malignancy. A special section on immunotherapy and gene therapy provides the most up-to-date information on the pre-clinical and clinical advances of this therapeutic venue. Each chapter in Brain Tumors: Current and Emerging Therapeutic Strategies is authored by international experts with extensive experience in the areas covered.

How to reference

In order to correctly reference this scholarly work, feel free to copy and paste the following:

Dezső Schuler, Péter Hauser and Miklós Garami (2011). Chemotherapy of Medulloblastoma in Children, Brain Tumors - Current and Emerging Therapeutic Strategies, Dr. Ana Lucia Abujamra (Ed.), ISBN: 978-953-307-588-4, InTech, Available from: <http://www.intechopen.com/books/brain-tumors-current-and-emerging-therapeutic-strategies/chemotherapy-of-medulloblastoma-in-children>

INTECH

open science | open minds

InTech Europe

University Campus STeP Ri
Slavka Krautzeka 83/A
51000 Rijeka, Croatia
Phone: +385 (51) 770 447
Fax: +385 (51) 686 166
www.intechopen.com

InTech China

Unit 405, Office Block, Hotel Equatorial Shanghai
No.65, Yan An Road (West), Shanghai, 200040, China
中国上海市延安西路65号上海国际贵都大饭店办公楼405单元
Phone: +86-21-62489820
Fax: +86-21-62489821

© 2011 The Author(s). Licensee IntechOpen. This chapter is distributed under the terms of the [Creative Commons Attribution-NonCommercial-ShareAlike-3.0 License](#), which permits use, distribution and reproduction for non-commercial purposes, provided the original is properly cited and derivative works building on this content are distributed under the same license.