

# MR Imaging of Gastric Carcinoma

Il Young Kim  
*Soonchunhyang University*  
*Republic of Korea*

## 1. Introduction

Magnetic Resonance (MR) imaging has not become popular for staging of gastric carcinoma because of a number of limitations, including motion artifacts, lack of a stable contrast medium, and the high cost. However, continuous technical improvements have been made in MR imaging of the abdomen, thereby reducing motion artifacts and improving image quality. These improvements include breath-hold fast imaging techniques, placement of abdominal binders, administration of antiperistaltic agents, and the use of phased array coils. In vitro studies using 1 - 4.7- T MR systems have shown that MRI allows the depiction of gastric wall layers and therefore, technically permits the evaluation of the local tumor stage of gastric carcinomas. However, MR study in gastric carcinoma is challenging and it has much possibility. Usually, the preoperative staging workup of gastric carcinoma is performed mainly with computed tomography (CT). CT has been a favored method for preoperative evaluation and staging in patients with gastric carcinoma (Goldberg & Thoeni. 1989; Werthmuller & Margulis. 1991; Halvorsen & Thompson. 1991). Parallel advances in CT equipment and scanning techniques have reduced scanning time and decreased motion artifacts. Simultaneously, rapid IV contrast administration with an automatic power injector has improved contrast enhancement of the gastric wall and gastric carcinoma. Helical CT has advantages over conventional CT, including faster scanning time and fewer respiratory misregistration artifacts in a single breath-hold (Hahn, et al., as cited in Stark & Bradley. 1992). However, CT is limited, particularly in the diagnosis of lymph node metastasis, peritoneal metastasis, and small hematogenous metastasis. Endoscopic sonography has been reported to be the most accurate technique for the T staging of gastric carcinoma because it can define five layers of the gastric wall (Botet, et al. 1991). But this technique cannot evaluate other factors such as liver metastasis and peritoneal seeding. In addition, endoscopic sonography is an invasive technique dependent on the operator.

## 2. MR Imaging

### 2.1 MR Imaging techniques

Residual stool or foodstuff can obviate the evaluation of gastrointestinal wall structures. Therefore, MRI should be performed following a 6 hr fasting period to ensure a consistent assessment of the stomach. A reliable distension of stomach must be achieved to allow for a reliable evaluation of the gastric wall. Otherwise, insufficient distension may result in false-positive or false-negative findings. Adequate distension of the stomach can be easily accomplished by oral administration of water or water based contrast agents. Image data

should be collected without any time delay after contrast administration. Fast breath-hold MR sequences and antiperistaltic drugs are suggested for gastric carcinoma patient. A large volume (1 L) of tap water is ingested to the patient for the distention and opacification of the stomach (Seong, et al. 1998). This large volume of water was tolerated by the patients while providing sufficient distention of the stomach, which made it easier to differentiate gastric carcinoma from normal gastric wall. Water is absolutely safe and does not cause susceptibility artifacts. Sohn et al. (2000) used water or effervescent granules as oral contrast agents. Water is biphasic and the simplest contrast agent. Effervescent granules (a negative contrast agent) make the lumen of the stomach dark. If the stomach is overly distended with air, a magnetic susceptibility artifact may occur. However, the use of effervescent granules still provides improved evaluation of the gastric wall and can be used to supplement or replace water for gastric distention (Halvorsen, et al. 1996). Furthermore, oral Gd-DTPA does not provide additional diagnostic information over using tap water in MRI for gastric carcinoma (Kim A., et al. 2000a, 2000b). Therefore, the water-filling method may be appropriate for MRI of advanced gastric carcinoma (AGC).

There are various techniques for performing MR scanning. Sohn et al. (2000) used that imaging technique with a superconductive magnet operating at 1.5 T with a phased array coil. Patients fasted for 6 hr and ingested 500ml of water or effervescent granules as an oral contrast agent. Twenty milligrams of scopolamine (Buscopan; Boehringer International, Ingelheim, Germany) were administered intramuscularly 5 min before the examination for decrease of bowel peristalsis. Patients can be placed on the MR gantry in the supine or prone position to allow the lesion to contact the ingested water or air. When water was used as the oral contrast agent, the patients in whom the lesion was at the gastric cardia or fundus were imaged in the supine position, and the other patients were imaged in the prone position. The positions were reversed when effervescent granules were used as or patients were examined with a breath-hold T1-weighted 2D FLASH technique in the axial, coronal, and sagittal planes. The scanning parameters for T1-weighted axial images were TR/TE, 146.1/4.1 msec; flip angle, 80°; and one excitation. The bandwidth was 260 Hz; field of view, 33 cm; matrix size, 128× 256; and the slice thickness was 8 mm with a 1.6-mm gap. The scan time was 18 sec. The parameters for the T1-weighted coronal and sagittal images were the same as those for T1-weighted axial images, except for the TR (100 for coronal and sagittal images) and field of view (45 cm for coronal images). The scan times of coronal and sagittal images were 14 and 12 sec, respectively. T2-weighted axial turbo spin-echo images were obtained with a TR/TE of 3200/138, an echo spacing of 9.2 msec, an echo train length of 29, a flip angle of 18°, one excitation, a bandwidth of 260 Hz, a field of view of 33 cm, a matrix size of 116 × 256, an 8-mm slice thickness with a gap of 1.6 mm, and a scan time of 17 sec. Sixty seconds after an IV bolus injection of 15–20 mg of gadopentetate dimeglumine (Magnevist; Schering, Berlin, Germany) at a rate of approximately 1 ml/sec through an antecubital vein, axial T1-weighted FLASH images with fat suppression were obtained (157.6/4.1; flip angle, 80°; one excitation; bandwidth, 260 Hz; field of view, 33 cm; matrix size, 128× 256; slice thickness, 8 mm; gap, 1.6 mm) with a scan time of 19 sec. All sequences were performed in a single breath-hold. Nineteen slices were obtained for unenhanced and contrast-enhanced T1-weighted axial images, and 11 slices were obtained for coronal and sagittal T1- and T2-weighted images. For fast MR imaging, Sohn et al. (2000) performed breathhold T1-weighted 2D FLASH, T2-weighted turbo spin-echo, and contrast-enhanced T1-weighted FLASH sequences with fat suppression. In most cases, Sohn et al. (2000)

staged the tumor with two or three planes (axial, coronal, and sagittal) of unenhanced T1-weighted images only. Sohn et al. (2000) used the fat suppression technique in contrast-enhanced MR imaging to make the contrast between enhanced gastric tumor and perigastric fat more conspicuous. However, contrast-enhanced T1-weighted images showed more artifacts and lower visual contrast than unenhanced T1-weighted images. The T2-weighted images showed little difference in signal intensity between tumor and normal gastric wall and did not show an advantage for tissue characterization. Coronal and sagittal images were useful for evaluation of extraluminal outgrowth and omental infiltration by tumor. MR images, even with breath-hold fast MR imaging, were not completely free from motion artifacts, and sometimes a ghost artifact from aortic pulsation hid a lesion at the gastric angle.

On the other study, Kim A et al. (2000) used a 1.0 T scanner with a body phased array coil. Axial, coronal, and sagittal images of fast low angle shot (FLASH; TR/TE 160/6.6 ms, flip angle 75°, one excitation, matrix size 256 × 112), half-Fourier single shot turbo SE (HASTE; infinite TR, echo space 10.9 ms, TE 87 ms, flip angle 150°, matrix size 256 × 240), and true fast imaging with steady-state precession (true-FISP; TR/TE 7.6/3.5 ms, one excitation, flip angle 80°, matrix size 256 × 192) sequences were obtained in each patient immediately after ingestion of 1 L of tap water. Field of view varied from 40 to 42 cm. In all MR pulse sequences, 8 mm thickness scans were obtained during a single breath-hold. In each patient, spiral CT or MRI was performed after overnight fasting to empty the stomach. Time interval between the two examinations was either 1 or 2 days. Twenty milligrams of scopolamine (Buscopan; Boehringer International, Ingelheim, Germany) was given intramuscularly to reduce peristaltic bowel movement before MR examinations. Except for one patient in whom the lesion was located in the gastric fundus and who had images taken in the supine position, all other patients were imaged in the prone position.

## 2.2 MR imaging protocol of resected stomach

There is MR imaging study with gastric specimen by Kim I et al. (2009). In this study, there is gastric specimen distention with filling of saline solution. 1.5-T MRI is used for this study with the following multisection spin echo sequences for T1-weighted images, repetition time (TR) in sec/echo time (TE) in sec = 500/20, and for T2-weighted images, 2500/90. Two numbers of excitation were applied in this scanning. The matrix size was 256 × 256. Slice thickness was 5 mm and the intersection gap was 1 mm. Field of view was 20 cm. MR scans of the gastrectomy specimen were taken along the axial and sagittal planes. A head coil was used for scanning.

### 2.3.1 Image analysis of gastric carcinoma

A lesion is considered a cancerous lesion when the thickness of the gastric wall is >6mm and abrupt transition is noted between the thickened and adjacent normal gastric wall (Matsushita, et al. 1994). A lymph node of >8 mm on its short axis is considered to be pathologic (Dorfman, et al. 1991). The depth of tumor invasion on MRI is determined as follows: mT1 (no abnormal findings), mT2 (a clear and smooth outer surface of the lesion on FLASH/HASTE or intact low signal intensity band surrounding the lesion on true-FISP), mT3 (an irregular outer surface with obliteration of perigastric fat plane on FLASH/HASTE or interrupted low signal intensity band around the lesion on true-FISP), and mT4 (contiguous extension of gastric lesion to adjacent organs on any pulse sequences).

### 2.3.2 Image analysis of resected stomach

The number of visible wall layers and their specific signal intensity (SI) characteristics are studied by Kim I et al. (2009). Wall-layer correlation was made on the basis of the layer thickness of the visible layers in MRI compared with the ones visible in histology. The presence of a tumor, defined as destruction of the normal gastric wall layers, is noted. The tumors are examined for variations in SI. The depth of infiltration is evaluated according to earlier publications (Dux M., et al. 1997; Cho J-S., et al. 1994). A normal gastric wall is identified as having 3 layers. In terms of scanning direction and degree of distention of the wall, a gastric wall that is more than 1 cm thick or that showed an abrupt change of pattern from normal to pathologic is considered abnormal. The location, gross appearance, size and degree of serosal invasion of tumors are evaluated. Location is classified according to four areas: antrum, body, body and antrum, and fundus. Gross appearance is classified into four categories by Bormann's classification for advanced gastric carcinoma (Douglass, Nava. 1985). T and N staging were based on the TNM system developed by the American Joint Committee on Cancer (AJCC. 2002). Early gastric cancer is evaluated according to the Japanese Research Society for Gastric Cancer (Kajitani. 1981). The degree of tumor invasion in the gastric wall according to the T stage is measured as follows: T1 meant that MR showed obliteration of SI within the thickened mucosal layer and second submucosal layer, T2 meant that thickening of the gastric wall and obliteration of the third layer of muscularis propria, and T3 meant irregular SI in the outer margin of the third layer.

The total number of lymph nodes which were located in the perigastric area is counted. A lymph node of >8mm at the short axis is considered to be pathologic (Dorfman, et al. 1991). N staging of lymph nodes was performed. N0 is defined as no regional lymph node metastasis, N1 as metastasis in one to six regional lymph nodes, N2 as metastasis in seven to 15 regional lymph nodes, N3 as metastasis in more than 15 regional lymph nodes.

## 3. MR imaging finding of gastric carcinoma

### 3.1 T staging of gastric carcinoma

CT is widely used as a primary imaging modality for preoperative staging of gastric cancer. Although CT provides detailed information regarding the extent of tumor spread and provides guidelines to surgeons to avoid unnecessary exploratory laparotomy for patients with unresectable tumors, the role of CT in staging gastric cancer has been controversial. The diagnostic accuracy of CT scans in determining the degree of extraserosal invasion and identifying metastatic lymph nodes is still not satisfactory (Sussman, et al. 1988; Fukuya, et al. 1995; Adachi, et al. 1997; Seong, et al. 1988). Recent MR studies regarding the T staging of AGC suggest new possibilities to overcome these limitations of CT (Matsushita, et al. 1994; Oi, et al. 1997; Dux, et al. 1997; Costanzi, et al. 1996). A Japanese group reported high diagnostic accuracy (88% in T staging) from MRI in evaluating extraserosal invasion of AGC using a low signal intensity band on a gradient echo image, which was created by a chemical shift misregistration artifact and a phase cancellation artifact (Matsushita, et al. 1994). In an experimental study, Dux et al. (1997) described that MR staging of gastric cancer was technically possible (accuracy of T staging 65% and of N staging 80%), although they could not reproduce the results of the Japanese group. On the contrary, Costanzi et al. (1996) reported low accuracy of N staging (43%), induced by motion and respiratory artifacts and a long acquisition time. Such discrepancies in diagnostic accuracy of MR staging for gastric cancer are probably due to the variable imaging techniques and criteria of image interpretation.

Post contrast study of stomach show highly enhancement on gastric carcinoma and relatively well delineation of lesion and surrounding fat plain also well demonstrated (Figure 1). In case of serosal involvement of gastric carcinoma, there is fat obliteration of fat plain surrounding tumor (Figure 2).

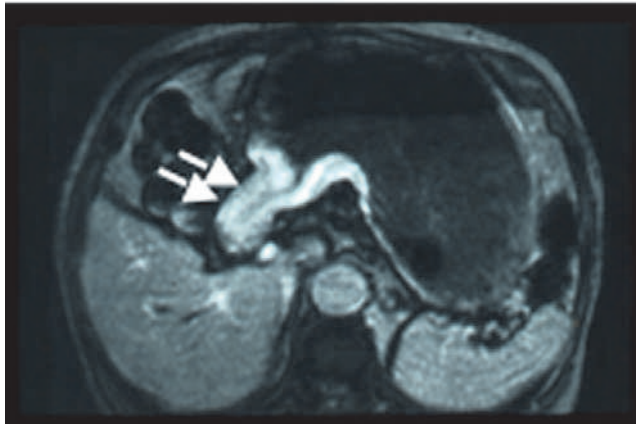

Fig. 1. T2 Gastric Carcinoma. 56-year-old man. Post contrast T1WI image show enhancement of the mass in stomach antrum and relatively preservation of surrounding fat plane (arrows).

Advanced gastric cancer presented as a thickened wall showing varied contrast enhancement from strong to minimal on MR imaging. According to Sohn et al. (2000) study, one of eight cases of early gastric cancer is detected on MR imaging. The tumor detection rate is 73.3% (22/30) on MR imaging. The overall accuracy of MR imaging for the T factor was 73.3% (22/30). On MR imaging, the incidence of under staging was 20% (6/30), whereas

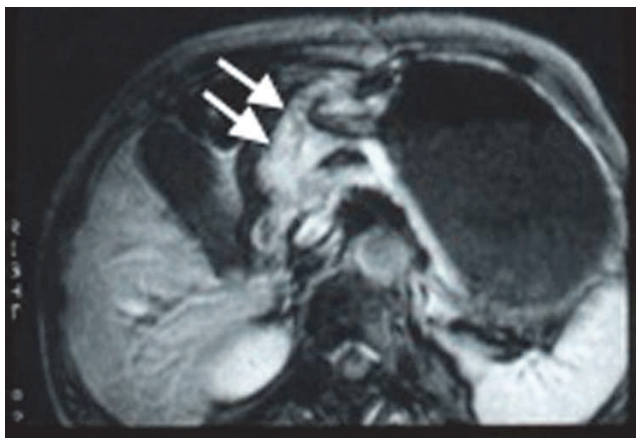


Fig. 2. T3 Gastric Carcinoma. 62-year-old woman. Post contrast T1WI show enhanced mass in stomach antrum and obliteration of pancreatic fat plane, but this case confirmed T3 gastric carcinoma without invasion of pancreas (arrows).

that of over staging was 6.7% (2/30). MR imaging is correct in 60% (18/30) of cases. The MR imaging findings are concordant with the pathologic findings for 87.5% (7/8) of pT1 tumors, 66.7% (2/3) of pT2 tumors, 78.6% (11/14) of pT3 tumors, and 40% (2/5) of pT4 tumors. One pT2 tumor is under staged as MRT1, two pT3 tumors are under staged as MRT2, and three of the pT4 tumors are under staged as MRT3. One pT1 tumor is over staged as MRT2, and one pT3 tumor is over staged as MRT4 (Figure 3). MR can delineate pancreatic invasion (Figure 4).

MR imaging showed the 80% detection rate of omental tumor infiltration. Peritoneal carcinomatosis is poorly delineated on MR imaging. Kim A et al. (2000) reported the study that comparative studies between MR and CT of gastric cancer. In this study, a markedly thickened wall considered as a cancerous lesion on MR images and in total T staging, MRI showed superior results to CT (81 vs. 73%).

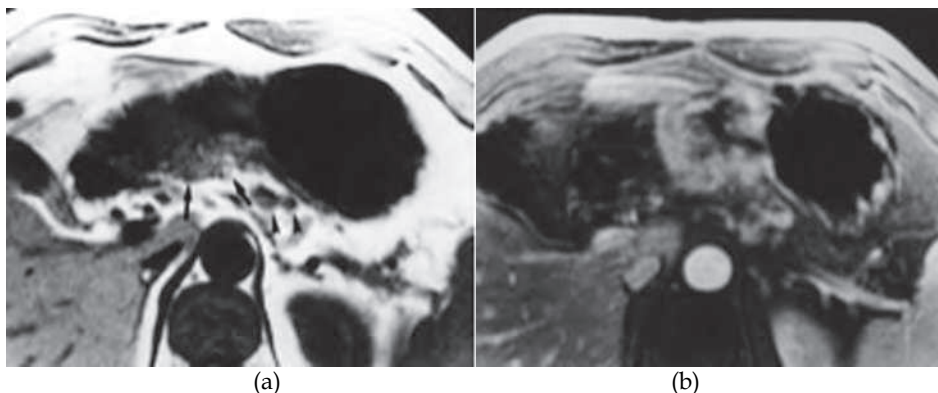


Fig. 3. T3 Gastric Carcinoma. 54-year-old man. A, B. Axial unenhanced (A) and contrast-enhanced (B) T1-weighted MR images show concentric tumor with strong contrast enhancement in gastric body. Extraluminal nodule of gastric tumor and infiltration in adjacent fat (arrows, A) are well seen on A. Note few enlarged lymph nodes in left perigastric region (arrowheads, A) (Sohn, et al. 2000).

According to Kim A et al. (2000) study, MRI was superior to CT in T staging (overall accuracy 81%;  $p < 0.005$ ). Several cases were overestimated with CT also in the present study, and they were mostly the pT2 cases. Six cases of pT2 were interpreted as T3 or T4 on CT scan due to the streaky densities in perigastric fat surrounding the gastric mass or due to the direct continuity between the gastric mass and the adjacent organs. This finding may have been induced by the partial volume-averaging effect of the angled gastric portion or by the associated perigastric inflammatory change (Sussman, et al. 1988; Minami, et al. 1992). Among these six patients, two were correctly diagnosed by MRI. This fact suggests that MRI can be potentially useful in providing multiplanar images and various pulse sequences compared with CT. Surgical resection clearly is the only potentially curative therapy for gastric cancer. Therefore, under any circumstances, there is no doubt that surgical resection is the best treatment of choice for patients with AGC whenever possible. In practice, accurate T staging can be less meaningful to surgeons when it is below T3 as the method of surgical resection does not change depending on the T stage (Siewert, et al. 1993). The differentiation between T3 and T4 is of more value to surgeons and patients prior to

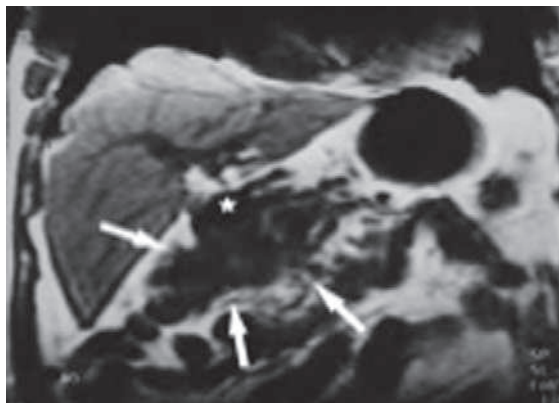


Fig. 4. T4 Gastric Carcinoma. 54-year-old woman. Coronal T1-weighted MR image shows matted appearance of gastric tumor, duodenal loop, and omentum of hepatic flexure of colon (MRT4) (*arrows*). These structures adhered to each other and were infiltrated by tumor, as noted at surgery (pT4). Star indicates pyloric antrum of stomach (Sohn, et al. 2000).

surgery. In Kim, A. et al (2000) study, unfortunately, cases with pathologic T4 were excluded because most patients who were diagnosed as T4 on preoperative imaging studies did not undergo surgery. Although Kim A et al. (2000) could not demonstrate the comparative data between the two imaging modalities in T4 staging, MRI seems to be superior to CT in T4 staging according to previously published data (diagnostic accuracy 75-80 vs. 58-75%) (Oi, et al. 1997; Dux, et al. 1997; Adachi, et al. 1997; Fukuya, et al. 1997; Cho, et al. 1994).

### 3.2.1 Signal intensity characteristics of normal gastric wall

Interest in the use of MRI for the staging of gastric carcinoma is increasing, but most clinical studies stage the local tumor situation without the differentiation of gastric wall layers (Sohn, et al. 2000; Goldberg & Thoeni. 1989; Halvorsen & Thomson. 1991; Campeau et al. 1995). Studies that use depiction of gastric wall layers as a basis for local tumor staging and lymph node metastasis are rare (Palmowski, et al. 2006; Dux, et al. 1997). The high quality of soft-tissue imaging of MR systems enables the depiction of anatomic wall layers. Auh et al. (1994) studied the gastric wall using an experimental 4.7-T system whereas Lubienski et al. (2002) used an experimental 2.4-T system. Both groups proved that the depiction of gastric-wall layers is technically possible. Auh et al. (1994) depicted 3 layers whereas Lubienski et al. (2002) was able to differentiate 4 layers and correlated them to the mucosa, lamina muscularis mucosa, submucosa and muscularis propria. Typically 3 gastric wall layers are visible. The inner layer corresponds to the mucosa and lamina muscularis mucosa and the middle layer to the submucosa. The outer layer showed the same SI as the muscularis propria in the study of Lubinski's et al. (2002) and therefore mainly consisted of muscle tissue and serosal layers. Palmowski et al. (2006) demonstrated that a reliable depiction of gastric-wall layers can be achieved by a conventional 1-T MRI. As no subserosa and serosa could be depicted, it must be presumed that they were located on the outer side of the third layer. So the third layer represented the muscularis propria, subserosa, and serosa together

(Palmowski, et al. 2006). Dux et al. (1997) proved that under experimental conditions, up to five layers of the gastric wall can be differentiated on MR imaging as they can in endoscopic sonography.

On MRI, two to three layers with different SI in the normal gastric wall can be depicted (Kim, I., et al. 2009). However, there was a mainly three-layered structure (multilayered pattern) of the gastric wall by MRI. The inner layer showed an increase of SI and was 1-3 mm thick on the T1-weighted images. The second had a lower SI with thickness that varied at different sites in the same individual. The outer layer showed a slightly higher SI. On T2-weighted images, the inner and outer layers regularly had a low SI, and the middle layer a high SI. On the basis of the comparison, these three layers were considered to correspond histologically to the mucosal, submucosal, and muscularis propria and serosal layers, respectively (Figure 5).

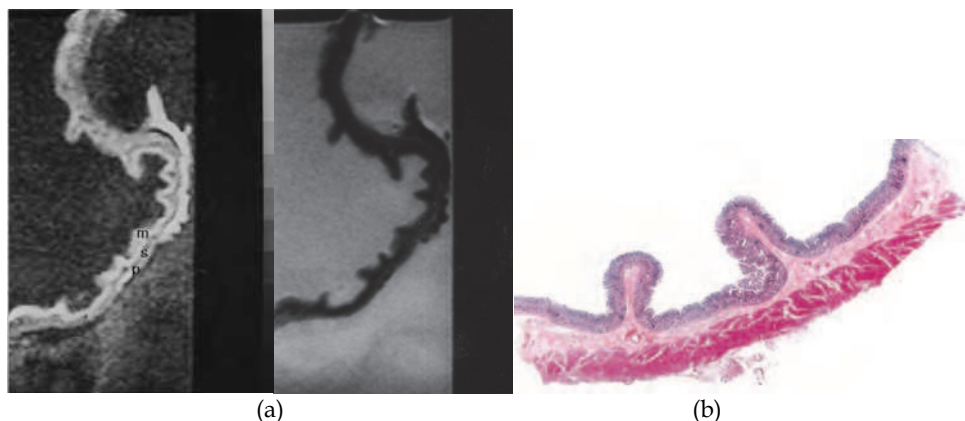


Fig. 5. MRI and Histology of Normal Gastric Wall. A: T1-weighted (500/20) sagittal image of resected gastric wall showed three layers. The inner layer corresponds to the mucosa (m) and the middle layer to the submucosa(s). The outer layer basically consists of the muscularis propria (p) from which the serosa cannot be differentiated; B: T2-weighted (2500/90) MR image showed low SI on mucosa and muscularis propria and relatively high SI on submucosa; C: Light microscopic section of normal gastric wall obtained from the greater curvature site of stomach body showed three layers which are compatible with inner mucosal layer, middle submucosa layer and outer muscularis propria and serosal layer (H-E stain; original magnification,  $\times 1$ ) (Kim, I., et al. 2009).

Kim I et al. (2009) reported that the inner and outer layers as hyperintense and the middle layer as hypointense at 1.5-MRI. When the three layers were depicted in the gastric wall, the mucosa and the muscularis propria were clearly different from the intervening submucosal layer on T1-weighted images. The distinction among the layers is based mainly on the lower SI of the submucosa compared with that of the mucosa or muscularis propria. The difference between the three layers was also depicted in the T2-weighted images.

### 3.2.2 Detection of primary tumor

MR imaging of gastric carcinoma on resected specimens studied by Kim I et al. (2009) showed as follows: two cases of Bormann's type 1 carcinoma (polypoid type), seven cases of Bormann's type 2 (ulcerative type), six cases of Bormann's type 3 (ulcerative type with



infiltration), and four cases of Borrmann's type 4 (infiltrating type). One case of early gastric carcinoma with type IIc was observed, whose lesion was seen as a depression of the mucosa with thinning of the gastric wall on axial and sagittal scanning (Figure 6). Gross pathologic findings showed tumor lesions as follows; two cases of Borrmann's type 1, four of Borrmann's type 2, nine of Borrmann's type 3, four of Borrmann's type 4. One case of early gastric carcinoma with type IIc was proved upon histologic examination. The accuracy of MR imaging in the Borrmann's type classification was 89% (16 of 19). Differentiation between Borrmann's type 2 and type 3 lesions was erroneous in three lesions.

The location of gastric carcinoma was also identified on the MR images. There were nine cases of gastric carcinoma involvement in the gastric antrum, three cases in the stomach body, seven cases in the antrum and the body, one case involving the entire stomach. Upon gross specimen examination, there was no difference between them and the MRIs.

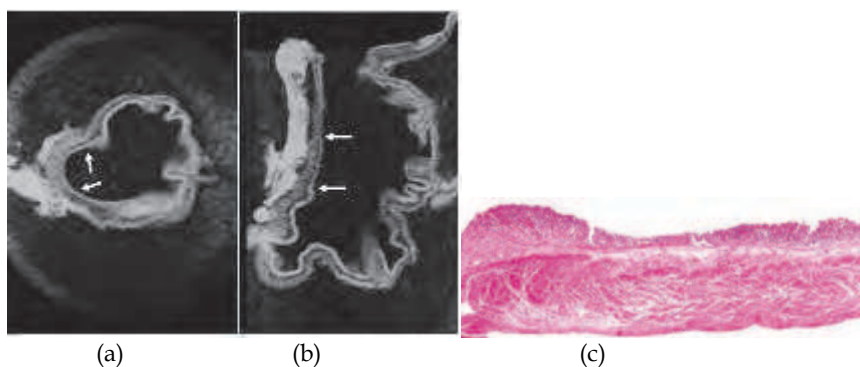


Fig. 6. MRI and Histology of Early Gastric Carcinoma. A: T1-weighted (500/20) axial image showed depression of gastric wall and obliteration of submucosal low SI (arrows); B: T1-weighted sagittal MR image showed depressed mucosa with tumor invasion to submucosa layer (arrows); C: Light microscopic section showed depressed mucosa with tumor invasion to submucosa (H-E stain; original magnification,  $\times 1$ ) (Kim, I., et al. 2009).

### 3.2.3 Depth of tumor invasion

According to Kim I et al. (2009) study, MRIs of gastric carcinoma in resected specimens showed various findings, including thickening of the gastric wall with irregularity in the mucosal SI obliteration, thickening of the gastric wall with first and second layer SI obliteration, diffuse thickening of the gastric wall with third layer SI obliteration and irregularity with ulceration as well.

T1-weighted images showed intermediate SI in regions affected by gastric carcinoma compared to the surrounding normal mucosa and muscularis propria SI. T2-weighted images showed low SI in the gastric carcinoma. Most tumors had a homogenous SI. However, in some cases necrosis and calcification caused an inhomogeneous SI. It is not possible to differentiate between the muscularis propria, subserosa, and serosa. The reason for this inability was that Kim I et al. (2009) considered the subserosa and serosa as being located on the outer border of the joint layer representing the muscularis propria, subserosa, and serosa. If an infiltration was visible, the tumor was classified as T2 as long as it did not reach the outer border. Penetration of the external margin meant at once infiltration of the

serosa, and the tumor was staged as a T3 carcinoma, according to the AJCC (2002). The MR imaging findings of gastric wall invasion included 1 case of T1, 7 of T2 (Figure 7), and 11 of T3 (Figure 8). Pathologic results of resected specimens included 3 cases of pT1, 4 of pT2, and 12 of pT3. Differentiation between T1 and T2 classifications was not difficult in cases displaying a distinction between three layers. However, two cases of pT1 were over staged as T2. One case of pT2 was over staged as T3. Two cases of pT3 were under staged as T2. Differentiation between T2 and T3 lesions was difficult due to the outer muscularis propria and serosal layer's thinness and could not always be demonstrated by MRIs. The level of accuracy in determining the T factor according to the TNM classification was 74% (14 of 19 lesions).

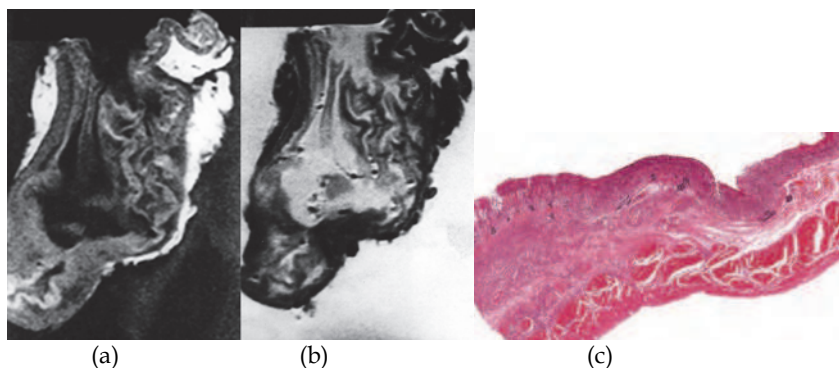


Fig. 7. MRI and Histology of T2 Gastric Carcinoma. A: T1-weighted (500/20) sagittal image showed diffuse thickening of gastric wall with obliteration of mucosa, submucosa and muscularis propria SI in antrum and lower body, while preserved outer marginal SI; B: T2-weighted (2000/90) sagittal MR images showed ill defined lesion with minimal increased and same SI compared to surrounding normal gastric wall; C: Light microscopic section demonstrate proper muscle invasion of gastric cancer (H-E stain; original magnification,  $\times 1$ ) (Kim, I., et al. 2009).

Palmowski et al. (2006) reported that carcinomas show an intermediate SI on T1-weighted images, a low SI on T2-weighted images and a high SI on opposed phase images. Opposed phase images were not obtained in Kim I et al. (2009) study, but Dux et al. (1997) demonstrated that opposed phase images show a very high SI in gastric tumors and insisted that this was useful for the staging of gastric carcinoma. In Kim I et al. (2009) study, the infiltration of gastric carcinoma was correctly defined in 74% of the cases. This was not different from that of CT images that had an accuracy rate of 50%-85% and that of MR images that had an accuracy rate of 73% (Sohn, et al. 2000; Botet, et al. 1991; Kim, A., et al. 2000). Yamada et al. (2001) reported that gastric specimens that were imaged after fixation in formalin and then MR imaged could also depict early gastric carcinoma.

Kim I et al. (2009) demonstrate that the inner and outer layers as hyperintense and the middle layer as hypointense at 1.5-MRI. When the three layers were depicted in the gastric wall, the mucosa and the muscularis propria were clearly different from the intervening submucosal layer on T1-weighted images. The distinction among the layers is based mainly on the lower SI of the submucosa compared with that of the mucosa or muscularis propria. The difference between the three layers was also depicted in the T2-weighted images. In this

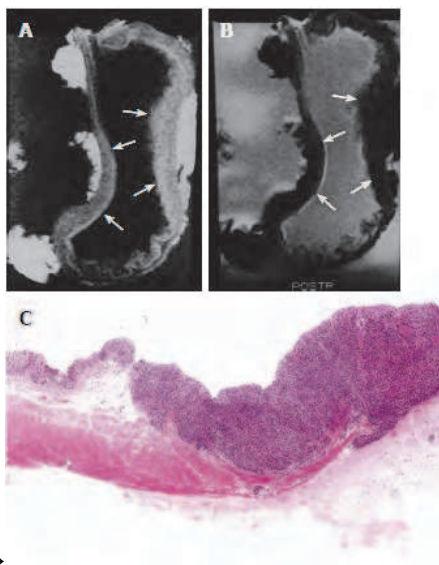


Fig. 8. MRI and Histology of T3 Gastric Carcinoma. A: T1-weighted (500/20) sagittal image showed thickening of gastric wall with all three layer SI change in lesser and greater curvature site of stomach body (arrows); B: T2-weighted (2000/90) sagittal MRI showed minimal increase of SI on lesion site and poor delineation of gastric wall SI at out layer margin compared to normal gastric wall (arrows); C: Light microscopic section showed extension of tumor invasion to serosal layer (HE stain; original magnification,  $\times 1$ ) (Kim, I., et al. 2009) .

study, gastric carcinomas appeared as masses with destruction of the normal structure of the gastric wall or diffuse thickening of the gastric wall and showed intermediate SI compared to surrounding normal gastric walls on T1-weighted images and low SI on T2-weighted images. Both sequences were useful for tumor localization and complement each other because some carcinomas in the study could only be recognized by deviating signal behavior in one of the 2 sequences. In Kim I, et al. (2009) study, signal characteristics of the carcinoma depending on the MR sequence were not analyzed. In this study, one case of early gastric carcinoma was depicted on MRI with a shallow depressed wall. This was made possible by adequate distention of the resected stomach with saline.

CT is the most frequently used imaging technique for the staging of gastric cancer. Cho et al. (1994) and Fukuya et al. (1997) studied using dynamic or helical CT and reported that the normal gastric wall frequently showed a two- or three-layer pattern that was interrupted by a tumor; thus, more accurate staging of the T factor could be expected. In addition, the use of thin collimation ( $\leq 5$  mm) could improve the depiction of small lesions and make it possible to obtain multiplanar reformatted images. However, it still is difficult for helical CT to differentiate between a pT2 tumor and a pT1 tumor with massive submucosal invasion because the hypoattenuating stripe corresponding to the intact submucosal layer could be obliterated in the latter (Fukuya, et al. 1997). Sohn et al. (2000) also experienced a case of a pT2 tumor with minimal invasion of the muscularis propria layer, which showed focal wall thickening with preservation of the hypoattenuating stripe. In this study, advanced gastric

cancer was easily detectable on both MR imaging and helical CT; however, the incidence of detectability of early gastric cancer was low on both techniques. MR imaging was slightly more accurate than helical CT in the T staging of gastric cancer, but this difference was not statistically significant ( $p > 0.05$ ). MR imaging and helical CT showed understaging more frequently than overstaging because of the frequent understaging of pT4 tumors. The low concordance rates of pT4 tumors on MR imaging and helical CT were partly caused by the fact that patients with evident CTT4 or MRT4 tumors did not undergo surgery and therefore were not included in this study. Also, invasion into the transverse mesocolon was difficult to detect. Under normal conditions, the transverse mesocolon can be identified on CT scans and MR images as the fatty plane extending from the pancreas to the transverse colon. However, cachexia and a distended stomach frequently efface this fatty plane in patients with advanced gastric cancer, thereby hindering proper evaluation. For pancreatic invasion, the accuracy was the same for both techniques; however, the number of cases of pancreatic invasion ( $n = 2$ ) was too small to analyze in this study. Lee et al. (1994) suggested the superiority of MR imaging over CT because the difference in signal intensity of the stomach and pancreas could make the detection of tumor invasion into the pancreas easier on MR images. However, further study is needed to evaluate the usefulness of MR imaging for this purpose. Early or miliary peritoneal carcinomatosis without ascites was difficult to detect preoperatively, but omental infiltration was easily detected on both MR imaging and helical CT in most (80%) (Sohn, et al. 2000). Generally, MR imaging is a powerful imaging tool with its high soft-tissue contrast, multiplanar imaging capability and ability to provide biochemical and anatomic information, technical versatility for sequence selection and modification, and its lack of ionizing radiation. However, excessive motion artifacts resulting from a combination of long imaging time and physiologic motion such as respiration, peristalsis, and cardiovascular pulsation, have made MR imaging unsuitable for the staging of gastric cancer. The recent development of fast imaging techniques with breath-hold sequences has allowed rapid data acquisition, thereby reducing the problem of motion artifacts. Additionally, the use of phased array coils has increased the signal-to-noise ratio and the spatial resolution in abdominal MR images. Many kinds of oral contrast agents distend the stomach for MR imaging, and these can be divided into positive (producing high signal intensity on T1- and T2-weighted images), negative (producing low signal intensity on T1- and T2-weighted images), and biphasic (producing opposite signal intensities on T1- and T2- weighted images) contrast agents (Halvorsen, et al. 1996).

## 4. Imaging findings of regional lymph nodes

### 4.1 Metastasis to regional lymph nodes

Clinically, N staging appears to be a more significant factor than T staging in determining the type of surgery to be performed and in predicting the patient's prognosis (Belcastro, et al. 1990). In AGC, the importance of noting the nodal stage N2 and differentiating it from the N1 stage is well known. This is because N2 nodes are not routinely removed at surgery and, as a result, are the causes of a large number of treatment failures following surgery (Levine & Megibow. 1994). Nevertheless, there has been no consensus until now as to how to measure lymph nodes (short or long axis) or the size that should be considered pathologic (Trenkner, et al. 1994). Wide ranges of sensitivity (48-91%) have been reported for nodal staging with CT (Sussman, et al. 1988; Botet, et al. 1991; Dehn, et al. 1984; Triller, et al. 1986). Fukuya et al. (1995) suggested that diagnosing lymphadenopathy is problematic for nodes of <14 mm in size: 87.2% were negative for metastases. Hence, they used a size criterion of 15

mm for positive metastatic lymph nodes. However, application of the 15 mm criterion can produce high specificity but can induce low sensitivity in N staging. 8 mm at the short axis of lymph node used as the size criterion (Dorfman, et al. 1991), and the N staging accuracy of spiral CT was slightly superior to that of MRI in Kim A et al. (2000) study ( $p > 0.05$ ). The relatively inferior N staging results of MRI to those of CT were related to a low detection rate of small-sized lymph nodes, as reported by Dux et al. (1997). The accuracy of CT in T and N staging of AGC was also variable in several reports (Cho, et al. 1994; Ziegler, et al. 1993; Minami, et al. 1992) and ranged from 73.1 to 83% in T staging and from 51 to 70% in N staging. According to these reports, CT has a tendency to overestimate T stage and underestimate N stage. Understaging occurs because it is difficult to identify fine metastases including peritoneal carcinomatosis, whereas overstaging occurs due to the obliteration of fat plane between the gastric lesion and adjacent organs, which is known to be an unreliable sign suggesting invasion of the adjacent structure. MR imaging correctly revealed regional lymph node involvement in 55% (16/29), understaged 34.5% (10/29), and overstaged 10% (3/29) according by Sohn et al. (2000). There is no significant difference between MR imaging and helical CT in the staging of regional lymph node metastasis. Lymph nodes showed a high SI on opposed phased images (Dux, et al. 1997). MRI had low rate in depicting lymph node metastasis, with an accuracy of 47%. MRI can reliably depict several anatomical layers of the gastric wall and also MRI of gastric carcinoma could enable accurate diagnosis of location, gross appearance, degree of gastric wall invasion of the tumors and delineation of regional lymph node metastasis. A clear image of the tumor can be achieved. Therefore, an evaluation of the local tumor stage of gastric carcinoma and Sohn et al. (2000) assumed that MR multiplanar imaging would be more accurate in nodal staging than helical CT with only axial images, but with a relative lack of experience and unfamiliarity with MR anatomy in coronal and sagittal images for lymph node detection, he could not prove the superiority of MR imaging over helical CT in nodal staging. Sohn et al. (2000) also considered the detectability of lymph node metastases would be improved by radiologists having more experience with interpretation of coronal and sagittal MR images. The detection rate of lymph node metastasis was low for both techniques. The low detection rate was due to frequent microscopic nodal invasion and the fact that reactive or inflammatory nodal enlargement could not be differentiated from metastatic nodal enlargement on MR imaging or helical CT. An accurate assessment of metastatic lymph nodes was difficult when they were grouped together or attached to a gastric mass. Though an exophytic tumor growth can sometimes mimic a regional lymph node metastasis on axial helical CT, coronal or sagittal MR imaging can easily differentiate them. Perigastric lymph node metastasis based on morphologic criteria is technically possible. Therefore, the additional application of signal intensity as a pathologic lymph node criterion or additional pulse sequences such as Gd-enhanced, breath-hold gradient echo images with fat suppression or breath-hold short T1 inversion recovery (STIR) images could be helpful in improving N staging with MRI.

#### **4.2 Regional lymph node metastasis of resected stomach**

According to Kim I et al. (2009) study, the lymph nodes presented with intermediate SI on T1-weighted images, intermediate SI on T2-weighted images. The sizes were measured as being from 0.35 cm to 3.5 cm on MR imaging (Figure 9, 10). The accuracy of N staging by MRI was 47%.

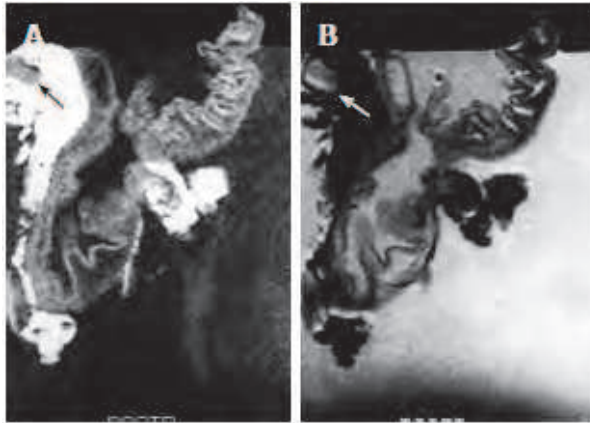


Fig. 9. MRI of N1 Gastric Carcinoma. A: T1-weighted (500/20) MR image showed single lymph node on lesser curvature site of stomach body (Arrow); B: T2-weighted (2000/90) MRI showed intermediated signal SI of lymph node (arrow) (Kim, I., et al. 2009).

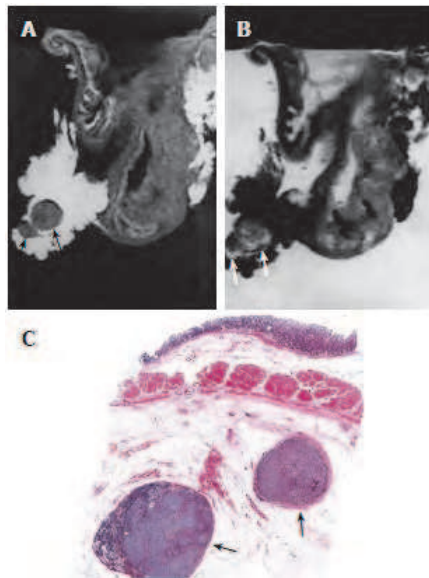


Fig. 10. MRI and Histology of N2 Gastric Carcinoma. A: T1-weighted (500/20) MRI showed two lymph nodes in lesser curvature site of stomach antrum (arrows). Eight lymph nodes are detected in total in perigastric area (not shown); B: T2-weighted (2000/90) MRI showed intermediate SI in the lymph nodes (arrows); C: Light microscopic section showed two lymph nodes in lesser curvature site of gastric antrum (arrows) (HE stain; original magnification,  $\times 1$ ) (Kim, I., et al. 2009).

MRI in combination with standard sequences demonstrated the potential of MRI in the staging of gastric carcinomas. Although the result obtained in N-staging was not acceptable, it should be explored further. However, there could be shown not only MR findings of gastric wall invasion but also perigastric lymph node involvement in the gastric carcinoma. MRI is useful for staging of T staging of gastric cancer, whereas MRI has shown some limitations in N staging. MRI can not completely replace spiral CT in staging AGC at the present time. However, MRI can be potentially useful as an alternative method of staging gastric cancer in that it provides multiplanar images. The evaluation of lymph node metastasis on MRIs had some limitation (Kim, I., et al. 2009), since the size criteria was used only on MRIs and there was no trial of contrast enhancement because of *in vitro* study of gastric carcinoma. Lymph node borders and signal intensity were not also evaluated for diagnosis of lymph node metastasis. But some cases of lymph nodes showed intermediate SI on T1 and T2-weighted images in the tumor infiltration region and this was correctly correlated with the histology. According to Dux et al. (1997) study, lymph nodes showed a high SI on opposed phased images. MRI had low rate in depicting lymph node metastasis, with an accuracy of 47 %. However, the result was similar to the other reports (Yamada, et al. 2001). MRI can reliably depict several anatomical layers of the gastric wall and also MRI of gastric carcinoma could enable accurate diagnosis of location, gross appearance, degree of gastric wall invasion of the tumors and delineation of regional lymph node metastasis. A clear image of the tumor can be achieved.

## 5. Discussion

Gastric carcinomas show an intermediate SI on T1-weighted images, a low SI on T2-weighted images and a high SI on opposed phase images (Palmowski, et al. 2006). Opposed phase images show a very high SI in gastric tumors and insisted that this was useful for the staging of gastric carcinoma (Dux, et al. 1997) and demonstrate that the infiltration of gastric carcinoma was correctly defined in 74% of the cases. Cho et al. (1994) and Fukuya et al. (1997) studied using dynamic or helical CT and reported that the normal gastric wall frequently showed a two- or three-layer pattern that was interrupted by a tumor; thus, more accurate staging of the T factor could be expected. In addition, the use of thin collimation ( $\leq 5$  mm) could improve the depiction of small lesions and make it possible to obtain multiplanar reformatted images. However, it still is difficult for helical CT to differentiate between a pT2 tumor and a pT1 tumor with massive submucosal invasion because the hypoattenuating stripe corresponding to the intact submucosal layer could be obliterated in the latter. Sohn et al. (2000) also experienced a case of a pT2 tumor with minimal invasion of the muscularis propria layer, which showed focal wall thickening with preservation of the hypoattenuating stripe. Sohn et al. (2000) demonstrated that advanced gastric carcinoma was easily detectable on both MR imaging and helical CT; however, the incidence of detectability of early gastric cancer was low on both techniques. MR imaging was slightly more accurate than helical CT in the T staging of gastric cancer, but this difference was not statistically significant ( $p > 0.05$ ).

The evaluation of lymph node metastasis on MRIs had some limitation, since the size criteria was used only on MRIs and there was no trial of contrast enhancement because of *in vitro* study of gastric carcinoma. Lymph node borders and signal intensity were not also evaluated for diagnosis of lymph node metastasis. But some cases of lymph nodes showed intermediate SI on T1 and T2-weighted images in the tumor infiltration region and this was

correctly correlated with the histology. MRI can be shown gastric wall invasion but also perigastric lymph node involvement in the gastric carcinoma. Advances in the variation of sequence techniques, as well as application of ultrafast imaging techniques, may be more useful preoperative staging of gastric carcinomas by MRI. MR imaging could be a useful alternative to helical CT because of its high resolution of soft tissue, its multiplanar imaging capability, and its lack of ionizing radiation. In addition, MR imaging could be useful for patients who cannot undergo CT because of renal impairment, pregnancy, or hypersensitivity to CT contrast materials.

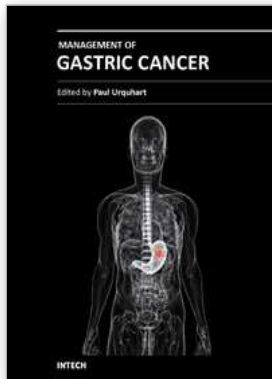
## 6. References

- Adachi, Y., Sakino, I., Matusmata, T., & et al (1997). Preoperative assessment of advanced gastric carcinoma using computed tomography. *Am J Gastroenterol* 1997; 92:872-880. Bibliographic Links.
- American Joint Committee on Cancer (2002). *Cancer staging handbook*. Philadelphia, Pa: Springer-Verlag, 2002.
- Auh, Y., Lim, T., Lee, D., Kim, Y., Lee, M., Cho, K., Mun, C., & Lee, I. (1994). In vitro MR imaging of the resected stomach with a 4.7-T superconducting magnet. *Radiology* 1994; 191: 129-134.
- Belcastro, G., Nicolanti, V., Ferri, M., Chiavellati, L., Fratticioli, C., & Schillaci, A. (1990). Prognostic factors in stomach cancer: invasion of gastric serosa and lymph node involvement [Italian]. *Minerva Chir* 1990; 45:1287-1291.
- Botet, J., Lightdale, C., Zauber, A., Gerdes, H., Urmacher, C., Brennan, M.(1991). Preoperative staging of gastric cancer: comparison of endoscopic US and dynamic CT. *Radiology* 1991; 181:426-432. Bibliographic Links
- Campeau, N., Johnson, C., Felmlee, J., Rydberg, J., Butts, R., Ehman, R., & et al (1995). MR imaging of the abdomen with a phased-array multicoil: prospective clinical evaluation. *Radiology* 1995; 195:769-776. PMID: 7754009.
- Cho, J., Kim, J., Rho, S., Lee, H., Jeong, H., & Lee, C. (1994). Preoperative assessment of gastric carcinoma: value of two-phase dynamic CT with mechanical injection of contrast material. *AJR* 1994; 163:69-75.
- Costanzi, A., Di Cesare, E., Guadagni, S., Masciocchi, C., De Bernardinis, G., & Maurizi Enrici, R. (1996). Gastric adenocarcinoma: magnetic resonance versus surgical staging. *Radiol Med* 1996; 92:726-730.
- Dehn, T., Reznick, R., Nockler, I., & White, F. (1984). The pre-operative assessment of advanced gastric cancer by computed tomography. *Br J Surg* 1984; 71:413-427.
- Dorfman, R., Alpern, M., Gross, B., & Sandler, M.A. (1991). Upper abdominal lymph nodes: criteria for normal size determined with CT. *Radiology* 1991; 180:319-322.
- Douglass, H., & Nava, H.R. (1985). Gastric adenocarcinoma-- management of the primary disease. *Semin Oncol* 1985; 12: 32-45.
- Dux, M., Roeren, T., Kuntz, C., Richter G.M., & Kauffmann G. W. (1997). MRI for staging of gastric carcinoma: first results of an experimental prospective study. *J Comput Assist Tomogr* 1997; 21:66-73.
- Fukuya, T., Hiroshi, H., Hayashi, T., & et al (1995). Lymph-node metastases: efficacy of detection with helical CT in patients with gastric cancer. *Radiology* 1995; 197:705-711. Bibliographic Links.



- Fukuya, T., Hiroshi, H., Kaneko, K., & et al (1997). Efficacy of helical CT in T staging of gastric cancer. *J Comput Assist Tomogr* 1997; 21:73-81. Ovid Full Text Request Permissions.
- Goldberg, H.I., & Thoeni, R.F. (1989). MRI of the gastrointestinal tract. *Radiol Clin North Am* 1989; 27:805-812.
- Hahn, P.F., Stark D.D., & Glastad, K.(1992). Biliary system, pancreas, spleen, and alimentary tract. In: Stark DD, Bradley WG Jr, eds. *Magnetic resonance imaging*, 2nd ed. St. Louis: Mosby, 1992:1.
- Halvorsen, R., & Thompson, W.M. (1991). Primary neoplasm of the hollow organs of the gastrointestinal tract: staging and follow up. *Cancer* 1991; 67: 1181-1188. PMID: 1991278.
- Halvorsen, R., Yee, J., & McCormick, V.D. (1996). Diagnosis and staging of gastric carcinoma. *Semin Oncol* 1996; 23:325-335.
- Kajitani, T. (1981). The general rules for the gastric cancer study in surgery and pathology. Part I. Clinical classification. *Jpn J Surg* 1981; 11: 127-139.
- Kim, A.Y., Han, J.K., Kim, T.K., Park, S.J., & Choi, B.I. (2000). MR imaging of advanced gastric cancer: comparison of various MR pulse sequences using water and gadopentetate dimeglumine as oral contrast agents. *Abdom Imag* 2000; 25:7-13.
- Kim, A.Y., Han, J.K., Seong, C.K., Kim, T.K., & Choi, B.I. (2000). MRI in staging advanced gastric cancer: is it useful compared with spiral CT? *J Comput Assist Tomogr* 2000; 24: 389-394.
- Kim, I., Kim, S.W., Shin, H.C., Lee, M.S., Jeong D.J., Kim. C. J., & Kim, Y. T. (2009). MRI of gastric carcinoma: Results of T and N-sting in an in vitro study. *World J Gastroentrol* 2009; 15: 3992-3998.
- Lee, J.M., Kim, C.Y., Chun, K.A., Kim, H.S, & Shinn, K.S. (1994). MR imaging of gastric carcinoma: comparison with CT. *J Korean Radiol Soc* 1994; 31:287-294.
- Levine, M.S., & Megibow, A.C. (1994). Gastric cancer. In: Gore RM, Levine MS, Laufer I, eds. *Textbook of gastrointestinal radiology*. Philadelphia: Saunders, 1994: 660-683.
- Matsushita, M., Oi, H., Murakami, T., & et al. (1994). Extraserosal invasion in advanced gastric cancer: evaluation with MR imaging. *Radiology* 1994; 192:87-91. Bibliographic Links.
- Minami, M., Kawauchi, N., Itai, Y., Niki, T., & Sasaki, Y. (1992). Gastric tumors: radiologic-pathologic correlation and accuracy of T staging with dynamic CT. *Radiology* 1992; 185:173-178. Bibliographic Links.
- Oi, H., Mutsushita, M., Murakami, T., & Nakamura, H. (1997). Dynamic MR imaging for extraserosal invasion of advanced gastric cancer. *Abdom Imag* 1997; 22:35-40. Bibliographic Links.
- Palmowski, M., Grenacher, L., Kuntz, C., Heye, T., & Dux, M. (2006). Magnetic resonance imaging for local staging of gastric carcinoma: results of an in vitro study. *J Comput Assist Tomogr* 2006; 30: 896-902.
- Seong, C., Kim, A., Kim, T.K., Song, C., Han, J., & Choi, B. (1998). MR imaging of advanced gastric cancer: comparison between T1-weighted FLASH, T2-weighted TSE, and trueFISP [Korean; English abstract]. *J Korean Radiol Soc* 1998; 39:1149-1156.
- Siewert, J., Bottcher, K., Roder, J.D., Busch, R., Hermanek, P., & Meyer, H.J. (1993). Prognostic relevance of systematic lymph node dissection in gastric carcinoma. German Gastric Carcinoma Study Group. *Br J Surg* 1993; 80:1015-1058.

- Sohn, K.M., Lee, J.M., Lee, S.Y., Ahn, B.Y., Park, S.M., & Kim, K.M. (2000). Comparing MR imaging and CT in the staging of gastric carcinoma. *AJR Am J Roentgenol* 2000; 174: 1551-1557.
- Sussman, S.K., Halvorsen, R.A., Illescas, F.F., Cohn R. H., Saeed M, Silverman P. M. & et al (1988). Gastric adenocarcinoma: CT versus surgical staging. *Radiology* 1988; 167:335-340.
- Trenkner, S.W., Halvorsen, R.A., & Thompson, W.M. (1994). Neoplasms of the upper gastrointestinal tract. *Radiol Clin North Am* 1994; 32:15-24.
- Triller, J., Roder, R., Stafford, A., & Schroder, R. (1986). CT in advanced gastric carcinoma: is exploratory laparotomy avoidable? *Eur J Radiol* 1986; 6:181-186.
- Werthmuller, W.C., & Margulis, A.R. (1991). Magnetic resonance imaging of the alimentary tube. *Invest Radiol* 1991; 26:195-200.
- Yamada, I., Saito, N., Takeshita, K., Yoshino, N., Tetsumura, A., Kumagai, J., & Shibuya, H. (2001). Early gastric carcinoma: evaluation with high-spatial-resolution MR imaging in vitro. *Radiology* 2001; 220: 115-121.
- Ziegler, K., Sanft, C., Zimmer, T., & et al (1993). Comparison of computed tomography, endoscopy, and intraoperative assessment in TN staging of gastric carcinoma. *Gut* 1993; 34:604-610.



## Management of Gastric Cancer

Edited by Dr Nabil Ismaili

ISBN 978-953-307-344-6

Hard cover, 146 pages

**Publisher** InTech

**Published online** 18, July, 2011

**Published in print edition** July, 2011

Gastric cancer is the fifth most common cancer and the second most common cause of cancer death worldwide. More than 50% of the patients have advanced disease at diagnosis and in this case the disease has a poor outcome. The staging of gastric cancers is based on endoscopic ultrasound, computed tomography, magnetic resonance imaging, positron emission tomography, in addition to the laparoscopic staging. Many improvements in the surgical techniques have been seen in the last decade. Laparoscopic surgery is an emerging approach which offers important advantages: less blood loss, reduced postoperative pain, accelerated recovery, early return to normal bowel function and reduced hospital stay. D1 lymphadenectomy, with a goal of examining 15 or greater lymph nodes is a standard. D2 dissection is considered as a standard in several institutions especially in eastern Asia. Perioperative chemotherapy and adjuvant concurrent radiochemotherapy are recognized as standards treatments. Palliative chemotherapy is the mainstay treatment of advanced stages of the disease (metastatic and non-operable tumors). Despite these treatment advances, the prognosis of gastric cancer remains poor with a 5-year survival ranging from 10 to 15% in all stages combined.

### How to reference

In order to correctly reference this scholarly work, feel free to copy and paste the following:

Il Young Kim (2011). MR Imaging of Gastric Carcinoma, Management of Gastric Cancer, Dr Nabil Ismaili (Ed.), ISBN: 978-953-307-344-6, InTech, Available from: <http://www.intechopen.com/books/management-of-gastric-cancer/mr-imaging-of-gastric-carcinoma>

**INTECH**  
open science | open minds

### InTech Europe

University Campus STeP Ri  
Slavka Krautzeka 83/A  
51000 Rijeka, Croatia  
Phone: +385 (51) 770 447  
Fax: +385 (51) 686 166  
[www.intechopen.com](http://www.intechopen.com)

### InTech China

Unit 405, Office Block, Hotel Equatorial Shanghai  
No.65, Yan An Road (West), Shanghai, 200040, China  
中国上海市延安西路65号上海国际贵都大饭店办公楼405单元  
Phone: +86-21-62489820  
Fax: +86-21-62489821

© 2011 The Author(s). Licensee IntechOpen. This chapter is distributed under the terms of the [Creative Commons Attribution-NonCommercial-ShareAlike-3.0 License](#), which permits use, distribution and reproduction for non-commercial purposes, provided the original is properly cited and derivative works building on this content are distributed under the same license.