

# We are IntechOpen, the world's leading publisher of Open Access books Built by scientists, for scientists

6,900

Open access books available

186,000

International authors and editors

200M

Downloads

Our authors are among the

154

Countries delivered to

TOP 1%

most cited scientists

12.2%

Contributors from top 500 universities



WEB OF SCIENCE™

Selection of our books indexed in the Book Citation Index  
in Web of Science™ Core Collection (BKCI)

Interested in publishing with us?  
Contact [book.department@intechopen.com](mailto:book.department@intechopen.com)

Numbers displayed above are based on latest data collected.  
For more information visit [www.intechopen.com](http://www.intechopen.com)



---

# Minimally Invasive Face and Neck Lift Using Silhouette Coned Sutures

---

Peter Prendergast

Additional information is available at the end of the chapter

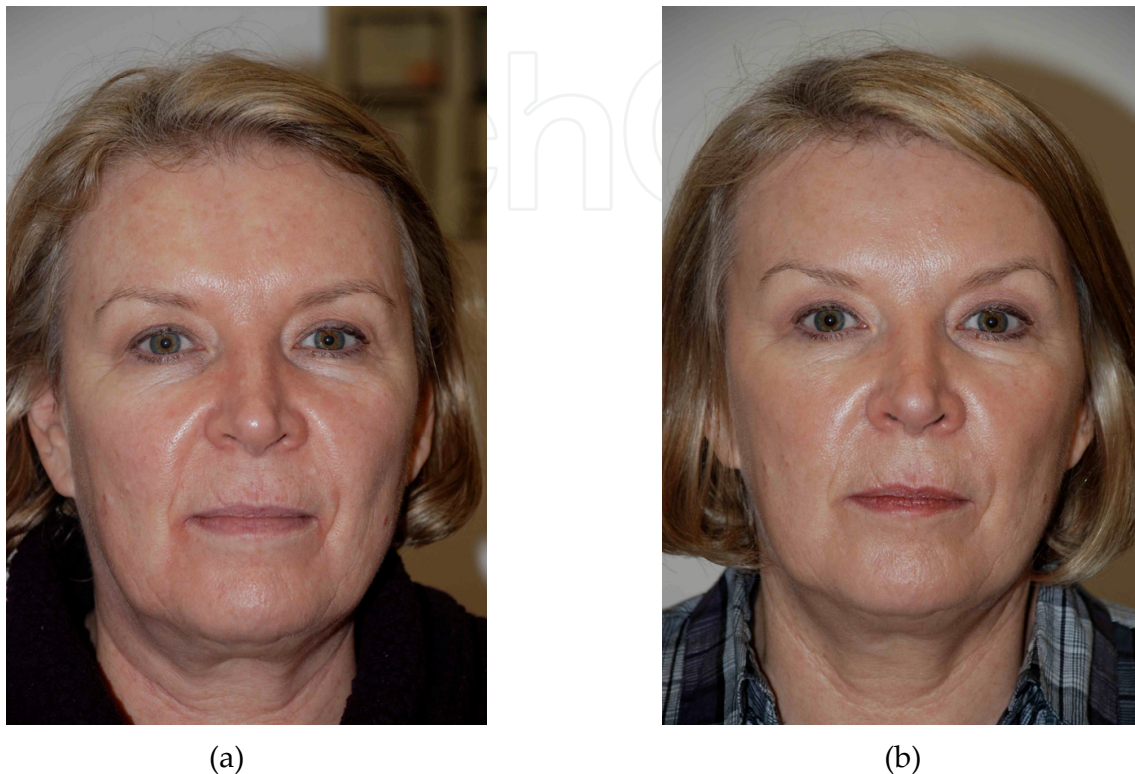<http://dx.doi.org/10.5772/51677>

---

## 1. Introduction

Over the last decade, the number of patients opting for minimally invasive procedures has increased [1]. In the US, noninvasive cosmetic procedures have increased by more than 350% since 1997, compared to about 70% for cosmetic surgical procedures. Although open facelift is still indicated for patients who have moderate or severe ptosis of the lower face and neck, younger patients with mild ptosis and patients who do not want to undergo open surgery or general anaesthesia are often suitable candidates for suture or thread lift techniques. Patients favour minimally invasive procedures because they are quick, relatively inexpensive, and do not require prolonged recovery time. Additionally, less invasive procedures typically produce less dramatic results compared to excisional surgery, so the result is subtle and natural looking (Fig.1). Although the story of barbed sutures probably began with Alcamo's design of a roughened suture in 1956, the concept of lifting the face or neck through minimal incisions or punctures using sutures or threads is relatively new. Buncke, a microsurgeon, referred to "facelifts and other cosmetic operations where the sutures would provide lines of tissue support beneath the skin" [2]. Following this, various sutures using different materials, morphologies, and designs were developed by surgeons in USA, Russia, Bulgaria, and elsewhere. Isse, an American surgeon, initially embraced the idea of using barbed sutures to lift soft tissues. He developed the Isse Endo Progressive Facelift Suture, a barbed suture similar to the sutures developed in Moscow by Sulamanidze, and Singapore by Wu. He later abandoned this design in favour of a novel approach—using cones instead of barbs to spear subcutaneous tissues. Isse designed these so-called Silhouette sutures for a number of reasons. He felt that the morphology of the cones or 'trumpets' along the suture would have superior holding power compared to barbs. He also believed that using cones made of an absorbable material (poly lactide) would incite an inflammatory reaction that would in turn stimulate neocollagenesis around the cones and potentially provide a longer lasting effect. Silhouette sutures are now FDA

approved and distributed worldwide. The author utilizes these sutures for minimally invasive lifting of the brow, midface, and neck. The procedure is performed in an office setting under local anaesthesia without sedation. This chapter details the Silhouette suture morphology, important anatomy, indications, technique, and potential complications.

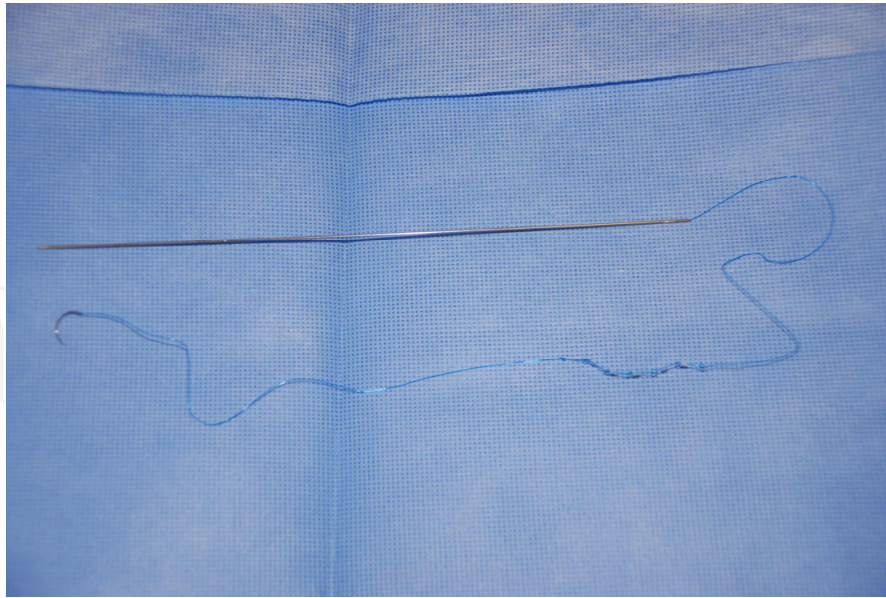


**Figure 1.** a Before, b After Silhouette suture lift. With kind permission from Springer Science+Business Media: Aesthetic Medicine. Art and Techniques, Suture lifting techniques, 2011, p.413, P.M. Prendergast, fig. 34.15.

## 2. Silhouette suture morphology

The Silhouette suture consists of a dyed polypropylene suture with six regularly spaced transparent cones or trumpets along its length. There is a 20.3cm 20 gauge straight blunt-tipped needle swaged to the distal end of the suture and a 26mm half-circle needle to the proximal end. The cones are made of absorbable poly-L-lactic acid and are held on the suture by six regularly spaced knots (Fig. 2).

As the sutures are inserted the cones slide proximally and cover the knots. When the proximal end of the suture is retracted, the cones slide distally as they purchase on the tissues, and are held on the sutures by the more distally placed knots. Included with Silhouette sutures are 2 x 0.5cm polypropylene mesh patches for anchorage to deep fascia. The biomechanics of the cone morphology provides excellent lifting and holding ability and less propensity to “cheesewire” through friable or soft fatty tissues compared to barbed sutures [3]. The knotted suture means there has been no compromise to the structure of the main body of the suture, unlike barbed sutures where linear shredding can occur when



**Figure 2.** The Silhouette suture with blunt-tipped straight needle for placement

tensions are applied to the barbs. Coned sutures are somewhat bulkier than barbed ones, leading occasionally to irregularities or visibility in patients who have a thin soft tissue envelope. This softens out quickly without intervention. Although the original sharp straight needle is available for suture passage, a blunt one was recently introduced, presumably to reduce the chance of nerve or vascular injury during deployment of sutures. The disadvantage of the blunt-tipped needle is the need for an extra step: puncturing the skin with a needle prior to exiting the skin. Also, more force is required to pass the blunt needle through fibrous tissues such as the lateral neck area and temporal area. Haematoma is rare using either a sharp or blunt tipped needle provided the needle is passed through the correct plane, particularly when lidocaine with epinephrine is used for infiltrative anaesthesia.

### 3. Clinically oriented anatomy

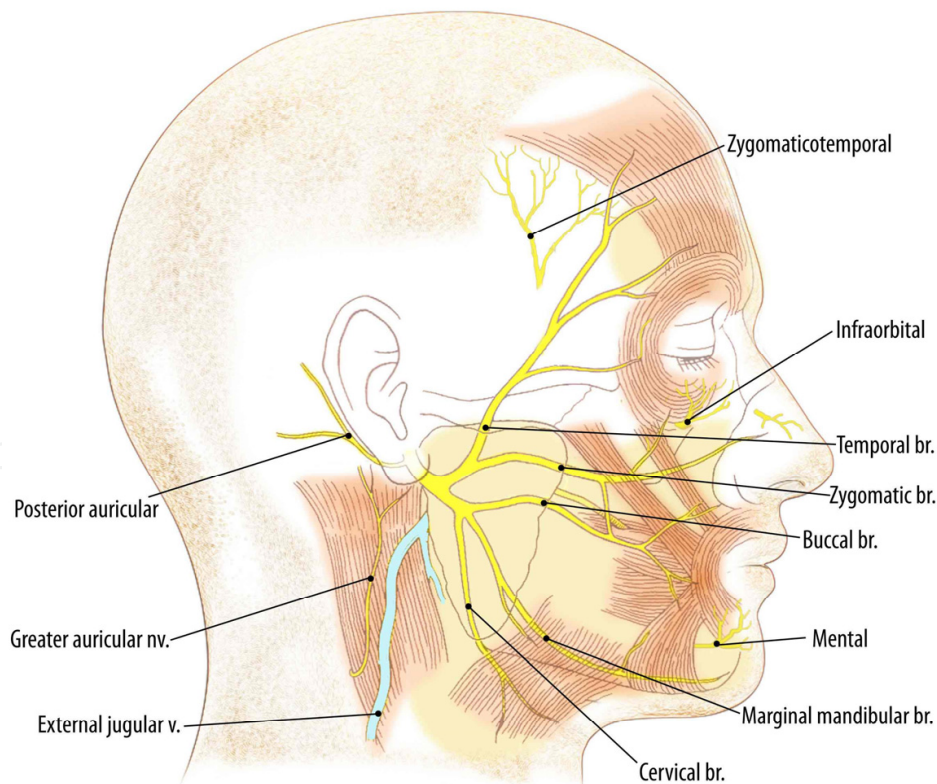
A thorough knowledge of facial anatomy is essential for any surgeon who performs suture or thread lift techniques. The thread lift techniques described in this chapter require small incisions, and the passage of blunt-tipped needles blindly through the subcutaneous fatty and fibrofatty tissues of the face and neck. Care must be taken to avoid inadvertent injury to important structures, including vessels, sensory nerves, and motor nerves. Understanding the anatomy of the soft tissue planes is also important for Silhouette suture lift techniques since different planes are traversed with the sutures, and anchorage to deep fascia in the temporal area or neck is required to secure the lift and prevent slippage.

In the temple behind the hairline, the temporalis muscle is covered with a tough, shiny white, adherent deep temporal fascia (DTF). An anchor patch can easily be sutured to this fascia through a small (3cm) temporal incision. Loosely attached to the DTF lies the superficial temporal fascia (STF). This thin layer is continuous with the superficial musculoaponeurotic system (SMAS) in the face beyond the hairline and the galea



aponeurotica medially over the forehead. At the hairline, the STF splits into two separate leaves that envelop branches of the temporal branch of the facial nerve. Close to the zygomatic arch, the DTF splits to envelop an intermediate fat pad and facial nerve branches.

The facial nerve emerges from the stylomastoid foramen 6-8mm medial to the tympanomastoid suture of the skull. The posterior auricular nerve and nerves to the posterior belly of digastric and stylohyoid branch from the main trunk before the facial nerve enters the substance of the parotid gland. Within the parotid gland, the facial nerve divides into its main branches: temporal branch, zygomatic branch, buccal branch, marginal mandibular branch, and cervical branch (Fig. 3). The temporal branch exists as 3-4 rami as it exits the superior part of the parotid gland and courses superficially over the zygomatic arch. From the zygomatic arch to the point where the nerve fascicles enter the orbicularis oculi above the brow, these nerve branches are susceptible to injury. Invariably, the temporal branch fibres cross the zygomatic arch between 0.8cm and 3.5cm anterior to the bony external acoustic meatus. They travel enveloped in two leaves of the superficial temporal fascia and enter fibres of frontalis and orbicularis oculi about 2cm superior to the brow. A danger zone exists in the plane of the superficial temporal fascia from the zygomatic arch to the temporal area where the temporal nerve branches are susceptible to injury by suture-passing needles [4].



**Figure 3.** The five branches of the facial nerve: temporal, zygomatic, buccal, marginal mandibular, and cervical. With kind permission from Springer Science+Business Media: *Advanced Surgical Facial Rejuvenation, Facial anatomy*, 2012, p.11, P.M. Prendergast, fig. 1.11.

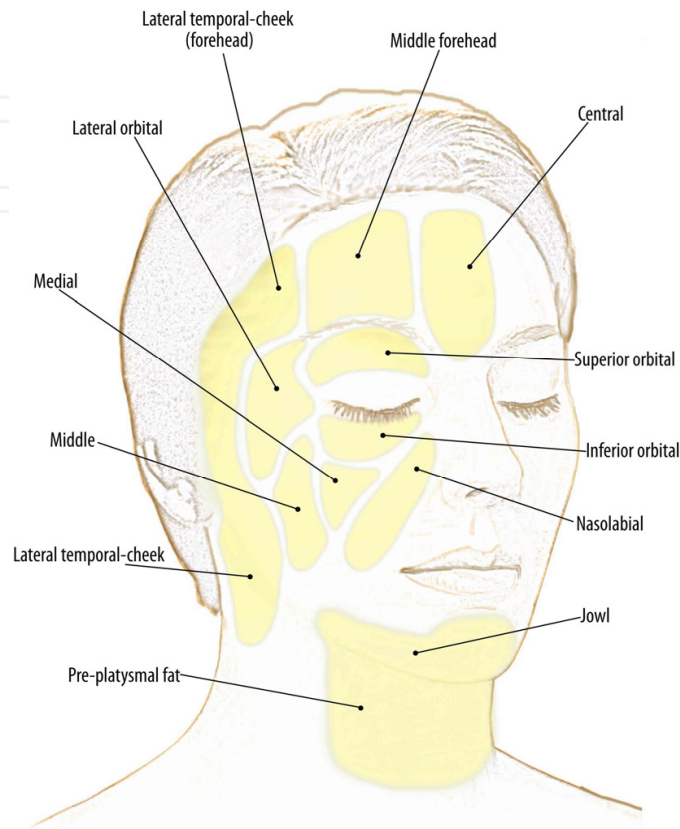
There may be up to three zygomatic branches of the facial nerve. One usually passes above the eye to innervate fibres of frontalis and orbicularis oculi. The lower branch passes under the origin of zygomaticus major and supplies this muscle, lip elevators, and the lower orbicularis oculi. Smaller branches also supply depressor supercillii and the superomedial orbicularis oculi. The buccal branch of the facial nerve is closely adherent to masseter within the parotidomasseteric fascia. It travels anteriorly over the buccal fat, below and parallel to the parotid duct. This nerve innervates the buccinators and muscles of the upper lip and nose. Injury to the buccal branches of the facial nerve during a Silhouette thread lift is unlikely since the needles pass in a more superficial plane to retract the superficial soft tissues and fat compartments.

The marginal mandibular nerve exits the inferior aspect of the parotid and travels anteriorly above the mandibular border, although it may drop to up to 4cm below the mandibular border. About 2cm posterior to the corner of the mouth, the nerve courses upward over the mandibular border, just deep to the wafer-thin platysma muscle. At this point, it is prone to injury during liposuction or surgical techniques in this area. Silhouette suture exit points are situated superiorly for midface lifting, although passage of the needles in the neck close to the mandible could theoretically injure this nerve.

Silhouette suture face lifting employs small absorbable cones to retract soft tissues of the midface. These soft tissues are essentially superficial fat compartments, separated from one another by condensations of connective tissue. The superficial fat compartments, as described by Rohrich [5] comprise the following: the nasolabial fat compartment, the medial, middle, and lateral temporal-cheek "malar" fat pads, the central, middle, and lateral temporal-cheek pads in the forehead, and the superior, inferior, and lateral orbital fat pads (Fig. 4). During midface elevation using Silhouette sutures, the nasolabial, medial, and middle cheek fat pads are retracted and elevated, compressing them somewhat against the inferior orbital and lateral orbital fat compartments. The result is volume restoration and softening of the nasolabial fold and tear trough deformity. Irregularities can occur where cones tether the ligaments that occur between these fat compartments. This is particularly true of the zygomatic ligament, a true ligament that arises from the zygomatic periosteum and inserts into the dermis near the lateral canthus. As described later, cones should be excised from the suture to prevent irregularities in this area. False retaining ligaments are more diffuse condensations of connective tissue that connect superficial and deep facial fasciae [6]. The cones on Silhouette sutures also retract these ligaments, increasing the stability of the lift. The mild waviness or irregularity that occurs immediately following suture lifts is transient and softens out within a few days without intervention.

The sensory innervation of the face is via the three divisions of the trigeminal nerve (fifth cranial nerve) ophthalmic nerve, maxillary nerve, and mandibular nerve. The ophthalmic nerve supplies the forehead, upper eyelid, and dorsum of the nose via the supraorbital, supratrochlear, infratrochlear, lacrimal, and external nasal nerves. The maxillary nerve supplies the lower eyelid, cheek, upper lip, ala of the nose, and part of the temple, through the infraorbital, zygomaticofacial, and zygomaticotemporal nerves. The mandibular nerve has motor and sensory fibres. Its branches include the inferior alveolar nerve, lingual nerve,

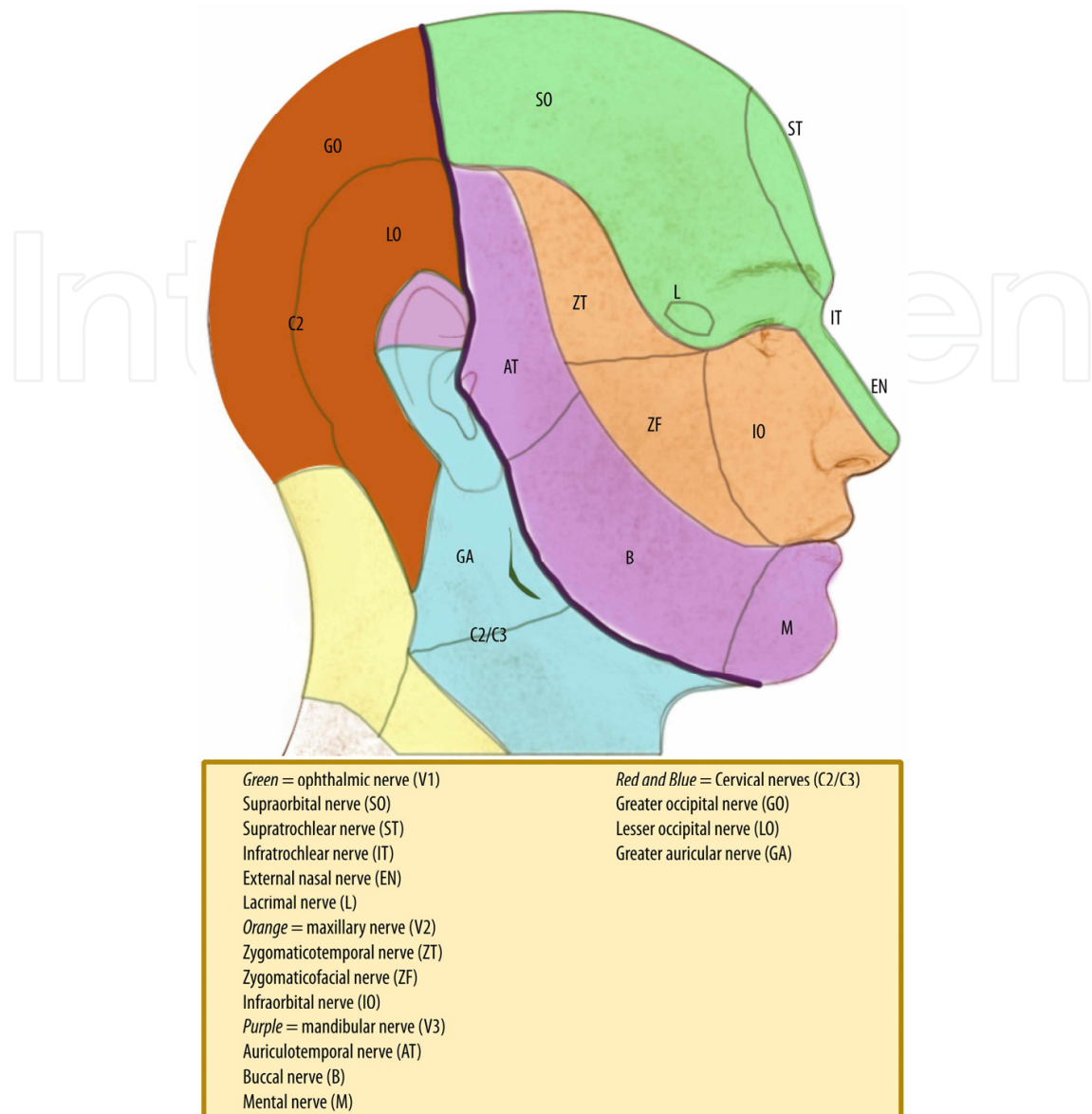
buccal nerve, and auriculotemporal nerve. These supply the skin over the mandible, lower cheek, part of the temple and ear, the lower teeth, gingival mucosa, and the lower lip (Fig. 5). The greater auricular nerve, derived from the anterior primary rami of the second and third cervical nerves, supplies the skin over the angle of the mandible.



**Figure 4.** The superficial fat compartments of the face

Silhouette suture lifts are performed under local anaesthesia: infiltrative, regional, or a combination of both. Infiltrative anaesthesia provides a “hydrotomy” or fluid plane through which suture needles can easily pass. Infiltrative anaesthesia also provides local vasoconstriction, via epinephrine, and potentially reduces bruising and the risk of haematoma. Newer blunt-tipped needles are designed to reduce the likelihood of vascular (and neural) injury. Regional nerve blocks anaesthetize large areas of the face and cause less localised tissue distortion than infiltrative anaesthesia. Tissue filling and distortion with anaesthetic solution can make it difficult to assess the soft tissues intraoperatively and the degree of retraction required for a satisfactory lift. Regional blocks of the main nerves providing sensation to the temples and midface are described here.

The zygomaticotemporal nerve emerges from its foramen on the deep surface of the zygomatic bone and supplies the anterior temple. It is blocked by injecting 1-2ml anaesthetic behind the junction of the lateral orbital rim and the upper border of the zygomatic arch. The zygomaticofacial nerve arises from its foramen below and lateral to the inferolateral border of the orbital rim and supplies the soft tissues and skin over the malar eminence. To block this nerve, anaesthetic is injected over the periosteum at the site of the zygomaticofacial foramen.



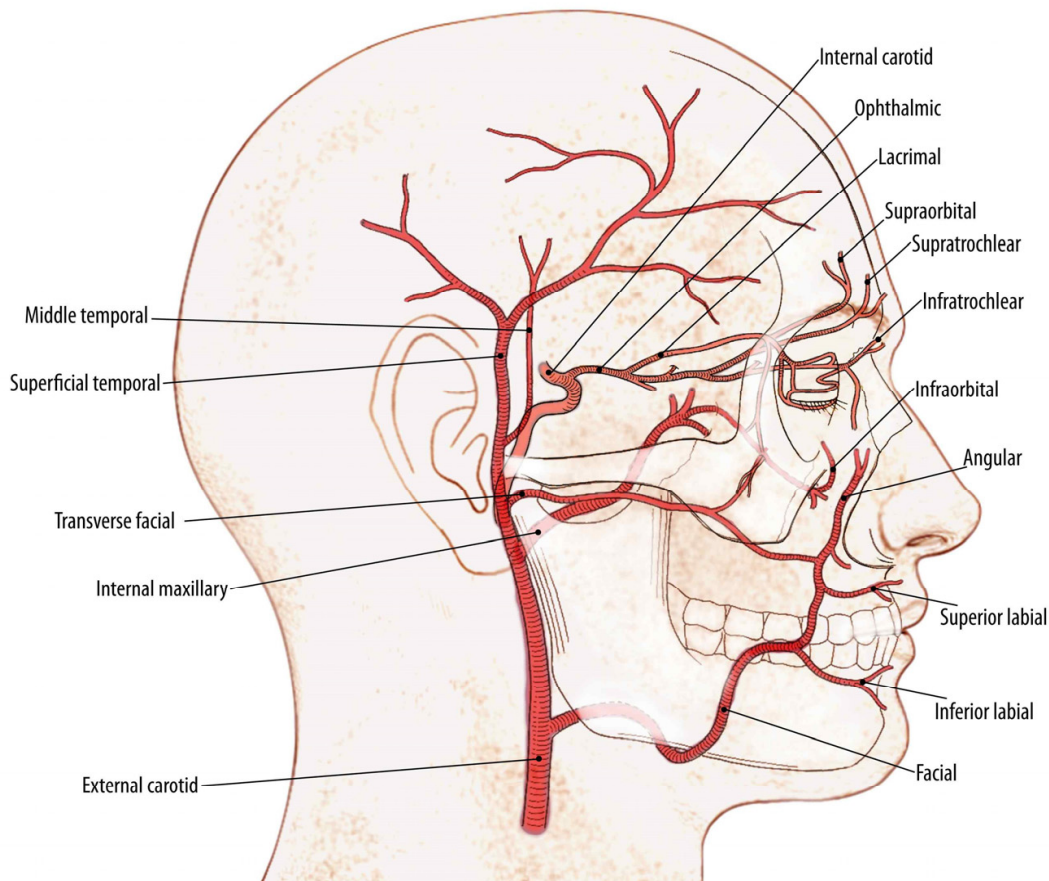
**Figure 5.** Sensory innervation of the face and neck. *With kind permission from Springer Science+Business Media: Advanced Surgical Facial Rejuvenation, Facial anatomy, 2012, p.12, P.M. Prendergast, fig. 1.12.*

The infraorbital nerve is the largest branch of the maxillary nerve. It enters the face through the infraorbital foramen 2.7-3 cm from the midline in men and 2.4-2.7 cm from the midline in women, about 7 and 6 mm inferior to the inferior orbital rim in men and women respectively. It supplies the lower eyelid, ala of the nose, medial cheek, nasolabial fold, and upper lip. To block the infraorbital nerve, about 2 ml anaesthetic solution is injected over the foramen. To reach the foramen, a transdermal or intraoral approach is used.

With proper placement of blunt-tipped Silhouette needles in the correct plane, bleeding is uncommon. Infiltrating small volumes of anaesthetic with epinephrine along the proposed suture paths provides a bloodless field and further reduces ecchymosis. It is important for the surgeon who performs suture lifting techniques to have a knowledge of the vascular supply to the face. The arterial supply is outlined here.



The skin and soft tissue of the face receive their arterial supply from branches of the facial, maxillary, and superficial temporal arteries—all branches of the external carotid artery. The ophthalmic arteries, arising from the internal carotid system, supply a masklike area including the central forehead, eyelids, and upper part of the nose (Fig. 6).



**Figure 6.** The arterial supply of the face. With kind permission from Springer Science+Business Media: *Advanced Surgical Facial Rejuvenation, Facial anatomy*, 2012, p.13, P.M. Prendergast, fig. 1.13.

The facial artery arises from the external carotid and loops around the inferior and anterior borders of the mandible, just anterior to masseter. It pierces the masseteric fascia and ascends upwards and medially toward the eye. It lies deep to the zygomatici and risorius muscles but superficial to buccinator and levator anguli oris [7]. At the level of the mouth the facial artery sends two labial arteries, inferior and superior, into the lips where they pass below orbicularis oris. The continuation of the facial artery near the medial canthus beside the nose is the angular artery.

The maxillary artery is a terminal branch of the external carotid with three main branches, mental, buccal, and infraorbital arteries. The mental artery is the terminal branch of the inferior alveolar artery that passes through the mental foramen to supply the chin and lower lip. The buccal artery crosses the buccinators to supply the cheek tissue. The infraorbital artery reaches the face through the infraorbital foramen and supplies the lower eyelid, cheek, and lateral nose. It anastomoses with branches of the transverse facial, ophthalmic, buccal, and facial arteries.

The superficial temporal artery is the terminal branch of the external carotid artery. In the substance of the parotid, just before reaching the zygomatic arch, it gives off the transverse facial artery which runs inferior and parallel to the arch and supplies the parotid, parotid duct, masseter, and skin of the lateral canthus. The superficial temporal artery crosses the zygomatic arch superficially within the superficial temporal fascia. Above the arch, it gives off a middle temporal artery that pierces the deep temporal fascia and supplies the temporalis muscle. Thereafter, about 2cm above the zygomatic arch, the superficial temporal artery divides into anterior and posterior branches. The anterior branch supplies the forehead and forms anastomoses with the supraorbital and supratrochlear vessels. The posterior part supplies the parietal scalp and periosteum.

The ophthalmic artery is a branch of the internal carotid system (Fig. 6). Its branches include the lacrimal, supraorbital, supratrochlear, infratrochlear, and external nasal arteries. There is significant communication between the external and internal carotid artery systems around the eye through several anastomoses.

#### **4. Indications**

Patients who may benefit from the Silhouette lift procedure include those with mild to moderate heaviness or ptosis of the face and neck. Typically, patients are 35 to 45 years old with normal or slightly excessive facial volume. The fat compartments in the midface have fallen slightly, accentuating the nasolabial crease. As the fat falls away from the lid-cheek junction, the tear trough deformity becomes apparent under the eyes. The anterior cheek flattens and the shape of the face changes from a youthful heart-shape to a more aging rectangular-shape. By elevating the midface fat compartments using the Silhouette sutures, all of these aging features can be improved. Repositioning the midface in a vector that is mostly superior improves the shape of the face, softens the nasolabial crease, and ameliorates the lid-cheek junction. It is important to remember that a Silhouette lift is not an excisional procedure, but one that merely repositions ptotic soft tissue. As such, if there is marked laxity of skin, a Silhouette lift is not indicated. Similarly, if the patient's face is very thin, Silhouette sutures are not appropriate. Where there is a very thin soft tissue envelope, lifting the fat with Silhouette sutures will simply bunch up the skin and create irregularities over the cones.

A Silhouette suture lift improves mild ptosis of the neck and helps restore an optimum mentocervical angle, which should be 80-95°. For more pronounced signs, including excessive laxity, heavy platysmal bands, and submental fat, other procedures may be more appropriate, including excisional surgery, platysmaplasty, liposuction, or chemodenervation.

Before any suture or thread lift procedure, the patient's expectations should be assessed. If the patient expects dramatic results, or a powerful lifting effect that could only be achieved through open surgery, the procedure should not be performed unless the patient can readjust their expectations. Suture lifting techniques do not replace open excisional surgery. The author explains to patients that suture lifts usually provide more lifting than external tissue tightening devices, but do not replace invasive surgery. They reposition tissue, but do not remove them. Once a patient has realistic expectations and appreciates that the aim is a

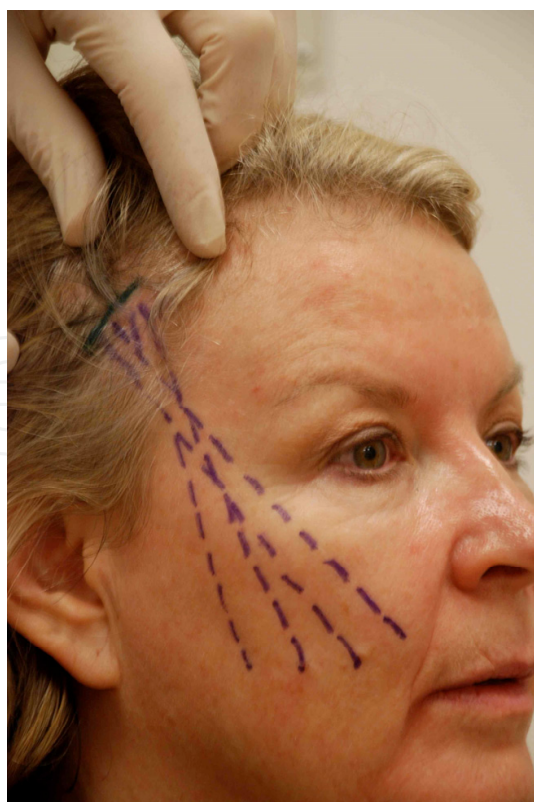natural-looking enhancement rather than a dramatic transformation, the likelihood of a successful outcome is high. Additionally, it should be explained to the patient that no intervention provides permanent results. Suture lifts can be repeated over time if necessary. The Silhouette sutures described here may be retightened during a secondary procedure.

## 5. Step-by-step technique

The author administers 1mg lorazepam and one solpadol (paracetamol 500mg, codeine 30mg) preoperatively for anxiolysis and moderate analgesia. Preoperative photographs should be taken in front, oblique, and side views.

### 5.1. Midface

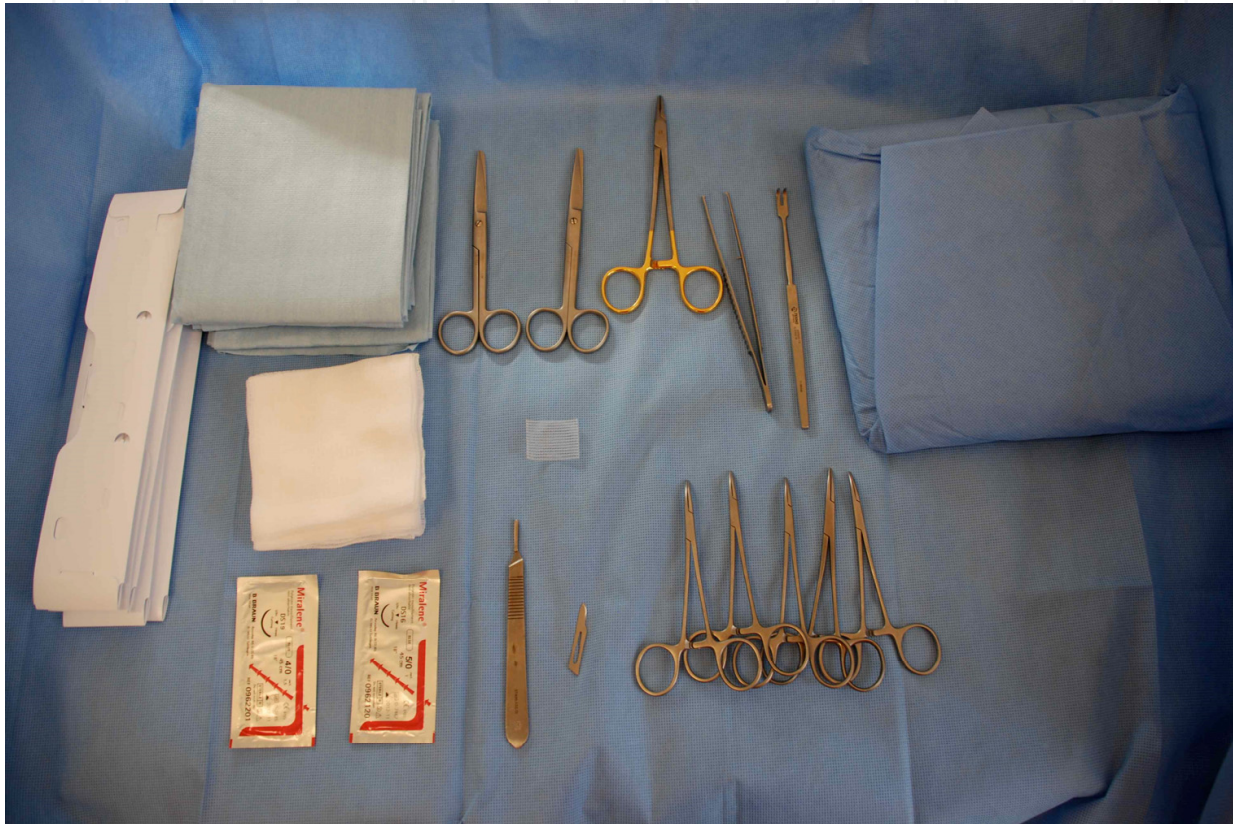
Markings are made with skin markers with the patient in the sitting position. First, a guide line is marked from the corner of the mouth to the angle of the mandible. Exit points should not be made inferior to this line to prevent disruption of the sutures during facial animation. Next, the proposed exit points are marked. For midface lifting, the standard exit points are as follows: 1 cm lateral to the midpoint of the nasolabial fold, 1.5 cm inferior to the first point, 1.5 cm lateral to the previous point at or just above the guide line, and 1.5 cm lateral to this point (Fig. 7). Depending on the desired lifting vector, the suture paths are estimated using a dashed line from these exit points to a point where the lines converge behind the temporal hairline. A line is marked behind the hairline in the temporal scalp, measuring about 3 cm, where the incision is made.



**Figure 7.** Preoperative markings for Silhouette midface lift



The patient is positioned supine for the procedure. Sterile technique is used, with formal skin preparation and surgical draping, exposing the operative field. The instruments and materials required for lifting using Silhouette sutures are shown in figure 8. A solution of 2% xylocaine (lidocaine 2% with epinephrine 1:200,000) and 0.9% sodium chloride is used for infiltrative anaesthesia. Using a combination of 30 gauge and 27 gauge short and long needles, the incision site and proposed suture paths are infiltrated. Adding sodium bicarbonate to the solution reduces discomfort on infiltration. A maximum of 7mg/kg lidocaine (with epinephrine) should not be exceeded to avoid lidocaine toxicity.

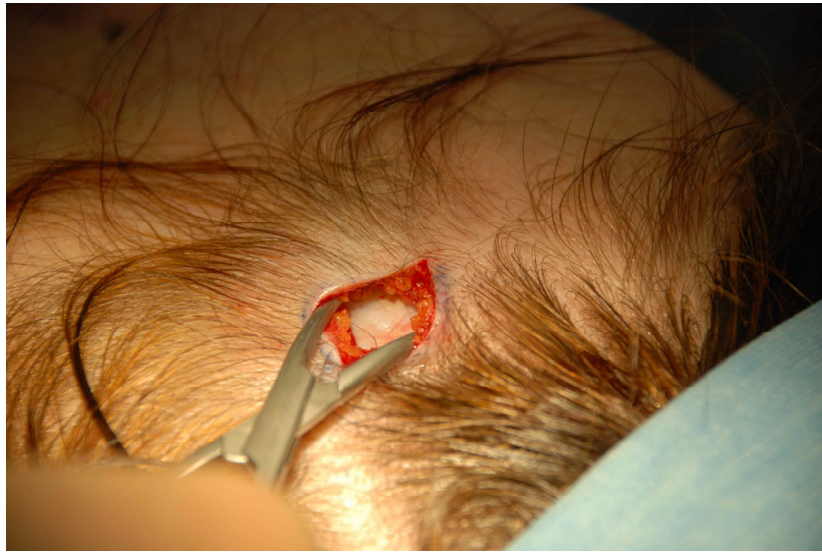

**Figure 8.** Instruments and materials required for Silhouette suture lift procedure

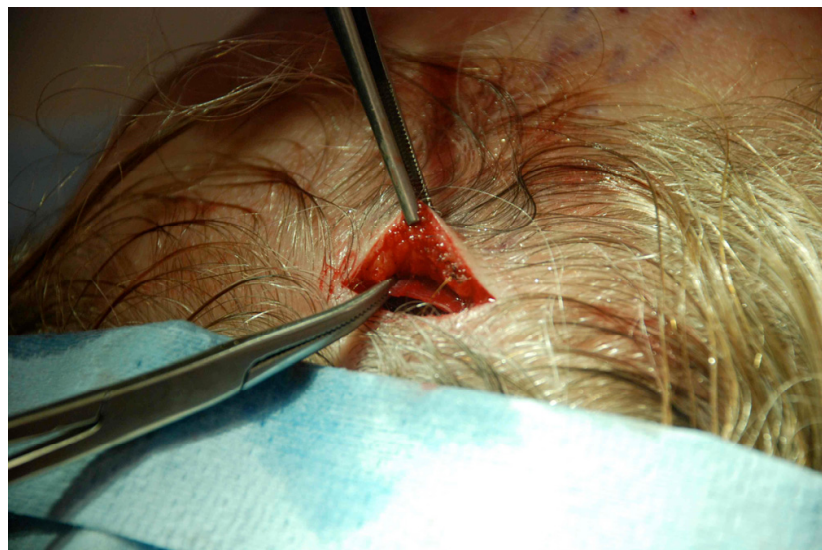A 3 cm incision is made in the temporal area. Since this area is particularly vascular, diathermy is essential for adequate haemostasis. Once the skin is opened, the subcutaneous fat is gently retracted, exposing the superficial temporal fascia (STF). This thin layer is opened to expose the white, shiny deep temporal fascia (Fig. 9). A space is created by bluntly dissecting over the deep temporal fascia.

A small, 1 cm x 0.5 cm patch of polypropylene mesh (Suramesh) is placed on the deep temporal fascia and secured using a single vicryl suture. In order to delineate the planes before suture placement, sharp dissection above the superficial temporal fascia separates the subcutaneous fatty plane and the superficial temporal fascia (Fig.10). To avoid placing the needles close to the temporal branch of the facial nerve beyond the hairline, the needles are placed in the subcutaneous fat above the superficial temporal fascia. It is best to start in the correct plane, rather than start deep to superficial temporal fascia (STF) and then change course at the hairline to come superficial to the STF blindly.





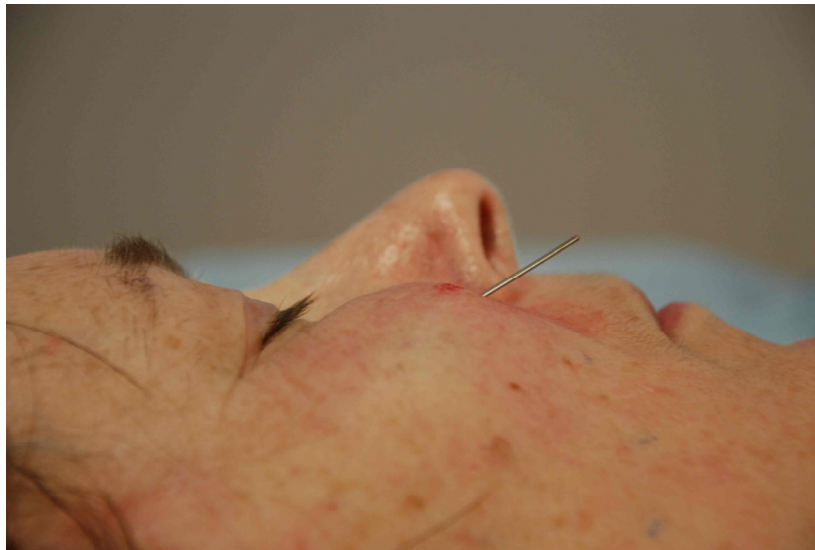**Figure 9.** Temporal incision with exposed deep temporal fascia.



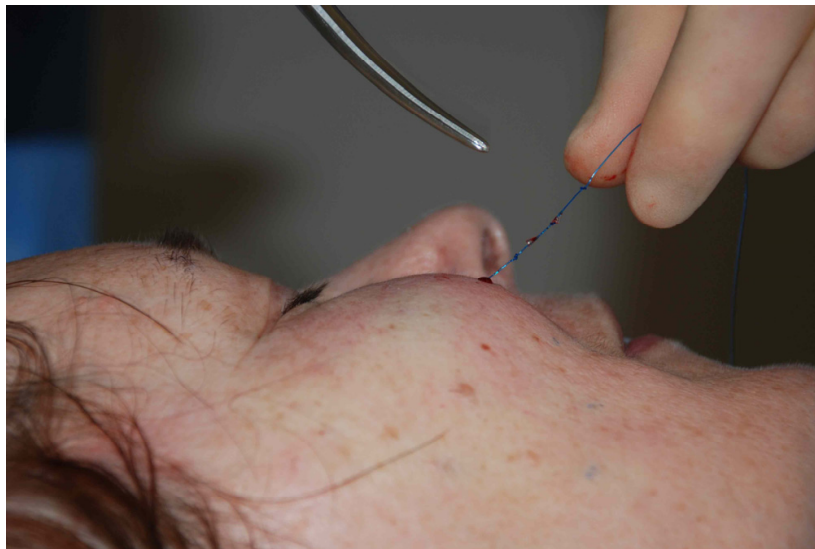**Figure 10.** Superficial temporal fascia. The suture is placed just above the superficial temporal fascia in the subcutaneous plane.

Before passing the first Silhouette suture, the suture is placed over the face externally to determine how many cones should be left on the suture and how many (if any) should be excised. Once lifted, all cones should be positioned inferior to the zygomatic arch, to avoid tethering the zygomatic ligament, resulting in irregularities that can be difficult to correct. Usually, leaving 3-4 cones on the suture is sufficient, although this depends on the size of the patient's face. The first suture is passed through the face by placing the blunt tip of the Silhouette needle subcutaneously, above STF, until the needle tip is ready to emerge through the dermis at the first exit point lateral to the nasolabial fold. The soft tissues should not be squeezed or compressed around the needle during passage to avoid irregularities. The malar fat can be lifted slightly to “present” it to the needle once the needle passes over the zygomatic arch. This maneuver also facilitates the needle to exit through the skin perpendicularly. A 16-gauge needle is used to puncture the skin over the

exit point to allow the blunt-tipped needle to emerge (Fig. 11). The needle is pulled through gently. A characteristic clicking of cones is heard as they pass through the soft tissues. Care should be taken not to pull through too many cones; once they exit the skin they cannot be retracted back into the tissues. The predetermined number of cones is excised from the suture, and the suture is cut distal to the knot that lies proximal to the last cone being removed (Fig. 12). The proximal end of the suture is lifted to retract the knot back into the cheek and lift the tissues. The same process is repeated for the other sutures until all four sutures are placed in the fibrofatty malar fat pad. Although four sutures are usually placed for midface lifting, more or fewer sutures can be employed depending on the patient and indications. However, the lateral face region should be avoided since the soft tissue envelope in this region is thinner and the dermis is more adherent to the superficial musculoaponeurotic system.

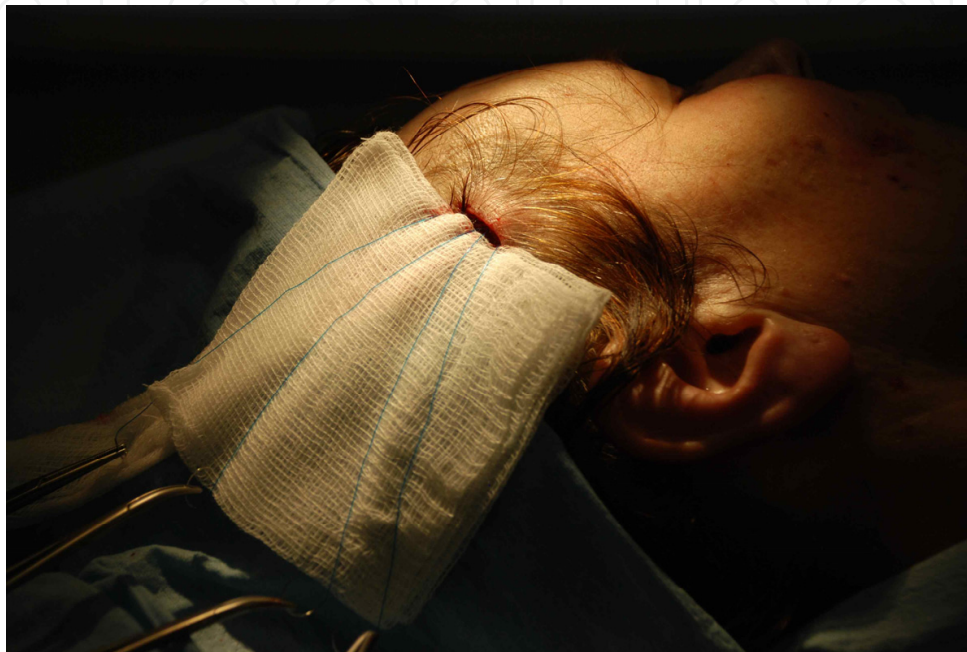

**Figure 11.** Blunt-tipped needle exits perpendicularly



**Figure 12.** The suture is brought through and the predetermined number of cones is excised from the suture

The half-circle needle swaged to the proximal end of the Silhouette suture is passed first through the superficial temporal fascia. Then a bite of the deep temporal fascia is taken, emerging through the polypropylene mesh. Once all of the proximal needles are anchored to the deep temporal fascia and mesh in this way, the sutures are retracted gently to affect a lift on the midface (Fig. 13). The sutures are tied to one another in pairs over the polypropylene mesh. The superficial temporal fascia is closed with vicryl. Skin closure is performed with interrupted skin sutures or skin clips.

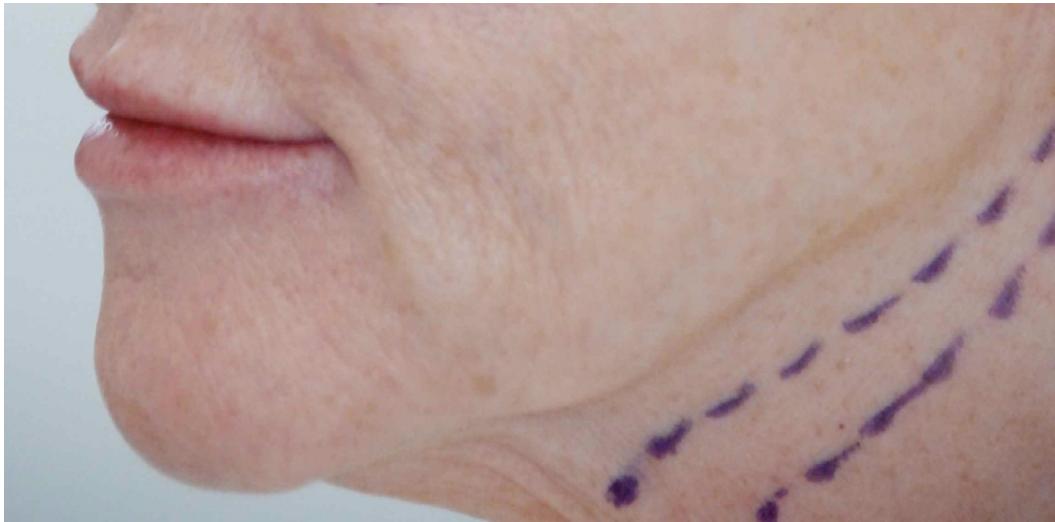

**Figure 13.** Four Silhouette sutures are used on each side to elevate the midface

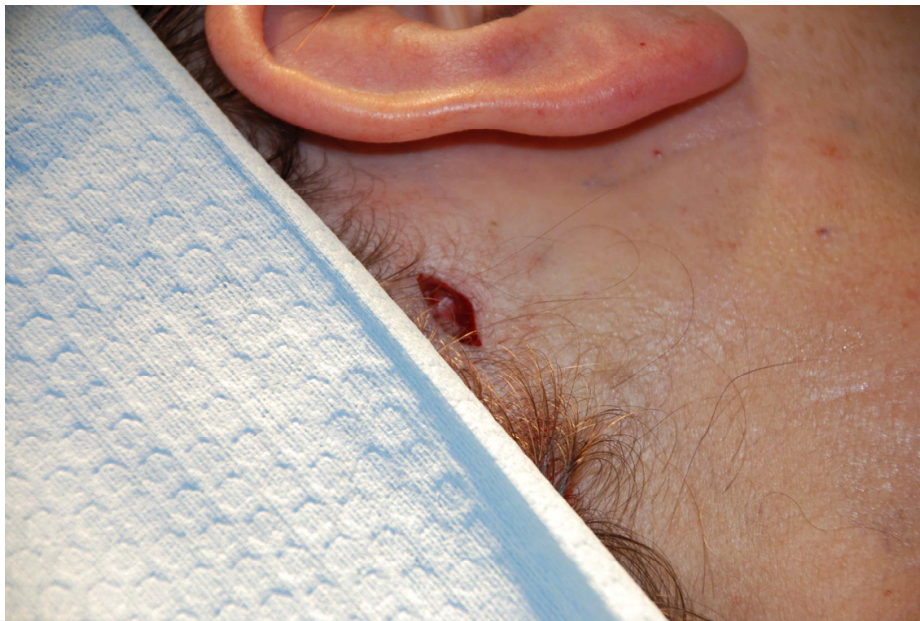## 5.2. Neck

Markings are made from an incision site at the hairline below the ear along the neck under the jawline toward the midline. Two exit points are marked on each side, before the midline (Fig. 14). Local anaesthetic is infiltrated subcutaneously along the suture paths. A 2 cm incision is made at the hairline and the cervical fascia is exposed with blunt dissection (Fig. 15). The first Silhouette needle is passed under the dermis toward the midline. Laterally, the dermis is adherent to the underlying fascia over sternocleidomastoid and more resistance is felt in this area using the blunt-tipped needle. More medially, less resistance is encountered as the needle glides through the preplatysmal fat. The dermis is punctured with a 20-gauge needle to allow the Silhouette needle exit. Most or all of the six cones on the Silhouette suture are left in place for neck lifting. In some cases, two cones are excised, leaving four on the suture to lift the tissues. Once both sutures are passed, the proximal ends are anchored by taking a bite of cervical fascia and tying the sutures down over a small pledget of polypropylene mesh. Care should be taken to avoid the mesh curling upward toward the dermis by seating it properly on the fascia. The skin is closed using 4/0 or 5/0 sutures. Moderate, transient bunching occurs laterally following Silhouette suture lifting of the neck.





**Figure 14.** Preoperative marking for Silhouette suture neck lift. Two sutures are passed on each side from the hairline to exit points near the midline.



**Figure 15.** Incision for Silhouette suture lift of the neck

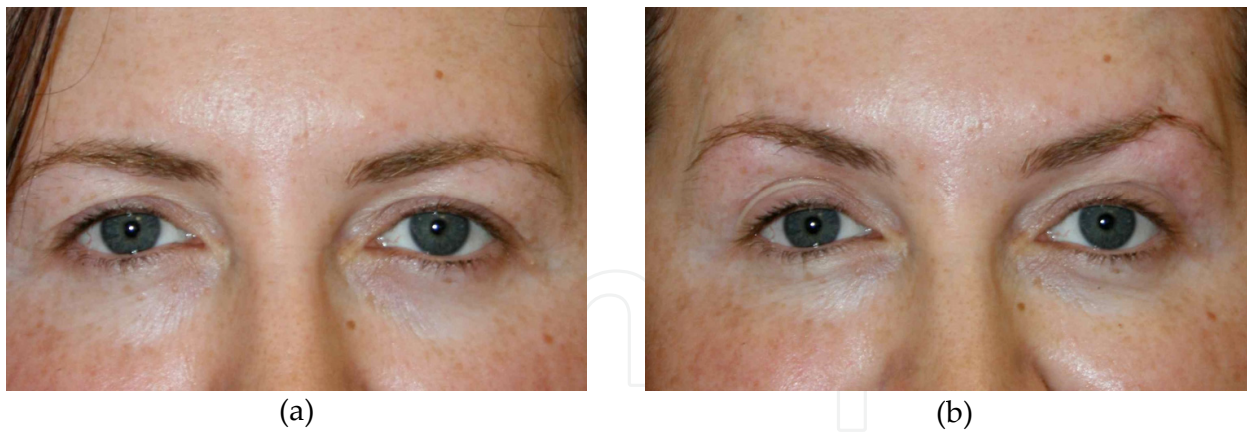
### 5.3. Brow

A Silhouette lift of the brow improves aesthetics by elevating the lateral aspect and tail of the eyebrow (Fig. 16). In heavy brows, elevation also reduces dermatochalasis. The author recommends chemodenervation of lateral fibres of orbicularis oculi with botulinum toxin at least two weeks prior to the suture lift to reduce downward movement on the cones.

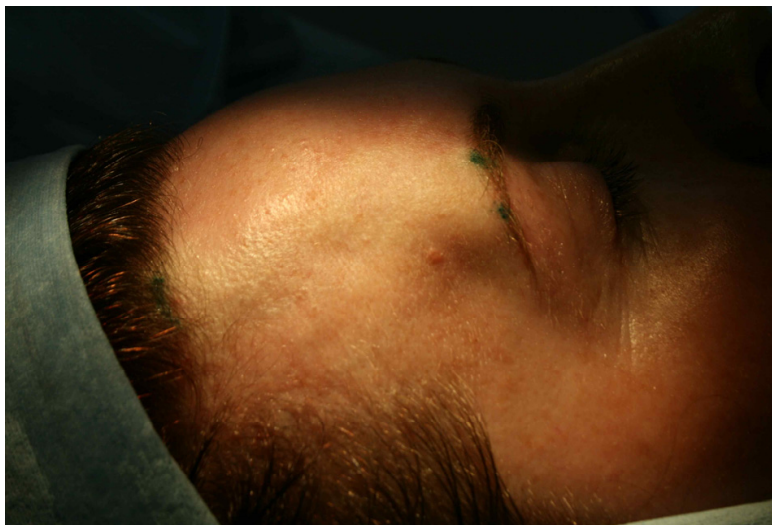The patient is carefully assessed to decide the best lifting points in the lateral brow (Fig. 17). The exit points and anchorage point will determine the ultimate lifting effect and shape of the brow.

Local anaesthesia is infiltrated along the suture paths, creating a hydrotomy that somewhat lifts the normally adherent dermis off the underlying frontalis. A 1 cm incision is made in the





**Figure 16.** a. Before, b. Immediately after Silhouette brow lift.



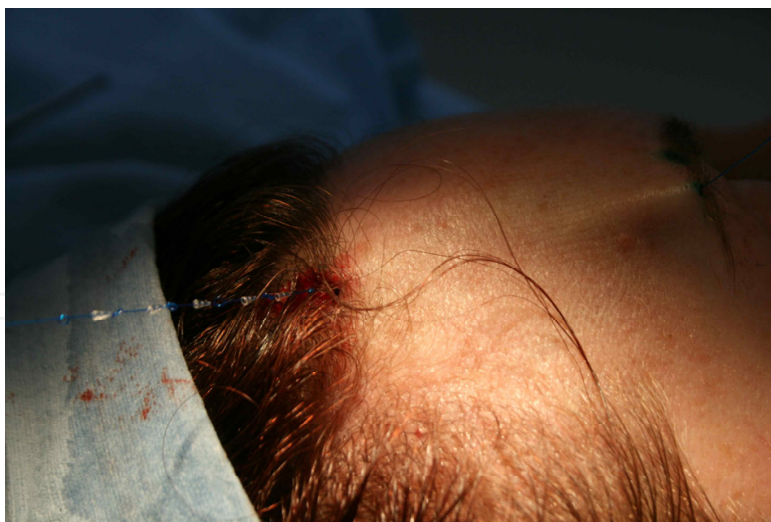**Figure 17.** Preoperative markings for brow lift using Silhouette sutures. An incision is made at the hairline. There are two exit points at the brow.

skin at the hairline. The first Silhouette suture is passed from the incision to the exit point in the brow (Fig. 18). There is usually no need to excise any cones from the suture, leaving six cones to elevate the tissues above the brow. The second suture is passed in the same way. Each proximal end of the suture is anchored by passing the half circular needle deep to periosteum. The suture ends are tied to one another over a small pledget of polypropylene mesh, which sits on the galea. The pledget and suture ends are buried satisfactorily before the skin is closed.

Mild irregularities or bunching occur immediately following Silhouette brow lifting. This resolves and softens in a number of days.

## 6. Results

The Silhouette suture lift procedure elevates and suspends tissues providing immediate results. These minimally invasive techniques, performed under local anaesthesia, do not replace excisional surgery such as cervicofacial rhytidectomy, but are ideally suited for younger patients or those who do not want more invasive intervention. They can also be performed as a complementary procedure during open surgery.



**Figure 18.** The first Silhouette suture is passed from the incision at the hairline to the brow.

Immediately after the procedure, there is usually mild swelling secondary to local anaesthesia, as well as some bunching or irregularities over the sutures. It should be explained to the patient preoperatively that it takes a few days for the tissues to smooth and soften and for the bunching to subside, particularly in the neck. The patient should not rub or massage the face or neck for several weeks. Gentle handling is important to avoid disruption of the sutures, and to allow fibrosis around the cones and knots on the sutures to occur.

After the poly-lactide cones on Silhouette sutures absorb over about 10 months, what remains are the polypropylene sutures, knots, and bundles of fibrous tissues that remain tethered to surrounding tissues. After 1-2 years, Silhouette sutures can be retightened by opening the old incision, re-suspending the proximal suture ends, and tying them down again to restore the desired lift. Alternatively, further sutures can be placed and anchored in a redo procedure.

## 7. Complications

Although complications associated with Silhouette suture lifts are uncommon, they can occur and the patient must be informed of all potential sequelae, side-effects, and risks. Normal after-effects include swelling, mild bunching and irregularities, ecchymosis, discomfort, and transient dysaesthesias. Complications are listed in table 1.

Infection should be treated with antibiotics initially. If there is evidence of infection along the suture, the sutures should be removed. Prophylactic antibiotics and sterile technique serve to minimise the risk of infection.

Whilst a small haematoma may resorb without intervention, if a large haematoma occurs, this may need to be evacuated. The presence of a haematoma also increases the risk of localized infection.

Non-absorbable sutures may extrude through the skin, even years following a suture lift. It is important to bury suture knots or seat the tied sutures or mesh deep where possible so that it is less likely to irritate the dermis. This is particularly important in the forehead with brow lifting and incision at the neck hairline with Silhouette neck lifts.

Persistent irregularities or dimples overlying sutures can usually be corrected with gentle manipulation of the tissues over the suture. If the dermis cannot be released using this maneuver, subcision may be used using a needle.

Infection	Facial nerve injury
Bleeding	Sensory impairment
Haematoma	Chronic pain
Suture extrusion	Palpability

**Table 1.** Complications associated with suture lifting

## 8. Conclusion

The Silhouette suture is a novel device used for minimally invasive face and neck lifting under local anaesthesia without the need for long incisions, tissue undermining, or skin excision. Retraction or suspension of soft tissues is achieved through absorbable cones distributed along the length of the suture. Silhouette sutures are most commonly employed for midface lifting, where the fibrofatty malar fat is elevated and anchored by suturing the proximal ends of the sutures to the deep temporal fascia behind the hairline. The non-absorbable polypropylene sutures allow secondary re-tightening at a later stage. Silhouette sutures are also suitable for lifting and improving ptosis in the neck and in the brows.

## Author details

Peter Prendergast  
*Venus Medical, Dublin, Ireland*

## 9. References

- [1] The American Society for Aesthetic Plastic Surgery: Cosmetic surgery national database statistics 2011, ASAPS website, <http://www.surgery.org> (accessed 1 May 2012).
- [2] Kress DW. The History of Barbed Suture Suspension: Applications, and Visions for the Future. In: Shiffman MA, Mirrafati SJ, Lam SM (eds.). *Simplified Facial Rejuvenation*. Berlin Heidelberg: Springer-Verlag; 2008. p247.
- [3] Sasaki GH, Komorowska-Timek ED, Bennett DC, Gabriel A. An Objective Comparison of Holding, Slippage, and Pull-out Tensions for Eight Suspension Sutures in the Malar Fat Pads of Fresh-Frozen Human Cadavers. *Aesthetic Surgery Journal* 2008; 28(4) 387-96.
- [4] Prendergast PM. Danger Zones in Surgical Facial Rejuvenation. In: Shiffman MA, Erian A (eds.). *Advanced Surgical Facial Rejuvenation*. Berlin Heidelberg: Springer-Verlag 2012. p24.
- [5] Rohrich RJ, Pessa JE. The Fat Compartments of the Face: Anatomy and Clinical Implications for Cosmetic Surgery. *Plastic and Reconstructive Surgery* 2007; 119(7): 2219-27.
- [6] Jones BM, Grover R. Anatomical Considerations. In: Jones BM, Grover R (eds.). *Facial Rejuvenation Surgery*. Philadelphia 2008. p18-22.
- [7] Berkovitz BKB, Moxham BJ. *Head and Neck Anatomy. A Clinical Reference*. Philadelphia: Taylor and Francis; 2002. p118.