

# Neuroimaging and Outcome Assessment in Vegetative and Minimally Conscious State

Silvia Marino, Rosella Ciurleo, Annalisa Baglieri, Francesco Corallo, Rosaria De Luca, Simona De Salvo, Silvia Guerrera, Francesca Timpano, Placido Bramanti and Nicola De Stefano  
*IRCCS Centro Neurolesi "Bonino-Pulejo", Messina,  
Dept. of Neurology, Neurosurgery & Behavioral Sciences, University of Siena, Siena,  
Italy*

## 1. Introduction

Consciousness is a multifaceted concept that has two dimensions: arousal, or wakefulness (i.e., level of consciousness), and awareness (i.e., content of consciousness) (Laureys et al., 2004). An accurate and reliable assessment of the arousal and awareness of consciousness in patients with severe brain damage is of greatest importance for the differential diagnosis of low levels consciousness patients and for outcome evaluation. Following coma, some patients permanently lose all brainstem function (brain death), some progress to "wakeful unawareness" (vegetative state - VS), whereas others recover typically and progress through different stages before fully or partly recovering consciousness (minimally conscious state - MCS). Patients in VS can open their eyes and exhibit basic orienting responses, but show no conscious, purposeful activity. Reflex and other movements are seen, mediated by brainstem, spinal cord, and brainstem-diencephalic arousal systems (Laureys et al., 2004). VS can occur after patients emerge from an acute catastrophic brain insult causing coma, or can also be seen in degenerative or congenital nervous system disorders. The two common findings are necrosis of the cerebral cortex, thalamus and brainstem (usually after anoxic injury) and diffuse axonal injury (usually after trauma), although other pathological findings can be seen in degenerative and other disorders (Laureys, 2008). The MCS patients do not meet diagnostic criteria for coma or VS because they demonstrate some inconsistent but clear evidence of consciousness (Laureys et al., 2008; Giacino et al., 2002). In the MCS, there is variable impaired function of the cerebral cortex, diencephalons and upper brainstem. This allows occasional conscious behaviours to occur, unlike in VS or coma. Patients may enter the MCS as they emerge from coma or VS, or they can become minimally conscious as a result of acute injury or chronic degenerative diseases. Recent studies suggest a number of potential clinical and rehabilitative applications of magnetic resonance (MR) techniques. Although bedside clinical examination remains the criterion standard for establishing diagnosis, MR may provide an adjunctive diagnostic role when behavioural findings are very limited or ambiguous. The future of diagnostic and prognostic assessment of patients with disorders of consciousness (DOC) envisions a battery of neurobehavioral and neuroimaging techniques (such as structural and functional MR imaging (MRI and

fMRI), MR spectroscopy (MRS), diffusion tensor imaging (DTI), fiber tracking, positron emission tomography (PET)) that serve as complementary clinical tools that may help differentiate the effects of underarousal, sensory impairment, motor dysfunction, and cognitive disturbance in the search for potential causes of behavioural unresponsiveness.

## 2. Magnetic Resonance and Magnetization Transfer Imaging

The morphological MRI acquisitions usually include non-contrast-enhanced sagittal T1, axial diffusion, axial fluid attenuated inversion recovery (FLAIR), axial T2-SE, coronal T2 sequences and a 3D T1-weighted volume acquisition. FLAIR and T2-SE sequences permit to detect brain edema, contusion, hematoma, herniation, subarachnoid hemorrhage, or hydrocephalus. T2 sequences are useful in detecting hemorrhagic diffuse axonal injuries (DAI). The total number of lesions detected by FLAIR and T2 are shown to be inversely correlated with Glasgow Outcome Scale (GOS) of traumatic coma patients; while the 3D T1 sequence provides an opportunity to evaluate the brain atrophy during the follow up of these patients. A lot of studies performed on traumatic coma patients with conventional MRI showed that lesions of the pons, midbrain, and basal ganglia were predictive of poor outcome especially when they are bilateral. Despite their encouraging results, these studies fail to explain why some patients in VS or with long-term marked cognitive impairments have no or minimal lesions on conventional MRI examination. This raises the question of the lack of specificity and insufficient sensitivity of conventional MR sequences which fail to reveal lesions such as ischemic axonal injuries. Therefore, it is clear that morphological and conventional MRI alone cannot be considered as a reliable tool to assess consciousness disorders severity or to predict their evolution and outcome (Tshibanda et al., 2009). Several studies investigated patients in VS and in MCS using non-conventional, quantitative and volumetric MR techniques, useful to provide information about the anatomical patterns, the prognosis and the outcome of these patients. Ammermann et al. (2007) have used volumetric analysis of MRI to determine the pattern of lesions in 12 patients with a severe neurological impairment after acute ischemic injury. At the time of scanning, the patients were either in VS or in an early remising state, that is MCS. Lesions were classified as having been present in the gray and/or white matter in four different brain regions (frontal, parietal, temporal, occipital). An additional separate evaluation was performed for the basal ganglia, thalamus, hippocampus, cerebellum, and brainstem. The total clinical follow-up period of all patients from the time of the causative event lasted for at least 5 months. The clinical outcomes were reported according to the Rancho Los Amigos Cognitive Scale (RLACS) as a universal guide to assess a patient's level of functioning. The final RLACS levels were correlated to the MRI lesion size with a Spearman correlation. All patients demonstrated extensive white matter lesions, with the largest lesions observed in the frontal and occipital lobe. A preferential involvement of the white matter located in the periventricular area and in the subcortical regions below the motor and internal temporal cortices was found, in addition to the classically described lesions of the striatum, motor and occipital cortices. Lesion magnitude showed an association with the severity of the outcome as quantitatively assessed by RLACS. With respect to gray matter lesions, the vulnerability pattern observed included frontal and occipital and in some cases parietal cortical areas, moreover in most cases the thalamus. Additionally, almost all of patients showed lesions of the hippocampus or lesions to the basal ganglia. An association between the extent of the MRI defined lesions located within the white matter and the clinical

outcomes of the patients was found. All patients in the most unfavorable class III clinical outcome group (i.e. persistent VS) exhibited white matter lesions exceeding 2/3 of the volume of at least one lobe, most frequently the occipital lobe.

Moreover, Juengling et al. (2005) investigated 5 patients in persistent VS due to prolonged cerebral hypoxia of non-traumatic origin, using combined Voxel-Based Morphometry (VBM) of 3D MRI and FDG-PET analysis. In the analysis of the regional distribution of gray matter atrophy, VBM revealed multiple areas of significantly decreased gray matter density at  $p < .001$ , corrected for multiple comparisons. Those were localized in multiple cortical areas, in particular including inferior parietal lobe, superior and medial frontal lobe, paracentral lobule, superior and medial temporal lobe, the cingulum, and the fusiform gyrus. Thalamic changes were limited to small voxel clusters in dorso-medial areas. These structural atrophic changes were compared with the local distribution of functional loss as assessed by regional hypometabolism in the FDG-PET group analysis. At the threshold  $p < 0.001$  (corrected for multiple comparisons), PET showed a widespread pattern of hypometabolic areas. In particular, the parietal and frontotemporal cortices, the cuneus/precuneus, the cingulum, the frontal medial and precentral gyrus, and the transverse temporal gyrus were involved, additionally the bilateral thalamus (mainly dorso-medial subnucleus). All changes were, similar to the VBM results, nearly symmetrical. Improved understanding of this complex lesion pattern gained by in vivo group analyses like here might help to provide deeper insights into the general pathoanatomy of patients in the persistent VS.

Using high-resolution T1-weighted magnetic resonance images and a novel approach to shape analysis applied SIENAX software, Fernandez-Espejo et al. (2010) investigated thalamic global and regional changes in a sample of patients in a VS or an MCS. They found that total thalamic volume was significantly lower in patients than in healthy volunteers. Shape analysis revealed significant bilateral regional atrophy in the dorso-medial body in patients compared to controls; this atrophy was more widespread in VS than in MCS patients. Lower thalamic volume was significantly correlated with worsening of Disability Rating Scale (DRS) scores. Shape analysis suggested that the dorso-medial nucleus and the internal medullary lamina were the main regions responsible for this correlation. These findings suggest that MCS and VS patients present different patterns of regional thalamic abnormalities. In particular, VS patients showed a more widespread pattern of atrophy than controls, producing differences in global thalamic volume. MCS patients did not show volumetric differences compared to controls, and regionally they showed a less pronounced inward collapse in both the dorsal and ventral areas, with the anterior-ventral body significantly spared. Neuropathological studies have demonstrated that thalamic damage is less common in MCS than in VS patients (Jennett et al., 2001).

Another quantitative RM technique is the Magnetization Transfer Imaging (MTI). The MTI relies on the principle that protons bound in structures exhibit T1 relaxation coupling with protons in the aqueous phase. When an off-resonance saturation pulse is applied, it selectively saturates those protons that are bound in macromolecules. These protons subsequently exchange longitudinal magnetization with free water protons, leading to a reduction in the detected signal intensity (Sinson et al., 2001). The MTI may provide a quantitative index of the structural integrity of tissue and might be useful to study the outcome of patients with low levels of consciousness.

However, further studies, on larger groups of patients, need to be performed to confirm the usefulness of quantitative MRI in the assessment of the eventual neurological prognosis and outcome of these challenging patients.

### 3. Functional Magnetic Resonance Imaging and Positron Emission Tomography

At present a diagnosis of VS or MCS is made using prognostic markers from the patient's clinical history supported by detailed neurological and behavioral assessment by a multidisciplinary team over several weeks. However, the behavioral assessment of these patients predominately relies upon the subjective interpretation of observed spontaneous and volitional behavior. A diagnosis of VS is supported if the patient demonstrates no evidence of awareness of self or environment, no evidence of sustained, reproducible, purposeful or voluntary behavioral response to visual, auditory, tactile or noxious stimuli and critically no evidence of language comprehension or expression (MSTF, 1994). In contrast the patient in MCS demonstrates partial preservation of awareness of self and environment, responding intermittently, but reproducibly, to verbal command and therefore demonstrating some degree of basic language comprehension (Giacino et al., 2002).

PET and recently fMRI, by measurement of cerebral metabolism and brain activations in response to sensory stimuli, can provide important MR indices on the presence and location of any residual brain function.

PET is the most sensitive method to image trace amounts of molecules in vivo. Therefore this technique is used to measure in man or in the living animal biochemical and physiological processes in any organ with three dimensional resolution. The last 25 years have seen a rapid and still ongoing development in the production of positron emitters, radiochemical labeling techniques, tomograph technology and image reconstruction algorithms. Because of the possibility to see and measure quantitatively physiological disorders in an early stage, before permanent morphological damage has occurred, which will only then be visible in x-ray or magnetic resonance computer tomography, PET is finally finding its way from a sophisticated research tool into routine clinical diagnosis.

Resting cerebral metabolism derived from quantitative glucose uptake provides an indirect assessment of neuronal activity against which brain states may be compared quantitatively (Levy et al., 1987). All previous quantitative [<sup>18</sup>F] fluorodeoxyglucose–positron emission tomograph (FDG-PET) investigations of VS have correlated the condition with a global reduction of brain metabolic activity: Laureys et al. (1999) have assessed regional cerebral glucose metabolism (rCMR<sub>glu</sub>) and effective cortical connectivity in four patients in VS by means of statistical parametric mapping and FDG-PET. Results showed a common pattern of impaired rCMR<sub>glu</sub> in the prefrontal, premotor, and parietotemporal association areas and posterior cingulate cortex/precuneus in VS. In a next step, they demonstrated that in VS patients various prefrontal and premotor areas have in common that they were less tightly connected with the posterior cingulate cortex than in normal controls. Schiff et al. (2005) have described the first evidence of reciprocal clinical–pathological correlation with regional differences of quantitative cerebral metabolism. They studied five patients in VS with different behavioral features employing FDG-PET, MRI and magnetoencephalographic (MEG) responses to sensory stimulation. Each patient's brain expressed a unique metabolic pattern. The specific patterns of preserved metabolic activity identified in these patients reflect novel evidence of the modular nature of individual functional networks that underlie conscious brain function. In three of the five patients, co-registered PET/MRI correlate islands of relatively preserved brain metabolism with isolated fragments of behavior. Two patients had suffered anoxic injuries and demonstrated marked decreases in overall cerebral

metabolism. Two other patients with non-anoxic, multifocal brain injuries demonstrated several isolated brain regions with relatively higher metabolic rates. A single patient who suffered severe injury to the tegmental mesencephalon and paramedian thalamus showed widely preserved cortical metabolism. The variations in cerebral metabolism in chronic VS patients indicate that some cerebral regions can retain partial function in catastrophically injured brains.

fMRI is based on the increase in blood flow to the local vasculature that accompanies neural activity in the brain. This results in a corresponding local reduction in deoxyhemoglobin because the increase in blood flow occurs without an increase of similar magnitude in oxygen extraction (Roy & Sherrington, 1890; Fox & Raichle, 1985). Since deoxyhemoglobin is paramagnetic, it alters the T2 weighted magnetic resonance image signal (Ogawa et al, 1990). Thus, deoxyhemoglobin is sometimes referred to as an endogenous contrast enhancing agent, and serves as the source of the signal for fMRI. Using an appropriate imaging sequence, human cortical functions can be observed without the use of exogenous contrast enhancing agents on a clinical strength (1.5 T) scanner (Bandettini et al., 1992, 1993; Schneider et al, 1993).

Functional activity of the brain determined from the magnetic resonance signal has confirmed known anatomically distinct processing areas in the visual cortex (Schneider, et al, 1993), the motor cortex, and Broca's area of speech and language-related activities (Hinke et al., 1993; Kim et al., 1995). Further, a rapidly emerging body of literature documents corresponding findings between fMRI and conventional electrophysiological techniques to localize specific functions of the human brain (Atlas et al., 1996; Detre, et al, 1995; George, et al, 1995). Consequently, the number of medical and research centers with fMRI capabilities and investigational programs continues to escalate.

Several fMRI studies in the VS have confirmed the findings of previous PET studies. Di et al. (2007) used fMRI to evaluate differences between seven VS and four MCS patients in brain activation occurring in response to the presentation of the patient's own name, spoken by familiar voice (SON-FV). They prospectively studied residual cerebral activation to SON-FV in seven patients with VS and four with MCS. Two patients with VS failed to show any significant cerebral activation. Three patients with VS showed SON-FV induced activation within the primary auditory cortex. Only two of the VS patients, and all four MCS patients, showed activation not only in the primary auditory cortex but also in hierarchically higher-order associative temporal areas.

Three months after fMRI examination, these two VS patients had progressed to the MCS. This study showed that fMRI measurement might be a useful tool for pre-clinically distinguishing MCS-like cognitive processing in some patients behavioural classified as vegetative. Schiff et al. (2005) have tested the hypothesis that MCS patients retain active cerebral networks that underlie cognitive function. fMRI was employed to investigate cortical responses in two male adults with severe brain injuries resulting to MCS and in seven healthy volunteers. Three passive stimulation tasks were performed: tactile stimulation, auditory narratives of familiar events presented by a familiar person, and the same auditory passages without language-related content. Results have showed a residual brain activity of cortical systems involved in a potential cognitive and sensory function despite their inability to follow simple instructions or communicate reliably.

In conclusion, results of these studies we analyzed confirm the idea that PET and fMRI activation profiles may constitute useful adjunctive diagnostic methods when behavioral

findings are very limited or ambiguous, helping in differential diagnosis, prognostic assessment and identification of pathophysiological mechanism.

#### 4. Diffusion Tensor Imaging

Diffusion tensor imaging (DTI) is an emerging technique that complements traditional MRI and may be able to provide erstwhile unavailable information about the pathological substrates of DOC. DTI is a modified MRI technique that is sensitive to microscopic, three-dimensional water motion within tissue. In cerebrospinal fluid, water motion is isotropic, i.e., roughly equivalent in all directions. In white matter, however, water diffuses in a highly directional or anisotropic manner. Due to the structure and insulation characteristics of myelinated fibers, water in these white matter bundles is largely restricted to diffusion along the axis of the bundle. DTI can thus be used to calculate two basic properties: the overall amount of diffusion and the anisotropy (Douaud et al., 2007; Benson et al., 2007; Kraus et al., 2007; Ringman et al., 2007; O'Sullivan et al., 2004). It is only very recently that DTI has been used to evaluate white matter integrity in patients with DOC. For example, Voss et al. (2006) described two patients with traumatic brain injury: one who had remained MCS for 6 years and one who had recovered expressive language after 19 years diagnosed as MCS. In both cases, widespread changes in white matter integrity were observed. Interestingly, however, the increased anisotropy and directionality in the bilateral medial parieto-occipital regions that was observed in the second patient reduced to normal values in a follow-up scan performed 18 months later. This coincided with increased metabolic activity, leading the authors to interpret these observations as evidence of axonal regrowth in this region. Although this is certainly a landmark finding in two high spectrum MCS patients, it remains to be seen whether DTI has any diagnostic or prognostic utility in a broader group of patients with disorders of consciousness. To this end, Tollard et al. (2009) and Perlberg et al. (2009) have recently demonstrated that DTI measures in sub-acute severe traumatic brain injury may be a relevant biomarker for predicting the recovery of consciousness at 1 year. However, VS and MCS patients were classified in the same outcome category and potential differences between these two groups were not investigated. Although, in this context DTI has been generally used to address specific clinical problems, the study of white matter integrity in behaviorally defined states has a more basic relevance to understanding the relationship between brain and behavior in both health and disease. For example, in healthy volunteers, DTI techniques have been used recently to examine how structural changes underpin the behavioral changes that are related to learning a complex skill (Scholz et al., 2009). In a very recent study (Espejo et al., 2011), the integrity of white and grey matter regions was assessed in a group of 25 VS and MCS patients *in vivo*. In accordance with previous post-mortem work (Jennett et al., 2001; Adams et al., 1999) significant changes were observed in the integrity of the tissue in subcortical, thalamic and brainstem regions in the patients when compared to healthy volunteers. The precise location of this damage was not different between the MCS and VS sub-groups, which, again, accords well with previous post-mortem studies. However, an analysis of the MD values within two of these regions of interest (subcortical white matter and thalami), revealed significant differences between the patients meeting the clinical (behavioral) criteria defining VS and those who met the criteria defining MCS. Specifically, the VS patient group exhibited a decrease in the peak height of

the histograms derived from the subcortical white matter and the thalami and an increase in the peak width of the thalamic histogram.

In addition, DTI may be a valuable biomarker for the severity of tissue injury and a predictor for outcome. It reveals changes in the WM that are correlated with both acute GCS and Rankin scores at discharge (Huisman et al., 2004). Significant early reduction of anisotropy was observed in WM structures, in particular in the internal capsule and the corpus callosum, which are the sites most commonly involved by DAI (Arfanakis et al., 2002). Moreover, several regions recovered normal values of anisotropy 1 month after the injury (Arfanakis et al., 2002). Xu et al. (2007) found significant differences in the corpus callosum, internal and external capsule, superior and inferior longitudinal fascicles, and the fornix in TBI patients. They showed that FA and ADC measurements offered superior sensitivity compared to conventional MRI diagnosis of DAI. Salmond et al. (2006) reported increased diffusivity in TBI patients at least 6 months after their injury in the cerebellum, frontal, insula, cingulate, parietal, temporal, and occipital lobes. The anisotropy seems to be reduced both in the major WM tracts such as the corpus callosum and the internal and external capsule, and the associative fibers underlying the cortex. DTI has a number of advantages as an imaging biomarker of brain injury: first, it can be used to evaluate brain trauma in an unconscious or sedated patient; second, it could permit the evaluation of responses to treatment even when the clinical scores are inadequate for assessing the patient; third, quantitative DTI measurements are unlikely to be tainted by adverse central nervous system (CNS) effects of hypnotic drugs, unlike clinical scores; and fourth, DTI may be an important alternative marker, as low initial Glasgow Coma Scale scores are of limited value in predicting the prognosis (Huisman et al., 2004). Finally, Perlberg et al. (2009) showed significant FA differences between favorable and unfavorable 1-year outcome groups around four FA tracks: in inferior longitudinal fasciculus, posterior limb of the internal capsule, cerebral peduncle, and posterior corpus callosum.

## 5. Magnetic Resonance Spectroscopy

Proton MRS ( $^1\text{H}$ -MRS) is a non-invasive imaging technique that enables *in vivo* quantification of certain neurochemical compounds. Using the same equipment utilized for the conventional MRI, single-voxel  $^1\text{H}$ -MRS and multi-voxel Imaging ( $^1\text{H}$ -MRSI) or Chemical Shift Imaging (CSI) provide metabolic information on brain damage that may not be visible with the conventional structural imaging methods. Then  $^1\text{H}$ -MRS, added to traditional MRI, offers the possibility to study the brain activity combining information on structure and function.

Classically, the exploration of DOC is performed on 1,5 or 3 Tesla MR scanners and at intermediate or long echo time (TE) (135-288 ms). Long TE  $^1\text{H}$ -MRS detects the signal arising from four metabolites: N-acetyl-aspartate containing compounds (NAA), choline-containing compounds (Cho), creatine + phosphocreatine (Cre) and lactate (Lac). Short TE  $^1\text{H}$ -MRS identifies peaks from mobile lipids, Lac, alanine, NAA, Glutamate/Glutamine (Glx),  $\gamma$ -aminobutyric acid, Cre, Cho, myo-inositol, and scyllo-inositol (Figure 1).

NAA, which resonates at 2.02 parts per million (ppm), represents the largest proton metabolic concentration in the human brain after water. Indeed the concentration of NAA reaches on the order of 10  $\mu\text{mol/g}$ . NAA is widely interpreted as a neuronal marker and implicated in several neuronal processes, mitochondrial functioning and osmoregulation.

NAA synthesis occurs in mitochondria and requires acetyl-CoA and L-aspartic acid as substrates. NAA has been proposed to serve as a mitochondrial shuttle of acetyl-CoA used for fatty acid synthesis. Its peak decreases when there is neuron suffering or loss. The Cho peak (3.2 ppm) represents a combination of several choline-containing compounds, including free Cho, phosphorylcholine and glycerophosphorylcholine, and to a small extent acetylcholine. Free Cho acts as a precursor to acetylcholine, while glycerophosphorylcholine is a product of breakdown of membrane phosphatidylcholine and acts as an osmoregulator. Its peak increases when there is greater membrane turnover, cell proliferation or inflammatory process. The peak of Cre at 3.03 ppm represents total creatine and phosphocreatine supplies phosphate for conversion of ADP to ATP in creatine kinase reaction. Indeed these metabolites buffer the energy use and energy storage of cells. The level of total Cre mainly remains constant in many neuronal diseases. Thus, total Cre is often used as an internal reference (i.e., a denominator in metabolite signal ratio). The Lac (1.3 ppm) is an end product of anaerobic glycolysis, thus increase in Lac concentrations often serves as an index of altered oxidative metabolism, i.e., in ischemia, hypoxia, and cancer. Increases of Lac in the brain are often accompanied by decreased intracellular pH and high-energy phosphates. The proposed role of Lac is a source of energy for neurons and the transport of Lac plays an essential role in the concept of metabolic coupling between neurons and glia. Glutamate (Glu) is the highest excitatory neurotransmitter in concentration in the CNS. Its peak increases when neuronal and astrocytic activation impairs mitochondrial function and energy utilization. Indeed this process impairs Glu transport and its following enhancement is associated to cellular toxicity.

<sup>1</sup>H-MRS has been used for at least 15 years in the exploration of patients with altered consciousness, both to investigate the mechanisms of vigilance and to predict the possibilities of regaining consciousness.

Predicting outcome of patients with DOC is an integral part of clinical care, facilitating medical decision making and therapeutic intervention. Current neurological and neurophysiological methods do not enable prediction of outcome of these patients in early stages. Although conventional neuroimaging can provide important information for acute clinical management, its prognostic value is limited, particularly at early stage of injury resolution, owing to its poor sensitivity.

Several studies present in literature have demonstrated the value of <sup>1</sup>H-MRS as an accurate tool to predict patient's clinical outcome. Indeed many investigators have shown that correlation exists between metabolite changes and outcome of patients with DOC.

Previous studies using single-voxel technique have shown in brain-injured subjects a significant correlation between unfavorable outcome and reduction of marker NAA in occipitoparietal white and gray matter (WM and GM) (Brooks et al., 2000; Friedman et al., 1999; Ross et al., 1998; Yoon et al., 2005), frontal WM (Garnett et al., 2000), parietal WM (Shutter et al., 2004), brainstem (Carpentier et al., 2006), splenium of the corpus callosum (Sinson et al., 2001; Cecil et al., 1998), and thalamus (Uzan et al., 2003), increase in choline a marker for cell membrane disruption in frontal WM (Garnett et al., 2000) and occipitoparietal WM and GM (Brooks et al., 2000; Cecil et al., 1998; Ross et al., 1998; Yoon et al., 2005), and increase in Glx in occipital GM and parietal WM (Shutter et al., 2004).

In particular, NAA levels seem to discriminate patients who recovered from coma from those who died or remained in persistent VS (Ricci et al., 1997). Uzan et al. (2003) carried out a thalamic proton MRS in patients in VS resulting from severe TBI. They found that



NAA/Cr ratios were able to differentiate patients in VS who recovered awareness from those who remained in persistent VS. However, this alteration was not found in the thalamus of patients in VS resulting from mild TBI (Kirov et al., 2007).

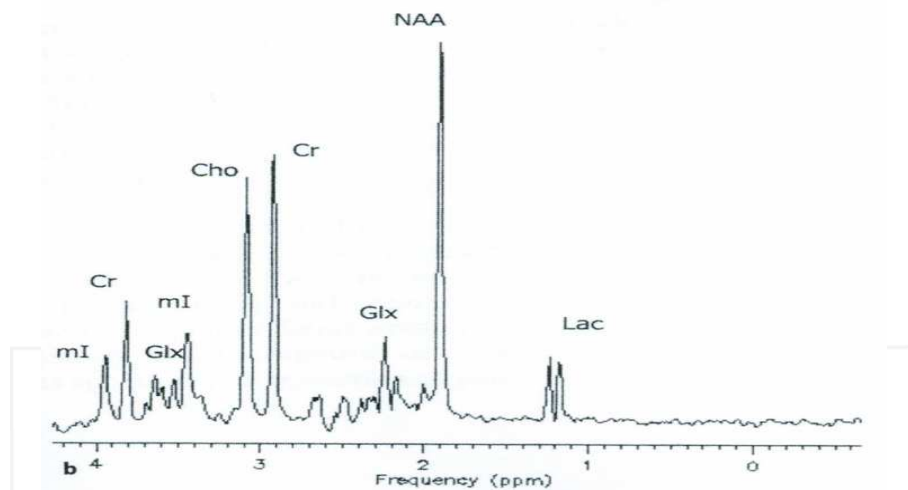
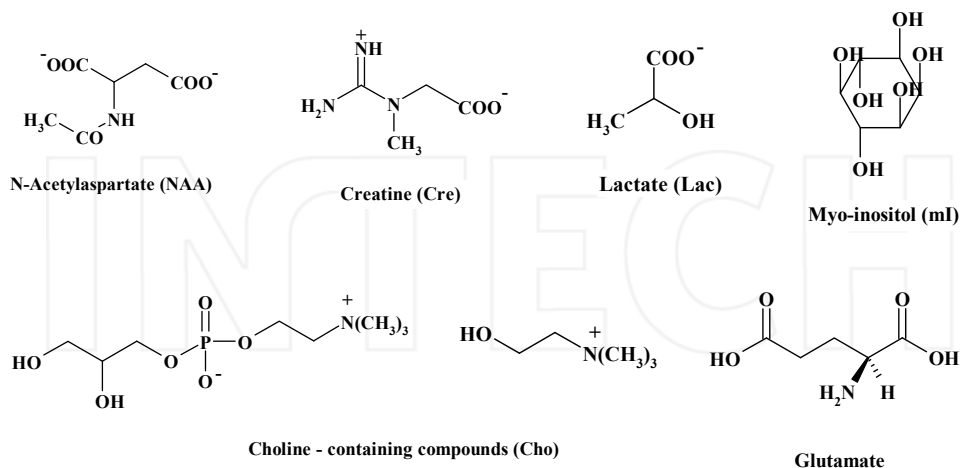


Fig. 1. Chemical structure and spectrum of main cerebral metabolites detected by  $^1\text{H}$ -MRS.

In some studies has been shown that the combination of imaging techniques may be useful to predict the long-term neurological outcome. A  $^1\text{H}$ -MRS study in the pons allowed separating of patients who recovered from patients with severe neurological impairment, death or in VS. In addition,  $^1\text{H}$ -MRS metabolic alterations were not correlated with anatomical MRI lesions, suggesting that these two techniques are strongly complementarity (Carpentier et al., 2006). Tollard et al. (2009) reported the first study on patients with TBI based on a combined quantitative analysis of  $^1\text{H}$ -MRS and DTI. This combined analysis was

97% specific for predicting an unfavorable outcome after 1 year, compared with 85% for DTI and 75% for  $^1\text{H}$ -MRS. Similarly, sensitivity was better with the combined analysis (86%) than with either DTI (79%) or MRS (75%).

To study metabolite changes from a wider area of the brain, with the advantage of identifying more anatomical and functional details, a few investigators have used  $^1\text{H}$ -MRSI (Holshouser et al., 2006; Marino et al. 2007; Shutter et al., 2006; Signoretti et al., 2002, 2008). This technique has an advantage over single-voxel  $^1\text{H}$ -MRS because generates individual spectra from multiple voxels at the same time. Also  $^1\text{H}$ -MRSI studies have highlighted close correlation between metabolite alterations and potential recovery.

Neurometabolite concentrations obtained soon after injury may be useful for predicting individual outcome. The decrease of NAA and the increase of Lac, seen by Marino et al. (2007) early after brain injury, were correlated with GOS score. Then these  $^1\text{H}$ -MRS data may be, at this stage, a reliable index of injury severity and disease outcome.

However it is need to note that  $^1\text{H}$ -MRS studies in patients with DOC are heterogeneous in terms of patient nature, injury types, time from cerebral damage, voxel location, methods and timing outcome assessment. In addition, in many studies the metabolite concentrations were expressed in terms of semiquantitative ratios. The assumption that the concentration of Cr as reference metabolite remains constant may be incorrect, especially in acute conditions. It is therefore advisable to obtain concentration expressed in standard units by applying absolute quantification. Some studies have expressed metabolite concentrations in term of absolute quantification (Brook et al., 2000; Friedman et al., 1999; Marino et al. 2007; Ross et al., 2000; Shutter et al., 2004).

Data reported so far demonstrate that MRS measure have the potential to provide new and important biological brain markers able to predict clinical outcome, helping in the therapeutic interventions, clinical and rehabilitative management of these patients, as well as to assist with family education.

## 6. Neurophysiological techniques

The neurophysiological approach to patients with DOC allows the recording of electrical activities of both CNS and Peripheral Nervous System (PNS) and provides a functional assessment, which can be integrated with data obtained mainly from morphological neuroimaging techniques (CT and MRI). The combined use of various neurophysiological examinations, such as Electroencephalogram (EEG), Evoked Related Potentials (ERPs), Transcranial Magnetic Stimulation (TMS), Deep Brain Stimulation (DBS), EEG in association with fMRI, contributes to the topographic and functional diagnosis of the various anatomical structures of the injured CNS and the PNS. The electrophysiological signals recorded from electrodes placed on the surface of the scalp reflect spatially the average post-synaptic potential originated by large neuronal populations. Experimental evidence and clinical observations suggest functional correlations among the neural mechanisms of sensory information, cognitive performance, sleep-wake cycle, alertness and electrophysiological signals generated by neuronal activity. A greater amount of patients can be assessed with electrophysiological techniques, including those who may not have access to a MRI due to geographic, financial, or physical (i.e., metal plates or pins) impairment.

The electroencephalogram in patients in VS has shown a spectrum of abnormalities with changes during the wake-sleep cycle. Patterns have included delta and theta activity and

spindle and alpha-like rhythms, but they are more diffusely distributed than in the typical posterior regions and are not reactive to sound, pain, and light stimuli (Chokroverty, 1975; Huges, 1978). During sleep, fewer muscle twitches are observed, but a REM sleep remains (Oksenberg et al., 2001). In most patients, the transition from wakefulness to sleep is accompanied by some desynchronization of the background activity. Very-low-voltage EEG activity is all that can be detected in some patients. In others, persistent alpha activity is the most remarkable feature. In around 10% of patients with VS, the EEG is nearly normal late in the course of disease but without evidence of vision-induced alpha blocking (Danze et al., 1989). There have been occasional reports of isoelectric EEGs in patients in a VS, although it has not been confirmed (Higashi et al., 1977; Mizrahi et al., 1985). Typical epileptiform activity is unusual in patients in VS, as seizure activity is (The Multi-Society Task Force on PVS, 1994). Clinical recovery from the vegetative state may be paralleled by diminished delta and theta activity and reappearance of reactive alpha rhythm. Indeed, Babiloni (2009) has observed that occipital source power in the alpha band (8-13 Hz) of resting EEG, when calculated with low-resolution electromagnetic tomography (LORETA), is correlated with recovery outcome at 3-month follow-up in a group of VS patients; those who made a behavioural recovery had higher resting alpha band power than those who did not make a significant recovery.

The EEG in MCS shows diffuse slowing brain activity, mainly of the theta band, and in most cases responsive to external stimuli. However, there are insufficient data as well as the typical pattern of MCS concerns. Evoked potentials have been studied in patients in a VS and showed normal brainstem auditory responses but abnormal somatosensory responses: prolonged conduction time or absence of scalp potentials. ERPs are more useful than EEG in the differential diagnosis between VS and MCS. ERPs studies focusing on the assessment of conscious awareness have frequently examined four specific components: the N100, the mismatch negativity (MMN), the P300, and the N400 (Connolly & D'Arcy, 2000).

In a recent work, the authors focused on the prediction of consciousness recovery in patients with post-traumatic VS. They used a classical two-stimulus oddball task to elicit the P300 using the patient's own name as deviant and a pure tone as standard stimulus ("subject's own name" paradigm). There is evidence that the amplitude of the P300 wave increases when more salient stimuli are used, such as the own first name instead of visual or auditory deviants. The authors found that P300 is a strong predictor of future recovery of consciousness in VS. This finding is in line with several studies that have confirmed the utility of P300 evoked by deviant tones to predict awakening and favourable outcome from coma and VS (Cavinato et al., 2009). In another study Cavinato et al., (2011) continue to using the "subject's own name" paradigm, but add a pure tone and an "other first name" paradigm. The authors instructed their patients to count the occurrence of deviant stimuli to better differentiate between patients in VS and MCS. The study indicates that in 6 out of 11 patients fulfilling the behavioral criteria for VS a reliable P300 component could be observed in all two conditions. These findings corroborate earlier reports showing that 38% of patients in VS generate a P300 wave. The patients in MCS exhibit significantly longer P300 latencies for the "subject's own name" and the "other first name" paradigms than patients in VS. The increase of P300 latencies for more complex and salient paradigms in MCS but not in VS might help in the difficult differential diagnosis of MCS vs. VS.

The TMS, for high temporal resolution, was proposed as an additional functional imaging technique for the study of cognitive function. To date only some studies have assessed VS and MCS patients with TMS. Moosavi et al. (1999) applied TMS to the hand and leg motor

area in 19 patients, few months after severe anoxic brain injury. Eleven patients were in VS, while eight patients were in MCS. The VS patient group differed from the MCS patient group in having a higher threshold, longer duration, and greater irregularity in the form of the response, while the threshold, form, and latency of motor evoked potentials (MEPs) from the MCS group were similar to healthy control subjects. In another study, TMS is used to monitor recovery. The authors examined MEPs from upper and lower limbs in 27 patients in the subacute period and then at 6 and 12 months post - ictus. During the study period, the authors observed an overall trend toward an increase and decrease of latency of MEPs. MEPs from upper and lower limbs progressively normalized in all patients, and at one year after trauma, only 12% of patients had mild abnormalities in MEP responses (Mazzini et al., 1999).

TMS elicited MEP responses in the majority of severely brain damage patients, and a trend toward an increase of amplitude and decrease of latency of MEPs could be observed during the recovery period.

DBS works on reactivating the cortex, aiming to produce a functional recovery. In study of Yamamoto et al. (2010) patients in VS were treated with DBS. Eight of the patients recovered from VS and were able to obey verbal commands at 13 and 10 months in the case of head trauma and a year and a half in the case of vascular disease after comatose brain injury, and no patients without DBS recovered from VS spontaneously within 24 months after brain injury.

In the last years the interest in using of neurophysiological investigations (EEG and EPs) in association with fMRI, has grown: the combination of these different neuroimaging techniques allows study of different components of the brain's activity (e.g., neurovascular coupling, electromagnetic activity) with both a high temporal and spatial resolution (Gosseries et al., 2008).

Clinical neurophysiology procedures are useful as easily performed, non invasive and repeatable at the bed side. These methods provide irreplaceable data about the degree of neuronal dysfunctions and their evolution, and gave also information to assess the outcome.

## 7. Cognitive recovery

A diagnosis of VS is made if a patient demonstrates no evidence of awareness of self or environment. No evidence of sustained, reproducible, purposeful or voluntary behavioral response to visual, auditory, tactile, or noxious stimuli and critically no evidence of language comprehension or expression. In contrast, the patient in a MCS demonstrates partial preservation of awareness of self and environment, responding intermittently, but reproducibly, to verbal command and therefore demonstrating some degree of basic language comprehension (Coleman et al., 2007).

VS and MCS patients may permanently remain in their clinical condition, or may partly or fully recover consciousness through different stages (Laureys et al., 2004). In this view, it's very important evaluate the residual cognitive across the time. In fact, it allows to make a differential diagnosis between VS and MCS, to monitoring functional changes of the patients, in order to customize the treatment, and, at least, to have a baseline evaluation of the patients in case of consciousness recovery. Nevertheless, the assessment of residual brain functions and the degree of recovery of these patients remain, still today, an opened issue in the medical field. To date, there have been no detailed studies of these patients evaluating cognitive changes and recovery over time through a specific neuropsychological battery (Neumann & Kotchoubey, 2004). This might suggest a new and possible way to further investigate the potential outcome of these challenging patients.

In this paragraph we try to identify some markers of consciousness with prognostic value, based on literature review. As it has been clearly established in clinical practice, significant spontaneous recovery frequently occurs during the subacute period (Wilson et al., 2002; Giacino & Trott 2004). Two factors can facilitate cognitive recovery of these patients: young age and immediate medical assistance after the injury.

Literature findings demonstrated that no clinical tools strongly predicted good outcome. In contrast, complementary examinations such as electrophysiological and functional neuroimaging studies objectively measure residual brain functions and are indicative of recovery of consciousness.

Several studies explore the prognostic validity of behavioural assessment scales (i.e. GOS, Coma Recovery Scale, Wessex Head Injury Matrix, Western Neuro Sensory Stimulation Profile, DRS, Functional Independence Measure), electrophysiological measures (ERPs), and functional neuroimaging (PET, fMRI), to predict outcome in patients with low levels of consciousness. Particular progress towards addressing this objective has been made using brain imaging techniques such as PET and fMRI. Schiff et al. (2002) suggested that rather than a complete loss of cortical function some patients retain "island" of preserved cognitive functions. PET and fMRI studies suggest that a higher-level associative cortical activation seems to predict recovery of consciousness with a 93% specificity and 69% sensitivity (Di et al., 2008). PET work has identified preserved responses to a variety of sensory stimuli, including photographs of familiar people, noxious, tactile (Laureys et al. 2000; Owen et al., 2002; Boly et al., 2004) in some vegetative and minimally conscious patients. Some studies underline the importance of the cognitive ERPs in the assessment of residual functions in comatose, VS, or MCS patients. As a general rule, early ERPs (such as the absence of cortical response on somatosensory evoked-potentials) predict bad outcome, while cognitive ERPs are indicative of recovery of consciousness (Vanhaudenhuyse et al., 2007). Moreover, auditory cognitive ERPs are useful to investigate residual cognitive functions, such as echoic memory (Mismatch Negativity), acoustical and semantic discrimination (P300), and incongruent language detection (N400). In VS patients, cognitive potential are more frequently obtained when using stimuli that are more ecologic or have an emotional content (such as the patients' own name) than when using classical sine tones.

Electrophysiological and functional neuroimaging studies may provide useful and objective information to the outcome and possibly cognition of patients with low levels of consciousness (Di et al., 2007). To date, there have been no detailed studies of these patients combining and correlating specific neuropsychological tools and functional imaging, in order to evaluate the cognitive changes and recovery over time (Bekinschtein et al, 2005). In spite of the important findings, functional neuroimaging cannot, and should not replace, clinical and behavioural evaluation as the criterion standard for assessment of patients with DOC. It offers an objective method of differentiating brain activity measured at rest and during external stimulation, but further studies are needed to assess the temporal evolution of individual patients' somatosensory and cognitive processing (Giacino et al., 2006). Despite converging agreement about the definition of persistent vegetative state, recent reports have raised concerns about the accuracy of diagnosis in some patients, and the extent to which, in a selection of cases, residual cognitive functions may remain undetected. Objective assessment of residual cognitive function can be extremely difficult as motor responses may be minimal, inconsistent, and difficult to document in many patients, or may be undetectable in others because no cognitive output is possible (Owen et al., 2002). There are no standards of care to guide the selection of rehabilitation assessment and treatment

procedures for patients with DOC (Neumann & Kotchoubey, 2004). Cognition abilities with theory of mind tasks, decision-making tasks, social performance tests and expanded cognitive assessment, to further characterize post-traumatic or hypoxic-ischemic brain damaged vegetative patients after recovery remain under evaluation at this time. The cognitive recovery in patients with DOC is a continual process rather than a step-by-step phenomenon and confirms that a good recovery assessment should include objective measures of behavioural, cognitive and functional domains, and neurophysiological data to support diagnosis. Survivors from a coma frequently suffer from long-lasting disability, which is mainly related to cognitive deficits. Such deficits include slowed information processing, deficits of learning and memory, of attention, of working memory, and of executive functions, associated with behavioral and personality modifications (Azouvi et al., 2009). An accurate cognitive assessment during the very first phase of the convalescence, when it is possible, is the first step for the management and the implementation of an individual and effective treatment.

Appropriate management requires an experienced inter-disciplinary as opposed to multidisciplinary team working style, whose skill repertoire equips them to recognize often-subtle improvements in cognitive function and act to maximize individual patient's quality of life. The current paucity of service provision for this vulnerable group of patients is highlighted. In fact, predicting the chances of recovery of consciousness and communication in patients who survive their coma, but transit in a VS or MCS remains a major challenge for their medical caregivers. Very few studies have examined the slow neuronal changes underlying functional recovery of consciousness from severe chronic brain damage.

## 8. Prognosis and rehabilitation

Determining the accurate prognosis of VS and MCS is a critical step in counseling families and determining appropriate treatment. Previous studies of prognosis in VS were limited by several factors: 1) because there were no accepted diagnostic criteria for MCS prior to 2002, some patients in MCS in those studies may have been diagnosed with VS; 2) it is more accurate to determine prognosis by the etiology of brain damage than merely by categorization in a clinical syndrome; and 3) retrospective experiential analysis of outcomes, such as that by the Multi-Society Task Force, committed the fallacy of the self-fulfilling prophecy because they included patients in their survival data who died primarily because their life-sustaining therapy was discontinued (Bernat et al., 2010). Nevertheless, the prognostic guidelines published in 1994 by Multi-Society Task Force on PVS have been generally accepted, showing a very low probability of recovering awareness once VS has been present for a year following TBI or for 3 months following hypoxic-ischemic neuronal injury (Bernat et al., 2009). Two recently published studies of prognosis in VS add useful data. Luauté and colleagues (Luauté et al., 2010), confirmed the prognostic guidelines of the Multi-Society Task Force in all the patients in VS. They studied and showed that age greater than 39 years and absence of the middle-latency auditory evoked potentials were independent early predictors of poor outcome irrespective of pathogenesis. Estraneo and colleagues (Estraneo et al., 2010), found that 88% of patients in VS in their serious conformed to the Multi-Society Task Force prognostic guidelines but 12% made late recoveries of awareness but only to the point of severe disability with MCS, most of whom had TBI. Because of varying pathophysiologies, prognostic indicators for MCS as a group have been difficult to establish whereas prognostic indicators in individual pathophysiologic subsets of

MCS (e.g. patients in MCS from TBI) have been more reliable (Bernat et al., 2010). The appropriate level of treatment of patients with chronic DOC depends on their diagnosis, prognosis and prior stated treatment values and preferences. Specialized neurorehabilitation units are the optimal treatment for patients with chronic DOC, at least until they are no longer improving. Patients have better functional outcomes when treated by skilled personnel who have been trained in neurorehabilitation. The difference between patients in VS and patients in MCS in their response to stimulatory treatment is noteworthy: patients in VS rarely improve as a consequence of stimulation but patients in MCS may improve to some extent. Treatment modalities that have been studied include environmental and sensory stimuli such as sounds, smells, touch, images and music. Pharmacologic stimuli include treatment with stimulants, levodopa, and dopamine agonists (by stimulating intact dopaminergic thalamic neurons), and selective serotonin reuptake inhibitor antidepressants. Electrical stimuli include deep brain stimulation of medial thalamic nuclei. Each of these modalities has been reported to improve functional responsiveness in some patients in MCS though there are few controlled studies. These therapies are also widely tried in patients in VS but a meta-analysis of their outcomes showed no consistent benefits (Bernat, 2006).

## 9. Sensory stimulation procedure

The use of unimodal and multimodal sensory stimulation for the treatment of comatose patient, both in the acute and prolonged states, has been advocated (Johnson et al., 1988). The rationale behind the use of these techniques is that all aspects of the patient must be treated; it is insufficient to attend to the maintenance of bodily well being alone. Sensory stimulation should at the least not have any ill-effects on the patient and could enhance the processes of recovery. S.L. Wilson et al. (1991) have observed patients diagnosed as being in prolonged coma, routinely treated according to a sensory stimulation protocol. They reported an evaluation of the efficacy of this procedure using the comparison of behavioral measures taken immediately prior and post-stimulation. Sensory stimulation treatment appears to be widely used with patients who are in VS arising from traumatic causes, but the term has to be regarded as generic rather than specific since sensory stimulation procedures appear to differ widely in content (Wilson et al., 1993). A number of studies have been published evaluating the effects of these treatments; some have methodological flaws, but the major difficulty in evaluating any treatment with this group of patients is getting sufficient subjects, so most of the published studies use relatively small numbers. Ideally, a large-scale matched control study would be looked for, which examined rate of recovery and long-term outcome. If sensory stimulation is rejected on the basis of lack of empirical evidence, then logically many other treatments used with medical settings should also be rejected. In real life, however, where definitive empirical evidence is not yet available, then clinicians can reasonably make decisions on treatment by combining clinical experience with inferences from scientific knowledge concerning related populations. For example, stimulation treatments which involve the use of some constant background stimulation within the patient's environment, such as TV or radio, have been justifiably criticized. As Wood points out, it is likely to be damaged within the brain that mediate selective attention are highly likely to be damaged within these patients; therefore it is unlikely they are going to be able to differentiate between stimuli in a situation where they are being bombarded with sensory input. In addition, habituation may exacerbate the problem.

## 10. Neuroimaging of self-consciousness and recovery

A recent meta-analysis by Northoff et al. (2006) of 27 PET and fMRI studies comparing hemodynamic brain responses obtained during active paradigms comparing processing of stimuli related to the self with those of non-self-referential stimuli identified activation in cortical midline structures in all studies and occurring across all functional domains (e.g. verbal, spatial, emotional, and facial). Cluster and factor analyses indicated functional specialization into ventral, dorsal, and posterior cortical midline areas. The latter encompasses the posterior cingulate cortex and adjacent precuneus and is considered to be involved in self-integration – that is linkage of self-referential stimuli to the personal context (Northoff et al., 2004). Neuroimaging studies during tasks involving self-processing (i.e. self-reflection, self-perspective and free thoughts) have also reported the activation of the medial prefrontal areas. Gusnard, Akbudak, Shulman, and Raichle (2001) for example showed medial frontal activation when subjects had to make two judgments in response to pleasant *vs* unpleasant pictures (i.e. self-referential) as compared to indoors *vs* outdoors pictures (i.e. not self-referential). The same area was also shown to be engaged when subjects had to make self-referential judgments about trait adjectives (i.e. self-referential processing) as compared to when they had to make case judgments (Kelley et al., 2002) and when subjects responded to statements requiring knowledge of, and reflection on, their own abilities, traits and attitudes, i.e. self-reflective thought (Johnson et al., 2002). Taking a self-perspective (i.e. being the agent of an history) also activated medial prefrontal/anterior cingulate cortices (Vogelely et al., 2001). Finally, activation of the mesiofrontal areas was describes in studies dealing with the conscious resting state, i.e. free thought (Mazoyer et al., 2001), a brain state which “instantiates functions that are integral to the self”. The recovery of consciousness of one VS patient has previously been linked to an increase in the functional connectivity within fronto-parietal network, (Laureys et al, 1999) encompassing the areas known to be most active in resting-state conditions (Gusnard et al., 2001). A growing body of evidence from Positron emission tomography (PET) and fMRI studies of healthy volunteers in a variety of altered states of consciousness has emphasized the role of this “default-mode” network in the genesis of awareness. In keeping with this, functional impairments to this network have been observed during sleepwalking, absence of seizures, deep sleep and anesthesia (Bassetti et al., 2000). fMRI has also proved its utility in identifying a number of cognitive functions which may be preserved in DOC patients, the results of which have, in some cases, proved prognostic of positive outcomes (Owen et al., 2008). In one such fMRI study investigating language processing, Coleman et. al found evidence of speech processing in three out of seven behaviorally non-communicative VS patients (Coleman et al., 2007). Six months after the scan, each of these patients had made a marked behavioral recovery relative to those patients who did not demonstrate comparable activations. Similar findings have also been reported for the neural responses observed when patients hear their own name (Di et al., 2007). Multimodal imaging approach can provide a powerful tool for assessing the mechanisms involved in the recovery of consciousness in DOC patients. Further longitudinal studies with large cohorts will prove useful in assessing its full value in predicting outcome. Such insights may then provide guidance for decisions relating to rehabilitation programs by those orientating these towards the effective stimulation of those functions that appear preserved, in order to maintain their integrity.



## 11. Conclusions

Patients with severe brain damage who are unable to communicate present several ethical concerns. Foremost is the concern that diagnostic and prognostic accuracy is certain, as treatment decisions typically include the possibility of withdrawal of life-support. Although imaging techniques have the potential to improve both diagnostic and prognostic accuracy, careful and repeated neurological assessment by a trained examiner remains best practice. Accurate clinical assessments of patients in these conditions must be obtained before they undergo neuroimaging. Moreover, in reports of neuroimaging studies, all relevant clinical details must be available for comparisons between studies.

Ethical concerns are commonly raised about the participation of patients with severe brain damage in neuroimaging studies. By definition, unconscious or minimally conscious patients cannot give informed consent to participate in clinical research and written approval must typically be obtained from family or legal representatives depending on governmental and hospital guidelines. Nonetheless, researchers studying these patients have been refused grants, ethics committee approval, and research publication; these decisions tend to be made on the basis that studies of patients who cannot provide consent are unethical. We prefer an ethical framework that balances access to research with medical advances alongside protection for defenseless patients. Severe brain damage represents an immense social and economic problem that warrants further research. Unconscious, minimally conscious, and locked-in patients deserve special procedural protections. However, it is important to stress that they are also at risk of being denied therapy that may be life-saving if clinical research cannot be done on these patient groups.

Patients who are in coma, VS, MCS, or locked-in syndrome present unique problems for diagnosis, prognosis, treatment, and everyday management. At the patient's bedside, assessment of cognitive function is difficult because voluntary movements may be very small, inconsistent, and easily exhausted. Functional neuroimaging will never replace the clinical assessment of patients with altered states of consciousness. Nevertheless, using population norms it can provide an objective measure of the regional distribution of cerebral activity at rest and under various conditions of stimulation. The quantification of brain activity differentiates patients who sometimes only differ by a brief and small movement of a finger. In our opinion, PET, MRS and fMRI will increase substantially our understanding of patients with severe brain damage.

## 12. References

- Adams, J.H.; Jennett, B.; McLellan, D.R.; Murray, L.S. & Graham D.I. The neuropathology of the vegetative state after head injury. *Journal of Clinical Pathology*, Vol. 52, No. 11, (November 1999), pp. 804-806, ISSN 1472-4146
- Ammermann, H.; Kassube, K.J.; Lotze, M.; Gut, E.; Kaps, M. et al. MRI brain lesion patterns in patients in anoxia-induced vegetative state. *Journal of the Neurological Sciences*, vol. 260, N° 1-2, (September 2007), pp. 65-70, ISSN 0022-510X
- Arfanakis K.; Houghton V.M.; Carew J.D.; Rogers, B.P.; Dempsey, R.J. et al. Diffusion tensor MR imaging in diffuse axonal injury. *American Journal of Neuroradiology*, Vol.23, No.5, (May 2002), pp. 794-802, ISSN 1936-959X
- Atlas, S.W.; Howard, I.I.R.S.; Maldjian, J.; Alsop, D.; Detre, J.A. et al. Functional magnetic resonance imaging of regional brain activity in patients with intracerebral gliomas:

- findings and implications for clinical management. *Neurosurgery*, Vol.38, No2, (February 1996), pp. 329-338, ISSN 0148-396X
- Azouvi, P.; Vallat-Azouvi, C. & Belmont, A. Cognitive deficits after traumatic coma. *Progress in brain research*, Vol. 117, (October 2009), pp. 89-110, ISSN 0079-6123
- Babiloni, C.; Sarà, M.; Vecchio, F.; Pistoia, F.; Sebastiano, F. et al. Cortical sources of resting-state alpha rhythms are abnormal in persistent vegetative state patients. *Clinical Neurophysiology*, Vol. 120, No. 4, (April 2009), pp. 719-729, ISSN 1388-2457
- Bandettini, P.A.; Jesmanowicz, A.; Wong, E.C. & Hyde, J.S. Processing strategies for time-course data sets in functional MRI of the human brain. *Magnetic Resonance in Medicine*, Vol.30, No2, (August 1993), pp. 161-173, ISSN 0740-3194
- Bassetti, C.; Vella, S.; Donati, F.; Wielepp, P. & Weder, B. SPECT during sleepwalking. *Lancet*, (August 2000), Vol. 356, No. 9, pp. 484-485, ISSN 0140-6736
- Bekinschtein, T.; Tiberti, C.; Niklison, J.; Tamashiro, M.; Ron, M. et al. Assessing level of consciousness and cognitive changes from vegetative state to full recovery. *Neuropsychological rehabilitation*, Vol. 15, No. 3/4, (July-September 2005), pp. 307-322, ISSN 0960-2011
- Benson, R.; Meda, S.; Vasudevan, S.; Kou, Z.; Govindarajan, K.A. et al. Global white matter analysis of diffusion tensor images is predictive of injury severity in traumatic brain injury. *Journal of Neurotrauma*, Vol. 24, No. 3, (March 2007), pp. 446-459, 0897-7151
- Bernat, J.L. Chronic disorders of consciousness. *Lancet*, (June 2006) Vol. 367, No. 9528, pp.1181-1192, ISSN 0140-6736
- Bernat, J.L. Chronic consciousness disorders. *Annual Review of Medicine*, (February 2009), Vol. 60, No. 1, pp. 381-392, ISSN 0066-4219
- Bernat, J.L. The natural history of chronic disorders of consciousness. *Neurology*, (July 2010), Vol. 75, No. 3, pp. 206-207, ISSN 0028-3878
- Boly, M.; Faymonville, M.; Damas, P.; Lambermont, B.; Del Fiore, G. et al. Auditory processing in severely brain injured patients: differences between the minimally conscious state and the vegetative state. *Archives of neurology*, Vol. 61, No. 2, (February 2004), pp. 233-238, ISSN 0003-9942
- Brooks, W.M.; Stidley, C.A.; Petropoulos, H.; Jung, R.E.; Weers, D.C. et al. Metabolic and cognitive to human traumatic brain injury: a quantitative proton magnetic resonance study. *Journal of Neurotrauma*, Vol.17, No.8, (August 2000), pp. 629-640, ISSN 0897-7151
- Carpentier, A.; Galanaud, D.; Puybasset, L.; Mullar, J.C.; Lescot, T. et al. Early morphologic and spectroscopic magnetic resonance in severe traumatic brain injuries can detect "invisible brain stem damage" and predict "vegetative states". *Journal of Neurotrauma*, Vol.23, No.5, (May 2006), pp. 674-685, ISSN 0897-7151
- Cavinato, M.; Freo, U.; Ori, C.; Zorzi, M.; Tonin, P. et al. Post-acute P300 predicts recovery of consciousness from traumatic vegetative state. *Brain Injury*, Vol.23, No. 12, (November 2009), pp. 973-80, ISSN 0269-9052
- Cavinato, M.; Volpato, C.; Silvoni, S.; Sacchetto, M.; Merico, A. et al. Event-related brain potential modulation in patients with severe brain damage. *Clinical Neurophysiology*, Vol. 122, No. 4, (April 2011), pp. 719-24, ISSN 1388-2457
- Cecil, K.M.; Hills, E.C.; Sandel, M.E.; Smith, D.H.; McIntosh, T.K. et al. Proton magnetic resonance spectroscopy for detection of axonal injury in the splenium of the corpus

- callosum of brain-injured patients. *Journal of Neurosurgery*, Vol.88, No.5, (May 1998), pp. 795-801, ISSN 0022-3085
- Chokroverty, S. "Alpha-like rhythms" in electroencephalograms in coma after cardiac arrest. *Neurology*, Vol. 25, No. 7, (July 1975), pp. 655-663, ISSN 0028-3878
- Coleman, M.R.; Rodd, J.M.; Davis, M.H.; Johnsrude, I.S.; Menon, D.K. et al. Do vegetative patients retain aspects of language comprehension? Evidence from fMRI. *Brain*, Vol. 130, No. 10, (September 2007), pp. 2494-2507, ISSN 0006-8950
- Connolly, J.F. & D'Arcy, R.C. Innovations in neuropsychological assessment using event-related brain potentials. *International Journal of Psychophysiology*, Vol. 37, No. 1, (July 2000), pp. 31-47, ISSN 0167-8760
- Danze, F.; Brule, J.F. & Haddad, K. Chronic vegetative state after severe head injury: clinical study; electrophysiological investigations and CT scan in 15 cases. *Neurosurgical Review*, Vol. 12, No.1, (March 1989), pp. 477-499, ISSN 0344-5607
- De Young, S. & Grass, R.B. Coma recovery program. *Rehabilitation Nursing*, (March 1987), Vol. 12, No 7, pp. 121-124, ISSN 0278-4807
- Di, H.; Boly, M.; Weng, X.; Ledoux, D. & Laureys, S. Neuroimaging activation studies in the vegetative state: predictors of recovery. *Clinical Medicine*, Vol. 8, No. 5, (October 2008), pp. 502-507, ISSN 1473-4893
- Di, H.; Yu, S.M.; Weng, X.C.; Laureys, S.; Yu, D. et al. Cerebral response to patient's own name in the vegetative and minimally conscious state. *Neurology*, Vol. 68, No. 12, (March 2007), pp. 895-899, ISSN 0028-3878
- Douaud, G.; Smith, S.; Jenkinson, M.; Behrens, T.; Johansen-Berg, H. et al. Anatomically related grey and whitematter abnormalities in adolescent-onset schizophrenia. *Brain*, Vol.130, No.9, (September 2007), pp. 2375-2386, ISSN 0006-8950
- Estraneo, A.; Moretta, P.; Loreto, V.; Lanzillo, B.; Santoro L. et al. Late recovery after traumatic, anoxic or hemorrhagic long-lasting vegetative state. *Neurology*, (July 2010), Vol. 75, No. 3 pp. 239-245, ISSN 0028-3878
- Fernandez-Espejo, D.; Junque, C.; Bernabeu, M.; Roig-Rovira, T.; Vendrell P. et al. Reductions of thalamic volume and regional shape changes in the vegetative and the minimally conscious states. *Journal of Neurotrauma*, vol. 27, N° 7, (July 2010), pp. 1187-1193, ISSN 0897-7151
- Fernández-Espejo, D.; Bekinschtein, T.; Monti, M.M.; Pickard, J.D.; Junque, C. et al. Diffusion weighted imaging distinguishes the vegetative state from the minimally conscious state. *Neuroimage*, Vol.51, No.1, (January 2011), pp. 103-112, ISSN 1053-8119
- Fox, P.T. & Raichle, M.E. Stimulus rate determines regional brain blood flow in striate cortex. *Annals of Neurology*, Vol.17, No3, (March 1985), pp.303-305, ISSN 0364-5134
- Friedman, S.D.; Brooks, W.M.; Jung, R.E.; Chiulli, S.J.; Sloan, J.H. et al. Quantitative proton MRS predicts outcome after traumatic brain injury. *Neurology*, Vol.52, No.7, (April 1999), pp. 1384-1391, ISSN 0028-3878
- Garnett, M.R.; Blamire, A.M.; Corkill, R.G.; Cadoux-Hudson, T.A.D.; Rajagopalan B. et al. Early proton magnetic resonance spectroscopy in normal-appearing brain correlates with outcome in patients following traumatic brain injury. *Brain*, Vol.123, No.10, (October 2000), pp. 2046-2054, ISSN 0006-8950
- George, J.S.; Aine, C.J.; Mosher, J.C.; Schmidt, M.D.; Ranken, D.M. et al., Mapping function in the human brain with magneto encephalography, anatomical magnetic

- resonance imaging, and functional magnetic resonance imaging. *Journal of Clinical Neurophysiology*, Vol.12, No5, (September 1995), pp. 406-429 ISSN 1676-2649
- Giacino, J.Y.; Ashwal, S.; Childs, N.; Cranford, R.; Jennett, B. et al. The minimally conscious state: definition and diagnostic criteria. *Neurology*, Vol. 58, No.3, (February 2002), pp. 349-353, ISSN 0028-3878
- Giacino, J.T. & Trott, C.T. Rehabilitative management of patients with disorders of consciousness: Grand rounds. *Journal of head trauma rehabilitation*, Vol. 19, No. 3, (May-June 2004) pp. 254-265, ISSN 1550-509X
- Giacino, J.T.; Hirsch, J.; Schiff, N. & Laureys, S. Functional neuroimaging for assessment and rehabilitation planning in patients with disorders of consciousness. *Archives of physical medicine and rehabilitation*, Vol. 87, Suppl. 2, (December 2006), pp. S67-S75, ISSN 0003-9993
- Gosseries, O.; Demertzi, A.; Noirhomme, Q.; Tshibanda, J.; Boly, M. et al. Functional neuroimaging (fMRI, PET and MEG): what do we measure? *Revue Medical de Liege*, Vol. 63, No. 5-6, (May-Jun 2008), pp.231-7, ISSN 0370-629X
- Gusnard, D.A. & Raichle, M.E. Searching for a baseline: functional imaging and the resting human brain. *Nature Reviews Neuroscience*, (October 2001), Vol. 2, No. 2, pp. 685-694, ISSN 1471-003X
- Higashi, K.; Sakata, Y.; Hatano, M.; Abiko, S.; Ihara, K. et al. Epidemiological studies on patients with a persistent vegetative state. *Journal of Neurology, Neurosurgery & Psychiatry*, Vol. 40, No. 9, (September 1977), pp. 876-885, ISSN 0022-3050
- Hinke, R.M.; Hu, X.; Stillman, A.E.; Kim, S.G.; Merkle, H. et al. Functional magnetic resonance imaging of Broca's area during internal speech. *NeuroReport*, Vol.4, No6, (June 1993) pp. 675-678 ISSN 0959-4965
- Holshouser, B.A.; Tong, K.A.; Ashwal, S.; Oyoyo, U.; Ghamsary, M. et al. Prospective longitudinal proton magnetic resonance spectroscopic imaging in adult traumatic brain injury. *Journal of Magnetic Resonance Imaging*, Vol.24, No.1, (July 2006), pp. 33-40, ISSN 1522-2586
- Hughes J.R. Limitations of the EEG in coma and brain death. *Annals of the New York Academy Sciences*, Vol. 315, No. 1, (November 1978), pp. 121-136, ISSN 0077-8923
- Huisman, T. A.; Schwamm, L. H.; Schaefer, P. W.; Koroshetz, W.J.; Shetty-Alva, N. et al. Diffusion tensor imaging as potential biomarker of white matter injury in diffuse axonal injury. *American Journal of Neuroradiology*, Vol.25, No.3, (March 2004), pp. 370-376, ISSN 1936-959X
- Jennett, B.; Adams, J.H.; Murray, L.S. & Graham, D.I. Neuropathology in vegetative and severely disabled patients after head injury. *Neurology*, vol. 56, N° 4, (February 2001), pp. 486-490, ISSN 0028-3878
- Johnson, D.A. & Roethig-Johnston, K. Coma stimulation: a challenge to occupational therapy. *British Journal of Occupational Therapy*. (April 1988), Vol. 51, No 5, pp. 88-90, ISSN 1477-6006
- Juengling, F.D.; Kassubek, J.; Huppertz, H.; Krause, T. & Els, T. Separating functional and structural damage in persistent vegetative state using combined voxel-based analysis of 3-D MRI and FDG-PET. *Journal of the Neurological Sciences*, vol. 228, N° 2, (February 2005), pp. 179- 184, ISSN 0022-510X
- Kaisti, K.K.; Metsahonkala, L.; Teras, M.; Oikonen, V.; Aalto, S. et al. Effects of surgical levels of propofol and sevoflurane anesthesia on cerebral blood flow in healthy subjects


- studied with positron emission tomography. *Anesthesiology*, (June 2002), Vol. 96, No. 6, pp. 1358-1370, ISSN 1528-1175
- Kim, K.; Hirsch, J.; DeLaPaz, R.L.; Relkin, N. & Lee, K.M. Comparison of cortical areas activated by primary and secondary languages in human brain using functional magnetic resonance imaging (fMRI). *Abstracts: Society of Neuroscience*, Vol.21, No3, (1993), pp.1763, ISSN 0270-6474
- Kirov, I.; Fleysher, L.; Babb, J.S.; Silver, J.M.; Grossman, R.I. et al. Characterizing "mild" in traumatic brain injury with proton MR spectroscopy in the thalamus: initial findings. *Brain Injury*, Vol.21, No.11, (October 2007), pp. 1147-1154, ISSN 0269-9052
- Kraus, M.F.; Susmaras, T.; Caughlin, B.P.; Walker, C.J.; Sweeney J.A. et al. White matter integrity and cognition in chronic traumatic brain injury: A diffusion tensor imaging study. *Brain*, Vol.130, No.19, (October 2007), pp. 250-2519, ISSN 0006-8950
- Laureys, S.; Goldman, S.; Phillips. C.; Van Bogaert, P.; Aerts, J. et al. Impaired effective cortical connectivity in vegetative state: preliminary investigation using PET. *Neuroimage*, Vol.9, No4, (April 1999), pp.377-82, ISSN 1053-8119
- Laureys, S.; Lemaire, C.; Maquet, P.; Phillips, C. & Franck, G. Cerebral metabolism during vegetative state and after recovery to consciousness. *Journal of Neurology, Neurosurgery & Psychiatry*, (April 1999), Vol. 67, No. 10, p. 121, ISSN 0022-3050
- Laureys, S.; Faymonville, M.E.; Luxen, A.; Lamy, M.; Franck, G. et al. Restoration of thalamocortical connectivity after recovery from persistent vegetative state. *Lancet*, (May 2000), Vol. 355, No. 9217, pp. 1790-1791, ISSN 0140-6736
- Laureys, S.; Faymonville, M.E.; Degueldre, C.; Fiore, G.D.; Damas, P. et al. Auditory processing in the vegetative state. *Brain*, Vol. 123, No. 8, (August 2000), pp. 1589-601, ISSN 0006-8950
- Laureys, S.; Owen, A.M. & Schiff, N.D. Brain function in coma, vegetative state, and related disorders. *Lancet Neurology*, Vol. 3, No. 9, (September 2004), pp. 537-546, ISSN 0028-3878
- Laureys, S. & Boly, M. The changing spectrum of coma. *Nature Clinical Practice Neurology*, Vol.10, No.10, (October 2008), pp. 544-546, ISSN 1745-8358
- Levy, D.E.; Sidtis, J.J.; Rottenberg, D.A.; Jarden, J.O.; Strother, S.C.; Dhawan, V. et al. Differences in cerebral blood flow and glucose utilization in vegetative versus locked-in patients. *Annals of Neurology*, Vol.22, No6, (December 1987), ISSN 0364-5134
- Lewinn, E.B. The coma arousal team. *Royal Society of Health Journal*, (May 1980) Vol. 1, No 4, pp. 19-21, ISSN 1477-6006
- Luautè, J.; Maucort-Boulch, D. & Tell, L. Long-term outcomes of chronic minimally conscious and vegetative states. *Neurology*, (June 2010), Vol. 75, No. 3, pp. 246-252, ISSN 0028-3878
- Maquet, P. Functional neuroimaging of normal human sleep by positron emission tomography. *Journal of Sleep Research*, (April 2000), Vol. 9, No. 3 pp. 207-231, ISSN 0962-1105
- Marino, S.; Zei, E.; Battaglini, M.; Vittori, C.; Buscalferri, A. et al. Acute metabolic brain changes following traumatic brain injury and their relevance to clinical severity and outcome. *Journal of Neurology, Neurosurgery and Psychiatry*, Vol.78, No.5, (May 2007), pp. 501-507, ISSN 0022-3050
- Mazzini, L.; Pisano, F.; Zaccala, M.; Miscio, G.; Gareri, F. et al. Somatosensory and motor evoked potentials at different stages of recovery from severe traumatic brain injury.

- Archives of Physical Medicine and Rehabilitation*, Vol. 80, No. 1, (January 1999), pp. 33-39, ISSN 0003-9993
- Medical aspects of the persistent vegetative state (1). The Multi-Society Task Force on PVS. *New England Journal Medicine*, Vol.330, No21, (May 1994), pp. 1499-508, ISSN 0028-4793
- Mizrahi, E.M.; Pollack, M.A. & Kellaway, P. Neocortical death in infants: behavioral, neurologic, and electroencephalographic characteristics. *Pediatric Neurology*, Vol. 1, No.5, (Sep-Oct 1985), pp.302-305, ISSN 0887-8994
- Moosavi, S.H.; Ellaway, P.H.; Catley, M.; Stokes, M.J. & Haque, N. Corticospinal function in severe brain injury assessed using magnetic stimulation of the motor cortex in man. *Journal of the Neurological Sciences*, Vol. 164, No. 2, (April 1999), pp. 179-186, ISSN 0022-510X
- Neumann, N., & Kotchoubey, B. Assessment of cognitive functions in severely paralysed and severely brain-damaged patients: neuropsychological and electrophysiological methods. *Brain Research Protocols*, Vol. 14, No. 1, (November 2004), pp. 25-36, ISSN 1385-299X
- Ogawa, S.; Lee, T.M.; Nayak, A. S. & Glynn, P. Oxygenation-sensitive contrast in magnetic resonance image of rodent brain at high magnetic fields. *Magnetic Resonance in Medicine*, Vol.14, No1, (April 1990) pp.68-78, ISSN 0740-3194
- Oksenberg A.; Gordon C.; Arons E. & Sazbon L. Phasic activities of rapid eye movement sleep in vegetative state patients. *Sleep*, Vol. 24, No. 6, (February 2001), pp. 703-706, ISSN 1550-9109
- O'Sullivan, M.; Singhal, S.; Charlton, R. & Markus H.S. Diffusion tensor imaging of thalamus correlates with cognition in CADASIL without dementia. *Neurology*, Vol.62, No.5, (March 2004), pp. 702-707, ISSN 0028-3878
- Owen, A.M.; Menon, D.K.; Johnsrude, I.S.; Bor, D.; Scott, S.K.; et al. Detecting residual cognitive function in persistent vegetative state. *Neurocase*, Vol. 8, No. 5, (2002), pp. 394-403, ISSN 1355-4794
- Owen, A.M. & Coleman, M.R. Functional neuroimaging of vegetative state. *Nature Reviews Neuroscience*, (March 2008), Vol. 9, No. 9, pp.235-243, ISSN 1471-003X
- Perlbarg, V.; Puybasset, L.; Tollard, E.; Lehericy, S.; Benali, H. et al. Relation between brain lesion location and clinical outcome in patients with severe traumatic brain injury: A diffusion tensor imaging study using voxel-based approaches. *Human Brain Mapping*, Vol.30, No.12, (December 2009), pp: 3924-3933, ISSN 1097-0193
- Rader, M.A.; Alston, J.B. & Ellis, D.W. Sensory stimulation of severely brain-injured patients. *Brain Injury*, (August 1988), Vol. 3, No. 6, pp.141-147, ISSN 0269-9052
- Ricci, R.; Barbarella, G.; Musi, P.; Boldrini, P.; Trevisan, C. et al. Localised proton MR spectroscopy of brain metabolism changes in vegetative patients. *Neuroradiology*, Vol.39, No.5, (May 1997), pp. 313-319, ISSN 0028-3940
- Ringman, J.M.; O'Neill, J.; Geschwind, D.; Medina, L.; Apostolova, L.G. et al. Diffusion tensor imaging in preclinical and presymptomatic carriers of familial Alzheimer's disease mutations. *Brain*, Vol.130, No.7 (July 2007), pp. 1767-1776, ISSN 0006-8950
- Ross, B.D.; Ernst, T.; Kreis, R.; Haseler, L.J.; Bayer, S. et al. <sup>1</sup>H MRS in acute traumatic brain injury. *Journal of Magnetic Resonance Imaging*, Vol.8, No.4, (August 1998), pp. 829-840, ISSN 0028-3878
- Roy, C. & Sherrington, C. On the regulation of the blood-supply of the brain. *The Journal of Physiology*, Vol.11, No1-2, (January 1980), pp.85-108, ISSN 1469-7793

- Salek-Haddadi, A.; Lemieux, L.; Merschhemke, M.; Friston, K.J.; Duncan, J.S. et al. Functional magnetic resonance imaging of human absence seizures. *Annals of Neurology*, (April 2003), Vol. 53, No. 10, pp. 663-667, ISSN 0364-5134
- Salmond, C. H.; Menon, D. K.; Chatfield, D. A.; Williams, G.B.; Pena, A. et al. Diffusion tensor imaging in chronic head injury survivors: Correlations with learning and memory indices. *Neuroimage*, Vol.29, No.1, (January 2006), pp. 117-124, ISSN 1053-8119
- Schiff, N.D.; Ribary, U.; Moreno, D.R.; Beattie, B.; Kronberg, E. et al. Residual cerebral activity and behavioural fragments can remain in the persistently vegetative brain. *Brain*, Vol.125, No6, (Jun 2002), pp.1210-1234, ISSN 0006- 8950
- Schiff, N.D.; Rodriguez-Moreno, D.; Kamal, A.; Kim, K.H.S.; Giacino, J.T. et al. fMRI reveals large-scale network activation in minimally conscious patients. *Neurology*, Vol.64, No11, (December 2005), pp. 1843-1843-a, ISSN 0028-3878
- Schneider, W.; Noll, D.C. & Cohen, J.D. Functional topographic mapping of the cortical ribbon in human vision with conventional MRI scanners. *Nature*, Vol.365, No6442, (September 1993), pp. 150-152, ISSN 0028-0836
- Scholz, J.; Klein, M.C.; Behrens, T.E. & Johansen-Berg H. Training induces changes in white-matter architecture. *Nature Neuroscience*, Vol. 12, No.11, (November 2009), pp. 1370-1371, ISSN 1097-6256
- Shutter, L.; Tong, K.A. & Holshouser B.A. Proton MRS in acute traumatic brain injury: Role for glutamate/glutamine and choline for outcome prediction. *Journal of Neurotrauma*, Vol.21, No.12, (December 2004), pp. 1693-1705, ISSN 0897-7151
- Shutter, L.; Tong, K.A.; Lee, A. & Holshouser, B.A. Prognostic role of proton magnetic resonance spectroscopy in acute traumatic brain injury. *Journal of Head Trauma Rehabilitation*, Vol.21, No.4, (August 2006), pp. 334-349, ISSN 1550-509X
- Signoretti, S.; Marmarou, A.; Aygok, G.A.; Fatouros, P.P.; Portella, G. et al. Assessment of mitochondrial impairment in traumatic brain injury using high-resolution proton magnetic resonance spectroscopy. *Journal of Neurosurgery*, Vol.108, No.1, (January 2008), pp. 42-52, ISSN 0022-3085
- Signoretti, S.; Marmarou, A.; Fatouros, P.; Hoyle, R.; Beaumont, A. et al. Application of chemical shift imaging for measurement of NAA in head injured patients. *Acta Neurochirurgica. Supplement*, Vol.81, (2002), pp. 373-375, ISSN 0065-1419
- Sinson, G.; Bagley, L.J.; Cecil, K.M.; Torchia, M.; McGowan, J.C. et al. Magnetization transfer imaging and proton MR spectroscopy in the evaluation of axonal injury: Correlation with clinical outcome after traumatic brain injury. *American Journal of Neuroradiology*, Vol.22, No.1, (January 2001), pp. 143-151, ISSN 1936-959X
- Steriade, M. Active neocortical processes during quiescent sleep. *Archives Italiennes Biologie*, (September 2001), Vol.139, no. 1/2, pp. 37-51, ISSN 0003-9829
- The Multi-Society Task Force on Persistent Vegetative State. Medical aspects of the persistent vegetative state (1). *The New England Journal of Medicine*, Vol. 330 , No. 21 , (May 1994), pp. 1499-508, ISSN 0028-4793
- Tollard, E.; Galanaud, D.; Perlberg, V.; Sanchez-Pena, P.; Le Fur, Y. et al. Experience of diffusion tensor imaging and <sup>1</sup>H spectroscopy for outcome prediction in severe traumatic brain injury: Preliminary results. *Critical Care Medicine*, Vol.37, No.4, (April 2009), pp. 1448-1455, ISSN 1364-8535
- Tshibanda, L.; Vanhauzenhuyse, A.; Boly, M.; Soddu, A.; Bruno, M.A. et al. Neuroimaging after coma. *Neuroradiology*, vol. 52, N° 1, (January 2010), pp. 15-24, ISSN 0028-3940

- Uzan, M.; Albayram, S.; Dashti, S.G.; Aydin, S.; Hanci, M. et al. Thalamic proton magnetic resonance spectroscopy in vegetative state induced by traumatic brain injury. *Journal of Neurology, Neurosurgery and Psychiatry*, Vol.74, No.1, (January 2003), pp. 33-38, ISSN 0022-3050
- Vanhaudenhuyse, A.; Laureys, S. & Perrin, F. Cognitive Event-Related Potentials in Comatose and Post-comatose States. *Neurocritical Care*, Vol. 8, No. 2, (2008), pp. 262-270, ISSN 1541-6933
- Voss, H.U.; Uluc, A.M.; Dyke, J.P.; Watts, R.; Kobylarz, R.J. et al. Possible axonal regrowth in late recovery from the minimally conscious state. *The Journal of Clinical Investigation*, Vol. 116, No. 7, (July 2006), pp. 2005-2011, ISSN 0021-9738
- Wilson, F.C.; Harpur, J.; Watson, T. & Morrow, J.I. Vegetative state and minimally responsive patients-regional survey, long-term case outcomes and service recommendations. *Neurorehabilitation*, Vol. 17, No. 3, (January 2002), pp. 231-236, ISSN 1053-8135
- Wilson, S.L. & Graham E. Powell, Karen Elliott, and Helen Thwaites .Sensory stimulation in prolonged coma: four single case studies. *Brain Injury*, Vol.5, No.4, (Oct-Dec 1991), pp.393-400, ISSN 0269-9052
- Wilson, S.L. & Mc Millan, T.M. A review of the evidence for the effectiveness of sensory stimulation treatment for coma and vegetative states. *Neuropsychological Rehabilitation*, (May 1993) Vol. 3, No 8, pp. 149-160 ISSN 0960-2011
- Wood, R.L. Critical analysis of the concept of sensory stimulation for patients in vegetative states. *Brain Injury*, (September 1991), Vol. 5, No. 5, pp. 401-409, ISSN 0006-8950
- Xu, J.; Rasmussen, I.A.; Lagopoulos, J. & Håberg, A. Diffuse axonal injury in severe traumatic brain injury visualized using high-resolution diffusion tensor imaging. *Journal of Neurotrauma*, Vol.24, No. 5, (May 2007), pp, 753-765, ISSN 0897-7151
- Yamamoto, T.; Katayama, Y.; Kobayashi, K.; Oshima, H.; Fukaya, C. et al. Deep brain stimulation for the treatment of vegetative state. *European Journal of Neuroscience*, Vol. 32, No. 7, (October 2010), pp. 1145-1151, ISSN 1460-9568
- Yoon, S.J.; Lee, J.H.; Kim, S.T. & Chun M.H. Evaluation of traumatic brain injured patients in correlation with functional status by localized <sup>1</sup>H MR spectroscopy. *Clinical Rehabilitation*, Vol.19, No.2, (February 2005), pp. 209-215, ISSN 1477-0873





## **Neuroimaging - Cognitive and Clinical Neuroscience**

Edited by Prof. Peter Bright

ISBN 978-953-51-0606-7

Hard cover, 462 pages

**Publisher** InTech

**Published online** 16, May, 2012

**Published in print edition** May, 2012

The rate of technological progress is encouraging increasingly sophisticated lines of enquiry in cognitive neuroscience and shows no sign of slowing down in the foreseeable future. Nevertheless, it is unlikely that even the strongest advocates of the cognitive neuroscience approach would maintain that advances in cognitive theory have kept in step with methods-based developments. There are several candidate reasons for the failure of neuroimaging studies to convincingly resolve many of the most important theoretical debates in the literature. For example, a significant proportion of published functional magnetic resonance imaging (fMRI) studies are not well grounded in cognitive theory, and this represents a step away from the traditional approach in experimental psychology of methodically and systematically building on (or chipping away at) existing theoretical models using tried and tested methods. Unless the experimental study design is set up within a clearly defined theoretical framework, any inferences that are drawn are unlikely to be accepted as anything other than speculative. A second, more fundamental issue is whether neuroimaging data alone can address how cognitive functions operate (far more interesting to the cognitive scientist than establishing the neuroanatomical coordinates of a given function - the where question).

### **How to reference**

In order to correctly reference this scholarly work, feel free to copy and paste the following:

Silvia Marino, Rosella Ciurleo, Annalisa Baglieri, Francesco Corallo, Rosaria De Luca, Simona De Salvo, Silvia Guerrera, Francesca Timpano, Placido Bramanti and Nicola De Stefano (2012). Neuroimaging and Outcome Assessment in Vegetative and Minimally Conscious State, Neuroimaging - Cognitive and Clinical Neuroscience, Prof. Peter Bright (Ed.), ISBN: 978-953-51-0606-7, InTech, Available from: <http://www.intechopen.com/books/neuroimaging-cognitive-and-clinical-neuroscience/neuroimaging-and-outcome-assessment-in-vegetative-and-minimally-conscious-state>

**INTECH**  
open science | open minds

### **InTech Europe**

University Campus STeP Ri  
Slavka Krautzeka 83/A  
51000 Rijeka, Croatia  
Phone: +385 (51) 770 447  
Fax: +385 (51) 686 166

### **InTech China**

Unit 405, Office Block, Hotel Equatorial Shanghai  
No.65, Yan An Road (West), Shanghai, 200040, China  
中国上海市延安西路65号上海国际贵都大饭店办公楼405单元  
Phone: +86-21-62489820  
Fax: +86-21-62489821

INTECH

INTECH