

# We are IntechOpen, the world's leading publisher of Open Access books Built by scientists, for scientists

6,900

Open access books available

186,000

International authors and editors

200M

Downloads

Our authors are among the

154

Countries delivered to

TOP 1%

most cited scientists

12.2%

Contributors from top 500 universities



WEB OF SCIENCE™

Selection of our books indexed in the Book Citation Index  
in Web of Science™ Core Collection (BKCI)

Interested in publishing with us?  
Contact [book.department@intechopen.com](mailto:book.department@intechopen.com)

Numbers displayed above are based on latest data collected.  
For more information visit [www.intechopen.com](http://www.intechopen.com)



# Kyphosis Physiotherapy from Childhood to Old Age

Jean Claude de Mauroy  
*Clinique du Parc – Lyon,  
France*

## 1. Introduction

### 1.1 Definition: Morphotypology of the spine in the sagittal plane

Antero-posterior deviations of the spine are usually named kyphosis and lordosis.

The term kyphosis comes from the Greek: arched back applying to vertebral deviations with posterior convexity, usually thoracic.

The term lordosis means curved and is applied to vertebral deviations with anterior convexity, usually lumbar.

There in the sagittal plane a physiological thoracic kyphosis and a physiological lumbar lordosis which limits can be specified with the morphotypology study.

### 1.2 Defining a reference position

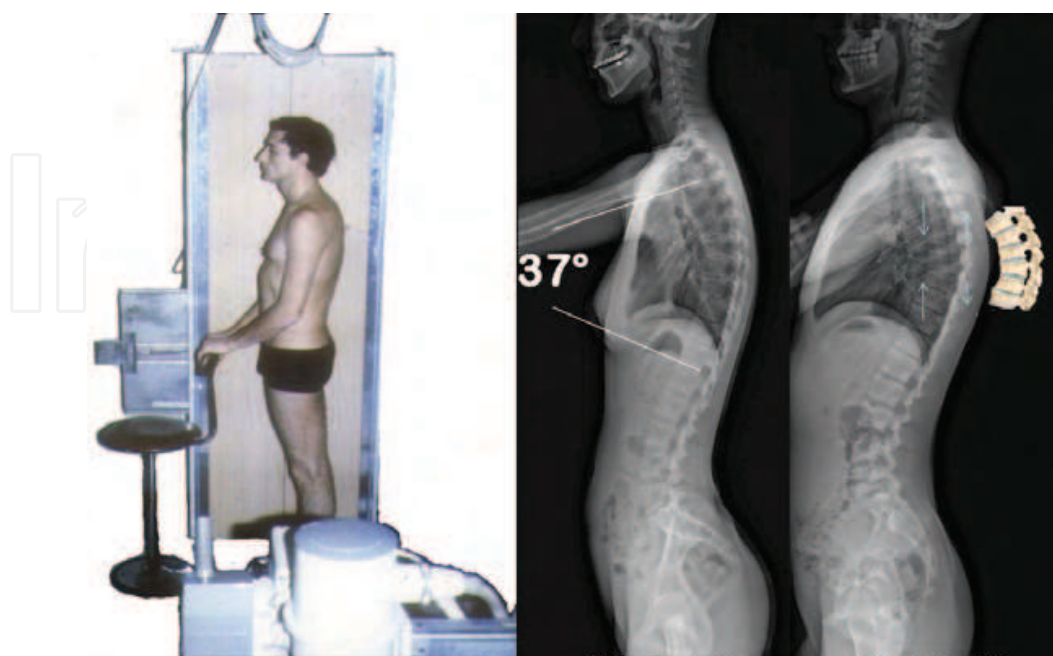


Fig. 1. Reference position, physiologic kyphosis and vicious circle of kyphosis

Unlike the frontal plane, in the sagittal plane, the upper limbs are projected onto the spine. The displacement of the upper limbs modifies the sagittal static. We chose to perform X-rays in a position closest to the clinical reference: lower limbs vertical, feet joint together, shoulder girdle and trunk released, looking horizontally. (Stagnara et al, 1982) With the agreement of some volunteers, we made two X-rays one in the clinical position (with upper limb overlaid on the spine), the other, in one of the positions normally used by radiologists ie: hands crossed in front of the chest, hands joint behind the neck, hands crossed on the head, horizontal upper limbs. None of these positions gave satisfaction so we described a specific position. The upper limbs are forward with hands resting on a support. The forearms are horizontal and the arms slightly tilted to avoid an overlapping with the spine. (Figure 1)

This position is now used by many American authors. (Voutsinas & MacEwen, 1986)

### **1.3 Statistical distribution of the angle of kyphosis: the gold standard**

Kyphosis is the angle formed by the top plate of T4 and the lower plate of the vertebra, which is most inclined to the horizontal at the thoracolumbar junction.

The average angulation is of  $37^{\circ} \pm 9^{\circ}$ . Many authors have confirmed these parameters. (Korovessis & all, 1988; Fon & all, 1980; Vedentam & all, 1998)

The distribution of these parameters is Gaussian: the mode, the mean and the median are identical and there is a relative symmetry of the curve, which allows the use of statistical laws of normality.

There is no significant difference between men and women and finally there is no correlation between lordosis and kyphosis.

### **1.4 Correlation between clinical and radiological assessment**

There is a correlation between clinical measures of C7 and L2 plumb line values (Figure 3) and radiological angulation. It is therefore possible to validate the evolution of a kypho-lordosis by clinical examination or better through a CAD CAM system of three-dimensional representation of the external shape of the trunk.

## **2. Biomechanics of the spine in the sagittal plane**

The study of the sagittal aspect of the spine needs to include a consideration of the biomechanical aspects of the spine. One needs to consider the existing physiological curves in the sagittal plane as the spine is not straight in this plane as it is in the frontal plane.

### **2.1 A powerful brake: The anterior longitudinal ligament of the spine**

The anterior longitudinal ligament inserts on the anterior vertebral body. Anatomically on a spine cadaver stripped of its muscles, it takes more than 27 kg of traction to cause a creep extension and an eventual rupture. (Figure 2)

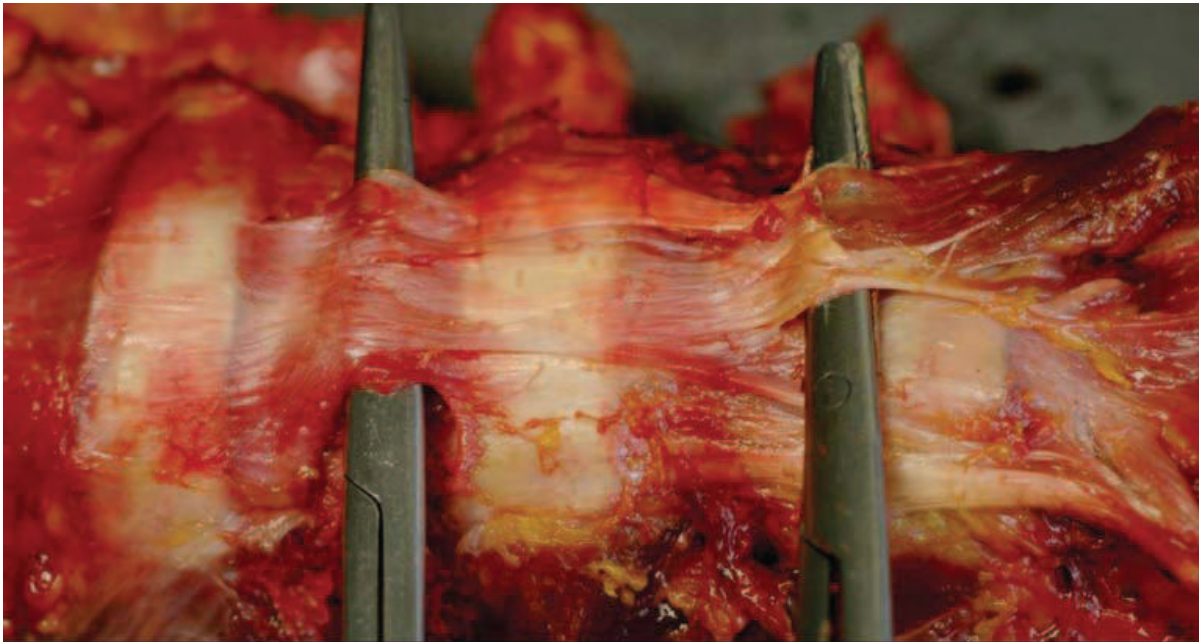


Fig. 2. The length modification of the common anterior vertebral longitudinal ligament requires a continuous traction of more than 27 Kg.

A retraction can be suspected when the patient reported pain when he is trying to correct the kyphosis spontaneously.

Clinically, this resistance can be assessed by conducting a test in hyper-extension. If the child is unable to correct their kyphosis one can measure the distance from the manubrium to a table to assess the effectiveness of physiotherapy. (Figure 4)

Radiologically, we could have a supine radiograph, the apex of the kyphosis resting on a hard pad. The lordosis is stabilized by bending the lower limbs; the upper limbs are in extension lying backward on the table. In our practice, we used x-ray in plaster cast for reducibility test and we do not take another X-ray to avoid excessive irradiation of the patient.

The concept of creeping is fundamental to understand treatment. Creeping can be defined as a definitive increase in the length of the ligament; it is opposed to the elasticity when the ligament regains its original length as the tension is released. For a creep, a continuous traction on the ligament must be performed for more than three weeks; this is the aim of the plaster cast in conservative orthopaedic treatment. The action of physiotherapy is limited in time; it remains at the level of elasticity. The removable brace does not cause a creep until it is worn continuously, which explains the importance of compliance in the results of treatment.

## 2.2 The vicious circle of adolescent and senescent kyphosis

### 2.2.1 Fragility of the vertebral body

The fragility of the vertebral body can occur either during adolescence in Scheuermann's disease or in old age, with osteoporosis. (Scheuermann, 1921)

Scheuermann's disease is a defect in the growth plate at the cortex of the main core of the vertebral body. The cortical plate is altered and deformed, secondarily disk will enter the

interior of the vertebral body (Schmorl's hernia), which causes a narrowing of the disc and stiffness. (Aufdermaur & Spycher 1986; Ippolito & all 1985)

Osteoporosis affects mainly the cortex of the vertebral body as a whole and the vertebral body collapses like a pancake. The quality of trabecular bone is important because it changes the modulus of elasticity of the entire vertebral body. Physiotherapy can improve the quality of trabecular bone.

### **2.2.2 Poor sitting position and antalgic posture in Kyphosis**

Three important points are discussed.

- In an open kinetic chain, the more the apical vertebral body moves away from the line of gravity while standing or sitting, the more the pressure will be important. Indeed the posterior musculature is forced to contract to maintain balance. In closed kinetic chain, such as when the forearms rely on the work plan, the pressure will be lower.
- A second element to be considered is the reduction of pressure on the vertebral body, when the back is applied to a rigid support. While sitting in the listening position, the spine properly applied on the backrest of the chair reduces pressure on the anterior part of the vertebra. Also sitting in the writing position when the thorax is applied on the anterior border of the table, the pressures are lower.
- The third element is the triangulation. While sitting in the listening position with both forearms and spine resting on a support, the brain will automatically correct the kyphosis. Sitting in the writing position with chondrocostal and forearms support allows the brain to correct the position of the spine in space. (Figure in scoliosis chapter)

### **2.2.3 Apical vertebra wedging**

On a weak vertebral bone, poor sitting position will place an increased pressure on the anterior wall of the vertebral body and kyphotic deformity with a reduction in the height of the anterior wall compared with the posterior wall. It is this asymmetry that causes kyphosis. It is less clear in adult osteoporosis, because the entire vertebral body is altered and the overall reduction in height is predominant. A correct posture maintained by physiotherapy may prevent the progression of kyphosis (Murray & all, 1993).

### **2.2.4 Asymmetrical growth (Hueter-Volkman laws)**

During the teenage years, growth is inhibited when the pressures on the growth plate are too strong. On the contrary when the pressures are lower growth is stimulated. We, therefore, find a greater increase of the posterior arch compared to the vertebral body. In adulthood remodelling is much slower as bone mass is renewed every seven years, but the deformation is similar to that of puberty. (Figure 1)

## **3. Clinical examination and assessment of the spine in the sagittal plane**

The order of examination of the spine in the sagittal plane will now be discussed

The standing position of the clinical examination needs to be reproducible. Ankles and toes are placed in a neutral anatomical posture. The lower limbs are stretched straight limiting an



excessive recurvatum. The trunk and upper limbs are relaxed, palms of the hands on the lateral thighs, the eye is looking horizontally (de Mauroy, 1983).

### 3.1 Static: Kyphotic hump, sagittal plumbline

A plumb line is placed on the axis of the column, the extremity located at the apex of the sacral cleft (S2). The hand holding the plumb line is close to the occiput. The line is usually at a tangent to the apex of the kyphosis in T7 (corresponding to the tip of the scapula).

The arrow is measured at the high thoracic C7 level where the spinous process is more prominent. The arrow of lumbar lordosis is measured at the apex of clinical lordosis usually in L2 (L3 vertebra corresponding to a line passing horizontally through the two iliac crests).

The plumbline measure of kyphosis is half the sum of the C7 plumbline and the L2 plumbline.

In the sagittal plane, the overall harmonious balance of the spine is appreciated: tragus, acromion, trochanter, and ankles must be superimposed with the plumb line on the same vertical.

The examination in the sitting position is unclear because it can be very variable. We must examine the child when seated in front of us at the beginning of medical consultation. (Figure 3)

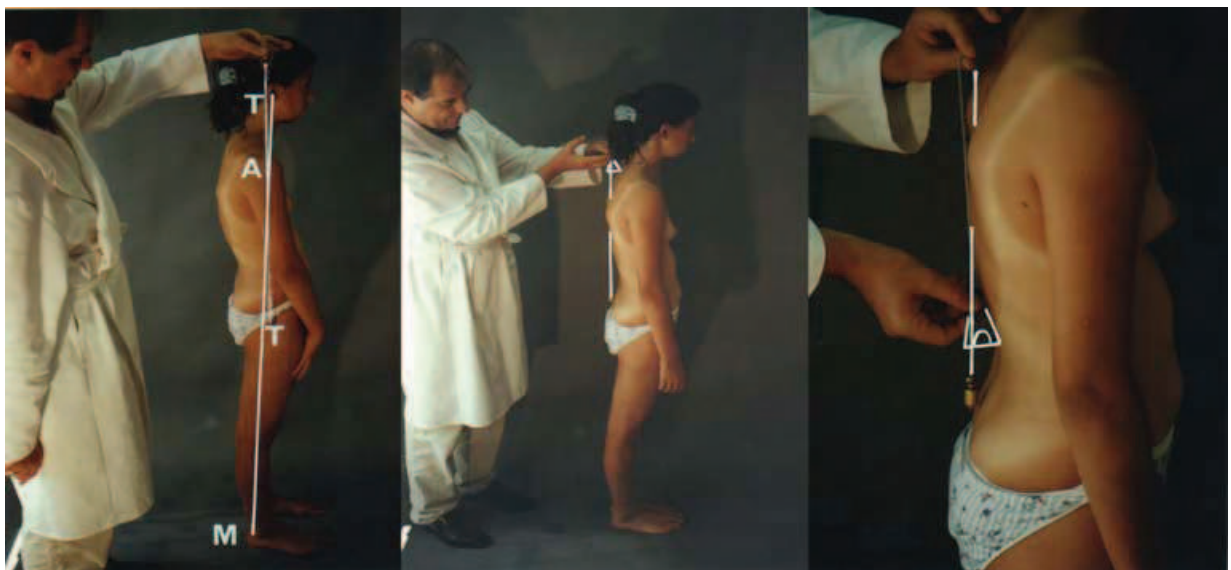

Fig. 3. Harmonious Kyphosis with TATM alignment | Cervical plumbline | Lumbar plumbline

### 3.2 Clinical diagnosis:

#### 3.2.1 Angular & round kyphosis

##### Angular kyphosis

- Congenital kyphosis with bone defect is mostly seen at birth. When the discovery of the defect occurs after the age of 3 years, a night Milwaukee brace with crossbar centred on the defect can prevent the aggravation.

- Major forms found before the age of 3 years need surgery: an epiphysiodesis can be performed since the age of 6 months. (Winter, 1977; Lonstein, 1999; McMaster & all, 1999)
- The compaction of the vertebral body fractures, usually at the thoracolumbar junction is often angular. (Shen & Shen, 1999)
- Achondroplasia: after lumbar spinal stenosis it is the second problem of these patients. Kyphosis is located at the thoracolumbar junction and should be systematically prevented by the brace. In most severe cases anterior surgery performed with a distractor needs to be performed
- Morquio disease of autosomal recessive causes a significant thoracolumbar kyphosis with platyspondily. In these patients there is also hypoplasia of the odontoid with unstable atlas / axis justifying caution in rehabilitation with neck mobilisation.

### Round or regular kyphosis

Corporeal deformation is distributed over more than three vertebrae.

- Idiopathic: Stagnara and de Mauroy have defined this new entity of progressive kyphosis without Scheuermann's disease during puberty by analogy with idiopathic scoliosis. The vicious circle still described can explain idiopathic kyphosis (de Mauroy & Stagnara, 1979).
- Dystrophy or spinal growth or Scheuermann's disease is a defect of the growth plate of the vertebral body at the cortical level weakening the vertebral body and can cause wedging. The vertebral rim or secondary nucleus of ossification is inhibited only by hyperpressure related to kyphosis and in case of conservative orthopaedic treatment the brace can compensate the anterior wedging and restore a rectangular vertebral body (Sorensen, 1964; Ali & all, 1999; Lowe, 1999).  
This disease stops at the end of growth, when the growth cartilage is no longer active.
- Neurological: the paralysis of abdominal muscles is compensated by a lumbar kyphosis. Paralysis of the spinal muscles causes lumbar lordosis; the patient uses the remaining muscles as struts to keep the spine in a position where it can be effective. Alterations in psychomotor developments are accompanied by postural abnormalities: either global kyphosis in children who are on a wheel chair, or lordosis, which are sometimes very unstable with athetosis.
- Post-laminectomy: the extension of the laminectomy at facet joints and posterior ligaments results in 80% of kyphosis being very severe (Lonstein, 1987; Albert & Vacarro, 1998). When the Milwaukee brace is insufficient an anterior fusion should be considered.
- Radiotherapy in neuroblastoma and Wilms' tumour sterilizes the growth cartilage and retraction of soft tissues and can cause kyphosis; which usually reacts favourably to the brace.
- Rheumatology: Ankylosing Spondylitis has symptoms that can begin before the age of 20. As a result we can observe a disharmonious kyphosis with loss of lordosis and forward projection of the trunk. In addition to the anti-inflammatory therapy, rehabilitation includes daily prone postures and the practice of lordotic activity such as swimming. In extreme cases when the eyes can no longer look horizontally, one can realize posterior osteotomies to balance the head on the line of gravity.

- Osteoporosis in adults: the high thoracic kyphosis is often painful. This type of kyphosis is worse when associated with a loss of physiological lordosis.

### 3.2.2 Clinical forms: High thoracic, thoracic, thoraco-lumbar

The apex of the kyphosis will be located on x-ray and by palpation and used to determine the appropriate physical therapy and conservative orthopaedic treatment. We can distinguish three different types of kyphosis:

- The high thoracic kyphosis or cervico-thoracic. It is accompanied by a forward projection of the neck and the shoulder in internal rotation.
- The medium thoracic kyphosis which is the more common type of kyphosis. It can be harmonious when accompanied by a lumbar hyperlordosis; however, it is disharmonious when the lordosis decreases.
- The thoracolumbar kyphosis is the most common form of non congenital angular kyphosis.

## 3.3 Dynamic clinical assessment

### 3.3.1 Dynamic balance

At our centre we use the rating of Russe and Gerhard quantifying the amplitudes of the spine in three planes (Russe & Gerhard, 1976).

In the sagittal plane, the axis of motion is a horizontal line across the two femoral heads. A virtual line joining the acromion to the trochanter is drawn; the position of this line from the vertical to maximal extension and flexion will be recorded. The finger-floor distance corresponds to the stiffness in the spine and pelvis.

For example: S 30-0-90 (which means 30° extension to 90° of flexion).

In the frontal plane, a virtual line joins the top of the medial gluteal fold (S2) to the C7 spinous process. The extreme positions of the virtual line from left to right are noted: F 35-0-30 F (from 35° lateral left tilt to right lateral 30°).

In the horizontal plane, the left to right rotation of the shoulder girdle is measured in relation to the fixed pelvic girdle. A first horizontal virtual line is joining the two femoral heads, at shoulder level, one second horizontal line is joining the two humeral heads: R 45-0-45 (45 ° rotation of the shoulder girdle from left and right). (Figure 4)

### 3.3.2 Testing vertebral reducibility: Direct rigidity

In the prone position, we make a systematic examination of the spine:

- Palpation of the skin in search of fibromyalgia at the cervico-scapular.
- The percussion of the spinous process can cause pain usually corresponding to Scheuermann's disease at the apex of the kyphosis and at the thoracolumbar junction.
- The muscle contractions will be found at the lumbar painful areas and at the apex of the kyphosis.
- The painful transverse pressure at the lumbosacral junction evokes a spondylolysis, common in cases of hyper-lordosis (7% of the population).



- A dehiscence at the spinous process evokes a spina bifida.
- The rigid spine will be assessed in this position, the upper limbs are positioned laterally along the body and the patient is asked to move with hyperextension of the spine. The distance manubrium-table is measured appreciating the reducibility of kyphosis in this position and we note the location of the rigid zone (apex of the kyphosis or thoracolumbar junction).

### 3.3.3 Testing scapular and pelvic girdle reducibility: The indirect rigidity

In the supine position, we evaluate the stiffness of the pelvic and scapular girdles.

Under the pelvis, the hamstrings are often retracted and the popliteal angle is measured: if the thigh is vertical, the popliteal angle is the angle between the vertical and the leg when trying to extend the entire leg.

In order to measure the retraction of anterior plane including the ilio psoas, the patient is asked to hold his knee; starting from the vertical the leg is lowered in extension asking the patient to relax the trunk and to bend the opposite limb. At the end of the movement a pelvic tilt is seen and the distance heel-table is measured corresponding to the start of the pelvic tilt.

At the shoulder level, the upper limbs are lowered in extension and anterior retraction is assessed by the distance table-elbow ensuring that the spine remains straight without hyperlordosis. (Figure 4)

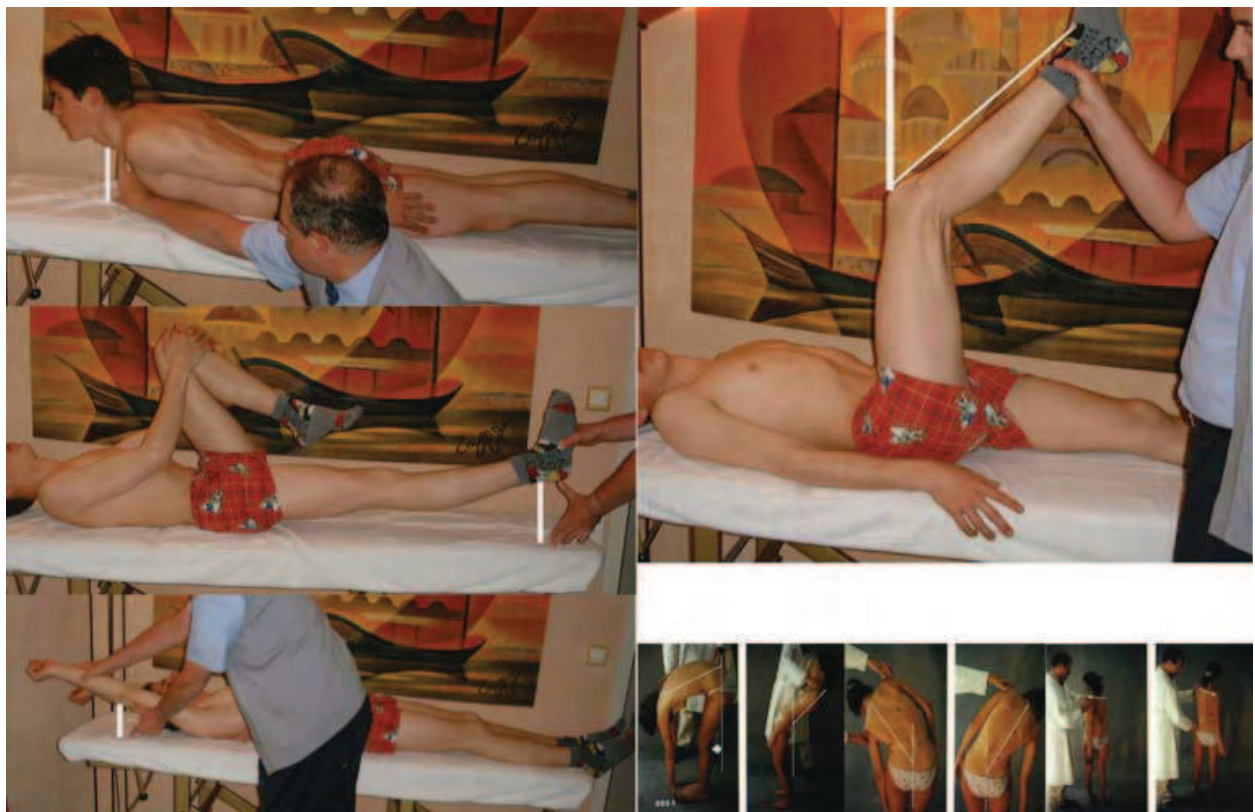

Fig. 4. Direct and indirect rigidity testing | Russe and Gerhard dynamic assessment

### 3.4 Muscle impairment

- The flexibility of anterior thoracic muscles is decreased in patients with kypholordosis. The role of the ilio psoas is difficult to assess, usually its retraction causes a lordosis and sometimes a compensatory kyphosis.
- The thoracic extensor muscles must be stretched. The posterior muscles are weak and mostly hypotonic, which means that they cannot maintain their contraction over time and they get tired very quickly.

### 3.5 Evaluation of thoracic pain in adolescents

Pain has special characteristics in children. The child does not memorize the pain he is experiencing, he lives in the present. In the absence of cortical representation of the spine, it does not somatise. Pain is classified into six stages:

- Stage 0: no pain,
- Stage+: pain found only with percussion of the spinous process during clinical examination,
- Stage ++: mechanical pain during or after sport,
- Stage +++: static positional pain: in prolonged sitting or standing position,
- Stage ++++: pain at rest,
- Stage +++++: using analgesics, which is exceptional in children.

After puberty some back pain are related to neuromuscular hyper excitability. The pain is the result of contractures which occurs when the neuro-muscular junction is poorly vascularized. Pain is associated with asthenia, tremor of eyelids and microcirculatory disorders: ends of the feet and hands cold.

### 3.6 Psychological assessment: body image: Quasimodo, Pulcinella...

Deviations of the spine were in the past of tuberculosis origin (Pott's disease) or secondary to poliomyelitis with kyphosis and scoliosis. Currently a flat back is mostly seen with idiopathic scoliosis and humps are the consequence of the asymmetric rib rotation of the vertebral body when the trunk is bending forward in the Adams test.

The round back is inscribed in a cultural context that assigns moral values in relation to defined standards: "Stand up straight, or you will become hunchbacked." The right axis is an axis of will, the verticality of the body is an element of expression. The relationship between body and mind is established on the basis of identity: a twisted body means twisted ideas.

The "bump" is often the seat of ridicule, malice, and is a cause of mockery. The evil spirit or devil seats in the hump. Saturn, the patron of sorcerers, is often depicted with a kyphosis. If it is the sign of the curse it can also bring good luck "touch the bump brings good luck."

This evocation of the cultural round back deformity can explain the attitude of the family of kyphotic children. The child who misbehaves is described as different and his body bearing a physical disgrace is devalued. The child may have kyphotic feelings of aggression, frustration and withdrawal. Hunched posture of old age, those who have "rolled their hump" destabilizes the adolescent. The kyphotic child escapes this negative attitude by taking refuge in an imaginary world. The child avoids having feelings and as a consequence the child will grow more and more frustrated when facing reality: "It's always me who is accused, but now it does nothing to me, I am accustomed to."

Psychological tests indicate insecurity, shyness and introversion.

The child's perception of the body is difficult and emotional control is worse. Support and encouragement in their actions is needed (Lindeman & Behm, 1999).

### 3.7 Adult camptocormia

Camptocormia is a medical condition that is characterized by forward flexion of the spine. The camptocormia kyphosis has become more common due to the aging population. It is a weakness of the paraspinal posterior muscles. This weakness is often of pyramidal origin and clinical signs of Parkinson's are often noted as well. Because of this weakness, the patient stretches the last muscle fibres with a forward bending tension. The characteristic of camptocormia is that kyphosis disappears in supine position. Some antigravity braces can delay the progression of the kyphosis (Ryan & Fried, 1997; Kado & all, 2007).

In conclusion after this examination we can already distinguish between different types of kyphosis:

- Kyphotic or lordotic attitudes, related to ligamentous laxity or muscular hypotonia. These deviations can be reduced during the hyperextension test and improved with specific therapy.
- The paramorphism can be the result of a sport activity encouraging the kyphosis, such as: swimming (dolphin, butterfly).
- The constitutional kyphosis or lordosis, corresponding to a family morphotype is usually stable.
- The kyphosis adaptation: for instance the myopia determines a significant kyphotic attitude that can stiffen during growth. Similarly the long persistence of kyphosis in children with infantile encephalopathy promotes progressive structural deformation of the vertebral bodies.
- The structural kyphosis that usually justifies specific management.

## 4. Radiological assessment and aetiology

Radiography is unfortunately necessary to clarify the diagnosis and measure the morphometric parameters which will guide physiotherapy (Van Rosen & all, 1998). The classical radiological assessment includes a profile X-ray done on cassette filter 30cm by 90cm in teleradiography tube located 2 meters from the patient. The focus is on T6 to avoid excessive deformation of the vertebral body. Currently we use the EOS technique which has the advantage of less irradiation for the patient and getting better visibility of the end plates, because the dose is adjusted for each horizontal plane and the ray is tangent to the plate, except of course in case of excessive kyphosis. Whatever the technique, patient positioning as described in the morphotypology section, is crucial for kyphosis.

### 4.1 Scheuermann disease

The diagnosis of Scheuermann's disease is radiological.

The radiographic signs are classified into four stages:

- Stage +: irregular cartilage plates,
- Stage ++: intraspongious hernia,
- Stage +++: 7° to 10° of vertebra wedging at the apex of the kyphosis,
- Stage ++++: wedging greater than 10 ° on one vertebra or dystrophic lesions spread over 5 vertebrae. (Tribus, 1998, Lowe & Line, 2007))

#### 4.2 Congenital malformation

Congenital kyphotic malformations are less frequent but more severe than those causing scoliosis, the risk of progressive paraplegia is important. There are two different types:

- Type I: hypoplasia of the vertebral body, the posterior arch is preserved and leads to kyphosis with growth.
- Type II: aplasia of the vertebral body. It is a congenital defect of the anterior segment of the vertebral body called "bars" or "block" (Lonstein, 1999).

#### 4.3 Vertebral osteoporosis

Bone densitometry is used to quantify osteoporosis, but for the same bone mineral density (BMD), vertebral consequences may differ depending on the patients. The x-ray shows the characteristic deformations of spinal osteoporosis: decreased height, more or less symmetrical compaction and deformation like a pancake.

Vertebral indices are used to quantify the progression of osteoporosis.

#### 4.4 Ankylosing spondylitis

Symptoms of ankylosing spondylitis can begin before the age of 20. It results in a disharmonious kyphosis with a loss of lordosis and a forward projection of the trunk. In addition to the anti-inflammatory therapy, rehabilitation includes:

- Daily prone postures,
- Practicing lordotic activity such as swimming.

In extreme cases we can make posterior vertebral osteotomies to improve lumbar lordosis and balance the head on the gravity line.

#### 4.5 Other aetiologies

Nutritional kyphosis can result from nutritional deficiencies, especially during childhood, such as vitamin D deficiency (producing rickets), which softens bones and results in curving of the spine and limbs under the child's body weight (Hensinger, 1977).

Myelomeningocele like laminectomies can evolve in kyphosis. (Banta & Hamada, 1976).

### 5. Typical exercises for adolescent hyperkyphosis

#### 5.1 Awareness of the deformation with a mirror or camcorder

The child must become aware of the deformed image of his back and gain a better representation of his shape, his position and his dynamics in space. This static and dynamic



awareness is achieved through a video camera placed laterally to get a profile view. It is necessary to explain to the child the ideal position in the sagittal plane. The child also needs to be told the means of achieving this ideal position in order to learn and correct disharmonious balance first in a segmental way from feet to head and then globally in static, and after in dynamic during the movement of walking. The difficulty lies in correcting sequentially:

- Anteversion or retroversion of the pelvis
- Lumbar lordosis,
- Thoracic kyphosis,
- Forward projection of the neck,
- Shoulders antepulsion.

In some structural cases, the correction is difficult because of stiffness or poor muscle quality. Correcting a kyphotic posture takes time and compliance with physiotherapy is vital for the best possible outcome.

## 5.2 Mobilization of the thoracic spine in hyperextension especially in case of direct stiffness: Segmental exercises

Direct rigid kyphosis is very often the result of Scheuermann's disease which has as a consequence height loss of the intervertebral disc with segmental mobility limitation.

The Stretching and the relaxing of the spine in extension are done with:

- Passive postures in prone or quadruped position
- Stretching of the anterior intervertebral ligament in a supine position with apex of kyphosis on a block,
- Passive postures with at the end active extension,
- Facet joint mobilization in the three planes by combining active and hyperextension lateral bending and rotation with active hyperextension. The relaxation must be global and three-dimensional.

The segmental stiffness at the kyphosis apex favours limiting the amplitudes of the chest if breathing is deep and wide. Breathing exercises especially diaphragmatic and lateral-costal are done in maximal deep inspiration and expiration. (Figure 5)




Fig. 5. Segmental mobilisation



The Schroth method is useful for lumbar kyphosis. (Lehnert-Schroth & Weiss, 1992)

### 5.3 Stretching of anterior thorax muscles and hamstrings in case of indirect stiffness

Passive stretching can increase range and reduce tension. For instance you can use the shoulder blade squeeze: with your back straight squeeze your shoulder blades together as hard and as far as possible pain-free. Hold for 7 seconds relax 7 seconds and repeat 10 times. To stretch the tight and overly developed chest or pectoral muscles it is necessary to lie on a mat with knees bent and hands placed at the base of the skull, shoulder blades and ribs connected to the mat, elbows down towards the floor are pressed feeling a pull across the front of the chest and under the armpits.

For hamstrings, place your foot on a step or chair, keep your knee and back straight and lean forward at your hips until you feel a stretch in the back of your thigh. Lying on your back with a rope or band wrapped around one foot and the other leg long and anchored to the mat; strap is tensioned with exhalation as the leg is brought up until feeling a pull in the back of the upper thigh.

### 5.4 Global stretching with RPG or Mézières exercises

Françoise Mézières (1909-1991), a French physiotherapist was teaching and practising classical segmented physiotherapy. She gradually discovered the value of a global stretch of muscle chains in a position with lower limbs and trunk flexed at 90 °. For the spine deformation is most often used in closed kinetic chain, feet on the ground and hands resting in front of a support in horizontal extension of the trunk (Mezieres, 1978). (Figure 6)



Fig. 6. Meziere's postures

Pilates' exercises are also useful for length/tension imbalance in the body with weak? Abdominal muscles, tight chest and hamstrings muscles and a weak overstretched upper back.

### 5.5 Integration of postural correction

We described the main stages of the postural correction with a mirror. Once the stiffness has disappeared and the muscles have been strengthened, this correction must be perfect and maintained in all the activities of daily life, what we call the 24 hours of the spine.

### 5.6 Extensor spinal and abdominal muscles strengthening in corrected position

Strengthening exercises are given for abdominal muscles and back extensors to stabilise the spine and maximise its function. These reinforcements are made with small weights of a maximum of 5 kg with a spine correctly positioned. The duration is 7 seconds, which is equal to the resting time. The direction of motion is extension. The positions need to be gradual, the first being the prone position used for testing reducibility in hyperextension. The progression is: sitting, standing, moving, for instance by walking. The pace should be relatively slow with breath control for aerobic metabolism and a preferential development of slow fibres muscle type I. (Lam & all, 1999)

### 5.7 Integration of the corrected posture during imbalance exercises (neuromuscular control and equilibrium)

At first we can use the supine position on a Swiss ball. The physiotherapist maintains the legs of the patient seeking to balance only with the upper limbs in extension and external rotation, the trunk being released. In a second step, the child is lying in prone position and he must straighten at maximum the spine, making a paravertebral muscles active strengthening in instable posture. (Figure 7)




Fig. 7. Exercises on a Swiss ball

### 5.8 Practice of `extension` sport activities

No sports activities are contraindicated in kyphosis, because almost all activities involve spinal extension. Sport activities performed in a sitting position like cycling and rowing are indicated in cases of harmonious kypho-lordosis ie hyperkyphosis balanced by hyperlordosis. The position of the spine needs to be controlled. With swimming some styles such as the dolphin and butterfly styles which increase curves in the sagittal plane must be avoided. Sport activities complete physical therapy and in case of conservative orthopaedic treatment, best results are obtained in patients regularly practicing a sport.

Hypotonia is physiological in teenagers and sport is one of the best ways to fight against this physiological hypotonia.

### 5.9 Back education

The back school is mostly used in cases of adult back pain and does not significantly modify any morphological parameters of the spine. An educational program for adolescents is very

useful for trainees (Troussier & all, 1999). Scheuermann first described apprentice watchmakers kyphosis... (Scheuermann, 1921)

## 6. Typical exercises for adult hyperkyphosis

In adult cases, kyphosis keeps on evolving. When the kyphosis is the main reason to consult a doctor and when a specific aetiology is eliminated; the following can be distinguished:

- Kyphosis in young adults, is mostly painful with a slightly stiffness of the paraspinal structures, but the muscles remain strong. The aesthetic aspect is important, the patient no longer accepts a hunchback image and often requires surgical morphologic correction.
- Old people kyphosis is characterized by bone fragility, often with osteoporosis. The charge on the osteoporosis pain which becomes increasingly resistant to conventional treatments, the musculature is less powerful and the spine is stiffer.
- Very old people kyphosis is characterized by progressive atrophy of the muscles that can lead to the extreme situation of camptocormia.

When the kyphosis occurs in a specific etiologic context such as a fracture, orthopaedic conservative treatments are generally more accepted.

### 6.1 Static prone corrective posture, relaxation

This is the main treatment of ankylosing spondylitis. It is very important that the stiffening of the spine occurs in a position closest to the line of gravity. The ideal position occurs when the direction of the gaze is stabilized in a slightly oblique line down from the horizontal. The patient should be able to see where he is going.

### 6.2 Analgesic and deep tissue massage

Painkillers for the patient are the easiest and fastest way to solve the pain problem. It is justified if the assessment reveals a precise aetiology associated with kyphosis. In other cases, it is a palliative solution for the short term that does not treat the actual cause of chronic mechanical pain. In addition to the side effects of painkillers, pain is often a protective mechanism for the spine, a kind of seatbelt. The excessive use of painkillers can be compared to driving without a seatbelt.

Massages are performed in the supine position and an anti-kyphosis posture achieved by adding pads under the pelvis and at the sterno-clavicular area.

Analgesic massages are also always preferable to palliative painkillers.

### 6.3 Global postural physiotherapy

Far from suffering from weaknesses, excessive strengths can be found in groups of paravertebral muscles called 'muscular chains' by Mézières. Being multi-joint, these muscles are banded together in a chain-like manner in which they overlap like tiles on a roof. There are four muscular chains in our bodies, the main one being situated at the back, running from head to feet. Although made of several muscles, muscular chains always behave like a single muscle. Sometimes they end up too tight and too short. The shortening of the anterior muscular chains causes kyphosis. Any departure from the normal, ideal shape will

inevitably cause pain and malfunction, restoring shape to its primitive condition has a powerful therapeutic value as it addresses the primary cause of our musculo-skeletal ills. The normalisation of morphology is the most efficient way, the only lasting way, to 'cure' back and related pains.

We have described for the teenager` the square` in closed kinetic chain with feet on the ground and fixed point on the Swedish ladder. For adolescents, the trunk is not applied on a support, in order to be accessible. This position is often painful for adults and we will use the position "at the extremity of the table" that allows a true relaxation of the paraspinal musculature. The table height is adjusted to maintain the right angle between the legs and the trunk. The upper limbs are extended in line with the trunk. (Figure 6)

#### **6.4 Muscular reharmonisation**

We have already considered the disharmony within the anterior and posterior muscle chains. There is also a disharmony between anterior and posterior chain, i.e between extensors and flexors of the trunk. In concentric isokinetic, the typical ratio is 0.7 with more strength for the extensors. This ratio can be changed in case of kyphosis with decreased extensor strength compared to the flexors.

#### **6.5 Breathing exercises for costovertebral mobility**

The exercises are executed in maximum magnitude using the upper limbs to facilitate the mobilization of the thorax. Movements will be slow if possible with an abdominal strap to avoid lordosis and focus on mobilizing the thoracic area (Priftis & all, 2003).

### **7. Physiotherapy if bracing is necessary**

#### **7.1 Exercise with a soft brace**

A soft back brace like spinecor can be used as an aid to bending and lifting properly when the kyphosis is flexible. They are worn during the day; they can never be worn at night. They have the disadvantage of increasing lordosis. In case of disharmonious kyphosis their use completes physiotherapy treatment

#### **7.2 Exercises in plaster cast: Flexibility, range of motion**

The plaster cast is made in a Cotrel's frame with a transversal band at the apex of the kyphosis (Cotrel & all, 1964). The superior limbs are in extension. The knees are bent if we want to correct the lordosis at the same time. In some cases of disharmonious kyphosis, the inferior limbs are in extension to maintain lumbar lordosis.

Immediately after the plaster cast the physiotherapist needs to achieve significant therapeutic patient education with:

- Advice for skin care under the plaster cast .Skin should be cleaned daily by a parent with a strip of gauze and rubbing alcohol.
- Advice to avoid digestive abdominal dilatation. The risk of gastric dilatation is not negligible. Meals need to be taken in small portions and, and soft drinks avoided
- Advice for sitting positions with increased trunk-thigh angle need to be provided

The exercises include:



- Breathing needs to be controlled. The body cast limits inspiration and it is necessary to focus on expiration. The swelling of a balloon or practice of the flute is recommended. Hyperventilation which decreases pulmonary oxygenation is avoided.
- Mobilization in plaster cast. It should be remembered that the movement is fundamental during the plaster cast time. It is this movement which will gradually creep and lengthen the anterior longitudinal ligament.
- Mobilizations of pelvic and scapular girdles are facilitated by the fixed point of the plaster on the trunk.
- A global strengthening of the paravertebral muscles in active auto-axial elongation is performed, but the weight of the plaster alone of about 7 kg is in itself a strengthening exercise.

Physiotherapy should be monitored daily and at least twice a week by a physiotherapist.

### **7.3 Exercises with Milwaukee brace**

The Milwaukee brace worn at night with posterior transversal bar cross centred on kyphosis is used routinely before the pubertal growth mainly in cases of congenital malformation. The brace guides the growth that occurs mainly at night. Physiotherapy is carried out in the evening keeping the brace on. The child stands with his hands on the anterior bar and performs two basic movements. The first is a self-active axial elongation to lift the chin from the cervical collar. The extension is held during 7 seconds and the release time is also 7 seconds. The second exercise is performed in sagittal plane; it is an anterior shift with distance from the transverse posterior pad. The corrective movement is also maintained 7 seconds; the same relaxation time is allowed (Blount & Moe, 1973; Sachs & all, 1987; Winter & all, 1987).

### **7.4 Exercises with adolescent Lyon Kyphosis brace**

The plexidur bivalve brace has a posterior shell usually T7-S3. The upper part is just under the apex of kyphosis. A screw box is a turning point enabling the adjustment in the standing and sitting position.

The anterior shell has a manubrial thrust reinforced by a metallic bar. (Figure 8)

Physiotherapy is a fundamental part of the Lyon orthopaedic treatment. There is no rigid brace without associated physiotherapy (Stagnara & all, 1966; Stagnara & de Mauroy, 1975).

In the initial phase, the exercises performed with the brace and identical to those described with the plaster cast.

When the shoulder and pelvic girdles have been relaxed and strengthened, physiotherapy can be carried out without brace. The aim is to maintain an identical position to that of the spine under brace in various static positions of daily life: sitting, standing, leaning forward...

Subsequently, the same position will be maintained in dynamic situations of imbalance, such as walking on a beam.

The third time is the integration of the corrected position in sport.

### **7.5 Exercises with adult polyethylene bivalve overlapped brace**

Two major factors determine the bracing of kyphosis in adults:



1. The difficulty of setting up the brace which often requires a third party.
2. The significant imbalance in the sagittal plane.

The first task of the physiotherapist will be to teach the patient to set up his brace alone. It will sometimes be necessary to relax the shoulders or to make some ergonomic changes to the brace. Then, the physiotherapist will insist on walking with the brace. The correction of kyphosis can change the eyes direction and the patient can be worse when he walks, he will teach him how to use adherent and flexible sports shoes closed by Velcro, as the traditional lacing will be very difficult. Proprioceptive stimulation is global and the technique of blindfolded can be used to increase inferences and enhance the patient's confidence.

The brace can also reduce vital capacity by 20%. For this reason a very important thoraco-abdominal window is made in the brace to change as little as possible the abdomino-diaphragmatic range of mobility. Respiratory physiotherapy aims to promote the expiratory time and control the breathing rate (de Mauroy, 1995).

## **8. Ergonomics: The sitting position depending on the lumbopelvic morphotype**

### **8.1 Radiological parameters**

To determine the lumbar-pelvic morphotype, we must measure and compare, in our radiological reference position, the inclination of the sacral slope to the horizontal and the pelvic incidence. The sacral slope is highly variable and there are often changes associated with kyphosis, the pelvic incidence does not depend on the posture and does not change with anteversion or retroversion of the pelvis.

In 80% of cases, the sacral slope is close to 37° and the pelvic incidence close to 53°. Standard sitting position resumes the Staeffel's 90° rule: Feet rest horizontally on the floor, vertical legs, horizontal thighs on a seating base itself horizontal and a vertical trunk.

In case of thoracolumbar kyphosis, there is often a horizontalisation of the sacral slope with stable pelvic incidence at 53°. In these cases, we may use an ergonomic kneeling chair.

In case of accentuated kypho-lordosis, there is often an increase of the inclination of the sacral slope. If the pelvic incidence is normal at 53°, we can use a triangular cushion slightly tilted backward.

In some cases, the pelvic incidence will be modified reflecting a constitutional defect in the lumbopelvic static. It is this change in lumbar-pelvic incidence which is responsible of overlying deviations. A conservative treatment with orthopaedic brace will be realized in these cases.

### **8.2 Using ergonomic seats**

A kneeling chair is an ergonomic chair with thighs dropped to an angle of 60° from vertical. The intended purpose of a kneeling chair is to reduce lower back strain by promoting proper spinal alignment. This spinal alignment can be useful for thoraco-lumbar kyphosis (Dury & Francher, 1985; Lander & all, 1987; Bettany-Saltikov & all, 2008).

In other cases, a classic ergonomic chair can be used, avoiding wheels in cases when the chair does not have to be moved often during the exercise. The seat height will be

determined by the size of the patient so that we find the Staeffel's 90° rule. The seat is usually horizontal and the back close to the vertical. The height of the work plan will be determined by the distance of the horizontal forearms to the ground.

The patient will differentiate the listening position and the writing position which are exactly opposite.

In the listening position, the coccyx is backward as possible, the back spine is pressed on the back of the chair, thighs are horizontal and the feet are in front of the seat. They may also rest on a support. Ideally forearms are on the armrest.

In the writing position, the feet are behind the chair, the coccyx is in front of the seat, thighs in forward tilt. The chest is pressed against the front edge of the work plan and forearms rest on the work plan. When there is a high cervico-thoracic kyphosis of more than 25° between T1 and T4, a lectern will be used with a desk tilted at 15° on the horizontal work plane.

Poor lighting of the work plan can promote kyphosis.

The computer screen should be vertical, the centre at eye level.

For technical professional reasons, it is not always possible to use these reference positions, and in these cases an ergonomic adaptation of the workplace will be conducted.

## 9. Results, consensus and best evidence

(Figure 8)

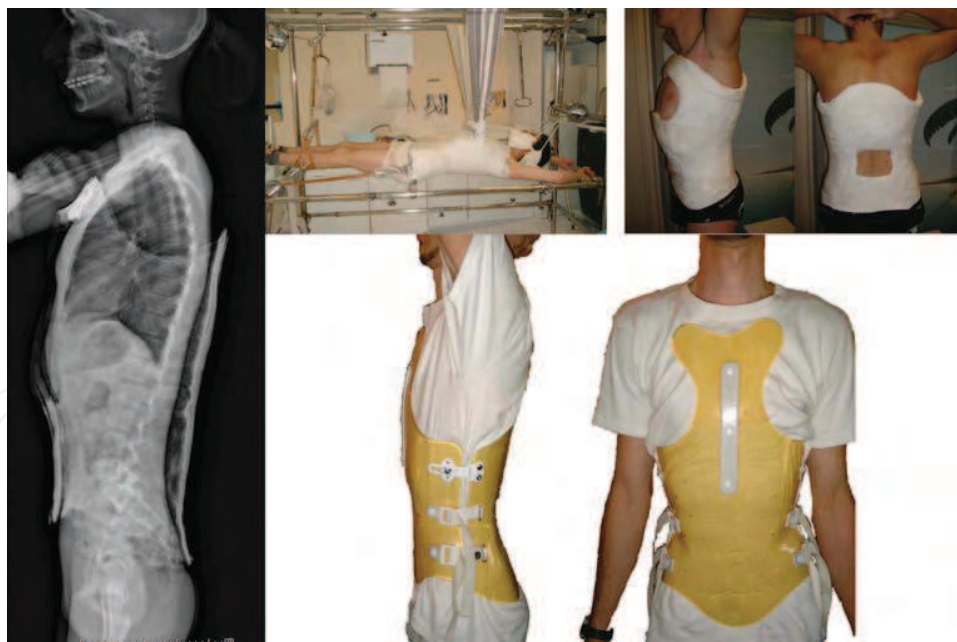

Fig. 8. Lyon kyphosis orthopaedic management

### 9.1 Results

272 patients (142 boys and 130 girls) with an average age of 13.6 months were treated from 1987 to 2005 and reviewed 2 years after removal of the brace, even if compliance with bracing was not satisfactory. Treatments were conducted according to the same historic

protocol in the same structure and followed by the same author. Braces were made by the same orthotic Company.

The Lyon orthopaedic treatment is usually carried out at the end of pubertal growth which is the more common indication. The plaster cast was systematically made in the day hospital before bracing. According to the importance of the angulation and the rigidity of the curvature, we made one or two plaster casts, each cast for one month time. The specific physiotherapy programme began when the plaster cast was made and carried on during the bracing phase. The brace was worn in sitting position at school or only the night for the most favourable cases. The brace was removed at the end of growth. A test of temporary removal of 6 months during summer allows the doctor to make sure the angle is stable (de Mauroy, 2010).

The diagnosis was Scheuermann in 119 cases and idiopathic in 153 cases. There were 10 cases with thoracolumbar patterns.

Patients were evaluated both by clinical or radiological examination. The first clinical and radiological assessment was made before the plaster cast. With a plaster cast, the reducibility of the curve needs to be measured radiologically. The successive controls take place at the time of the delivery of the brace then every 6 months until the removal, then 2 years and 5 years after the removal of the brace. All the clinical and radiological data are written according to a precise form on the computer programme. Since 1998 an automatic update of a specific spreadsheet is performed by the secretary during the medical control. All the data was analyzed by SPSS 18 IBM software.

After a description of the main parameters: means, SD, normal distribution. We shall use the parametric paired tests to compare the data, usually the Pearson correlation coefficient. The main criterion variable is the Stagnara angular correction between the initial radiography and that realized 2 years after the end of the treatment.

9.1.1 Angular evolution during treatment

Results are presented in table 1. X-ray at 1 year and removal are done without brace.

By comparing Cobb angles at the beginning of treatment and two years after the brace removal:

- 0 patient had an angular worsening of more than 5° (bad results)
- 16 patients had a stabilization between more or less 5° (stabilization)
- 256 Patients had an improvement of more than 5° (good results)

	Initial	In Plaster	in brace	1 year	Removal	Removal + 2 years
Kyphosis	59,43 +- 8,00	32,09 +- 8,21	37,12 +- 11,01	39,58 +- 8,34	39,78 +- 7,81	40,84 (31%) +- 8,15
Lordosis	48,90 +- 11,83	38,21 +- 9,17	41,76 +- 8,91	44,71 +- 9,09	43,74 +- 9,63	44,20 (10%) +- 9,23
Sacral slope	39,13 +- 7,88	34,89 +- 7,34	36,36 +- 6,89	37,26 +- 7,14	36,89 +- 6,87	37,27 (5%) +- 7,37

Table 1. Angular evolution of Kyphosis, lordosis and sacral slope

9.1.2 Correlation between the measure of the clinical plumline measures and the radiological angulation

The correlation is very significant between the clinical measurement and radiological evaluation. (Table 2)

Arrow Kyp / Cobb Kyph init	0,322		significant at the 0,01 level (2-tailed)
----------------------------	-------	--	--

Table 2. Correlation between the measure of the plumline measures and the radiological angulation

9.1.3 Correlations between Scheuermann, sex, pain and thoraco-lumbar localization

Our statistics analysis encompasses 142 males and 130 females. Males have more Scheuermann’s disease. 116 patients present a Scheuermann’s disease with more pain (126/140 cases) and thoraco-lumbar localization (8/10 cases). (Table 3)

Sex / Etiology	0,194	significant at the 0,01 level (2-tailed)
Etiology / TL	-0,177	significant at the 0,05 level (2-tailed 0,034)
Etiology / Pain	0,142	significant at the 0,05 level (2-tailed)

Table 3. Correlations between Scheuermann, sex, pain and thoraco-lumbar localization

9.1.4 Study of the correlations influencing the final angular correction

We shall present the significant results according to the value of the Pearson’s correlation coefficient. The immediate reduction in plaster cast is an excellent predictive criterion of the final correction (table 4).

Cobb Kyp plaster / Cobb Rem + 2	0,536	significant at the 0,01 level (2-tailed)
Plaster cast correction / Final Cobb	0,497	significant at the 0,01 level (2-tailed)
Cobb Kyph init/Cobb correction	0,455	significant at the 0,01 level (2-tailed)

Table 4. Most significant correlations with the final result.

9.1.5 Many parameters are not significant:

The final result does not depend on: the initial height and weight, the sex, the pain, the aetiology and the tight hamstring (table 5).

Height/Cobb K Correction	-0,115	non significant : sig, (2-tailed 0,057)
Weight / Cobb K Correction	-0,039	non significant : sig, (2-tailed 0,518)
Sex/Cobb K Correction	0,043	non significant : sig, (2-tailed 0,480)
Pain / Cobb K Correction	0,026	non significant : sig, (2-tailed 0,676)
Aetiology / Cobb K Correction	-0,039	non significant : sig, (2-tailed 0,521)
Tight Hamstrings/ Cobb K Correction	0,034	non significant : sig, (2-tailed 0,585)
Lord init / Cobb K Correction	0,007	non significant : sig, (2-tailed 0,914)

Table 5. Non significant parameters

9.1.6 Correlation between the reduction in plaster cast and bivalve plexidur brace

The correction in plaster cast is an excellent predictive criterion of the ‘in brace’ correction (table 6).

Cobb Kyp plaster / in brace	0,476	significant at the 0,01 level (2-tailed)
-----------------------------	-------	--

Table 6. Correlation between the reduction in plaster cast and bivalve plexidur brace

9.1.7 Stability 5 years after the removal of the brace

In 90 cases revised 5 years after the brace removal, we confirm the excellent stability (table 7).

Kyp R / Kyp R+ 5 (N=90)	0,545	significant at the 0,01 level (2-tailed)
Kyp R+2 / Kyp R+5 (N=90)	0,798	significant at the 0,01 level (2-tailed)

Table 7. Stability 5 years after the removal of the brace

It is difficult to express the obtained correction, because contrary to scoliosis, the angulation of reference is not 0°, but 37°[7] .The result of 40° on average corresponds practically to a total correction. Some studies use a percentage of angular correction. It is to be compared with the results obtained by Platero (17,55 % with exercises only | 25,21 % with brace only | 30,88 % plaster cast + brace) (Platero & all, 1997). We obtain an identical correction percentage of 31 % for the protocol associating plaster cast and brace. The corrections of sacral slope and lordosis correspond to a balance of the spine in the sagittal plane. All the cases of this study concern patient treated in pre-pubertal phase. As for the scoliosis, we prefer the Milwaukee modified brace before puberty.

The Kyphosis plumline measure is the half-sum of the distance measured in mm with a plumb line in C7 and L2. The good correlation with the radiological angulation makes of this measure a reliable element to monitor.

The Scheuermann’s disease concerns boys more and the thoraco-lumbar localization. The results of the treatment are similar. In every case, the pain is improved by the conservative treatment, usually during the plaster cast.

As for the scoliosis, the angular correction obtained initially in plaster cast is predictive of the final result. That is why we do not hesitate to make the second plaster cast if we think we can obtain an additional correction. The elements, which were not significant initially (aetiology, pain, tight hamstring...), prove the mechanical character and the reliability of the treatment.

The correction in plaster cast must be reproduced in plexidur bivalve brace it constitutes a reference element.

The stability between 2 and 5 years is excellent. It is connected to the improvement of the vertebral wedging reported by numerous authors (Bradford & all, 1974; Bradford, 1977; Gutowski & Renshaw, 1988; Weiss & all, 2009).

9.2 Consensus

The experts from SOSORT are convinced of the usefulness and appropriateness of conservative treatment for the management of Kyphosis and they use this treatment on a daily basis in their clinical practice (de Mauroy, 2010).



The main rehabilitation techniques used are: self postural control and self-elongation. Back school does not seem useful. Physiotherapy exercises should be repeated at home daily for 20 minutes; they are indeed useful before bracing.

The main indications are Scheuermann and pain especially if the kyphosis is rigid.

The biomechanical base for conservative treatment is to decrease mechanical stress on the anterior wall of the vertebral body.

The main indications for early treatment are: rigidity, size of the curve and the Cobb angle.

The best time is at the onset of puberty. The brace should be worn for about 2 years and removed at the end of growth without skeletal maturity at Risser 5.

For a Thoracic Kyphosis: the brace must be worn all night and for part of the day. The most appropriate brace is a 4 point system or a 5 point system in case of muscular imbalance.

For a Thoraco-lumbar kyphosis: the brace must be worn during the day in the sitting position and the ideal brace is a 4 point system.

For a juvenile kyphosis: the brace must be worn part time, and the ideal brace is the Milwaukee.

## 10. Conclusion

Physiotherapy and more generally orthopaedic management of kyphosis is not as well known as scoliosis management because the breathing consequences of kyphosis are less disabling. With the aging population kyphosis often becomes a major problem due to the pain and imbalance in standing and walking. The loss of autonomy becomes crucial and often it is too late to treat effectively. The management needs to be effective during adolescence; there is no "light" treatment of kyphosis. Regarding adult cases, treatment is more of a lifestyle issue and an adaptation of the workplace, which makes it very difficult to prove the efficacy of physiotherapy. The results are better with conservative orthopaedic treatment and the retrospective study is encouraging. Long term prospective studies are expected to confirm the interest of these treatments, as for regular kyphosis, neurological surgical risk is greater than in scoliosis due to the risk of stretching of the Adamkiewicz' artery.


## 11. References

- Albert, TJ.; Vacarro, A.(1998). Postlaminectomy kyphosis. *Spine* 1998 ; 23 : 2738-2745, ISSN 0362-2436
- Ali, RM.; Green, DW.; Patel, TC.(1999). Scheuermann's kyphosis. *Curr Opin Pediatr* 1999 ; 11 : 70-75, ISSN 1040-8703
- Aufdermaur, M.; Spycher, M.(1986). Pathogenesis of osteochondrosis juvenilis Scheuermann. *J Orthop Res* 1986 ; 4 : ISSN: 0736-0266
- Banta, JV.; Hamada, JS.(1976). Natural history of the kyphotic deformity in meningomyelocele. *J Bone Joint Surg* 1976 ; 58-A : 279, ISSN 0021-9355
- Bettany-Saltikov, J.; Warren, J.; Jobson, M.(2008). Ergonomically designed kneeling chairs are they worth it? : Comparison of sagittal lumbar curvature in two different seating postures. *Studies in health technology and informatics* 140: 103-6. ISSN: 0926-9630

- Blount, WP.; Moe, JH.(1973) The Milwaukee brace. *The William and Wilkins Co* Baltimore, ISBN 0683008691
- Bradford, DS.; Moe, JH.; Montavaldo, FJ.; WINTER, RD.(1974). Scheuermann's Kyphosis and Roundback Deformity. Results of Milwaukee Brace treatment. *J Bone Joint Surg*, 1974;56:740-758, ISSN 0021-9355
- Bradford, SD.(1977). Juvenile Kyphosis. *Clin Orthop* 1977 ; 128 : 44-55, ISSN: 0009-921X
- Cotrel, Y.; Morel, G.; Rey, JC.(1964). Le traitement orthopédique des cyphoses structurales en cours de croissance. *Rev Rhum* 1964 ; 31 : 445-451, ISSN:0301-8474
- Drury, CG; Francher, M (1985). Evaluation of a forward-sloping chair. *Applied ergonomics* 16 (1):41-7, ISSN: 0003-6870
- Fender, P.; de Mauroy, JC.; Sengler, J.; Bourderont, D.(1995). Jusqu'à quel âge peut-on envisager le traitement orthopédique d'une hypercyphose dorsale de l'adolescent. *Les cyphoses : de l'enfant à l'adulte*. Masson 1995 ; Col Pathol Locom 30 : 141-147, ISBN 2-225-84775-4
- Fon, GT.; Pitt, MJ.; Thies, ACJ.(1980). Thoracic kyphosis: Range in normal subjects. *AJR Am J Roentgenol* 1980, 134:979-83, ISSN: 0361-803X
- Gutowski, WT.; Renshaw, TS.(1988). Orthotic results in adolescent kyphosis. *Spine* (Phila Pa 1976). 1988; 13(5):485-9, ISSN: 0362-2436
- Hensinger, R.(1977). Kyphosis secondary skeletal dysplasia and metabolic disease. *Clin Orthop* 1977, 128, 113-127, ISSN: 0009-921X
- Ippolito, E.; Bellocci, M.; Montanaro, A.; Ascani, E.; Ponseti, IV.(1985). Juvenile Kyphosis: An Ultrastructural Study. *J Pediatr Orthop* 1985;5:315. ISSN: 1060-152X
- Kado, DM.; Prenovost, K.; Crandall, C.(2007). Narrative review: hyperkyphosis in older persons. *Ann. Intern. Med.* 147 (5): 330-8, ISSN: 0003-4819
- Korovessis, PG.; Stamatakis, MV.; Baikousis, AG.(1998). Reciprocal angulation of vertebral bodies in the sagittal plane in an asymptomatic Greek population. *Spine* 1998 ; 23 : 700-705, ISSN 0362-2436
- Lam, KS.; Mehdiian, H.(1999). The importance of an intact abdominal musculature mechanism in maintaining spinal sagittal balance. Case illustration in prune-belly syndrome. *Spine* 1999 ; 27 : 719-722, ISSN 0362-2436
- Lander, C.; Korbon, GA.; Degood, DE.; Rowlingson, JC.(1987). The Balans chair and its semi-kneeling position: an ergonomic comparison with the conventional sitting position. *Spine* 12 (3): 269-72, ISSN: 0362-2436
- Lehnert-Schroth, C: Dreidimensionale Skoliosebehandlung - *Atmungs-Orthopädie System Schroth*. 7. Auflage. Urban & Fischer in Elsevier, München 2007, ISBN 978-3-437-44025-0.
- Lindeman, M.; Behm, K.(1999) Cognitive strategies and self-esteem as predictors of brace-wear noncompliance in patients with idiopathic scoliosis and kyphosis. *J Pediatr Orthop* 1999 ; 19 : 493-499, ISSN: 1060-152X
- Lonstein, JE.(1999). Congenital spine deformities : scoliosis, kyphosis, and lordosis. *Orthop Clin North Am* 1999 ; 30 : 387-405, ISSN: 0030-5898
- Lonstein, JE.(1987). Post laminectomy kyphosis *Clin Orthop* 1987 ; 128, 93-100, ISSN: 0009-921X
- Lowe, TG.(1999). Scheuermann's disease. *Orthop Clin North Am* 1999 ; 30 : 475-487, ISSN: 0030-5898

- Lowe, TG.; Line, BG.(2007) Evidence based medicine: analysis of Scheuermann kyphosis. *Spine*. 2007; 32(19 Suppl):S115-119, ISSN: 0362-2436
- de Mauroy, JC.; Stagnara, P.(1979). Cyphose idiopathique : entité pathologique. Masson 1979 ; *Actual Rééd Fonct Réadapt* 4 : 216-219, ISSN 0223-9183
- de Mauroy, JC.(1983). La cyphose de l'adolescent. *J Readapt Med* 1983 ; 3 : 144-148, ISSN 0242-648X
- de Mauroy, JC.(1995) Traitement orthopédique des cyphoses. *Les cyphoses de l'enfant à l'adulte*. Masson edit. 1995 ; Collection de pathologie locomotrice 30 : 133-141, ISBN 2-225-84775-4
- de Mauroy, JC. ; Weiss, HR. ; Aulisa, A. ; Aulisa, L. ; Brox, J. ; Durmala, J. ; Fusco, C. ; Grivas, T. ; Hermus, J. ; Kotwicki, T. & all. (2010) 7th SOSORT consensus paper: conservative treatment of idiopathic & Scheuermann's kyphosis. *Scoliosis*. 2010 May 30;5:9. DOI 10.1186/1748-7161-5-9
- de Mauroy, JC.; Vallèse, P.; Fender, P.; Lecante, C. (2010) Historical Lyonaise brace treatment for adolescent hyperkyphosis. Results of 272 cases reviewed 2 years minimum after removal of the brace. *Scoliosis*. 2010; 5(Suppl 1): O69. DOI 10.1186/1748-7161-5-S1-O69
- Mc Master, MJ.; Singh, H.(1999). Natural history of congenital kyphosis and kyphoscoliosis. A study of one hundred and twelve patients. *J Bone Joint Surg Am* 1999 ; 81 : 1367-1383, ISSN 0021-9355
- Mezières, F.(1978) Retour à l'harmonie morphologique par une rééducation spécialisée. Sur des notions nouvelles reconstruisons. la cinésiologie. *Kinésit Scient* 1978 ; 157 : 45-54, ISSN 0023-1576
- Mollon, G.; Viollay, M.(1978). Kinésithérapie et appareillage des cyphoses traitées par chirurgie. *Kinesit Scient* 1978 ; 157 : 13-21, ISSN 0023-1576
- Murray, PM.; Weinstein, SL.; Spratt, KF.(1993). The natural history and long term follow-up of Scheuermann's kyphosis. *J Bone Joint Surg* 1993 ;75-A : 236-248, ISSN 0021-9355
- Platero, D.; Luna, JD.; Pedraza, V.(1997). Juvenile kyphosis : effects of different variables on conservative treatment outcome. *Acta Orthop Belg* 1997 ; 63(3) : 1194-201, ISSN: 0001-6462
- Priftis, KN.; Hager, J.; Vlachou, M.; Anthracopoulos, MB.(2003). Effects of bracing on lung function in idiopathic juvenile kyphosis. *Pediatr Pulmonol*. 2003; 35(2):83-6, ISSN: 8755-6863
- Russe, OA.; Gerhardt, J.(1976). International SFTR method of measurement end recording joint motion. pp81, Hans Huber, Berne 1976
- Ryan, SD.; Fried, LP.(1997). The impact of kyphosis on daily functioning. *J Am Geriatr Soc* 1997 ; 45(12) : 1479-1486, ISSN: 0002-8614
- Sachs, B.; Bradford, SD.; Winter, RB.; Lonstein, J.; Moe,J.(1987). Scheuermann Kyphosis, follow-up of Milwaukee brace treatment. *J Bone Joint Surg* 1987 ; 69 : 50-57, ISSN 0301-620X
- Scheuermann, H.(1921). Kyphosis Dorsalis Juvenilis. *Zeitschr Orthop Chir* 1921 ; 41 : 305-317, ISSN 0044-3220
- Shen, WJ.; Shen, YS.(1999). Nonsurgical treatment of three-column thoracolumbar junction burst fractures without neurologic deficit. *Spine* 1999 ; 24 : 412-415, ISSN: 0362-2436
- Sorensen, KH.(1964). Scheuermann juvenile kyphosis. Clinical appearance, radiography, aetiology and prognosis. *Munksgaard*, Copenhagen 1964

- Stagnara, P.; de Mauroy, J.C.; Dran, G.; Gonon, G.P.; Costanzo, G.; Dimnet, J.; Pasquet, A.(1982). Reciprocal angulation of vertebral bodies in a sagittal plane : approach to references for the evaluation of Kyphosis and Lordosis. *Spine* 1982 ; 7 : 335-342, ISSN: 0362-2436
- Stagnara, P.; de Mauroy, J.C.; Villard, B.(1975). Traitement des cyphoses régulières. *Ann Med Phys* 1975 ; 18 : 481-496, ISSN 0168-6054
- Stagnara, P.; du Peloux, J.; Fauchet, R.(1966). Traitement orthopédique ambulatoire de la maladie de Scheurmann en période d'évolution. *Rev Chir Orthop* 1966 ; 52 (7) : 585-600, ISSN 1877-051
- Tribus, C.B.(1998). Scheuermann's kyphosis in adolescents and adults : diagnosis and management. *J Am Acad Orthop Surg* 1998 ; 6 : 36-43, ISSN: 1067-151X
- Troussier, B.; Marchou-Lopez, S.; Pironneau, S.; Alais, E.; Grison, J.; Prel, G.; Pequegnot, C.; Degaudemaris, R.R.; Phelip, X.(1999). Back pain and spinal alignment abnormalities in schoolchildren. *Rev Rhum Engl Ed* 1999 ; 66 : 370-380, ISSN 1169-8446
- Van Rosen, B.J.; Toussaint, H.M.; Kingma, I.; Bot, S.D.; Caspers, M.; Harlaar, J.; Wuisman, P.I.(1998). Accuracy of the sagittal vertebral axis in a standing lateral radiograph as a measurement of balance in spinal deformities. *Eur Spine* 1998 ; 7 : 408-412, ISSN 0940-6719
- Vedantam, R.; Lenke, L.G.; Keeney, J.A.; Bridwell, K.H.(1998). Comparison of standing sagittal spinal alignment in asymptomatic adolescents and adults. *Spine* 1998 ; 23 : 211-215, ISSN: 0362-2436
- Voutsinas, S.A.; Mac Ewen, G.D.(1986). Sagittal Profiles of the Spine. *Clin Orthop Res* 1986 ; 210 : 235-242, ISSN 0009-921X
- Weiss, H.R.; Turnbull, D.; Bohr, S.(2009). Brace treatment for patients with Scheuermann's disease - a review of the literature and first experiences with a new brace design. *Scoliosis*. 2009, Sep 29;4:22. PMCID: PMC2761858, DOI 10.1186/1748-7161-4-22
- Winter, R.B.; Hall, J.E.(1978). Kyphosis in Childhood and adolescence. *Spine* 1978 ; 3 : 285-308, ISSN: 0362-2436
- Winter, R.B.; Lonstein, J.; Moe, J.; Willson, S.(1987). Scheuermann kyphosis. Follow-up of Milwaukee brace treatment. *J Bone Joint Surg* 1987 ;69-A : 50-57, ISSN 0021-9355
- Winter, R.B.(1977). Congenital kyphosis. *Clin Orthop* 1977 ; 128 : 26-32, ISSN 0009-921X
- Zaina, F.; Atanasio, S.; Ferraro, C.; Fusco, C.; Negrini, A.; Romano, M.; Negrini, S.(2009). Review of rehabilitation and orthopedic conservative approach to sagittal plane diseases during growth: hyperkyphosis, junctional kyphosis, and Scheuermann disease. *Eur J Phys Rehabil Med*. 2009 Dec;45(4):595-603, ISSN: 1017-6721



## **Physical Therapy Perspectives in the 21st Century - Challenges and Possibilities**

Edited by Dr. Josette Bettany-Saltikov

ISBN 978-953-51-0459-9

Hard cover, 386 pages

**Publisher** InTech

**Published online** 05, April, 2012

**Published in print edition** April, 2012

This book contains new information on physical therapy research and clinical approaches that are being undertaken into numerous medical conditions; biomechanical and musculoskeletal conditions as well as the effects of psychological factors, body awareness and relaxation techniques; specific and specialist exercises for the treatment of scoliosis and spinal deformities in infants and adolescents; new thermal agents are being introduced and different types of physical therapy interventions are being introduced for the elderly both in the home and clinical setting. Additionally research into physical therapy interventions for patients with respiratory, cardiovascular disorders and stroke is being undertaken and new concepts of wheelchair design are being implemented.

### **How to reference**

In order to correctly reference this scholarly work, feel free to copy and paste the following:

Jean Claude de Mauroy (2012). Kyphosis Physiotherapy from Childhood to Old Age, Physical Therapy Perspectives in the 21st Century - Challenges and Possibilities, Dr. Josette Bettany-Saltikov (Ed.), ISBN: 978-953-51-0459-9, InTech, Available from: <http://www.intechopen.com/books/physical-therapy-perspectives-in-the-21st-century-challenges-and-possibilities/kyphosis-physiotherapy-from-childhood-to-old-age>

**INTECH**  
open science | open minds

### **InTech Europe**

University Campus STeP Ri  
Slavka Krautzeka 83/A  
51000 Rijeka, Croatia  
Phone: +385 (51) 770 447  
Fax: +385 (51) 686 166  
[www.intechopen.com](http://www.intechopen.com)

### **InTech China**

Unit 405, Office Block, Hotel Equatorial Shanghai  
No.65, Yan An Road (West), Shanghai, 200040, China  
中国上海市延安西路65号上海国际贵都大饭店办公楼405单元  
Phone: +86-21-62489820  
Fax: +86-21-62489821



© 2012 The Author(s). Licensee IntechOpen. This is an open access article distributed under the terms of the [Creative Commons Attribution 3.0 License](https://creativecommons.org/licenses/by/3.0/), which permits unrestricted use, distribution, and reproduction in any medium, provided the original work is properly cited.

IntechOpen

IntechOpen