

We are IntechOpen, the world's leading publisher of Open Access books Built by scientists, for scientists

6,900

Open access books available

186,000

International authors and editors

200M

Downloads

Our authors are among the

154

Countries delivered to

TOP 1%

most cited scientists

12.2%

Contributors from top 500 universities



WEB OF SCIENCE™

Selection of our books indexed in the Book Citation Index
in Web of Science™ Core Collection (BKCI)

Interested in publishing with us?
Contact book.department@intechopen.com

Numbers displayed above are based on latest data collected.
For more information visit www.intechopen.com



Congenital Obstructive Nephropathy: Clinical Perspectives and Animal Models

Susan E. Ingraham and Kirk M. McHugh

*Department of Pediatrics, Division of Pediatric Nephrology, The Ohio State University
and The Research Institute at Nationwide Children's Hospital,
Columbus, Ohio,
USA*

1. Introduction

Congenital obstructive nephropathy is the leading cause of pediatric chronic kidney disease (CKD). Consequently, it engenders a tremendous societal burden in terms of morbidity and mortality and in health care expenses over the lifespan of affected patients. The challenges clinicians face in the diagnosis, prognosis, and treatment of congenital obstructive nephropathy illustrate the utility of developing effective experimental models for the study of this complex disease process. In this review, we characterize congenital obstructive nephropathy with its myriad causes and manifestations, outline current standards of diagnosis and care, and discuss experimental animal models with relevance in unraveling clinical conundrums and molecular mechanisms of this important renal disease.

Congenital obstructive nephropathy is a complex process of pathologic changes in kidney development and function that arise when antegrade urine flow is impaired beginning *in utero*. The term *congenital obstructive uropathy* is frequently used to describe this condition. However, every urologic obstruction – whether anatomic, mechanical, or functional – should be approached with the knowledge that obstruction can affect the kidneys. For this reason, we prefer the term *congenital obstructive nephropathy*.

Intrinsic anatomic obstructions may occur in isolation or accompanied by other pathology such as renal hypodysplasia. Functional obstructions also occur, which may be transient and self-resolving, or chronic with potentially profound consequences on renal function. Although the etiologies of congenital obstructive nephropathy are myriad, any restriction of urine flow has the potential to produce hydronephrosis, altered renal development, and progression of CKD. This direct link between obstructed urine flow and abnormal kidneys represents a central paradigm of urogenital pathogenesis that has far-reaching implications (Woolf & Thiruchelvam, 2001).

2. Epidemiology of congenital obstructive nephropathy

Congenital obstructive nephropathy is the most common cause of CKD in children and is among the top three etiologies of pediatric end-stage renal disease (ESRD; NAPRTCS, 2009).

Congenital obstructive nephropathy is often grouped with renal agenesis, hypoplasia/dysplasia and other abnormalities as a heterogeneous entity termed *congenital anomalies of the kidney and urinary tract* (CAKUT). CAKUT is relatively common, affecting up to 2% of pregnancies (Ismaili et al., 2003; Wiesel et al., 2005). CAKUT accounts for 51% of childhood CKD in North America (NAPRTCS, 2009), and similar frequencies in registry data from around the world (Neild, 2009a). Among the diagnoses within the broad category of CAKUT, obstructive disease carries the greatest risk for developing ESRD (Sanna-Cherchi et al., 2009). The association of renal hypodysplasia and impaired glomerular filtration rate with urological obstruction is well-established. More subtle renal changes such as hypertension, impaired sodium/water handling, and acidosis are also common (Farnham et al., 2005; Gillenwater et al., 1975). Thus the full clinical impact of congenital obstructive nephropathy is immense.

3. Classification of congenital obstructive nephropathy

The timing, extent, etiology, and location of impaired urine flow are important considerations in describing and classifying the causes of obstructive nephropathy. One of the most important and useful distinctions is the anatomic level at which the obstruction occurs – namely, the upper urinary tract (kidney or ureter) versus the lower urinary tract (bladder, bladder outlet or urethra). Upper urinary tract lesions have little potential to affect the contralateral kidney, whereas lower tract anomalies generally put both kidneys at risk.

3.1 Upper urinary tract obstructions

Congenital obstructions of the upper urinary tract include ureteropelvic junction (UPJ) and ureterovesical junction (UVJ) obstructions, as well as obstructing ureteroceles and other anomalies of ureteric structure or position.

3.1.1 Ureteropelvic junction obstruction

UPJ obstruction is the most common congenital urological obstruction (Figure 1). It occurs in one of every 1000-2000 births, with a 3:1 male predominance. Obstruction is bilateral in 20-25% of cases (Woodward & Frank, 2002). Congenital UPJ obstructions usually arise from an adynamic proximal ureteral segment. This dysfunctional segment of the ureter often exhibits abnormal distribution of collagen and/or smooth muscle, and may show altered innervation or vasculature (Hosgor et al., 2005; Payabvash et al., 2007; Yoon et al., 1998). Less common intrinsic causes of UPJ obstruction include a convoluted ureteral course and deformations of the mucosa, including valve-like folds or polyps. UPJ obstruction may also arise from extrinsic compression of the proximal ureter by another structure such as aberrant vasculature or fibrous bands.

3.1.2 Ureterovesical junction obstruction

UVJ obstruction, or primary obstructive megaureter, arises when urine flow is restricted at or near the insertion of the ureter into the bladder (Figure 2). This is the second most common site of congenital obstruction, after the UPJ (Brown et al., 1987; Reinberg et al.,

1991). UVJ obstruction is four times more common in males and arises more often on the left, with bilateral obstructions occurring in up to 25% of cases (Gimpel et al., 2010; Woodward & Frank, 2002). Like UPJ obstruction, UVJ obstruction is typically associated with an adynamic ureteric segment that fails to propagate effective urine flow.

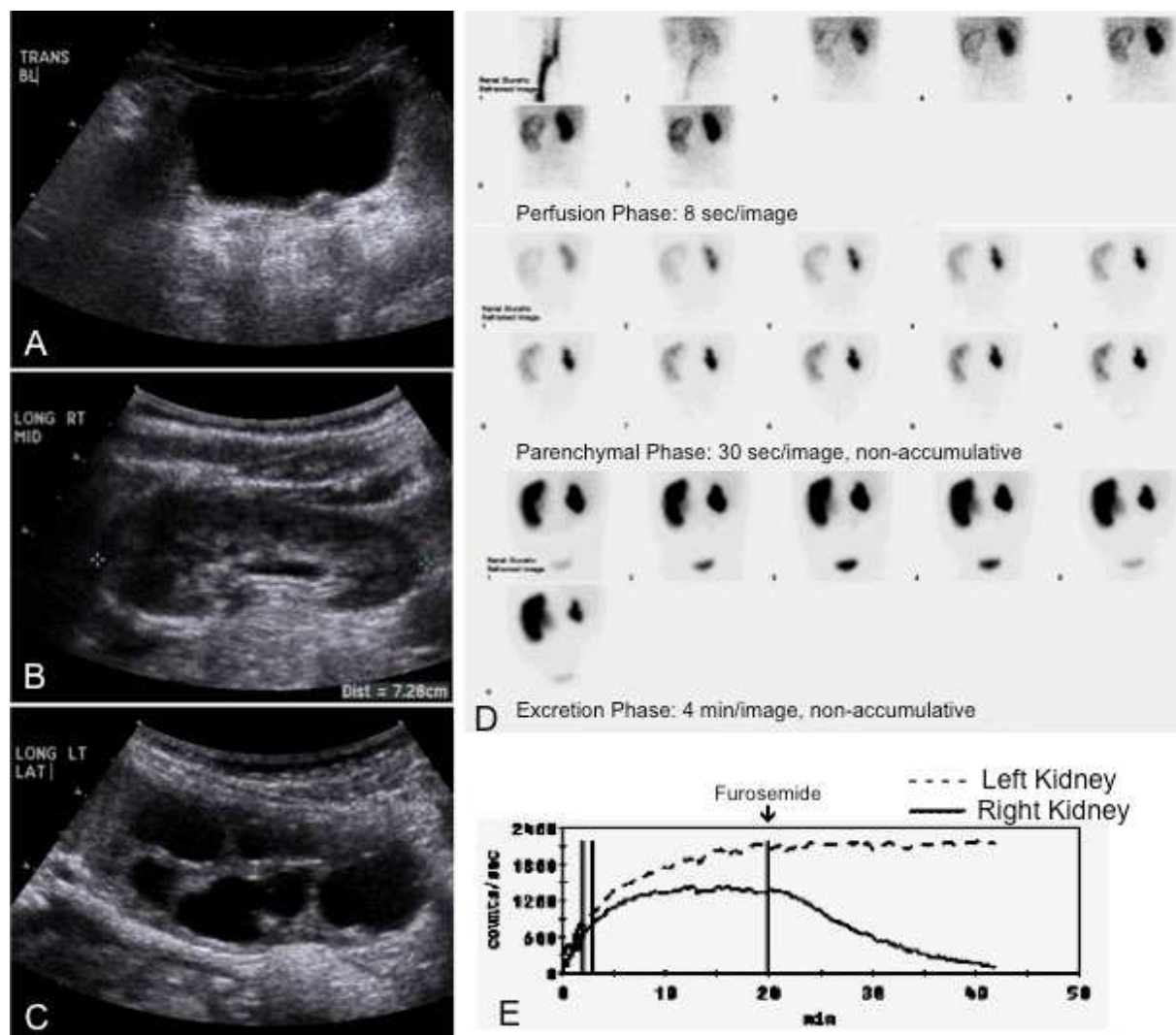


Fig. 1. Radiological findings associated with UPJ obstruction in an 18 month old female. Left hydronephrosis was detected prenatally, and the patient had normal postnatal renal function with no vesicoureteral reflux (VUR). She was managed conservatively, with gradual improvement in hydronephrosis on serial imaging studies through age 15 months. However, at 18 months of age hydronephrosis worsened. A - C. Ultrasound of urinary bladder (A), right (B) and left (C) kidneys. The bladder (A) is normal in conformation with normal wall thickness, and no hydroureter is seen. The right kidney (B) is structurally normal with slight pelviectasis. The left kidney (C) demonstrates marked hydronephrosis with blunted calyces and thinned parenchyma, which had worsened from previous findings of moderate but improving hydronephrosis. D and E. Technetium-99m MAG3 diuretic renal scan using the F+20 protocol confirmed a left ureteropelvic junction obstruction. Sequential posterior images of the abdomen and pelvis (D) are grouped into perfusion, parenchymal, and excretion phases. Ten milligrams of furosemide were administered 20 minutes after tracer injection. With injection of the tracer, there is bolus visualization of the inferior vena

cava, followed by prompt visualization of renal parenchyma bilaterally. On the right side, there is prompt cortical transit and accumulation in a normal-caliber collecting system followed by appropriate washout. Renogram curve (E) shows a normal right drainage half-time ($T_{1/2}$) of 8.9 minutes. On the left side, the kidney is enlarged with central photopenia consistent with hydronephrosis. Cortical transit is slightly delayed on the left compared to the right. In the excretion phase, tracer accumulates in the hydronephrotic collecting system but there is no washout of the radiopharmaceutical from the left kidney. Left $T_{1/2}$ was not reached in the duration of the study. The patient subsequently underwent left pyeloplasty for UPJ obstruction.

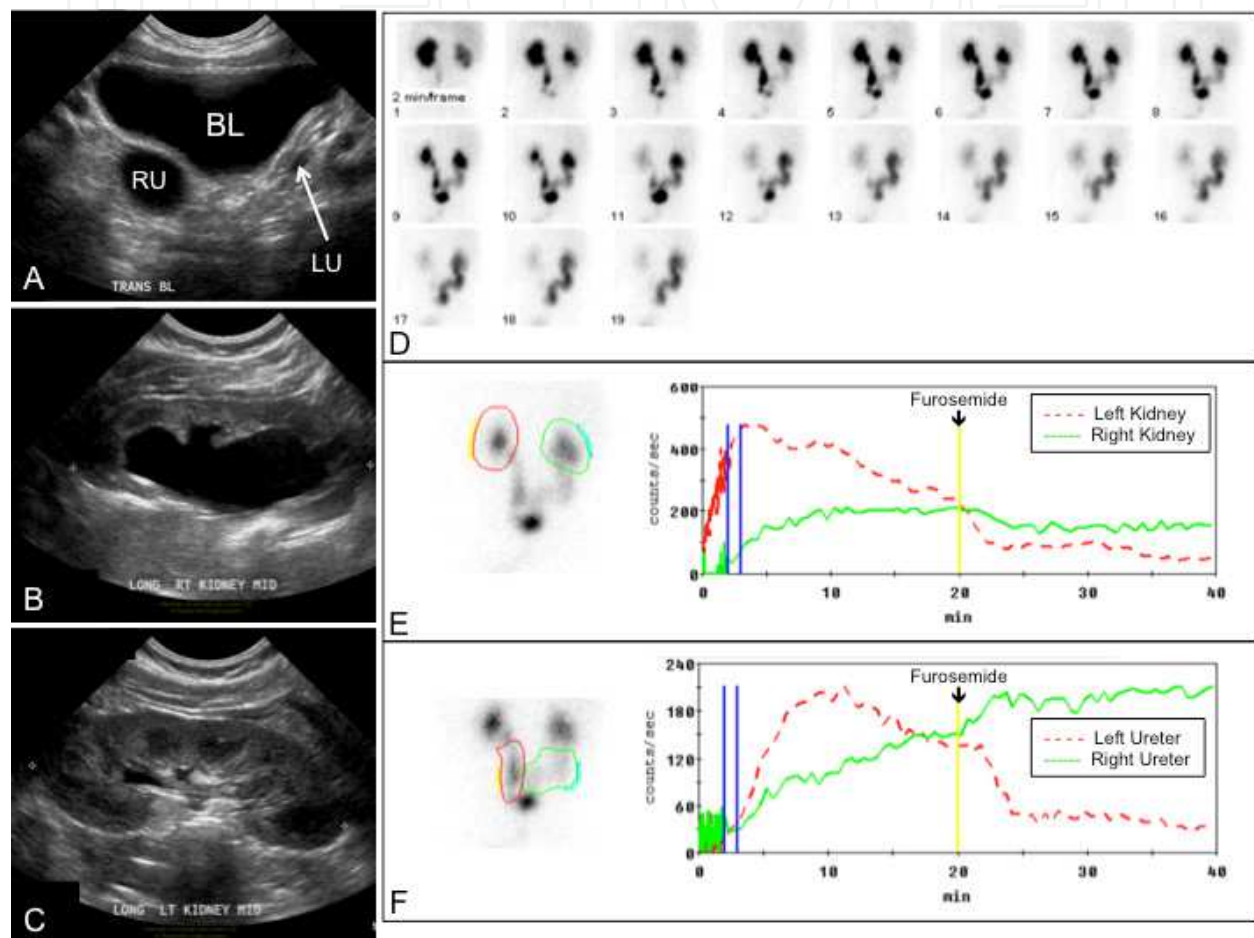


Fig. 2. Radiological findings associated with UVJ obstruction in a 4 month old male. **A - C.** Ultrasound of urinary bladder (A), right (B) and left (C) kidneys. The bladder (BL) is normal in conformation with a smooth wall of normal thickness. Bilateral distal hydroureter is seen, greater on the right (RU) than the left (LU). The right kidney (B) is moderately hydronephrotic with well-preserved parenchyma. The left kidney (C) demonstrates normal echotexture and no hydronephrosis, but urothelial thickening is seen. **D - F.** Technetium-99m MAG3 diuretic renal scan using the F+20 protocol confirmed a right UVJ obstruction. Sequential posterior images are shown for the excretion phase only (D). Renogram curves are illustrated for both kidneys (E) as well as for both ureters (F). Appropriate excretion is observed in the left kidney and ureter both before and after administration of furosemide. On the right side, minimal excretion is demonstrated prior to and following the diuretic. Renal $T_{1/2}$ is 2.3 minutes on the left and never reached on the right.

3.1.3 Ureterocele

Ureteroceles are cystic dilations of the submucosal or intravesical segment of a ureter (Figure 3). If the opening to the ureterocele is stenotic or ectopically positioned, obstruction often results. The prevalence of ureterocele is 1 in 5000 newborns. Unlike the majority of obstructive lesions, ureteroceles demonstrate a female predominance (Woodward & Frank, 2002). Ureteroceles are often associated with a duplex collecting system and/or ectopic ureteral insertion. Depending on the location, configuration and size, unilateral ureteroceles may cause bilateral obstruction. Bilateral ureteroceles are present in 20-50% of cases (Pohl et al., 2007).

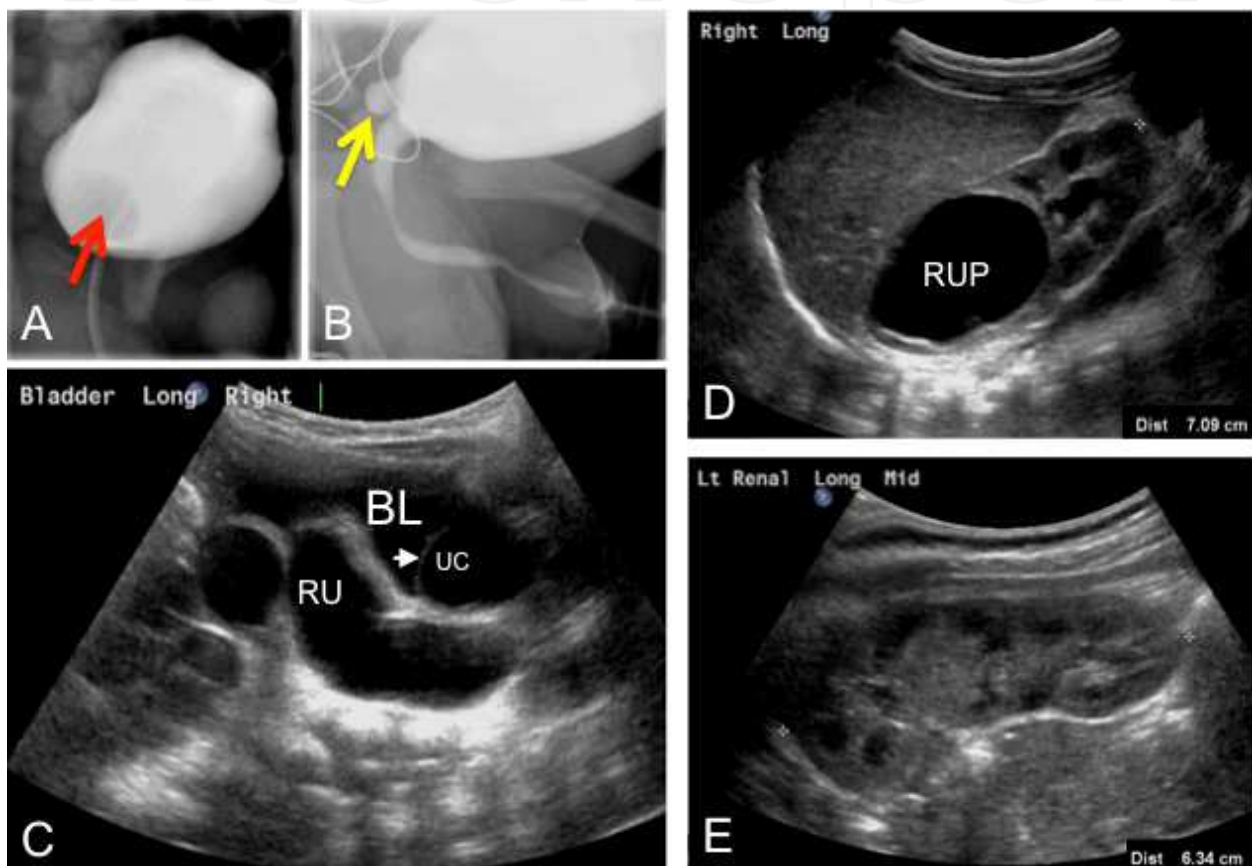


Fig. 3. Radiological findings associated with ureterocele in a 6 day old male. **A and B.** Voiding cystourethrogram (VCUG). Filling image (A) shows the ureterocele as an ovoid filling defect (red arrow). Voiding image (B) shows eversion of the ureterocele (yellow arrow) through an ectopic ureteral insertion, resembling a congenital paraurethral diverticulum. **C - E.** Ultrasound of urinary bladder (C), right (D) and left (E) kidneys. The bladder (BL, image C) is minimally distended but demonstrates smooth walls of normal thickness. Within the bladder, the thin rounded septation (white arrowhead) delineating the ureterocele (UC) is seen. A markedly dilated right distal ureter (RU) is also evident on this lateral, longitudinal view. The right hydroureter is associated with right upper pole hydronephrosis (RUP, image D) in a duplex right kidney. There is minimal hydronephrosis in the right lower pole duplex moiety. A duplex kidney is also observed on the left (E), with no hydronephrosis.

3.1.4 Other upper urinary tract obstructions

Although less common than UPJ or UVJ obstructions, congenital obstructions can arise elsewhere within the kidney or along the course of the ureter. Examples include infundibular or infundibulopelvic stenosis, which may be idiopathic or associated with Beckwith-Wiedemann or Bardet-Biedl syndrome; anomalous ureteric position, such as a retroiliac or retrocaval course; and mid-ureteral stricture.

3.2 Lower urinary tract obstructions

There are several congenital anomalies that result in chronic lower urinary tract obstruction, the most familiar being posterior urethral valves (PUV). Other inborn causes of lower urinary tract obstruction include urethral atresia, stenosis or hypoplasia; anterior urethral valves; urethral diverticula; and cloacal anomalies. Congenital lower urinary tract obstructions put both kidneys at risk for abnormalities in fetal renal development and impaired renal function, and may be associated with oligohydramnios and pulmonary hypoplasia. Congenital lower urinary tract obstructions may also result in bladder dysfunction, ultimately leading to a secondary functional obstruction that may require careful management to optimize renal outcomes.

3.2.1 Posterior urethral valves

PUV, also known as *congenital obstructing posterior urethral membrane*, is found in 1 out of 5000-8000 live births, and occurs only in males (King, 1985). Oligohydramnios is a common consequence, and renal dysplasia may also be present. Using postnatal fluoroscopic VCUG, the gold standard for diagnosis of PUV and other lower urinary tract obstructions (Riedmiller et al., 2001), the classic finding for PUV is a linear filling defect in the column of radiocontrast filling a markedly dilated posterior urethra. However, this distinct linear radiolucent band corresponding to the “valve” is not always seen, because the obstructing membrane can become distended and take on a more sail-like or windsock appearance, as shown in Figure 4. Secondary VUR is found in 25-50% of PUV cases (Agarwal, 1999). In a subset of patients, unilateral VUR may provide a “pop-off” effect, whereby renal tissue and function on the non-refluxing side is preserved at the expense of severe dysplasia and dysfunction in the refluxing kidney (Greenfield et al., 1983).

3.2.2 Urethral atresia, stenosis, or hypoplasia

Although PUV is the most common cause of congenital lower urinary tract obstruction postnatally, detailed postmortem analysis of fetuses with megacystis and hyperechogenic kidneys showed that isolated severe lower urinary tract obstruction before 25 weeks' gestation was as likely to be due to urethral atresia or stenosis as PUV (Robyr et al., 2005). Urethral atresia may arise in association with complex collections of other genitourinary and/or gastrointestinal anomalies. Moreover, urethral atresia may be a cause of bladder outlet obstruction in females whereas PUV is not. Urethral atresia is incompatible with life unless an alternative connection between the bladder and the amniotic sac is present. Prenatal surgical decompression has been performed to relieve this obstruction, although a spontaneous fistula or patent urachus may also provide the necessary bladder drainage

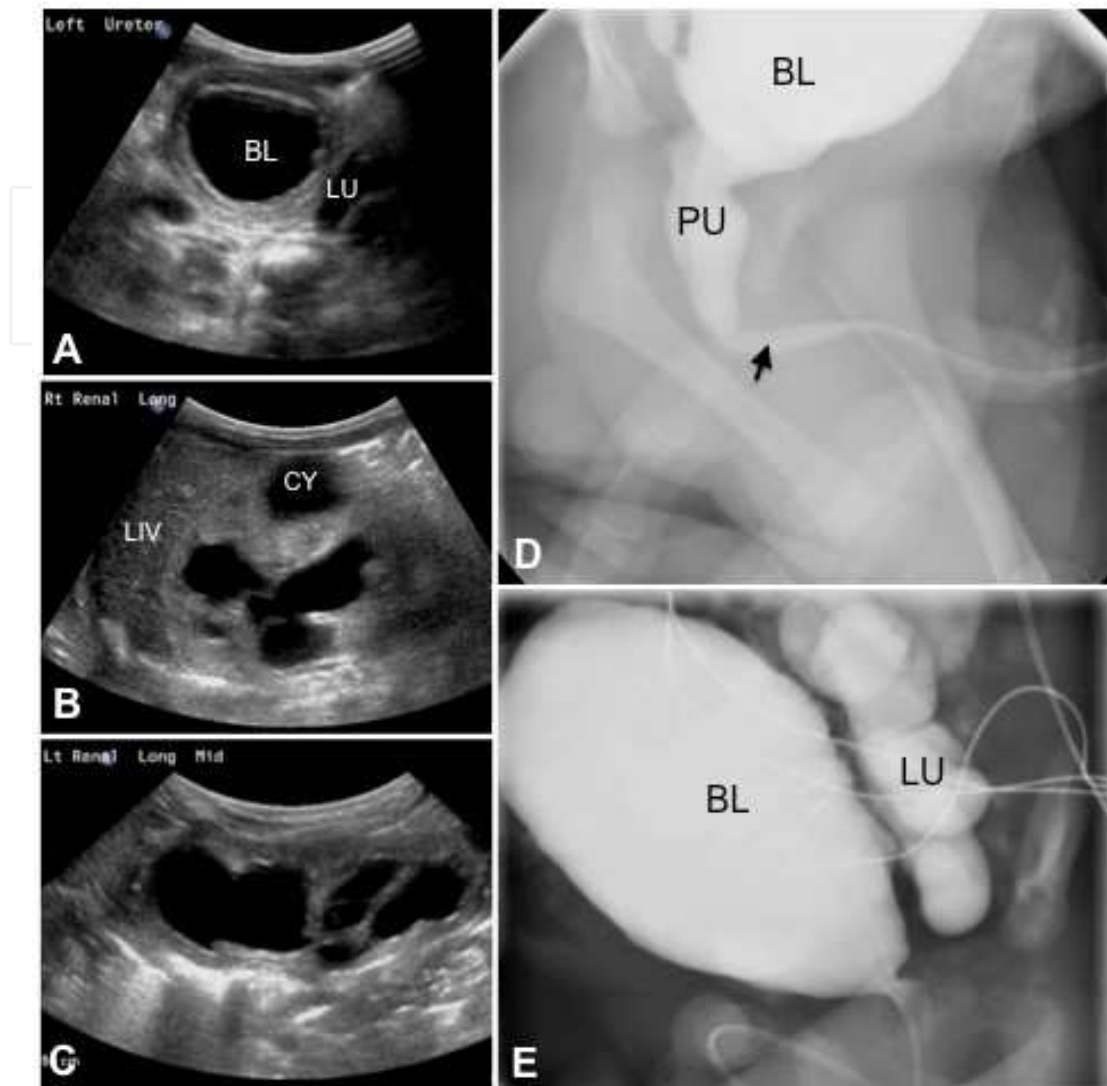


Fig. 4. Radiological findings associated with PUV in a 2 day old male. **A - C.** Ultrasound of urinary bladder (A), right (B) and left (C) kidneys. The bladder (BL) is rounded with a thickened and trabeculated wall. This patient had severe hydroureter bilaterally, although only the left ureter (LU) is clearly observed in image A. Moderate to severe hydronephrosis is present bilaterally, with thinning of the cortex, increased echogenicity relative to the liver (LIV), and poor corticomedullary differentiation. One fluid-filled area (CY) in the right kidney did not clearly communicate with the collecting system, and likely represents a large cyst. **D and E.** VCUG. The lobulated and undulating contours of the urinary bladder (BL) reflect thickening and trabeculation of the bladder wall. The posterior urethra (PU) is dilated. Rather than the classic abrupt transition to a normal caliber anterior urethra, this patient has the “wind-sock” appearance generated by distal prolapse or distention of the valve membrane (arrow). VUR into a tortuous and dilated left ureter (LU) is obvious.

(Gonzalez et al., 2001; Herndon & Casale, 2002). An association between urethral atresia and prune belly syndrome has been recognized (Reinberg et al., 1993). Progression to ESRD is

common, although not universal, in surviving patients with urethral atresia (Gonzalez, et al., 2001).

3.2.3 Prolapsing ureterocele

Large ureteroceles can prolapse through the urethra, which may result in bladder outlet obstruction. This is most frequently an acquired condition, although rarely prolapse may occur *in utero*, leading to features of congenital obstructive nephropathy (Sozubir et al., 2003).

3.2.4 Other urethral obstructions

Urethral diverticula and anterior urethral valves are rare causes of infravesicular obstruction. Interestingly, although bladder pathology and variable degrees of hydroureteronephrosis result, renal function is usually not impaired after surgical correction of the obstruction (Arena et al., 2009; Gupta & Srinivas, 2000; Rawat et al., 2009).

3.3 Functional obstruction

Functional urological obstructions are conditions that result in impaired antegrade urine flow without evidence of a physical blockage. In many patients, the situation may be transient and can ultimately resolve without intervention, in which case a specific etiology may never be identified. In other cases a functional obstruction may result from myogenic or neurogenic causes, which can result in lifelong voiding dysfunction as well as significant renal impairment. Examples include conditions such as congenital neurogenic bladder (Ewalt & Bauer, 1996), congenital non-neurogenic neurogenic bladder (Vidal et al., 2009), and prune belly syndrome (Woodhouse et al., 1982).

3.4 Multisystem conditions associated with obstruction or voiding dysfunction

3.4.1 Prune belly syndrome

Prune belly syndrome (Figure 5), also known as Eagle-Barrett syndrome, consists of the triad of underdeveloped abdominal wall musculature, urinary tract dilatation, and undescended testicles (Eagle & Barrett, 1950). Postnatally, urinary obstruction in prune belly syndrome is often functional rather than anatomic in nature. Prune belly syndrome has an incidence of 3.8 per 100,000 male births (Routh et al., 2010). The condition also occurs rarely in females, albeit necessarily lacking cryptorchidism (Reinberg, et al., 1991). Secondary VUR is present in 85% of patients with prune belly syndrome, and associated anomalies of the gastrointestinal, pulmonary, skeletal, and/or cardiac systems are common (Strand, 2004).

Two major theories, which are not mutually exclusive, have been advocated regarding the development of prune belly syndrome. One proposes that the condition arises from a fundamental flaw in mesoderm development (Straub & Spranger, 1981), while the other suggests that prune belly syndrome originates from a severe fetal urethral obstruction that results in massive distention of the bladder, degeneration of the abdominal wall musculature, and interruption of testicular descent (Pagon et al., 1979).

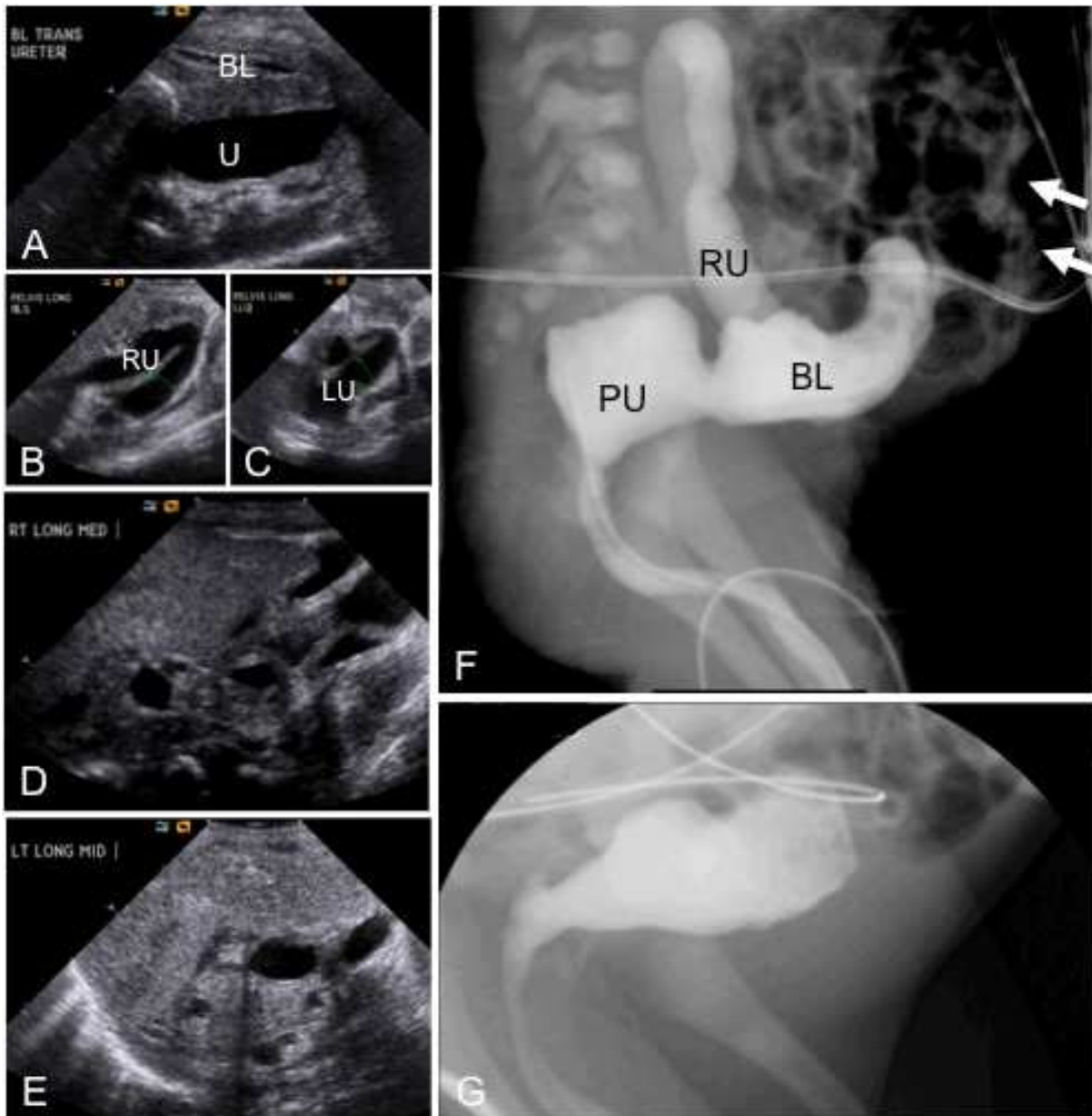

Fig. 5. Radiological findings associated with prune belly syndrome in a 2 day old male. **A - E.** Ultrasound of urinary bladder (A), right (B) and left (C) ureters, right (D) and left (E) kidneys. The bladder (BL) is decompressed but bladder wall thickness is normal. Tortuous dilated ureters (U, RU, LU) are observed bilaterally in the lower abdomen. The kidneys are dysplastic and amorphous in appearance, with cysts of varying sizes. There is no corticomedullary differentiation in either kidney. **F.** VCUG. The protuberant abdomen resulting from lack of abdominal wall musculature is evident from the position of bowel loops (arrows) on this lateral view. This patient has an unusual configuration of the bladder, bladder base and posterior urethra. There is absence of the normal prostate and a very distended posterior urethra (PU) connecting to a dysplastic-appearing bladder (BL). No evidence of true PUV was found on this or any subsequent investigations. Reflux is observed into the distended right ureter (RU) but not the left. **G.** VCUG from another patient 10 days postnatally shows a more typical trabeculated bladder with the characteristic tubular shape of the bladder base in prune belly syndrome.

3.4.2 Spina bifida

Approximately 50% of children with myelomeningocele have detrusor-bladder sphincter dyssynergy, resulting in a functional bladder outlet obstruction and development of hydronephrosis (Anderson & Travers, 1993). These patients can develop the same complications as those with anatomical obstructions, including upper urinary tract dilatation, VUR, incomplete bladder emptying, recurrent urinary tract infections, and CKD (van Gool et al., 2001).

4. Diagnosis of congenital obstructive nephropathy

4.1 Prenatal ultrasound

In developed countries, antenatal diagnosis of congenital urinary obstructions is often made in mid-gestation (at 18-20 weeks), when many pregnant women undergo a detailed prenatal ultrasound. Megacystis with or without oligohydramnios is the characteristic ultrasound finding of lower urinary tract obstruction, whereas hydronephrosis may signal upper or lower urinary tract obstruction. Hydronephrosis is the most commonly detected anomaly on prenatal ultrasound, found in as many as 4.5% of fetuses (Ismaili, et al., 2003). Prenatal hydronephrosis may result from non-obstructive processes such as primary VUR or physiologic dilatation as well as from obstruction. Differentiating obstruction from non-obstructive causes of congenital hydronephrosis is critical because the prognosis and management vary significantly among these conditions. Factors for consideration in assessing fetal hydronephrosis include gestational age; gender; whether the finding is unilateral or bilateral; the degree of dilatation; the ultrasonic appearance of the renal parenchyma, including presence/absence of a kidney, echogenicity, evidence of cysts or dysplasia, cortical thickness, and corticomedullary differentiation; the presence, volume, and structure of the bladder; any evidence of dilatation elsewhere in the urinary tract; the presence of other abnormalities of the urogenital system (such as duplication) or outside the urinary tract; amniotic fluid volume; and the progression of all findings over serial evaluations (Pates & Dashe, 2006). Several diagnostic algorithms have been proposed for the evaluation of patients with prenatally detected hydronephrosis (de Kort et al., 2008; Ismaili et al., 2005; Karnak et al., 2009; Riccabona et al., 2008; Shokeir & Nijman, 2000; Yiee & Wilcox, 2008).

4.2 Postnatal diagnosis

In the neonate with a suspected urological obstruction, multiple modalities may be needed for full evaluation. Renal ultrasound and voiding cytourethrogram usually play important roles in postnatal assessment of these patients, and in some cases CT, MRI, diuretic renography, urodynamic studies, or cystoscopy may be useful.

If not detected prenatally, congenital obstructive nephropathy may present in the neonate, infant, child, adolescent or adult with poor urine output, weak urine stream, abdominal distention, palpable abdominal or flank mass, pain, incontinence, urinary tract infection, hematuria, altered serum chemistries, or as an incidental finding on imaging studies.

4.3 Prospective diagnostic and prognostic biomarkers

Many attempts have been made to identify useful diagnostic and prognostic biomarkers for congenital obstructive nephropathy. These include gestational age at diagnosis (Hutton et al., 1994); the volume of amniotic fluid (Oliveira et al., 2000; Sarhan et al., 2008); the presence of megacystis (Oliveira, et al., 2000); the appearance of the renal parenchyma on prenatal ultrasound (Morris et al., 2009; Robyr, et al., 2005; Sarhan, et al., 2008); fetal urinary sodium, calcium, β 2-microglobulin, and other urinary solutes and proteins (Decramer et al., 2008; Morris et al., 2007). Additionally, pilot studies show that urine proteome analysis can identify urodynamically significant UPJ obstruction in infants with hydronephrosis with a sensitivity of 83% and a specificity of 92%, although the test had poor diagnostic accuracy in patients older than 1 year of age (Drube et al., 2010). Although several of these markers and tests show promise as diagnostic or prognostic tools, no consensus yet exists as to the best panel of biomarkers to assess congenital obstructive nephropathy.

Prenatally, the volume of amniotic fluid as well as ultrasound appearance of the bladder, urethra, and kidneys are common discriminators of the plan of care. Analysis of fetal urine can provide additional information; fetal urinary sodium less than 100 mmol/L, chloride less than 90 mmol/L, osmolality less than 210 mOsm/L, and low levels of urinary protein indicate good renal function (Shokeir & Nijman, 2000). Postnatally and in patients who present outside the neonatal period, management decisions are most frequently reliant on ultrasonography findings and other imaging modalities, coupled with serial measurements of serum creatinine. Serum creatinine is a relatively late marker of renal injury whose elevation often signals irreversible kidney damage (Nickavar et al., 2008; Sarhan et al., 2010). Nonetheless, nadir serum creatinine level is a useful and reliable prognostic indicator in patients with congenital obstructive nephropathy (Ansari et al., 2010; Bajpai et al., 2001; Warshaw et al., 1985).

5. Clinical course, management, and outcomes

The effects of fetal urinary tract obstruction on renal development, renal function, and urodynamics will be unique to each individual patient, and there may be significant clinical variability between patients thought to have similar obstructive lesions or processes. The clinical course is influenced by many factors; those intrinsic to each patient include the developmental stage at which the obstruction arises, the degree and duration of blockage, and its location. However, accurate tools to measure and determine the prognostic impact of these various factors in any individual case do not exist.

5.1 Management of congenital upper urinary tract obstruction

Regardless of the specific cause, unilateral upper urinary tract obstructive lesions rarely result in azotemia. Conservative management of these patients is often recommended, with surgery reserved for patients with clinical symptoms or declining renal function. However, over time up to 50% of patients with unilateral UPJ obstruction will meet these criteria and require surgical correction (Chertin et al., 2006). Additionally, some authors have raised concern about an increased long-term risk for hypertension as a result of ureteral obstruction, advocating for reconsideration of these conservative management approaches (Carlstrom, 2010). Relative to unilateral obstruction, bilateral upper tract obstruction or obstruction of a solitary functional kidney is far more ominous, and generally requires prompt surgical intervention and careful postsurgical management to minimize and monitor renal injury.

5.2 Natural history of lower urinary tract obstruction

Obstruction of the bladder outlet or urethra affects urologic and renal functions at all points proximal to the lesion. Extrarenal effects may also occur, primarily in the lungs due to associated oligohydramnios. The profound changes that can result are outlined in Figure 6.

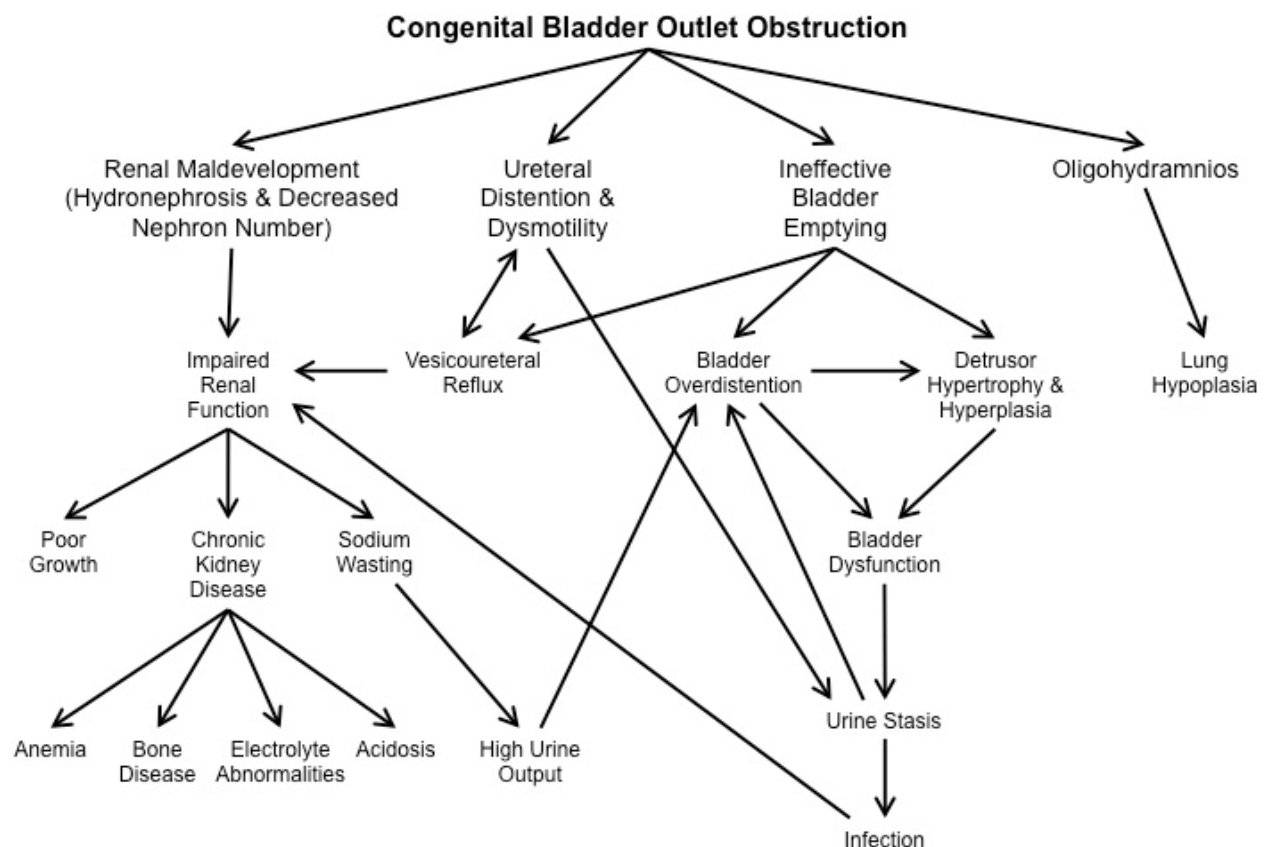


Fig. 6. Cascade of physiological consequences associated with lower urinary tract obstruction.

As many as 70% of boys with PUV develop advanced chronic or end-stage kidney disease (CKD Stage 3-5; Parkhouse et al., 1988; Reinberg et al., 1992; Roth et al., 2001; Sanna-Cherchi, et al., 2009). Those with ultrasound findings at or before 24 weeks' gestation are significantly more likely to have a poor renal outcome than children with PUV detected later in pregnancy after a normal second trimester scan (Hutton, et al., 1994). Among patients with PUV who survive the perinatal period, bladder dysfunction and nadir serum creatinine greater than 1.0 mg/dl are independent risk factors for progression to end stage renal disease (Ansari, et al., 2010; DeFoor et al., 2008). Unilateral or bilateral VUR associated with PUV may also have a significant impact on kidney function (Heikkila et al., 2009).

Long-term follow-up studies decades after treatment for PUV offer additional insight into the postnatal renal progression of this condition. Holmdahl and colleagues (2005) assessed Swedish men who were treated for PUV between 1956 and 1970. Over the 30 to 40 years between initial intervention and this follow-up assessment, the prevalence of ESRD in this population increased from 8% to 21%, and only 37% of the cohort had apparently normal renal function as adults (Holmdahl & Sillen, 2005). Kousidis et al. (2008) found that in a British cohort of patients diagnosed prenatally between 1984 and 1996, 28% died or

developed ESRD and 58% had normal renal function after a mean follow-up of 17.7 years. The authors of the latter study note that for the more severely affected patients, the functional outcome may be primarily determined by the severity of intrauterine obstruction and presence of renal dysplasia and not significantly altered by early diagnosis and treatment; however, for patients with more moderate disease, long-term prognosis may be improved by prenatal diagnosis and early interventions (Kousidis, et al., 2008). Other studies have not shown a statistically significant difference in outcomes between patients with renal dysplasia and those with normal-appearing kidneys (Nickavar, et al., 2008; Ylinen et al., 2004).

5.3 Antenatal intervention

Antenatal intervention for suspected fetal obstructive nephropathy has been attempted by vesicoamniotic shunting, vesicocentesis, fetal cystoscopy, or open fetal bladder surgery. The results are variable and these methods remain controversial. A 2003 meta-analysis of the available data suggested improved perinatal survival following prenatal bladder drainage, particularly in cases with poor predicted prognoses (Clark et al., 2003). However, these procedures carry a high risk for complications including shunt malfunction or migration, urinary ascites, hemorrhage, chorioamnionitis, iatrogenic gastroschisis, premature labor, or miscarriage (Carr & Kim, 2010; Elder et al., 1987). The Percutaneous shunting in Low Urinary Tract Obstruction (PLUTO) study, a multicenter, prospective, randomized trial, was designed to systematically evaluate the prenatal and perinatal outcomes and risk/benefit ratio of *in utero* intervention for urological obstruction versus conservative management, and is currently in the data analysis phase (Kilby et al., 2007; Morris & Kilby, 2009; University of Birmingham, 2011).

5.4 Postnatal intervention

In cases where renal function is affected or threatened, surgical relief of the obstruction or diversion of the urine path is necessary. Stents, catheters, or percutaneous drains may be useful to provide temporary drainage, but long-term management requires surgery. Discussion of the variety of surgical techniques and approaches that may be implemented in the management of congenital urinary obstructions is beyond the scope of this review.

Although such surgical interventions can relieve some of the effects of congenital impairment of urine flow, many developmental and pathologic changes associated with this condition appear irreversible. Many patients with congenital obstructive nephropathy, including the majority of patients with PUV, do not have complete recovery of kidney function following postnatal intervention (Parkhouse, et al., 1988; Reinberg, et al., 1992; Roth, et al., 2001; Sanna-Cherchi, et al., 2009).

5.5 Progressive chronic kidney disease in congenital obstructive nephropathy

Given the frequency of chronic and progressive renal impairment, the importance of long-term monitoring of all patients with congenital obstructive nephropathy cannot be overemphasized. Serial measurements of renal function, periodic urinalysis, blood pressure checks, and monitoring of growth should be performed for all patients with a history of congenital urinary obstruction. Renal impairment, if detected, should be fully evaluated and

managed, along with any complications of CKD such as hypertension, proteinuria, electrolyte abnormalities, metabolic acidosis, anemia, dyslipidemia, or renal bone disease. In young adult patients with congenital obstructive nephropathy and CKD, there is a strong correlation between proteinuria and rate of decline in renal function. The ItalKid Project found no benefit from angiotensin converting enzyme inhibitors (ACEi) in a population of patients with renal hypodysplasia, many of whom also had congenital obstructive nephropathy (Ardissino, 2007). However, a later study in young adults with congenital obstructive nephropathy or primary VUR with hypodysplasia indicated that ACEi can slow this decline in renal function, but impact renal outcome only when the estimated glomerular filtration rate is greater than 35 ml/min (Neild, 2009b). In patients with post-obstructive bladder dysfunction, an individualized voiding regimen designed to maintain bladder volume below a critical filling volume can stabilize deteriorating renal function (Hale et al., 2009).

5.6 End-stage kidney disease due to congenital obstructive nephropathy

For patients with congenital obstructive nephropathy who progress to ESRD, renal transplantation is generally a safe and effective therapy, with 5 year graft survival rates approximately 85% for living donor transplants and 72% for deceased donor grafts in patients with a primary diagnosis of obstructive nephropathy (NAPRTCS, 2009). Appropriate and effective management of any residual urinary tract dysfunction is critical to long-term outcomes following renal transplantation in patients with congenital obstructive nephropathy (Morita et al., 2009).

6. Experimental models of congenital obstructive nephropathy

The experimental analysis of urological obstructions dates back to antiquity. The physician Galen of Pergamon described ligation of both the ureter and the urethra in animals in the 2nd century A.D. (Galen, 1914). In the 21st century, surgical introduction of a urologic obstruction is still an important research tool. Other animal models of congenital obstructive nephropathy have been created by non-surgical approaches, including genetic manipulation and chemical induction. This review focuses on animal models for investigating the consequences of obstruction on the subsequent maturation and function of the kidneys and urinary tract. For an analysis of how mouse models have contributed to understanding ureter and bladder organogenesis from the earliest stages of development, we recommend Dr. Mendelsohn's excellent review (Mendelsohn, 2009).

6.1 Surgical models

6.1.1 Ureteral ligation/Unilateral ureteral obstruction

The vast majority of data on the progression of renal injury following urinary tract obstruction has come from experiments involving surgical ligation of a ureter, a technique known as unilateral ureteral obstruction (UUO) (Bing et al., 2003; de Souza et al., 2004; Eroglu et al., 2004; Flynn et al., 2002; Hanai et al., 2002; Klahr & Morrissey, 2002; Stanton et al., 2003; Thiruchelvam et al., 2003). Several studies have examined partial or complete ureteral ligations in embryonic rabbits, opossums, and sheep (Becker & Baum, 2006; Kitajima et al., 2010; Steinhardt et al., 1994). In these models, animals develop hydroureteronephrosis *in utero* with variable degrees of renal dysplasia depending on the timing and severity of obstruction.

The majority of investigations using UUO have employed postnatal and adult rats, mice and pigs. In these species, nephrogenesis continues for a limited period after birth (Moritz & Wintour, 1999), so postnatal ligation in these animals may have some relevance to congenital ureteral obstructions. Even though postnatal models do not reproduce the fetal environment, the delay in renal maturation in rodents versus humans permits relative comparisons of the effects of obstruction on kidney development to be made. In addition, postnatal surgical models can isolate the effects of mechanical obstruction on the developing urinary tract from parallel renal maldevelopment, a concern that often confounds analysis of genetic models of congenital obstructive nephropathy. However, many obstructive lesions that lead to congenital obstructive nephropathy in humans arise earlier in the course of renal development, or exert their effects on the kidney more gradually, than the circumstances modeled by UUO. Therefore, the precise pathophysiological applicability of this model to congenital obstructive nephropathy remains to be determined.

UUO in rodents has been shown to have profound and often irreversible effects on renal growth, maturation, and function in neonatal and adult animals. The progressive renal injury associated with UUO has been characterized as four overlapping stages: 1) interstitial inflammation, 2) tubular and myofibroblast proliferation, 3) tubular apoptosis, and 4) interstitial fibrosis (Bascands & Schanstra, 2005; Chevalier, 2006; Klahr & Morrissey, 2002). The renin-angiotensin and transforming growth factor β (TGF- β) pathways appear to play critical roles in these changes (Bascands & Schanstra, 2005; Chevalier, 2006; Esteban et al., 2004; Inazaki et al., 2004).

6.1.2 Bladder outlet obstruction models

Surgical introduction of a bladder outlet obstruction has been investigated in fetal sheep, immature guinea pigs, and young rats (Cendron et al., 1994; Kitagawa et al., 2001; Kitagawa et al., 2004; Mostwin et al., 1991; O'Connor et al., 1997). As in ureteral obstruction models, the effects of these urethral manipulations are also highly dependent on the timing and severity of the obstruction. Experimental urethral ligation resulted in a spectrum of findings ranging from minimal renal pathology to hydronephrosis, renal dysplasia, pulmonary hypoplasia and/or Potter's sequence. Unfortunately, the data on surgical models of *in utero* bladder outlet obstruction are limited by small numbers of animals, and by the lack of complementary genetic studies since many of the large animal models are not easily amenable to genetic manipulation.

6.2 Chemically-induced models

The antineoplastic anthracycline antibiotic Adriamycin has well-known teratogenic effects, and has been used in pregnant rats to generate an animal model of congenital obstructive nephropathy (Kajbafzadeh et al., 2011; Thompson et al., 1978). At Adriamycin dosages above 1.5mg/kg/d, bladder hypoplasia or agenesis occurs in all offspring, but fetal viability is low. At decreased doses, Kajbafzadeh et al. (2011) observed a high frequency of hydronephrosis with coexisting bladder anomalies and minimal fetal lethality. The kidneys of these animals demonstrated cortical thinning and cystic dilatation of collecting ducts. However, Adriamycin-treated rats display multiple extrarenal anomalies consistent with the VATER/VACTERL association, including vertebral defects, anal atresia, tracheoesophageal

fistula with esophageal atresia, and radial limb dysplasia, which complicates application of this approach to modeling congenital obstructive nephropathy.

6.3 Genetic models

Although numerous genes have been postulated to play a role in the normal and abnormal development of the urinary tract, none have been shown to be directly responsible for the primary lesions associated with congenital obstructive nephropathy in humans. Even so, several mutational or transgenic rodent models of obstructive nephropathy have been described.

6.3.1 Naturally-arising mutations associated with obstructive nephropathy

Congenital progressive hydronephrosis, a hereditary condition in a mutant strain of *C57BL/6J* mice, results from a spontaneous point mutation in the aquaporin-2 gene. Affected mice produce excessive quantities of hypotonic urine, which is believed to exceed the capacity of the ureteral peristaltic machinery producing hydronephrosis, obstructive nephropathy, and death (McDill et al., 2006). Male *C57BL/KsJ* mice also have a high incidence of hydronephrosis, although the mechanism of this finding has not been identified (McDill, et al., 2006; Weide & Lacy, 1991). In both of these strains, hydronephrosis is not present at birth; therefore, the urological defect is hereditary, but not congenital. Genetic models that develop *in utero* obstruction include certain inbred lines of rats (Aoki et al., 2004; Fichtner et al., 1994; Miller et al., 2004) that develop unilateral UPJ obstruction. Some of these strains display minimal or no morphological change in the renal parenchyma, but one strain of Wistar rats has been shown to develop hydronephrosis, loss of renal parenchyma, tubular and ductal atrophy and dilation, and interstitial fibrosis (Seseke et al., 2000).

6.3.2 Targeted models with complex phenotypes

Mice with the targeted deletion of ADAMTS (a disintegrin and metalloproteinase with thrombospondin motifs), lysosomal membrane protein LIMP-2/LGP85, or calcineurin also develop urinary tract obstruction in the postnatal period (Chang et al., 2004; Gamp et al., 2003; Yokoyama et al., 2002). Transgenic mice over-expressing human chorionic gonadotropin develop functional urethral obstruction that is not apparent until adulthood (Rulli et al., 2003). Mice deficient in the transcription factor *Id2* (Aoki, et al., 2004; Fichtner, et al., 1994; Miller, et al., 2004) develop unilateral UPJ obstruction. Bilateral ureteral obstruction *in utero* has been reported in mice heterozygous for bone morphogenetic protein 4 (Miyazaki et al., 2000). However, each of these animal models exhibits complex urological phenotypes including renal hypoplasia, dysplasia, aplasia, ureteral tortuosity, or duplicated ureters, thereby confounding analysis due to the inextricability of the secondary effects of obstruction from primary renal maldevelopment.

Developmental urinary tract anomalies including hydronephrosis also arise from knockout of the uroplakin II or III genes and conditional knockout of homeobox gene *Lim1* in the nephric duct epithelium (Hu et al., 2000; Kong et al., 2004; Pedersen et al., 2005). However, VUR is also a prominent feature in these CAKUT models, and it is not clear whether there is a true or a functional obstruction, nor what the relative contributions of reflux and obstruction to the renal phenotype are.

Mice lacking either of the two angiotensin receptors likewise develop abnormal renal phenotypes. The *Agtr2* knockout has incomplete penetrance, with approximately 2-20% of mutant mice demonstrating a wide spectrum of renal and urological anomalies including UPJ stenosis or megaureter as well as multicystic dysplastic kidney, hypoplastic kidney, VUR, or duplicated ureter (Nishimura, et al., 1999). Deficiency of *Agtr1* produces a renal phenotype with some features similar to that seen in complete UUO, including papillary atrophy, medullary thinning, calyceal enlargement, tubulointerstitial apoptosis, macrophage infiltration, and fibrosis. The *Agtr1* mutant also demonstrates hypertrophy of the renal vasculature, a feature not seen in UUO models. There is some evidence supporting a role for *Agtr1* in promoting growth and contractility of smooth muscle cells (Miyazaki & Ichikawa, 2001), but the relative contributions of primary effects of the mutation on renal development and secondary consequences of a possible functional obstruction in these mice remain unclear. *Agtr1* knockout mice also display significant extrarenal abnormalities, including poor weight gain, marked hypotension, and increased frequency of ventral septal defects (Tsuchida et al., 1998).

6.3.3 Megabladder mouse

Our laboratory has identified a unique transgenic mouse model of congenital obstructive nephropathy designated the megabladder (*mgb*) mouse (Ingraham et al., 2010; Singh et al., 2007). As shown in Figure 7, these mice develop a nonfunctional, over-distended bladder due to a bladder-specific defect in smooth muscle differentiation. This leads to a functional lower urinary tract obstruction, antenatal hydronephrosis, and signs of renal failure evident shortly after birth. Male *mgb* homozygotes develop early renal insufficiency and rarely survive beyond 4-6 weeks, whereas females may live a year or longer.

Megabladder mice closely mirror the pathophysiology associated with a lower urinary tract obstruction in several key respects (Ingraham, et al., 2010; Singh, et al., 2007). *Mgb*^{-/-} mice develop a functional obstruction of the lower urinary tract that leads to hydroureteronephrosis during embryogenesis. *Mgb*^{-/-} mice are born with histopathological evidence of renal injury, indicating that their kidneys possess preexisting pathological changes resulting from *in utero* obstruction. The obstruction and its renal consequences develop within the uterine and fetal environment, in contrast to the postnatal timing of obstruction in UUO and many genetic models of obstructive nephropathy. *Mgb*^{-/-} mice preferentially develop right-sided hydronephrosis reminiscent of the “pop-off” mechanism theorized in children with PUV and secondary unilateral VUR (Greenfield, et al., 1983). *Mgb*^{-/-} mice also exhibit a variable clinical course, in much the same way that children with seemingly identical obstructive lesions may have very different clinical outcomes. Male *mgb*^{-/-} mice can be rescued from the complications of renal failure and early demise by cutaneous vesicostomy, but of the vesicostomized animals that survive the perioperative period, approximately 40% die within the first two weeks despite a patent stoma and no apparent surgical complications. This result is reminiscent of the fact that 27% to 70% of children with PUV will have progressive CKD despite surgery (Ansari, et al., 2010; Kousidis, et al., 2008; Parkhouse, et al., 1988; Roth, et al., 2001; Sanna-Cherchi, et al., 2009). Finally, *mgb*^{-/-} mice possess no extrarenal features to complicate their utilization as a functional model of congenital obstructive nephropathy. Taken together, these observations suggest that *mgb*^{-/-} mice represent an excellent experimental model for the study of the pathophysiological events associated with congenital obstructive nephropathy involving the lower urinary tract.

In the kidneys of *mgb*^{-/-} mice, fibrotic changes are observed in a distinctive pattern. Increased interstitial collagen deposition is first apparent in the renal parenchyma immediately subadjacent to the urothelium of the renal capsule, followed by the outer cortex near the renal capsule. In severe cases, fibrosis ultimately extends throughout the renal parenchyma. Altered patterns of α -smooth muscle isoactin (α -SMA), E-cadherin, TGF- β 1 and connective tissue growth factor expression are also observed in *mgb*^{-/-} kidneys, supporting a role for these pathways in the development of fibrosis associated with congenital obstructive nephropathy (Ingraham, et al., 2010). Severely affected *mgb*^{-/-} kidneys also display several dysplastic features including alteration in the developmental distribution of WT1 and PAX2. These observations are consistent with Edith Potter's classic work suggesting that the renal pathology associated with CAKUT includes varying degrees of renal hypodysplasia (Potter, 1972). In contrast to the well-characterized UUO model of upper urinary tract obstruction, inflammation does not appear to play a prominent or early role in the pathogenesis of renal injury in the megabladder model.

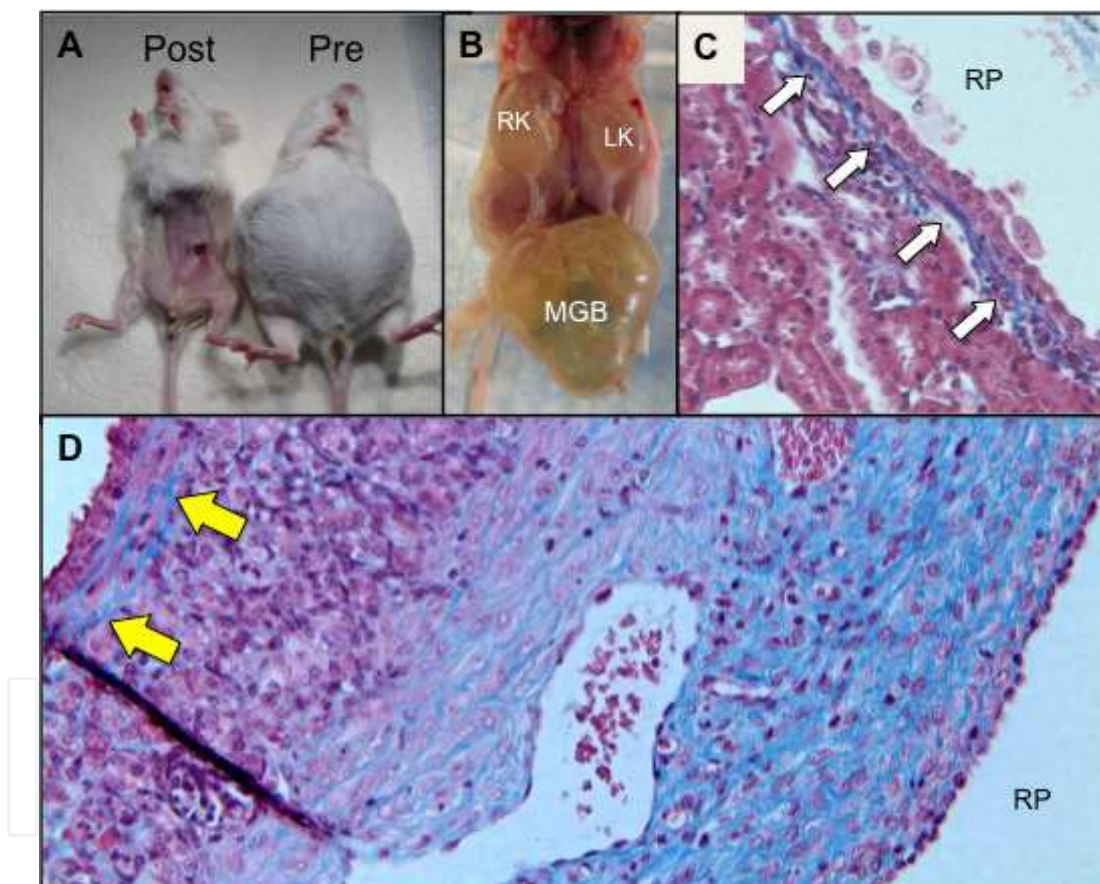


Fig. 7. Megabladder (*mgb*) mouse. **A.** Two *mgb*^{-/-} mice, prior to (right) and immediately after (left) cutaneous vesicostomy. The mouse on the right demonstrates a massively distended abdomen secondary to the megabladder, whereas the mouse on the left demonstrates the flat belly attained with decompression of the bladder. **B.** Upon dissection and with the megabladder (MGB) reflected caudally, hydronephrosis involving both kidneys (RK and LK) is apparent. **C.** Trichrome staining demonstrates a band of fibrosis (white arrows) underlying the urothelium in a mildly affected *mgb*^{-/-} mouse. **D.** In a more severely affected kidney from a *mgb*^{-/-} mouse, interstitial fibrosis (blue staining) extends throughout the renal medulla, and in a stripe along the outer cortex (yellow arrows) adjacent to the renal capsule.

7. Conclusion

Morbidity and mortality remain very high for patients with congenital obstructive nephropathy, with few effective therapeutic options. Clearly, additional research is needed to illuminate the cellular and molecular changes that characterize congenital obstructive nephropathy, with particular emphasis on developing reliable biomarkers and new therapeutic approaches to reduce the impact of this devastating disease. Experimental animal models of obstructive nephropathy have provided valuable information regarding renal pathogenesis and function following surgical occlusion or genetic manipulation. The continued development of new animal models of congenital obstructive nephropathy, like the *mgb* mouse, will provide increasing opportunities to identify and manipulate the key molecular pathways associated with the development of chronic renal failure, while at the same time providing an experimental platform for biomarker development and the assessment of novel therapeutic strategies.

8. Acknowledgment

We thank Dr. Andrew Schwaderer and Dr. Brian Becknell for valuable comments in drafting this manuscript, Ashley R. Carpenter for technical assistance in obtaining images of the *mgb* mouse, and our clinical colleagues at Nationwide Children's Hospital for patient cases and associated images.

9. References

- Agarwal, S. (1999). Urethral valves. *BJU Int*, 84(5), 570-578.
- Anderson, P. A., & Travers, A. H. (1993). Development of hydronephrosis in spina bifida patients: predictive factors and management. *Br J Urol*, 72(6), 958-961.
- Ansari, M. S., Gulia, A., Srivastava, A., & Kapoor, R. (2010). Risk factors for progression to end-stage renal disease in children with posterior urethral valves. *J Pediatr Urol*, 6(3), 261-264.
- Aoki, Y., Mori, S., Kitajima, K., Yokoyama, O., Kanamaru, H., Okada, K., & Yokota, Y. (2004). Id2 haploinsufficiency in mice leads to congenital hydronephrosis resembling that in humans. *Genes Cells*, 9(12), 1287-1296.
- Ardissino, G., Viganò, S., Testa, S., Daccò, V., Paglialonga, F., Leoni, A., Belingheri, M., Avolio, L., Ciofani, A., Claris-Appiani, A., Cusi, D., Edefonti, A., Ammenti, A., Cecconi, M., Fede, C., Ghio, L., La Manna, A., Maringhini, S., Papalia, T., Pela, I., Pisanello, L., & Ratsch, I. M. (2007). No clear evidence of ACEi efficacy on the progression of chronic kidney disease in children with hypodysplastic nephropathy - report from the ItalKid Project database. *Nephrol Dial Transplant*, 22(9), 2525-2530.
- Arena, S., Romeo, C., Borruto, F. A., Racchiusa, S., Di Benedetto, V., & Arena, F. (2009). Anterior urethral valves in children: an uncommon multipathogenic cause of obstructive uropathy. *Pediatr Surg Int*, 25(7), 613-616.
- Bajpai, M., Dave, S., & Gupta, D. K. (2001). Factors affecting outcome in the management of posterior urethral valves. *Pediatr Surg Int*, 17(1), 11-15.
- Bascands, J. L., & Schanstra, J. P. (2005). Obstructive nephropathy: insights from genetically engineered animals. *Kidney Int*, 68(3), 925-937.
- Becker, A., & Baum, M. (2006). Obstructive uropathy. *Early Hum Dev*, 82(1), 15-22.

- Bernardes, L. S., Aksnes, G., Saada, J., Masse, V., Elie, C., Dumez, Y., Lortat-Jacob, S. L., & Benachi, A. (2009). Keyhole sign: how specific is it for the diagnosis of posterior urethral valves? *Ultrasound Obstet Gynecol*, 34(4), 419-423.
- Bing, W., Chang, S., Hypolite, J. A., DiSanto, M. E., Zderic, S. A., Rolf, L., Wein, A. J., & Chacko, S. (2003). Obstruction-induced changes in urinary bladder smooth muscle contractility: a role for Rho kinase. *Am J Physiol Renal Physiol*, 285(5), F990-997.
- Brown, T., Mandell, J., & Lebowitz, R. L. (1987). Neonatal hydronephrosis in the era of sonography. *AJR Am J Roentgenol*, 148(5), 959-963.
- Carlstrom, M. (2010). Causal link between neonatal hydronephrosis and later development of hypertension. *Clin Exp Pharmacol Physiol*, 37(2), e14-23.
- Carr, M. C., & Kim, S. S. (2010). Prenatal management of urogenital disorders. *Urol Clin North Am*, 37(2), 149-158.
- Cendron, M., Horton, C. E., Karim, O. M., Takishima, H., Haberlik, A., Mostwin, J. L., & Gearhart, J. P. (1994). A fetal lamb model of partial urethral obstruction: experimental protocol and results. *J Pediatr Surg*, 29(1), 77-80.
- Chang, C. P., McDill, B. W., Neilson, J. R., Joist, H. E., Epstein, J. A., Crabtree, G. R., & Chen, F. (2004). Calcineurin is required in urinary tract mesenchyme for the development of the pyeloureteral peristaltic machinery. *J Clin Invest*, 113(7), 1051-1058.
- Chertin, B., Pollack, A., Koulikov, D., Rabinowitz, R., Hain, D., Hadas-Halpren, I., & Farkas, A. (2006). Conservative treatment of ureteropelvic junction obstruction in children with antenatal diagnosis of hydronephrosis: lessons learned after 16 years of follow-up. *Eur Urol*, 49(4), 734-738.
- Chevalier, R. L. (2006). Pathogenesis of renal injury in obstructive uropathy. *Curr Opin Pediatr*, 18(2), 153-160.
- Clark, T. J., Martin, W. L., Divakaran, T. G., Whittle, M. J., Kilby, M. D., & Khan, K. S. (2003). Prenatal bladder drainage in the management of fetal lower urinary tract obstruction: a systematic review and meta-analysis. *Obstet Gynecol*, 102(2), 367-382.
- de Kort, E. H., Bambang Oetomo, S., & Zegers, S. H. (2008). The long-term outcome of antenatal hydronephrosis up to 15 millimetres justifies a noninvasive postnatal follow-up. *Acta Paediatr*, 97(6), 708-713.
- de Souza, G. M., Costa, W. S., Bruschini, H., & Sampaio, F. J. (2004). Morphological analysis of the acute effects of overdistension on the extracellular matrix of the rat urinary bladder wall. *Ann Anat*, 186(1), 55-59.
- Decramer, S., P, Z. U. R., Wittke, S., Mischak, H., Bascands, J. L., & Schanstra, J. P. (2008). Identification of urinary biomarkers by proteomics in newborns: use in obstructive nephropathy. *Contrib Nephrol*, 160, 127-141.
- DeFoor, W., Clark, C., Jackson, E., Reddy, P., Minevich, E., & Sheldon, C. (2008). Risk factors for end stage renal disease in children with posterior urethral valves. *J Urol*, 180(4 Suppl), 1705-1708.
- Drube, J., Zurbig, P., Schiffer, E., Lau, E., Ure, B., Gluer, S., Kirschstein, M., Pape, L., Decramer, S., Bascands, J. L., Schanstra, J. P., Mischak, H., & Ehrich, J. H. (2010). Urinary proteome analysis identifies infants but not older children requiring pyeloplasty. *Pediatric nephrology*, 25(9), 1673-1678.
- Eagle, J. F., Jr., & Barrett, G. S. (1950). Congenital deficiency of abdominal musculature with associated genitourinary abnormalities: A syndrome. Report of 9 cases. *Pediatrics*, 6(5), 721-736.

- Elder, J. S., Duckett, J. W., Jr., & Snyder, H. M. (1987). Intervention for fetal obstructive uropathy: has it been effective? *Lancet*, 2(8566), 1007-1010.
- Eroglu, E., Kucukhuseyin, C., Ayik, B., Dervisoglu, S., Emir, H., & Danismend, N. (2004). Changes in the threshold voltage and alterations of smooth-muscle physiology after bladder outlet obstruction. *Eur J Pediatr Surg*, 14(1), 39-44.
- Esteban, V., Lorenzo, O., Ruperez, M., Suzuki, Y., Mezzano, S., Blanco, J., Kretzler, M., Sugaya, T., Egido, J., & Ruiz-Ortega, M. (2004). Angiotensin II, via AT1 and AT2 receptors and NF-kappaB pathway, regulates the inflammatory response in unilateral ureteral obstruction. *J Am Soc Nephrol*, 15(6), 1514-1529.
- Ewalt, D. H., & Bauer, S. B. (1996). Pediatric neurourology. *Urol Clin North Am*, 23(3), 501-509.
- Farnham, S. B., Adams, M. C., Brock, J. W., 3rd, & Pope, J. C. t. (2005). Pediatric urological causes of hypertension. *J Urol*, 173(3), 697-704.
- Fichtner, J., Boineau, F. G., Lewy, J. E., Sibley, R. K., Vari, R. C., & Shortliffe, L. M. (1994). Congenital unilateral hydronephrosis in a rat model: continuous renal pelvic and bladder pressures. *J Urol*, 152(2 Pt 2), 652-657.
- Flynn, B. J., Mian, H. S., Cera, P. J., Kabler, R. L., Mowad, J. J., Cavanaugh, A. H., & Rothblum, L. I. (2002). Early molecular changes in bladder hypertrophy due to bladder outlet obstruction. *Urology*, 59(6), 978-982.
- Galen. (1914). *On the Natural Faculties* (A. J. Brock, Trans.). New York: G. P. Putnam's Sons.
- Gamp, A. C., Tanaka, Y., Lullmann-Rauch, R., Wittke, D., D'Hooge, R., De Deyn, P. P., Moser, T., Maier, H., Hartmann, D., Reiss, K., Illert, A. L., von Figura, K., & Saftig, P. (2003). LIMP-2/LGP85 deficiency causes ureteric pelvic junction obstruction, deafness and peripheral neuropathy in mice. *Hum Mol Genet*, 12(6), 631-646.
- Gillenwater, J. Y., Westervelt, F. B., Jr., Vaughan, E. D., Jr., & Howards, S. S. (1975). Renal function after release of chronic unilateral hydronephrosis in man. *Kidney Int*, 7(3), 179-186.
- Gimpel, C., Masioniene, L., Djakovic, N., Schenk, J. P., Haberkorn, U., Tonshoff, B., & Schaefer, F. (2010). Complications and long-term outcome of primary obstructive megaureter in childhood. *Pediatric nephrology*, 25(9), 1679-1686.
- Gonzalez, R., De Filippo, R., Jednak, R., & Barthold, J. S. (2001). Urethral atresia: long-term outcome in 6 children who survived the neonatal period. *J Urol*, 165(6 Pt 2), 2241-2244.
- Greenfield, S. P., Hensle, T. W., Berdon, W. E., & Wigger, H. J. (1983). Unilateral vesicoureteral reflux and unilateral nonfunctioning kidney associated with posterior urethral valves--a syndrome? *J Urol*, 130(4), 733-738.
- Gupta, D. K., & Srinivas, M. (2000). Congenital anterior urethral diverticulum in children. *Pediatr Surg Int*, 16(8), 565-568.
- Hale, J. M., Wood, D. N., Hoh, I. M., Neild, G. H., Bomanji, J. B., Chu, A., & Woodhouse, C. R. (2009). Stabilization of renal deterioration caused by bladder volume dependent obstruction. *J Urol*, 182(4 Suppl), 1973-1977.
- Hanai, T., Ma, F. H., Matsumoto, S., Park, Y. C., & Kurita, T. (2002). Partial outlet obstruction of the rat bladder induces a stimulatory response on proliferation of the bladder smooth muscle cells. *Int Urol Nephrol*, 34(1), 37-42.
- Heikkila, J., Rintala, R., & Taskinen, S. (2009). Vesicoureteral reflux in conjunction with posterior urethral valves. *J Urol*, 182(4), 1555-1560.
- Herndon, C. D., & Casale, A. J. (2002). Early second trimester intervention in a surviving infant with postnatally diagnosed urethral atresia. *J Urol*, 168(4 Pt 1), 1532-1533.

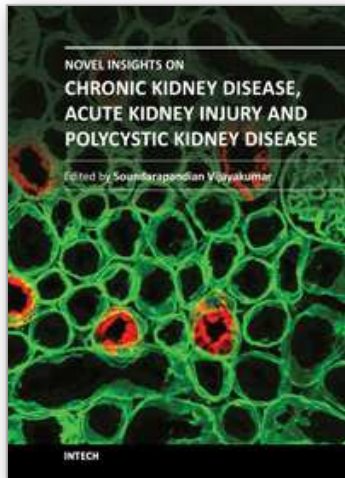
- Holmdahl, G., & Sillen, U. (2005). Boys with posterior urethral valves: outcome concerning renal function, bladder function and paternity at ages 31 to 44 years. *J Urol*, 174(3), 1031-1034; discussion 1034.
- Hosgor, M., Karaca, I., Ulukus, C., Ozer, E., Ozkara, E., Sam, B., Ucan, B., Kurtulus, S., Karkiner, A., & Temir, G. (2005). Structural changes of smooth muscle in congenital ureteropelvic junction obstruction. *J Pediatr Surg*, 40(10), 1632-1636.
- Hu, P., Deng, F. M., Liang, F. X., Hu, C. M., Auerbach, A. B., Shapiro, E., Wu, X. R., Kachar, B., & Sun, T. T. (2000). Ablation of uroplakin III gene results in small urothelial plaques, urothelial leakage, and vesicoureteral reflux. *J Cell Biol*, 151(5), 961-972.
- Hutton, K. A., Thomas, D. F., Arthur, R. J., Irving, H. C., & Smith, S. E. (1994). Prenatally detected posterior urethral valves: is gestational age at detection a predictor of outcome? *J Urol*, 152(2 Pt 2), 698-701.
- Inazaki, K., Kanamaru, Y., Kojima, Y., Sueyoshi, N., Okumura, K., Kaneko, K., Yamashiro, Y., Ogawa, H., & Nakao, A. (2004). Smad3 deficiency attenuates renal fibrosis, inflammation, and apoptosis after unilateral ureteral obstruction. *Kidney Int*, 66(2), 597-604.
- Ingraham, S. E., Saha, M., Carpenter, A., Robinson, M., Ismail, I., Singh, S., Hains, D., Robinson, M., Hirselj, D. A., Koff, S., Bates, C. M., & McHugh, K. M. (2010). Pathogenesis of renal injury in the Megabladder mouse: A genetic model of congenital obstructive nephropathy. *Pediatr Res*, 68, 500-507.
- Ismaili, K., Hall, M., Donner, C., Thomas, D., Vermeulen, D., & Avni, F. E. (2003). Results of systematic screening for minor degrees of fetal renal pelvis dilatation in an unselected population. *Am J Obstet Gynecol*, 188(1), 242-246.
- Ismaili, K., Hall, M., Piepsz, A., Alexander, M., Schulman, C., & Avni, F. E. (2005). Insights into the pathogenesis and natural history of fetuses with renal pelvis dilatation. *Eur Urol*, 48(2), 207-214.
- Kajbafzadeh, A. M., Javan-Farazmand, N., Motamedi, A., Monajemzadeh, M., & Amini, E. (2011). The optimal dose of Adriamycin to create a viable rat model potentially applicable to congenital obstructive uropathy. *J Pediatr Surg*, 46(8), 1544-1549.
- Karnak, I., Woo, L. L., Shah, S. N., Sirajuddin, A., & Ross, J. H. (2009). Results of a practical protocol for management of prenatally detected hydronephrosis due to ureteropelvic junction obstruction. *Pediatr Surg Int*, 25(1), 61-67.
- Kilby, M., Khan, K., Morris, K., Daniels, J., Gray, R., Magill, L., Martin, B., Thompson, P., Alfirevic, Z., Kenny, S., Bower, S., Sturgiss, S., Anumba, D., Mason, G., Tydeman, G., Soothill, P., Brackley, K., Loughna, P., Cameron, A., Kumar, S., & Bullen, P. (2007). PLUTO trial protocol: percutaneous shunting for lower urinary tract obstruction randomised controlled trial. *BJOG*, 114(7), 904-905, e901-904.
- King, L. R. (1985). Posterior urethral valves. In P. Kelalis, L. R. King & A. B. Belman (Eds.), *Clinical Pediatric Urology* (2nd ed., pp. 527-558). Philadelphia W. B. Saunders.
- Kitagawa, H., Pringle, K. C., Koike, J., Zuccollo, J., & Nakada, K. (2001). Different phenotypes of dysplastic kidney in obstructive uropathy in fetal lambs. *J Pediatr Surg*, 36(11), 1698-1703.
- Kitagawa, H., Pringle, K. C., Koike, J., Zuccollo, J., Sato, Y., Sato, H., Fujiwaki, S., Odanaka, M., & Nakada, K. (2004). The early effects of urinary tract obstruction on glomerulogenesis. *J Pediatr Surg*, 39(12), 1845-1848.

- Kitajima, K., Aoba, T., Pringle, K. C., Seki, Y., Zuccollo, J., Koike, J., Chikaraishi, T., & Kitagawa, H. (2010). Bladder development following bladder outlet obstruction in fetal lambs: optimal timing of fetal therapy. *J Pediatr Surg*, 45(12), 2423-2430.
- Klahr, S., & Morrissey, J. (2002). Obstructive nephropathy and renal fibrosis. *Am J Physiol Renal Physiol*, 283(5), F861-875.
- Kong, X. T., Deng, F. M., Hu, P., Liang, F. X., Zhou, G., Auerbach, A. B., Genieser, N., Nelson, P. K., Robbins, E. S., Shapiro, E., Kachar, B., & Sun, T. T. (2004). Roles of uroplakins in plaque formation, umbrella cell enlargement, and urinary tract diseases. *J Cell Biol*, 167(6), 1195-1204.
- Kousidis, G., Thomas, D. F., Morgan, H., Haider, N., Subramaniam, R., & Feather, S. (2008). The long-term outcome of prenatally detected posterior urethral valves: a 10 to 23-year follow-up study. *BJU Int*, 102(8), 1020-1024.
- McDill, B. W., Li, S. Z., Kovach, P. A., Ding, L., & Chen, F. (2006). Congenital progressive hydronephrosis (cph) is caused by an S256L mutation in aquaporin-2 that affects its phosphorylation and apical membrane accumulation. *Proc Natl Acad Sci U S A*, 103(18), 6952-6957.
- Mendelsohn, C. (2009). Using mouse models to understand normal and abnormal urogenital tract development. *Organogenesis*, 5(1), 306-314.
- Miller, J., Hesse, M., Diemer, T., Haenze, J., Knerr, I., Rascher, W., & Weidner, W. (2004). Congenital unilateral ureteropelvic junction obstruction of the rat: a useful animal model for human ureteropelvic junction obstruction? *Urology*, 63(1), 190-194.
- Miyazaki, Y., & Ichikawa, I. (2001). Role of the angiotensin receptor in the development of the mammalian kidney and urinary tract. *Comp Biochem Physiol A Mol Integr Physiol*, 128(1), 89-97.
- Miyazaki, Y., Oshima, K., Fogo, A., Hogan, B. L., & Ichikawa, I. (2000). Bone morphogenetic protein 4 regulates the budding site and elongation of the mouse ureter. *J Clin Invest*, 105(7), 863-873.
- Morita, K., Iwami, D., Hotta, K., Shimoda, N., Miura, M., Watarai, Y., Hoshii, S., Obikane, K., Nakashima, T., Sasaki, S., & Nonomura, K. (2009). Pediatric kidney transplantation is safe and available for patients with urological anomalies as well as those with primary renal diseases. *Pediatr Transplant*, 13(2), 200-205.
- Moritz, K. M., & Wintour, E. M. (1999). Functional development of the meso- and metanephros. *Pediatr Nephrol*, 13(2), 171-178.
- Morris, R. K., & Kilby, M. D. (2009). An overview of the literature on congenital lower urinary tract obstruction and introduction to the PLUTO trial: percutaneous shunting in lower urinary tract obstruction. *Aust N Z J Obstet Gynaecol*, 49(1), 6-10.
- Morris, R. K., Malin, G. L., Khan, K. S., & Kilby, M. D. (2009). Antenatal ultrasound to predict postnatal renal function in congenital lower urinary tract obstruction: systematic review of test accuracy. *BJOG*, 116(10), 1290-1299.
- Morris, R. K., Quinlan-Jones, E., Kilby, M. D., & Khan, K. S. (2007). Systematic review of accuracy of fetal urine analysis to predict poor postnatal renal function in cases of congenital urinary tract obstruction. *Prenat Diagn*, 27(10), 900-911.
- Mostwin, J. L., Karim, O. M., van Koeveringe, G., & Brooks, E. L. (1991). The guinea pig as a model of gradual urethral obstruction. *J Urol*, 145(4), 854-858.
- NAPRTCS. (2009). North American Pediatric Renal Transplant Cooperative Study (NAPRTCS) 2008 annual report. October 16, 2011, Available from <https://web.emmes.com/study/ped/annlrept/Archiveannlrept.html>

- Neild, G. H. (2009a). What do we know about chronic renal failure in young adults? I. Primary renal disease. *Pediatr Nephrol*, 24(10), 1913-1919.
- Neild, G. H. (2009b). What do we know about chronic renal failure in young adults? II. Adult outcome of pediatric renal disease. *Pediatr Nephrol*, 24(10), 1921-1928.
- Nickavar, A., Otoukesh, H., & Sotoudeh, K. (2008). Validation of initial serum creatinine as a predictive factor for development of end stage renal disease in posterior urethral valves. *Indian J Pediatr*, 75(7), 695-697.
- Nishimura, H., Yerkes, E., Hohenfellner, K., Miyazaki, Y., Ma, J., Hunley, T. E., Yoshida, H., Ichiki, T., Threadgill, D., Phillips, J. A., 3rd, Hogan, B. M., Fogo, A., Brock, J. W., 3rd, Inagami, T., & Ichikawa, I. (1999). Role of the angiotensin type 2 receptor gene in congenital anomalies of the kidney and urinary tract, CAKUT, of mice and men. *Mol Cell*, 3(1), 1-10.
- O'Connor, L. T., Jr., Vaughan, E. D., Jr., & Felsen, D. (1997). In vivo cystometric evaluation of progressive bladder outlet obstruction in rats. *J Urol*, 158(2), 631-635.
- Oliveira, E. A., Diniz, J. S., Cabral, A. C., Pereira, A. K., Leite, H. V., Colosimo, E. A., & Vilasboas, A. S. (2000). Predictive factors of fetal urethral obstruction: a multivariate analysis. *Fetal Diagn Ther*, 15(3), 180-186.
- Pagon, R. A., Smith, D. W., & Shepard, T. H. (1979). Urethral obstruction malformation complex: a cause of abdominal muscle deficiency and the "prune belly". *J Pediatr*, 94(6), 900-906.
- Parkhouse, H. F., Barratt, T. M., Dillon, M. J., Duffy, P. G., Fay, J., Ransley, P. G., Woodhouse, C. R., & Williams, D. I. (1988). Long-term outcome of boys with posterior urethral valves. *Br J Urol*, 62(1), 59-62.
- Pates, J. A., & Dashe, J. S. (2006). Prenatal diagnosis and management of hydronephrosis. *Early Hum Dev*, 82(1), 3-8.
- Payabvash, S., Kajbafzadeh, A. M., Tavangar, S. M., Monajemzadeh, M., & Sadeghi, Z. (2007). Myocyte apoptosis in primary obstructive megaureters: the role of decreased vascular and neural supply. *J Urol*, 178(1), 259-264; discussion 264.
- Pedersen, A., Skjong, C., & Shawlot, W. (2005). Lim 1 is required for nephric duct extension and ureteric bud morphogenesis. *Dev Biol*, 288(2), 571-581.
- Pohl, H. G., Joyce, G. F., Wise, M., & Cilento, B. G., Jr. (2007). Vesicoureteral reflux and ureteroceles. *J Urol*, 177(5), 1659-1666.
- Potter, E. L. (1972). *Normal and abnormal development of the kidney*. Chicago: Year Book Medical Publishers, Inc.
- Rawat, J., Khan, T. R., Singh, S., Maletha, M., & Kureel, S. (2009). Congenital anterior urethral valves and diverticula: diagnosis and management in six cases. *Afr J Paediatr Surg*, 6(2), 102-105.
- Reinberg, Y., Chelimsky, G., & Gonzalez, R. (1993). Urethral atresia and the prune belly syndrome. Report of 6 cases. *Br J Urol*, 72(1), 112-114.
- Reinberg, Y., de Castano, I., & Gonzalez, R. (1992). Prognosis for patients with prenatally diagnosed posterior urethral valves. *J Urol*, 148(1), 125-126.
- Reinberg, Y., Shapiro, E., Manivel, J. C., Manley, C. B., Pettinato, G., & Gonzalez, R. (1991). Prune belly syndrome in females: a triad of abdominal musculature deficiency and anomalies of the urinary and genital systems. *J Pediatr*, 118(3), 395-398.
- Riccabona, M., Avni, F. E., Blickman, J. G., Dacher, J. N., Darge, K., Lobo, M. L., & Willi, U. (2008). Imaging recommendations in paediatric urology: minutes of the ESPR workgroup session on urinary tract infection, fetal hydronephrosis, urinary tract

- ultrasonography and voiding cystourethrography, Barcelona, Spain, June 2007. *Pediatr Radiol*, 38(2), 138-145.
- Riedmiller, H., Androulakakis, P., Beurton, D., Kocvara, R., & Gerharz, E. (2001). EAU guidelines on paediatric urology. *Eur Urol*, 40(5), 589-599.
- Robyr, R., Benachi, A., Daikha-Dahmane, F., Martinovich, J., Dumez, Y., & Ville, Y. (2005). Correlation between ultrasound and anatomical findings in fetuses with lower urinary tract obstruction in the first half of pregnancy. *Ultrasound Obstet Gynecol*, 25(5), 478-482.
- Roth, K. S., Carter, W. H., Jr., & Chan, J. C. (2001). Obstructive nephropathy in children: long-term progression after relief of posterior urethral valve. *Pediatrics*, 107(5), 1004-1010.
- Routh, J. C., Huang, L., Retik, A. B., & Nelson, C. P. (2010). Contemporary Epidemiology and Characterization of Newborn Males with Prune Belly Syndrome. *Urology*, 76(1), 44-48.
- Rulli, S. B., Ahtiainen, P., Makela, S., Toppari, J., Poutanen, M., & Huhtaniemi, I. (2003). Elevated steroidogenesis, defective reproductive organs, and infertility in transgenic male mice overexpressing human chorionic gonadotropin. *Endocrinology*, 144(11), 4980-4990.
- Sanna-Cherchi, S., Ravani, P., Corbani, V., Parodi, S., Haupt, R., Piaggio, G., Innocenti, M. L., Somenzi, D., Trivelli, A., Caridi, G., Izzi, C., Scolari, F., Mattioli, G., Allegri, L., & Ghiggeri, G. M. (2009). Renal outcome in patients with congenital anomalies of the kidney and urinary tract. *Kidney Int*, 76(5), 528-533.
- Sarhan, O., El-Dahshan, K., & Sarhan, M. (2010). Prognostic value of serum creatinine levels in children with posterior urethral valves treated by primary valve ablation. *J Pediatr Urol*, 6(1), 11-14.
- Sarhan, O., Zaccaria, I., Macher, M. A., Muller, F., Vuillard, E., Delezoide, A. L., Sebag, G., Oury, J. F., Aigrain, Y., & El-Ghoneimi, A. (2008). Long-term outcome of prenatally detected posterior urethral valves: single center study of 65 cases managed by primary valve ablation. *J Urol*, 179(1), 307-312.
- Seseke, F., Thelen, P., Hemmerlein, B., Kliese, D., Zoller, G., & Ringert, R. H. (2000). Histologic and molecular evidence of obstructive uropathy in rats with hereditary congenital hydronephrosis. *Urol Res*, 28(2), 104-109.
- Shokeir, A. A., & Nijman, R. J. (2000). Antenatal hydronephrosis: changing concepts in diagnosis and subsequent management. *BJU Int*, 85(8), 987-994.
- Singh, S., Robinson, M., Nahi, F., Coley, B., Robinson, M. L., Bates, C. M., Kornacker, K., & McHugh, K. M. (2007). Identification of a unique transgenic mouse line that develops megabladder, obstructive uropathy, and renal dysfunction. *J Am Soc Nephrol*, 18(2), 461-471.
- Sozubir, S., Lorenzo, A. J., Twickler, D. M., Baker, L. A., & Ewalt, D. H. (2003). Prenatal diagnosis of a prolapsed ureterocele with magnetic resonance imaging. *Urology*, 62(1), 144.
- Stanton, M. C., Clement, M., Macarak, E. J., Zderic, S. A., & Moreland, R. S. (2003). Partial bladder outlet obstruction alters Ca²⁺ sensitivity of force, but not of MLC phosphorylation, in bladder smooth muscle. *Am J Physiol Renal Physiol*, 285(4), F703-710.

- Steinhardt, G. F., Salinas-Madrigal, L., deMello, D., Farber, R., Phillips, B., & Vogler, G. (1994). Experimental ureteral obstruction in the fetal opossum: histologic assessment. *J Urol*, 152(6 Pt 1), 2133-2138.
- Strand, W. R. (2004). Initial management of complex pediatric disorders: prunebelly syndrome, posterior urethral valves. *Urol Clin North Am*, 31(3), 399-415, vii.
- Straub, E., & Spranger, J. (1981). Etiology and pathogenesis of the prune belly syndrome. *Kidney Int*, 20(6), 695-699.
- Thiruchelvam, N., Wu, C., David, A., Woolf, A. S., Cuckow, P. M., & Fry, C. H. (2003). Neurotransmission and viscoelasticity in the ovine fetal bladder after in utero bladder outflow obstruction. *Am J Physiol Regul Integr Comp Physiol*, 284(5), R1296-1305.
- Thompson, D. J., Molello, J. A., Strebing, R. J., & Dyke, I. L. (1978). Teratogenicity of adriamycin and daunomycin in the rat and rabbit. *Teratology*, 17(2), 151-157.
- Tsuchida, S., Matsusaka, T., Chen, X., Okubo, S., Niimura, F., Nishimura, H., Fogo, A., Utsunomiya, H., Inagami, T., & Ichikawa, I. (1998). Murine double nullizygotes of the angiotensin type 1A and 1B receptor genes duplicate severe abnormal phenotypes of angiotensinogen nullizygotes. *J Clin Invest*, 101(4), 755-760.
- University of Birmingham. (2011). PLUTO (Percutaneous shunting in Lower Urinary Tract Obstruction) trial home page. October 12, 2011, Available from <http://www.pluto.bham.ac.uk>
- van Gool, J. D., Dik, P., & de Jong, T. P. (2001). Bladder-sphincter dysfunction in myelomeningocele. *Eur J Pediatr*, 160(7), 414-420.
- Vidal, I., Heloury, Y., Ravasse, P., Lenormand, L., & Leclair, M. D. (2009). Severe bladder dysfunction revealed prenatally or during infancy. *J Pediatr Urol*, 5(1), 3-7.
- Warshaw, B. L., Hymes, L. C., Trulock, T. S., & Woodard, J. R. (1985). Prognostic features in infants with obstructive uropathy due to posterior urethral valves. *J Urol*, 133(2), 240-243.
- Weide, L. G., & Lacy, P. E. (1991). Hereditary hydronephrosis in C57BL/KsJ mice. *Lab Anim Sci*, 41(5), 415-418.
- Wiesel, A., Queisser-Luft, A., Clementi, M., Bianca, S., & Stoll, C. (2005). Prenatal detection of congenital renal malformations by fetal ultrasonographic examination: an analysis of 709,030 births in 12 European countries. *Eur J Med Genet*, 48(2), 131-144.
- Woodhouse, C. R., Ransley, P. G., & Innes-Williams, D. (1982). Prune belly syndrome--report of 47 cases. *Arch Dis Child*, 57(11), 856-859.
- Woodward, M., & Frank, D. (2002). Postnatal management of antenatal hydronephrosis. *BJU Int*, 89(2), 149-156.
- Woolf, A. S., & Thiruchelvam, N. (2001). Congenital obstructive uropathy: its origin and contribution to end-stage renal disease in children. *Adv Ren Replace Ther*, 8(3), 157-163.
- Yiee, J., & Wilcox, D. (2008). Management of fetal hydronephrosis. *Pediatr Nephrol*, 23(3), 347-353.
- Ylinen, E., Ala-Houhala, M., & Wikstrom, S. (2004). Prognostic factors of posterior urethral valves and the role of antenatal detection. *Pediatr Nephrol*, 19(8), 874-879.
- Yokoyama, H., Wada, T., Kobayashi, K., Kuno, K., Kurihara, H., Shindo, T., & Matsushima, K. (2002). A disintegrin and metalloproteinase with thrombospondin motifs (ADAMTS)-1 null mutant mice develop renal lesions mimicking obstructive nephropathy. *Nephrol Dial Transplant*, 17 Suppl 9, 39-41.
- Yoon, J. Y., Kim, J. C., Hwang, T. K., Yoon, M. S., & Park, Y. H. (1998). Collagen studies for pediatric ureteropelvic junction obstruction. *Urology*, 52(3), 494-497.



Novel Insights on Chronic Kidney Disease, Acute Kidney Injury and Polycystic Kidney Disease

Edited by Dr. Soundarapandian Vijayakumar

ISBN 978-953-51-0234-2

Hard cover, 134 pages

Publisher InTech

Published online 07, March, 2012

Published in print edition March, 2012

This book offers novel insights on topics such as congenital obstructive nephropathy, cerebral-renal salt wasting, and the role of hemoglobin variability in clinical outcomes of CKD which are not very often discussed in the literature. With comprehensive and insightful reviews by eminent clinicians and scientists in the field, this book is a valuable tool for nephrologists.

How to reference

In order to correctly reference this scholarly work, feel free to copy and paste the following:

Susan E. Ingraham and Kirk M. McHugh (2012). Congenital Obstructive Nephropathy: Clinical Perspectives and Animal Models, Novel Insights on Chronic Kidney Disease, Acute Kidney Injury and Polycystic Kidney Disease, Dr. Soundarapandian Vijayakumar (Ed.), ISBN: 978-953-51-0234-2, InTech, Available from: <http://www.intechopen.com/books/novel-insights-on-chronic-kidney-disease-acute-kidney-injury-and-polycystic-kidney-disease/congenital-obstructive-nephropathy-clinical-perspectives-and-animal-models>

INTECH
open science | open minds

InTech Europe

University Campus STeP Ri
Slavka Krautzeka 83/A
51000 Rijeka, Croatia
Phone: +385 (51) 770 447
Fax: +385 (51) 686 166
www.intechopen.com

InTech China

Unit 405, Office Block, Hotel Equatorial Shanghai
No.65, Yan An Road (West), Shanghai, 200040, China
中国上海市延安西路65号上海国际贵都大饭店办公楼405单元
Phone: +86-21-62489820
Fax: +86-21-62489821

© 2012 The Author(s). Licensee IntechOpen. This is an open access article distributed under the terms of the [Creative Commons Attribution 3.0 License](#), which permits unrestricted use, distribution, and reproduction in any medium, provided the original work is properly cited.

IntechOpen

IntechOpen