We are IntechOpen, the world's leading publisher of Open Access books Built by scientists, for scientists

7,000
Open access books available

186,000
International authors and editors

200M
Downloads

Our authors are among the

154
Countries delivered to

TOP 1%
most cited scientists

12.2%
Contributors from top 500 universities

WEB OF SCIENCE™

Selection of our books indexed in the Book Citation Index in Web of Science™ Core Collection (BKCI)

Interested in publishing with us?
Contact book.department@intechopen.com

Numbers displayed above are based on latest data collected.
For more information visit www.intechopen.com

5

Inflammation and Pulmonary Fibrosis

Michael G. Crooks, Imran Aslam and Simon P. Hart
Hull York Medical School and Hull and East Yorkshire Hospitals NHS Trust, United Kingdom

1. Introduction

The development of pulmonary fibrosis is the end point of a wide range of respiratory diseases including organic and inorganic dust exposure, pulmonary infection, acute lung injury, radiation, the idiopathic interstitial pneumonias (IIP), and connective tissue diseases. The most common fibrotic lung disorder is idiopathic pulmonary fibrosis (IPF), an IIP with the histological appearance of usual interstitial pneumonia (UIP). Formerly also known as cryptogenic fibrosing alveolitis (CFA), the definition of this disease has evolved in recent years to exclude fibrotic non-specific interstitial pneumonia (NSIP), a histological sub-type of IIP with more diffuse interstitial pulmonary fibrosis, a different clinical course and better prognosis than IPF. This change in definition must be considered when looking at historical studies that grouped UIP and NSIP under the same umbrella term.

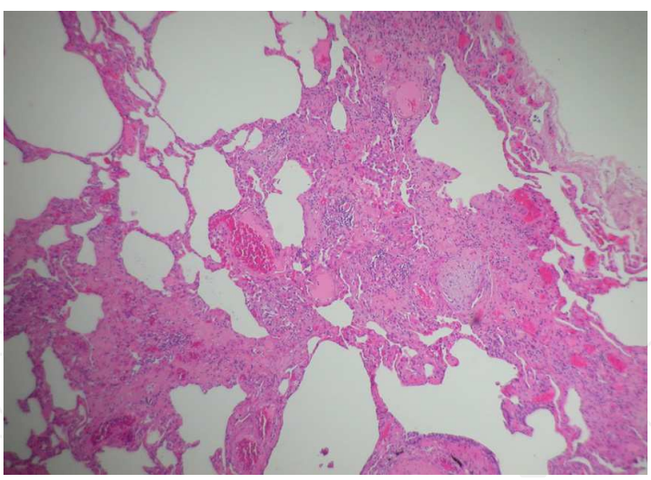

Fig. 1. Usual Interstitial Pneumonia (UIP) on Lung Biopsy, demonstrating patchy remodeling of lung architecture by fibrosis, fibroblastic foci, and a chronic inflammatory cell infiltrate interspersed with areas of normal lung (upper left).

IPF carries a prognosis worse than many cancers with mean disease duration of 2.8 years from diagnosis to death (Bjoraker et al., 1998). It typically presents with gradually progressive shortness of breath with clinical signs including finger clubbing and fine inspiratory crackles at both lung bases on auscultation. This devastating interstitial lung disease leads to irreversible impairment of lung function with a restrictive defect on spirometry and reduced gas transfer causing debilitating symptoms of shortness of breath

and cough, progressing to respiratory failure and ultimately death. The diagnosis is multidisciplinary and is based on correlation of clinical and high resolution computed tomography (HRCT) findings with lung biopsy being required only when the clinico-radiological diagnosis is unclear. However, despite advances in recent years the pathogenesis of IPF remains poorly understood with no established disease modifying treatment.

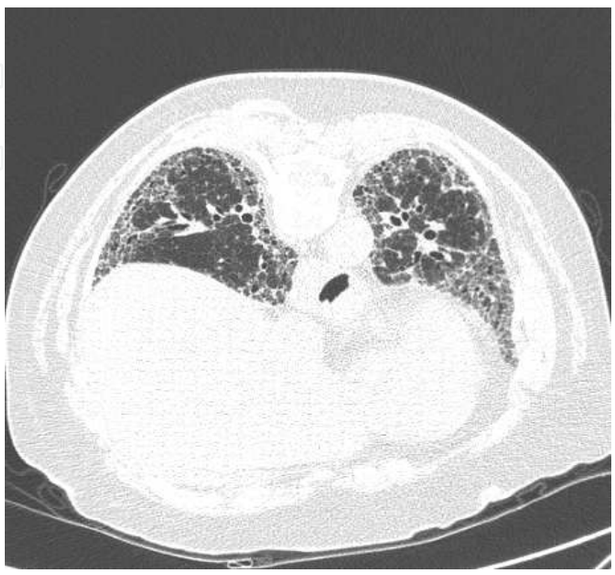

Fig. 2. Thoracic HRCT slice from a patient with IPF demonstrating bilateral peripheral and basal fibrosis, with honeycomb cysts and traction bronchiectasis.

Early studies of IPF led to the classic hypothesis that chronic inflammation preceded the development of fibrosis providing a window of opportunity for management with immunosuppressant therapies (Crystal et al., 1976); however, this has been called into question due to treatment regimens consisting of corticosteroids and other immunosuppressants proving largely ineffective in altering natural disease progression and subsequent mortality (Douglas et al., 2000). This has led to the development of a new hypothesis focusing on the role of epithelial and/or endothelial injury and subsequent aberrant wound healing/tissue repair independent of preceding inflammation (Strieter & Mehrad, 2009). This modern hypothesis suggests that initial lung injury leads to loss of the integrity of the alveolar-capillary basement membrane, failure of re-epithelialisation and re-endothelialisation, and subsequent cytokine mediated fibroblast proliferation, activation and differentiation into myofibroblasts with associated collagen deposition (Strieter & Mehrad, 2009). Additionally, the origin of the fibroblast in IPF has been the subject of recent research with the discovery of epithelial-mesenchymal transformation (EMT) (Chilosi et al., 2003) and bone marrow progenitor cells (fibrocytes) that migrate to the lung prior to differentiation into fibroblasts (Bucala et al., 1994).

However, there remains debate whether this shift in hypothesis based on a lack of inflammation in the histological appearance of UIP and poor response to immunosuppressants results in the role of inflammation being unfairly dismissed. Despite IPF appearing to be rapidly progressive with early death it is important to consider that there may be a long asymptomatic stage of disease that goes unrecognized prior to clinical diagnosis. The majority of our understanding of IPF is based on animal models in which the aetiology is known or

in symptomatic patients who have UIP on lung biopsy. It is important to consider that this only represents a "snap shot" of the disease in time and therefore fails to address the natural progression of the disease from pre-symptomatic to end stage fibrosis and death. The pre-symptomatic stage in which inflammation may play a central role is therefore neglected.

Indeed, it has been suggested that NSIP in which ground-glass opacification (a radiological appearance suggested to correlate with inflammation) on HRCT is a prominent feature and inflammation is noted on biopsy is not a distinct entity but represents a different time period in the natural course of the disease with progression to UIP if left untreated. This is supported by the coexistence of UIP and NSIP in biopsies from different lobes of 26% of patients with IIP in a prospective study of histological variability in surgical lung biopsies form multiple lobes (Flaherty et al., 2001). NSIP is believed to be more steroid responsive and have a better prognosis than UIP and it could be argued that this is because NSIP represents an earlier stage in the same disease process where inflammation has a role.

Additionally, dismissing the role of inflammation based on poor response to steroids fails to recognize the possible deleterious effects that steroids can have on pulmonary epithelium including reduced alveolar cell proliferation and increased apoptosis potentially negating any benefit through reducing inflammation (Piguet, 2003). Indeed treatment with steroids has been demonstrated to worsen lung injury caused by hyperoxia (Barazzone-Argiroffo et al., 2001).

It is therefore clear that the pathogenesis of IPF is incompletely understood and the role of inflammation not fully established. This chapter will discuss the role of inflammation in IPF exploring: inflammation in animal and human models of pulmonary fibrosis, the genetics of inflammation in IPF, markers of inflammation in IPF, the immunology of pulmonary fibrosis, pulmonary fibrosis and connective tissue disease, IPF and malignancy, and the role of inflammation in fibrosis in other organ systems.

2. Models of inflammation and fibrosis

Inflammation is classically followed by repair, during which injured tissue is replaced by a combination of regeneration of native cells and fibrosis (filling of the tissue defect with scar tissue). In animal models of wound healing following tissue injury, the initial acute inflammatory response is followed within 24-48h with initiation of healing. The healing process is characterised by formation of granulation tissue in which macrophages persist and there is proliferation of vascular endothelial cells and fibroblasts. Macrophages are key cells linking inflammation with repair and fibrosis, mediated by release of growth factors including epidermal growth factor (EGF), platelet-derived growth factor (PDGF), fibroblast growth factor (FGF), and transforming growth factor-beta (TGF-β). Some fibroblasts bear the hallmarks of activated, collagen-producing, contractile myofibroblasts. As healing progresses there is an increase in extracellular collagen and reduced numbers of inflammatory cells, regeneration of parenchymal cells, cell migration and proliferation, synthesis of matrix proteins, and matrix remodelling.

A number of animal models of pulmonary fibrosis have been developed aiming to look at the mechanisms of fibrotic responses. These models have individually identified several key mediators, cells and processes involved in human fibrosis. A summary of a selection of inflammatory mediators implicated in animal models of pulmonary fibrosis and the resulting investigation in human disease are presented in Table 1. Moeller et al and more recently Moore et al have summarised the various advantages and disadvantages of murine models of pulmonary fibrosis (Moeller et al., 2006;Moore & Hogaboam, 2008).

www.intechopen.com

Paper	Model (Species)	Mediator	Summary of Findings
Piguet et al., 1993	Bleomycin (Mouse)	IL-1	Reduced collagen deposition measure content on day 15 with IL-1 receptor a
Saito et al., 2008	Bleomycin (B6.129S2-*Il6*^{tm1Kopf}/J Mice)	IL-6	IL-6 deficient mice demonstrated redu measured by Sircol assay 21 days follo bleomycin compared with wild-type l
Nakatani-Okuda et al., 2005	Bleomycin (C57BL/6 Mice)	IL-18	Pre-treatment with intraperitoneal IL- content on day 21 following intratrach
Keane et al., 2001	Bleomycin (CBA/J Mice)	Interferon gamma (IFN-γ)	IL-12 administered days 1-12 post intr resulted in reduced collagen depositio hydroxyproline content on day 12 ass IFN-γ levels. IFN-γ blockade reversed
King et al., 2009	IPF (Humans)	Interferon gamma-1b (IFN-γ1b)	Large randomised placebo controlled IFN-γ1b in IPF. Trial stopped early du benefit.
Piguet & Vesin, 1994	Bleomycin & silica (C57Bl/10 and CBA/Ca Mice)	TNF-α	Administration of the TNF-α antagoni TNFR-β on days 25-32 in the bleomyci group resulted in significant reduction measured by hydroxyprolline content
Raghu et al., 2008	IPF (Humans)	TNF-α	Randomised, double-blind placebo co in IPF. There was no significant differe endpoints including rate of lung funct
Jakubzick et al., 2003	Bleomycin (CBA/J Mice)	IL-4 and IL-13	Intranasal administration of IL-13 Pse (IL-13 PE) between days 21 and 28 foll bleomycin reduced IL-4 and IL-13 resp fibrosis assessed by histological scores measured by hydroxyproline content.
Keane et al., 1999	Bleomycin (CBA/J Mice)	Macrophage Inflammatory Protein-2 (MIP-2)	Reduced collagen deposition measure content on day 20 following intratrach blocking antibodies

Table 1. Inflammatory mediators implicated in pulmonary fibrosis in animal models, and human cl blockade.

IntechOpen

2.1 Bleomycin

Bleomycin induced lung fibrosis in mice is the most widely used animal model as it is well characterized, highly reproducible and easily accessible. Bleomycin is an antineoplastic antibiotic derived from *Streptomyces verticillatus* (Turner-Warwick & Doniach, 1965). It induces lung injury by causing DNA strand breakage (Lown & Sim, 1977) and can be administered by intraperitoneal, intravenous, subcutaneous or intratracheal routes. The fibrotic response depends on the route of administration, the dose and the strain of mice. Following intravenous administration of bleomycin the initial lesion appears in the pulmonary endothelium followed subsequently by epithelial damage (Adamson, 1976). The pathological response to this injury is in the form of damage to the alveolar epithelium, leakage of fluid and plasma proteins into the alveolar space, alveolar consolidation and the formation of hyaline membranes. In response to this injury there is focal necrosis of type I alveolar epithelial cells (pneumocytes) and metaplasia of type II alveolar epithelial cells with fibrosis developing in sub-pleural regions (Muggia et al., 1983). The advantage of intravenous administration of the drug is that it closely mimics the way humans are exposed to the drug regimen. The disadvantage of this model is that fibrosis does not develop in all animals and takes a longer period of time for the development of fibrosis. It is therefore not widely used.

Intratracheal administration of bleomycin is by far the most commonly used model. A single dose of bleomycin when given via the intratracheal route produces lung injury and subsequent fibrosis (Phan et al., 1980;Snider et al., 1978;Thrall et al., 1979). The initial damage is to the alveolar epithelium followed by development of a neutrophilic and lymphocytic pan-alveolitis within the first week. The disadvantage of this model is that the fibrosis is patchy (depending on lung deposition of the instillate) and self-resolving beyond a certain period.

While the development of fibrosis in response to bleomycin is T-cell independent (Helene et al., 1999;Szapiel et al., 1979), the development of fibrotic lesions is dependent on the release of chemokines (CCL2 or CCL12) and the recruitment of inflammatory cells including neutrophils, monocytes, and lymphocytes (Baran et al., 2007;Inoshima et al., 2004;Moore et al., 2001;Moore et al., 2006;Smith et al., 1995;Zhang et al., 1994). Pro-fibrotic cytokines (e.g. TGF-β), leukotrienes, and coagulation factors have also been implicated. Other mechanisms including altered epithelial-mesenchymal interactions, circulating mesenchymal precursors, epithelial mesenchymal transformation and their regulation by inflammatory mediators have recently been reviewed (Keane et al., 2005).

2.2 Fluorescein isothiocyanate (FITC)

The FITC induced pulmonary fibrosis model was originally described by Roberts et al. (Roberts et al., 1995) and further characterized by Christensen et al. (Christensen et al., 1999). Intratracheal instillation of FITC resulted in marked infiltration of mononuclear cells and neutrophils around respiratory bronchioles with focal evidence of oedema and alveolar epithelial cell hyperplasia. These findings suggest acute lung injury. Patchy focal areas of interstitial fibrosis were noted five months post FITC instillation. Presence of anti-FITC antibodies in treated mice indicated an immune response that may be important to the development of the disease. Christensen demonstrated that like bleomycin-induced fibrosis, the FITC model is T-cell independent. Recent investigations have implicated CCR2 signaling (Moore et al., 2001) and production of IL-13 in the fibrotic response to FITC (Korfhagen et al., 1994).

The two advantages of the FITC model are: firstly, the areas where FITC has been deposited leading to fibrosis can be visualized using immunofluorescence imaging; and secondly, the fibrotic response to FITC seems to be persistent for at least 6 months and not self-limiting like the bleomycin model (Fisher et al., 2005), making it more suitable for long term studies.

2.3 Radiation induced fibrosis

Pulmonary fibrotic response to irradiation in mice depends on the dose of radiation and the genetic background of the mice. A single dose of 12-15 Gy of total body radiation can induce lung fibrosis as early as 20 weeks post exposure (McDonald et al., 1993). Several studies have lead to the hypothesis that chronic mononuclear cell recruitment and activation may be the key feature in radiation induced lung fibrosis (Johnston et al., 2002). Other factors implicated are TGF-β, tumour necrosis factor-alpha (TNF-α), bone marrow derived cells including macrophages, and fibroblasts (Chiang et al., 2005;Epperly et al., 2003;Rube et al., 2000).

2.4 Silica

Silica can be delivered to mice via aerosolization, intratracheal administration or via oropharyngeal aspiration. This leads to the development of fibrotic nodules that are similar to the lesions humans develop secondary to occupational dust exposure. The development of fibrosis in mice secondary to silica exposure is strain dependent and the fibrotic response is different in mice and rats (Barbarin et al., 2005). In rats exposure to silica induces a chronic and progressive inflammation that is accompanied by the over production of TNF-α. Anti-inflammatory therapies are effective in blocking the fibrotic effect of silica in rats. Conversely, in mice there is very limited and transient inflammation with over expression of the anti-inflammatory cytokine IL-10. Hence, in this model anti-inflammatory therapy is ineffective.

The advantage of the silica model is that the fibrotic response is persistent and the fibrosis is easily identified in fibrotic nodules. The disadvantage is that it can take up to 60 days for the development of fibrosis.

2.5 Transgenic models of pulmonary fibrosis

Another animal model for investigating pulmonary fibrosis is the transgenic modulation of tissue specific over expression of cytokines and growth factors leading to activation of specific cytokine pathways. The most widely used inducible transgenic system for the lung is based on the tetracycline-controlled transcriptional regulator controlling pneumocyte-specific gene promoter sequences (Lee et al., 2004;Zhu et al., 2002). Transient transgenic models using adenoviral vector-mediated cytokine gene transfer to bronchial, bronchiolar and alveolar epithelium have been successfully developed and can be applied to all ages of rodents.

Although a variety of factors including TNF-α, connective tissue growth factor (CTGF), PDGF, endothelin, IL-6, granulocyte-macrophage colony stimulating factor (GM-CSF), IL-1b, IL-10 and IL-13 are thought to play a pivotal role in the pathogenesis of pulmonary fibrosis (Ask et al., 2006;Gauldie et al., 2002), transgenic models have shown TGF-β to be a major cytokine associated with development of pulmonary fibrosis (Sime et al., 1997). TGF-β

is produced by a variety of cell types including platelets, macrophages, lymphocytes, epithelial cells, endothelial cells and fibroblasts. TGF-β1 is implicated in progressive fibrosis and regulates other cytokines including EGF, FGF, PDGF, TNF-α and IL-1.

2.6 Conclusion

Animal models have provided valuable insight into the mechanisms of fibrogenesis facilitating human research in this area and identifying potential therapeutic targets. However, none of the described animal models truly mimics human disease and therefore conclusions must be drawn with care.

3. Genetics of inflammation and IPF

Case-control association studies have suggested important links between genes involved in inflammation and risk of developing IPF and/or disease severity. In these studies the prevalence of a particular genetic variant (single nucleotide polymorphism, SNP) is compared between a group of patients with IPF and a group of controls. Case control studies such as these are relatively straightforward to perform compared with other genetic research strategies such as family linkage analysis or genome wide association studies. It must be recognized however that a genetic association demonstrated in a case control study does not imply a causative role for that particular gene, and confirmation of association should be made using unrelated patient populations.

Genes encoding the IL-1α (IL1A), IL-1β (IL1B) and the IL-1 receptor antagonist (IL1RN) are localized on chromosome 2q14. Carriage of the rarer IL1RN allele +2018C>T was associated with increased risk of developing IPF in two cohorts in one study (Whyte et al., 2000), but these results were not confirmed in other cohorts (Hutyrova et al., 2002). Polymorphisms in IL1A and IL1B do not seem to be associated with risk of developing IPF (Hutyrova et al., 2002), but there may be associations between -889T IL1A and IPF severity (du Bois, 2002). In two small European studies polymorphisms of various cytokine genes including IL-1α, IL-1RA, IL-4, IL-4RA, and IL-12 were associated with IPF severity, but not risk of developing disease (Vasakova et al., 2007b;Vasakova et al., 2007a).

Type II pneumocytes in lung tissue from patients with IPF express increased levels of TNF-α (Nash et al., 1993;Pan et al., 1996;Piguet, 1990). In three Caucasian populations there was an association between the TNF-α -308A allele and risk of IPF (Riha et al., 2004;Whyte et al., 2000), although this was not confirmed in a fourth population (Pantelidis et al., 2001). No associations were demonstrated for other TNF-α polymorphisms, or polymorphisms in the genes encoding TNF-α receptor II or lymphotoxin-α (Renzoni et al., 2000). IL6 intron 4 A>G polymorphism was associated with severity of IPF, and co-carriage of TNFRII 1690C was associated with disease risk (Pantelidis et al., 2001). No association with IPF could be demonstrated with polymorphisms in genes encoding the anti-inflammatory cytokine IL-10 (Whittington et al., 2003), the neutrophil chemoattractant IL-8 (Renzoni et al., 2000), IL12B, or IFN-γ (Latsi et al., 2003).

A significantly increased prevalence of MHC class I chain-related gene A(MICA)*001 and MICA*001/*00201 genotype was seen in Mexican patients with IPF compared with the healthy controls (Aquino-Galvez et al., 2009). A polymorphism in the complement receptor 1 (CR1) gene has been reported to be associated with low erythrocyte expression of CR1, which theoretically may lead to impaired clearance of immune complexes. In an Italian

cohort a strong (OR6.2) association was reported between the CR1 C5507G allele and IPF (Zorzetto et al., 2003), but in three subsequent Caucasian cohorts there were no significant differences in distribution of CR1 C5507G variants between IPF patients and control groups (Hodgson et al., 2005;Kubistova et al., 2008).

Immune complexes have been detected in blood and lung tissue of patients with IPF, and a role in pathogenesis is supported by the association of lung fibrosis with connective tissue diseases. Furthermore, pulmonary fibrosis in animal models can be induced by administration of immune complexes. Recently, Bournazos and colleagues have demonstrated that polymorphisms in the low affinity IgG receptors FcγRIIA and FcγRIIIB are associated with IPF. FCR3B copy number and carriage of the NA1 polymorphism were associated with increased risk of IPF (Bournazos et al., 2010;Bournazos et al., 2011), and the H allele of FcγRIIA (R131H) was associated with more severe disease at presentation and with progressive disease (Bournazos et al., 2010). In combination, these finding support an immunological/inflammatory hypothesis for IPF pathogenesis.

4. Immunology of IPF

4.1 Autoantibodies

The role of auto-antibodies in IPF has been investigated with variable results. A case control study by Magro et al. identified patients with either UIP or NSIP on lung biopsy and observed evidence of microvascular injury in all samples with variable deposition of IgG, IgM and IgA. Antiphospholipid antibodies were present in 37 of the 40 patients studied with elevated factor VIII, a marker of endothelial cell activation, and C-reactive protein (CRP), a marker of inflammation (Magro et al., 2006). Two similar studies by Matsui et al. and Kakugawa et al. included 20 patients and 38 patients with IIP respectively and failed to demonstrate anti-endothelial antibodies in patients with UIP but did demonstrate them in patients with NSIP (Kakugawa et al., 2008;Matsui et al., 2008). Earlier studies have also demonstrated a range of non-organ specific autoantibodies in patients with cryptogenic fibrosing alveolitis prior to the distinction between the subtypes of IIP (Chapman et al., 1984; Dobashi et al., 2000b; Meliconi et al., 1989; Turner-Warwick & Doniach, 1965).

A study of antibodies against type II pneumocytes and Clara cells failed to demonstrate any difference between patients with IPF, pulmonary fibrosis secondary to connective tissue disease and healthy controls (Erlinger et al., 1991). However, this study only included 10 patients with IPF with 93 patients in the other groups.

Autoantibodies against native collagen have been demonstrated in 13 of 16 IPF patients studied with an inverse correlation between disease duration and antibody level (Nakos et al., 1993). This was significantly greater than the control arm of healthy age and sex matched controls and patients with fibrotic change following TB infection. The authors of this study concluded that measurement of anti-collagen antibodies could be used as a marker of disease activity, but cautioned that the role of autoantibodies in the pathogenesis of IPF remains unclear and may occur as a secondary event.

The relatively small number of patients included in these studies and variable distinction between subtypes of IIP makes it difficult to draw firm conclusions however the role of autoantibodies in IPF warrants further investigation.

4.2 Immune complexes and IPF

Immune complexes have been described in the blood and lung tissue of patients with pulmonary fibrosis. However, their significance in IPF remains unclear. Historical studies

have described the presence of immune complexes in patients with idiopathic interstitial pneumonias using complement-binding assays (Dreisin et al., 1978;Haslam et al., 1979). However, these studies may not be directly applicable to IPF since both studies predated the modern classification of IIP and included patients with connective tissue disease. Indeed, increased levels of immune complexes were observed in patients with connective tissue disease and in patients with cellular pulmonary fibrosis on biopsy but not in those with advanced interstitial fibrosis with low cellularity.

More recently, circulating cytokeratin 8:anti-cytokeritin 8 immune complexes have been demonstrated in patients with IPF (confirmed on open lung biopsy) and in pulmonary fibrosis in patients with known connective tissue disease (Dobashi et al., 2000b). Cytokeratin 8 demonstrates increased expression in bronchiolar epithelial cells in IPF compared to normal lung (Iyonaga et al., 1997) and it is suggested may be released following injury resulting in immune complex deposition perpetuating lung injury (Dobashi et al., 2000b). A similar study by the same authors also demonstrated cytokeratin 18 immune complexes in IPF (Dobashi et al., 2000a). However, the role of immune complexes remains unclear and their significance in the pathogenesis of the IPF has not been explored.

4.3 Immunoglobulins and IPF

It has long been recognized that IPF is associated with raised serum concentrations of IgG, IgA, or IgM, reflecting polyclonal hypergammaglobulinaemia due to non-specific B-cell activation (DeRemee et al., 1972). This pattern of hypergammaglobulinaemia is similar to that described in chronic infectious diseases and in autoimmune disease, particularly SLE and Sjogren's syndrome (Ehrenstein & Isenberg, 1992). The mechanisms underlying polyclonal B cell activation in IPF have not been studied. However, in infectious disease, postulated mechanisms include B cell stimulation by microbial molecules such as lipopolysaccharide (LPS) and increased responsiveness of B cells to stimulation by cytokines including IL-4 and IL-5 (Alarcon-Riquelme et al., 1991). Microbial polyclonal B cell stimulators produced by various viruses, bacteria, and parasites induce proliferation of multiple B cell clones and up-regulate surface molecules major histocompatibility complex (MHC) class II, CD69, CD25, CD80, and CD86 (Montes et al., 2007). The antibodies produced by indiscriminately activated B cells may recognize heterologous or homologous antigens, the latter including actin, myosin, and DNA (Montes et al., 2007). Microbial polyclonal B cell stimulators are typically molecular components of the cell wall, cytosol, or secretion products. Some examples derived from *Trypanosoma cruzi* include mitochondrial malate dehydrogenase, glutamate dehydrogenase, proline racemase, and trans-sialidase (Montes et al., 2007). Several other polyclonal B call stimulating proteins from *Schistosoma japonicum*, *Leishmania major*, and *Plasmodium falciparum* have been well characterized. Furthermore, the IgG-binding staphylococcal protein A has the potential to bind surface Ig and activate multiple B cell clones (Anderson et al., 2006). Non-protein B cell activators include LPS derived from Gram-negative bacteria. Viral envelope glycoproteins and viral DNA or CpG-containing oligodeoxynucleotides (OXD) may also stimulate proliferation of naïve B cells (Montes et al., 2007). Whilst the precise molecular pathways have not been described for many of these molecules, the TLR-mediated mechanisms underlying LPS- and CpG-OXD have been extensively described, involving ligation of host cell surface CD14/TLR4 and TLR9 respectively. This mechanism applies to B cells directly, but may also involve indirect

involvement of TLR-bearing macrophages and dendritic cells which respond by secreting IL-1, IL-6, and IL-15 (Kacani et al., 1999;Riva et al., 1996). Indeed, B cell responses were diminished in IL-6 deficient mice (Karupiah et al., 1998). None of the mechanisms described above require involvement of T lymphocytes, but some examples requiring T cell help have been described. For example, polyclonal B cell activation induced by murine gamma herpes virus 68 infection is dependent on CD4 T cells in vivo (Stevenson & Doherty, 1999). In addition, γδ T cells may play a role in the polyclonal B cells activation seen in parasitic infections.

In many infections characterized by polyclonal B cell activation, expansion of CD5+ B-1 cells and marginal zone B cells is a notable feature and these populations are considered the principal sources of natural antibodies (Montes et al., 2007). The biological significance of polyclonal B cell activation in infectious and autoimmune disease remains uncertain, despite the fact that this phenomenon has been relatively well-studied in these conditions. In pulmonary fibrosis, polyclonal hypergammaglobulinaemia is a notable feature in many patients, but like many biomarkers we can only postulate whether it represents cause or consequence of the fibrotic process in the lung. In favour of a causative role is the established strong association of pulmonary fibrosis with systemic autoimmune disease, particularly rheumatoid arthritis and systemic sclerosis, but also including systemic lupus erythematosis (SLE), Sjogren's syndrome, and polymyositis. Precisely how polyclonal B cell activation and hypergammaglobulinaemia could predispose to pulmonary fibrosis remains to be determined.

Antigen presentation to B lymphocytes usually occurs in lymph nodes, but development of organized lymphoid structures elsewhere may occur in infective and autoimmune disorders. Antigen is presented by follicular dendritic cells in association with CD57+ follicle centre Th cells. Immature B lymphocytes are stimulated to proliferate, become activated, and undergo somatic mutation of their Ig genes. Following affinity maturation the surviving antigen-specific B cells differentiate into antibody-producing plasma cells or become memory cells (Heinen & Tsunoda, 1987). Formation of ectopic lymphoid tissue, described as lymphoid follicles is tissues other than lymph nodes or spleen, is a feature of certain chronic inflammatory diseases secondary to infection, autoimmunity, or neoplasia (Hjelmstrom, 2001). Early immunohistochemistry studies of lung tissue from patients with fibrosing alveolitis demonstrated chronic inflammatory infiltrates in the lung interstitium, composed predominantly of lymphocytes and macrophages (Campbell et al., 1985). In many patients this chronic inflammatory infiltrate included organized aggregates of B cells, and it was suggested that this was evidence of a local humoral immune reaction (Emura et al., 1990;Wallace et al., 1996). A more detailed analysis revealed discrete lymphocyte aggregates in 37 of 38 consecutive lung biopsies from IPF patients, with germinal centre formation in 5/38 (13%) (Wallace et al., 1996). Lymphoid aggregates were identified as separate from areas of severe established fibrosis and honeycomb cysts, and there was no evidence of associated focal infection to account for them. Immunohistochemistry demonstrated CD20+ B cells and CD21+, CD23+, S100- follicular dendritic cells. The B lymphocytes expressed markers of proliferation (MIB-1+) and activation (CD23+). Ten to 20 percent of the lymphocytes were CD3+ CD45RO+ memory type T lymphocytes, with some evidence of specialized follicle centre development (Wallace et al., 1996). A subsequent study confirmed that these lymph node-like structures in IPF lung were composed of activated B cells, CD40L+ activated T cells,

mature DCs and a network of FDCs (Marchal-Somme et al., 2006). The lymphocytes had features of non-proliferating antigen-experienced activated T and B cells, including follicular dendritic cells. Interestingly, anti-inflammatory drugs, which are considered generally ineffective in IPF, have little effect on mature differentiated lymphocytes (Matyszak et al., 2000). This mucosa-associated lymphoid tissue (MALT)-like tissue in IPF lung may reflect a humoral immune reaction in the lung parenchyma which may be a component of the pathogenesis of IPF.

5. Pulmonary fibrosis and connective tissue disease

Connective tissue diseases (CTD) are a group of immunologically mediated inflammatory disorders in which pulmonary involvement is strongly associated. This may be in the form of interstitial lung disease (ILD), pulmonary vascular disease, bronchiolitis, and other airspace abnormalities. These pulmonary manifestations may result from specific manifestations of the immune process, but also infection or drug toxicity (Eisenberg, 1982;Hunninghake & Fauci, 1979). In this section of the chapter we will concentrate on ILD in CTD. Rheumatoid arthritis (RA), scleroderma and dermatomyositis will be discussed in detail. ILD has also been reported in association with SLE, Sjogren's syndrome and mixed connective tissue disease (MCTD).

5.1 Rheumatoid arthritis (RA)

Ellmann and Ball (Ellman & Ball, 1948) described ILD as the predominant pulmonary manifestation of RA. Arthritis precedes the development of ILD in 90% of affected patients with mean age of onset of lung disease in the 5th or 6th decade. Significant risk factors for developing lung disease in RA include presence of subcutaneous nodules, high titres of circulating rheumatoid factor or antinuclear antibodies (Gordon et al., 1973) and genetic factors, for example, the presence of non-MM alpha 1- antitrypsin phenotypes. (Geddes et al., 1977;Michalski et al., 1986) Common symptoms include exertional dyspnoea and non-productive cough. Clinical examination reveals bibasal pulmonary crackles in most patients. Finger clubbing is uncommon.

Histologically RA-related ILD is indistinguishable from other fibrotic IIPs including IPF. A wide spectrum of elementary lesions found in a series of 40 patients led to the determination in each patient of a predominant or primary pattern (Yousem et al., 1985). UIP was the most frequent lesion followed by lymphoid hyperplasia, cellular interstitial pneumonia, desquamative interstitial pneumonia and proliferative bronchiolitis and patchy organizing pneumonia.

Early histological studies demonstrated the presence of immune complexes in the alveolar walls with the potential to activate inflammatory cells and alveolar macrophages. Activation of polymorphonuclear cells in the lung has been demonstrated by the increased release of myeloperoxidase , collagenase and elastase (Garcia et al., 1987;Weiland et al., 1987). Gilligan et al demonstrated that patients with overt ILD had a greater concentration of pro-collagen peptide and collagenase activity in BAL fluid than those with early lung disease (Gilligan et al., 1990). Balbi et al demonstrated a preferential increase in Tec T-5,9+T cells, a subset of CD4 lymphocytes responsible for many helper T-cell functions including the response to allogenic antigens (Balbi et al., 1987). Such expansion might reflect increased T-cell-dependent stimulation of B cells to produce immunoglobulins in the lungs of RA patients.

5.2 Scleroderma

Interstitial lung disease (ILD) is the most common pulmonary complication in scleroderma. ILD may occur in either limited or diffuse cutaneous scleroderma with up to 70–80% of patients exhibiting pulmonary fibrosis at autopsy (Sime et al., 1997;Steen et al., 1985;Weaver et al., 1968). Exertional dyspnoea and non-productive cough are the common symptoms and bi-basal fine crackles are heard on chest auscultation.

Retrospective studies of lung biopsies in patients with scleroderma-ILD suggest that the pathological pattern of lung involvement is more frequently that of non-specific interstitial pneumonia (NSIP) than of usual interstitial pneumonia (UIP) (Bouros et al., 2002). The pathogenesis of scleroderma lung disease is poorly understood. Early changes may include interstitial oedema and widening and inflammation of the alveolar walls with collections of mononuclear cells and neutrophils, leading to a combination of an inflammatory reaction and concommittant fibroblast proliferation (Harrison et al., 1989;Harrison et al., 1991). Tiny cysts result from progressive thinning and rupture of the alveolar walls associated with extensive interstitial and peri-bronchial fibrosis (Hayman & Hunt, 1952).

Early in the course of scleroderma, activated fibroblasts expressing high levels of type I and type III collagen messenger ribonucleic acid (mRNA) are present adjacent to blood vessels, suggesting the occurrence of a vascular-related event mediating both fibroblast activation and tissue fibrosis (Ask et al., 2006). Increased levels of endothelin-1, a vasoconstrictor and mitogenic peptide, which is believed to play a role in fibrosis and collagen production, has been found in the plasma of scleroderma patients (Kahaleh, 1991) and in the lungs of patients with IPF (Giaid et al., 1993). These data suggest an increased expression and/or production of endothelin by the vascular endothelium in scleroderma which might be mediated, at least in part, by cytokines (TNF-α, TGF-β, and IL-8) released from alveolar inflammatory cells. In addition, intense expression of PDGF by the endothelial lining of small capillaries in scleroderma (Gay et al., 1989) suggests that endothelin may act in synergy with other cytokines and growth factors to activate fibroblasts. Consistent with the concept that immune processes initiate inflammation, immune complexes are found in the epithelial lining fluid of patients with scleroderma (Jansen et al., 1984;Silver et al., 1986). Several lines of evidence support the concept that alveolitis, i.e. the accumulation of immune and inflammatory cells within the alveolar structures, precedes lung injury and may be the first step of the fibrotic process for which it may be entirely responsible. The alveolitis in scleroderma is characterized by an accumulation of activated alveolar macrophages, lymphocytes, neutrophils and eosinophils (Edelson et al., 1985;Harrison et al., 1989;Konig et al., 1984;Owens et al., 1986;Pesci et al., 1986;Silver et al., 1984;Wallaert et al., 1988;Zhu et al., 2002). In scleroderma, alveolar macrophages have been shown to spontaneously release greater amounts of superoxide anion than normal alveolar macrophages (Wallaert et al., 1988). Collagenase, neutrophil elastase and elastase-like activities have been found in bronchoalveolar lavage (BAL) fluid (Konig et al., 1984;Sibille et al., 1990). Inflammatory cells can also activate the coagulation system (increased levels of plasminogen activator are present in BAL fluid) (Martinot et al., 1989) and release various mediators leading to the recruitment and accumulation of fibroblasts, and to the formation of connective tissue matrix substances. Alveolar macrophages from scleroderma patients release exaggerated amounts of IL-1, IL-6, TNF-α, fibronectin and alveolar macrophage derived growth factor (Bolster et al., 1997;Edelson et al., 1985;Rossi et al., 1985;Wallaert et al., 1988). Cytokines

induce the recruitment of inflammatory cells by the induction of chemokines (Rolfe et al., 1991) or by the modulation of cellular adhesion molecule expression by vascular endothelium and leukocytes (Springer, 1990). In this context, Carre et al. (Carre et al., 1991) recently demonstrated increased expression of IL-8 mRNA and IL-8 protein by alveolar macrophages from patients with ILD associated with scleroderma. The presence of high levels of IL-8 in BAL fluid correlates with the percentage of neutrophils (Southcott et al., 1995). Moreover, monokines are known either to stimulate fibroblast growth directly or through induction of growth factors potentially active in fibroblast proliferation (Sugarman et al., 1985), or to inhibit fibroblast growth through prostaglandin E2 (PGE2) synthesis. The fibrogenic cytokines TGF-β and PDGF are elevated in BAL fluid (Ludwicka et al., 1992). All these findings support the hypothesis that inflammatory and immune effector cells might modulate the injury and repair process occurring in the lung of scleroderma patients.

5.3 Dermatomyositis (DM) and polymyositis (PM)

The prevalence of ILD in DM/PM ranges from 5% to 30% depending on the diagnostic method (Ikezoe et al., 1996;Schwarz, 1992). Lung involvement may precede muscle or skin manifestations in up to one-third of cases. Clinically, the presentation of ILD in DM/PM can range from a rapidly progressive adult respiratory distress syndrome (ARDS)-like syndrome (Hamman-Rich syndrome) to slowly progressive exertional dyspnoea with abnormal imaging or can be asymptomatic only evidenced by abnormal radiology and lung function. Precipitating antibody to the acidic nuclear protein antigen Jo-1 (histidyl-transfer RNA synthetase) has been reported to be a marker of associated ILD in DM/PM, despite the fact that some patients are Jo-1 negative, but have ILD (Bernstein et al., 1984;Yoshida et al., 1983). Another study reported that antobodies to PL-7 (threonyl-transfer RNA synthetase) and to PL-12 (alanyl-transfer RNA synthetase) may be found in patients with DM/PM-related ILD (Hengstman et al., 2000)

Three major histological patterns are identified and include bronchiolitis obliterans-organizing pneumonia (BOOP), diffuse alveolar damage (DAD), and UIP. In BOOP, inflammatory polyps protrude into the terminal bronchioles and young connective tissue extends from the terminal bronchioles into the alveolar structures. This pattern of lesion is associated with acute ILD, and is related to a better prognosis than chronic ILD. In chronic UIP, alveolar septal collagen deposition, sparse interstitial lymphoplasmocytic infiltrates and type II alveolar lining cell hyperplasia are seen. DAD is characterized by alveolar lining cell injury, alveolar wall oedema and intra-alveolar fibrin deposition, with formation of hyaline membranes and focal haemorrhages (Takizawa et al., 1985;Tazelaar et al., 1990).

6. Idiopathic pulmonary fibrosis and malignancy

Idiopathic pulmonary fibrosis is related to malignant disease in a number of important ways: firstly, the pathophysiology of IPF has been likened to malignant disease with reference to apparently uncontrolled proliferation of fibroblasts resulting in alteration of local tissue architecture and resulting organ dysfunction; secondly, IPF is associated with an increased incidence of primary lung cancer; and finally, oncology treatments including chemotherapy and radiotherapy are known to induce pulmonary fibrosis.

6.1 Neoplastic hypothesis in IPF

Malignant disease is characterized by genetic alterations leading to uncontrolled cellular proliferation and local invasion leading to alteration in local tissue architecture and organ dysfunction. The histological hallmark of UIP is collections of fibroblasts, activated myofibroblasts and deposited collagenous extracellular matrix termed 'fibroblastic foci', often occurring in the margins between microscopically normal lung and areas of established fibrosis with little cellular inflammation (Cool et al., 2006). Originally it was suggested that these foci represent distinct areas of aberrant healing in response to local epithelial injury. However through three-dimensional reconstruction of lung biopsy specimens of UIP, Cool et al. demonstrated that the fibroblastic foci represent an interconnected network with associated abnormal vasculature. Whilst this finding would seem to support the hypothesis describing IPF as a neoplastic process, analysis of clonality of the fibroblasts demonstrated polyclonal rather than monoclonal proliferation suggesting a reactive rather than malignant process (Cool et al., 2006). It can however be argued that polyclonality alone does not rule out malignancy with polyclonality being described in a small number of haematological and other solid organ tumours (Davidsson et al., 2005;Parsons, 2008).

6.2 IPF as a risk factor for lung cancer

Early reports described an association between fibrosing alveolitis and increased risk of lung cancer (Haddad & Massaro, 1968). More recently, a large population-based cohort study utilized the General Practice Research Database in the United Kingdom to investigate the incidence of lung cancer in patients with CFA and controls (Hubbard et al., 2000). This study of 890 patients with CFA syndrome and 5,884 controls reported a clear increased incidence of lung cancer in CFA with an odds ratio of 7.31 with little modification when smoking status was taken into account. The authors acknowledged that through use of a large general practice database there was inherent risk of misreporting in the data with particular focus on smoking status. However, the size of this study and the magnitude of increased incidence strongly suggest a positive association. Subsequent research has further defined the association with increased risk reported in male IPF patients who smoke with a similar frequency of histological cancer subtypes observed in non-IPF sufferers (Park et al., 2001) supporting historical observations (Stack et al., 1972). However, other studies have failed to confirm an association between IPF and malignancy although varying methodology, each with inherent risk of errors, means that a degree of uncertainty remains (Samet, 2000).

Although the mechanism of fibrosis predisposing to malignancy is unclear, the notion of fibrotic disease predisposing to the development of malignancy is not isolated to the lung also being observed in liver cirrhosis.

6.3 Radiation induced lung injury and pulmonary fibrosis

In addition to the recognized association between IPF and lung cancer, cancer therapies including certain cytotoxic agents and radiotherapy are associated with developing fibrosis within the lung and other tissues.

Radiotherapy is used to treat a wide range of malignant disease and can be used in isolation or in combination with surgery and/or chemotherapy in order to achieve survival benefit or palliate symptoms. External beam radiotherapy delivers a concentrated dose of ionizing

radiation to a targeted area aiming to minimize the exposure of surrounding tissues - however a degree of exposure is unavoidable. The use of radiotherapy for the treatment of thoracic tumours can result in exposure of the lung parenchyma to ionizing radiation and can result in the development of radiation pneumonitis and subsequent fibrosis. The aetiology and temporal relationship between the inducing agent and fibrosis is poorly understood in the majority of fibrotic diseases, but radiation-induced fibrosis provides insight into this area.

Radiotherapy results in immediate oxidative DNA, protein and lipid damage. The resulting cellular injury leading to apoptosis and cell death within tumour cells results in its therapeutic benefit. However, exposure of surrounding tissues including epithelial and endothelial cells results in release of inflammatory and pro-fibrotic mediators and generation of reactive oxygen species that are felt to be important in driving and perpetuating the fibrotic process. Indeed, microvascular injury resulting from endothelial injury has been shown to result in chronic tissue hypoxia following radiotherapy for head and neck cancers and is known to contribute to sustained ECM deposition in vitro (Yarnold & Brotons, 2010).

Clinically, radiation pneumonitis usually occurs 4-12 weeks after completion of treatment and may result in breathlessness, cough, pyrexia and chest discomfort although this acute phase may be asymptomatic. Progression to fibrosis can result in progressive breathlessness and dry cough however this stage can also be asymptomatic being identified only on thoracic imaging (Davis et al., 1992). The risk of developing radiation induced lung injury is related to the total radiation dose, the dose rate and the volume of lung irradiated. Three stages of lung injury have been described with initial exudative and organizing phases occurring in radiation pneumonitis followed by a chronic fibrotic phase (Gross, 1977). Initial epithelial and endothelial injury occurs resulting in vascular congestion and thrombosis leading to leak of proteinacious fluid into the lung interstitum and alveoli. In addition to microvascular injury, type II pneumocyte damage with resulting surfactant deficiency and alveolar collapse has also been suggested as a mechanism contributing to lung injury (Davis et al., 1992).

The role of inflammation in this process is subject of debate. Infiltration with inflammatory cells including macrophages has been observed within weeks of lung irradiation. Macrophages are an important source of inflammatory and pro-fibrotic cytokines including TGF-β. In contrast to the classical pattern of radiation induced lung injury with changes occurring only within the irradiated field as a direct result of local cellular injury, in some cases the pattern of lung injury is not confined to the irradiated field occurring sporadically throughout both lungs. This pattern has been associated with a lymphocytic alveolitis on bronchalveolar lavage (Morgan & Breit, 1995). The role of this lymphocytic inflammation is unclear but a subset of T lymphocytes are known to release the profibrotic mediators IL-4 and IL-13 that may be of significance in these patients (Morgan & Breit, 1995).

As in other models of fibrosis, TGF-β plays a central role in initiating and sustaining fibrosis following radiation exposure. TGF-β stimulates a cascade of events leading to fibrosis including induction of CTGF production by fibroblasts through direct activation of gene transcription (Grotendorst et al., 1996). TGF-β and CTGF along with other pro-fibrotic mediators including PDGF result in fibroblast recruitment, proliferation and differentiation into myofibroblasts with ECM deposition (Yarnold & Brotons, 2010). The combined profibrotic effect of TGF-β and CTGF has been shown to be important in producing a

sustained fibrotic response in animal models and has been described in other chronic fibrotic disorders including scleroderma (Leask et al., 2004).

The interaction between TGF-β and CTGF has been studied in vivo following pelvic irradiation for colorectal cancer. Irradiated rectal mucosa stained positive for TGF-β in non-tumour containing tissues 7-40 weeks following radiotherapy (Canney & Dean, 1990). However, patients undergoing surgery for fibrotic strictures in chronically fibrotic bowel following pelvic irradiation exhibit high levels of CTGF mRNA and protein but levels of TGF-β no greater than non-irradiated tissue (Vozenin-Brotons et al., 2003) suggesting that TGF-β is important in initiation of the fibrotic process with CTGF perpetuating fibrosis. Reactive oxygen species generated during radiation exposure are believed to be an important activator of TGF-β with resulting cascade of events leading to fibrosis. The importance of TGF-β in radiation-induced lung injury is supported by evidence that inhibiting TGF-β reduces the effects of radiation exposure including reduction in fibrosis, inflammation and respiratory distress (Anscher et al., 2008).

7. Inflammation and fibrosis in other organ systems

7.1 Diabetes and diabetic nephropathy

Diabetic nephropathy (DN) is a major health problem worldwide. Histologically it is characterized by tissue remodeling, particularly tubular atrophy and interstitial fibrosis similar to that seen in the lung in IPF. Diabetes is currently regarded as an inflammatory disease as well as a metabolic disorder. The interplay between hyperglycaemia, insulin resistance, and a systemic inflammatory response in type II diabetes mellitus (T2DM) is believed to promote microvascular complications via endothelial cell dysfunction and induction of a procoagulant state. For example, increased expression of ICAM-1 has been reported in rodent models of DN, and elevated soluble ICAM-1 has been reported in human subjects with DN. Similarly, endothelial VCAM-1 expression was increased in animal models of DN, and increased concentrations of soluble VCAM-1 have been reported in blood samples from patients with DN. However, the precise molecular mechanisms underlying the systemic inflammatory response in DM are poorly understood (Goldberg, 2009).

Recruitment of inflammatory cells into the diabetic kidney may be an initiating event in renal injury leading to fibrosis and development of the end-stage kidney (ESK). For example, in the streptozotocin rat model of diabetes, the chemokine MCP-1 mediated macrophage accumulation and activation at an early stage of nephropathy (Chow et al., 2007), and blockade of MCP-1/CCR2 ameliorated DN in this model (Kanamori et al., 2007). Interestingly, renal MCP-1 excretion is reduced by rennin-angiotensin-aldosterone blockade, an effective therapeutic intervention on slowing progression in DN.

Various inflammatory mediators have been implicated in the renal lesions in DN. Relative deficiency of circulating adiponectin has pro-inflammatory effects on macrophages, endothelial cells, and smooth muscle cells (Rivero et al., 2009). Leptin excess has pro-inflammatory effects in terms of impaired endothelial function, stimulation and aggregation of platelets, increased oxidative stress, and stimulation of vascular smooth muscle cells. Leptin is metabolized principally in the kidney tubules by binding to its receptor megalin where it may lead to proliferation of endothelial cells and mesangial cell hypertrophy, increased TGF-β and collagen type I and IV production. Furthermore, TLR-

mediated immune activation has been implicated in diabetes and various types of renal disease. In the Diabetes Control and Complications Trial, baseline E-selectin and fibrinogen levels predicted DN in T1DM (Lopes-Virella et al., 2008). The classical pro-inflammatory cytokines IL-1 and IL-6 were up-regulated in animal models of DN. Renal expression of tissue factor was up-regulated 2.5-times in the kidneys of diabetic compared with control rats, and this preceded clinical renal disease manifested by albuminuria. Similarly, correlations have been reported in diabetic patients between serum concentrations of TNF-α and severity of DN. Other serum markers associated with DN include CRP and IL-6 (Goldberg, 2009).

7.2 Liver fibrosis

Worldwide, the causes of liver fibrosis have largely been established and are the consequence of liver injury and inflammation (hepatitis) caused by chronic viral infection (HBV, HCV), alcohol, or obesity (steatohepatitis), or autoimmunity (Bousse-Kerdiles et al., 2008). In the well characterized carbon tetrachloride liver injury model in rodents, iterative injury leads to inflammation followed by intense scarring, followed by resolution and disappearance of scar tissue. Resolution of scarring is believed to be mediated by macrophage-derived matrix metalloproteases (MMPs). Duffield et al (Duffield et al., 2005) examined the role of macrophages in fibrosis and resolution using a transgenic mouse model in which macrophages could be depleted. Macrophage depletion during the early injury phase led to loss of myofibroblasts and failure to lay down matrix including collagen III and elastin, and reduced scarring. Macrophage depletion during the late resolution phase led instead to persistence of myofibroblasts, attenuated matrix degradation, and failure to resolve the scar tissue. These data defined two macrophage populations with opposite functions – promoting fibrosis in the initial injury phase and resolving scar tissue after removal of the injurious stimulus - and identified macrophages as key players regulating healing and fibrosis.

7.3 Myelofibrosis

The marked bone marrow fibrosis seen in primary myelofibrosis is associated with immunological abnormalities implicating lymphocytes in the scarring process (Bousse-Kerdiles et al., 2008). Similarly, studies of bone marrow fibrosis in Hairy Cell Leukaemia suggest that the abnormal B lymphocytes may play a key role as a source of fibrogenic cytokines. Abnormal immune complex-stimulated megakaryocytes have also been implicated as they release PDGF, a potent stimulator of fibroblast activation, as well as other fibrogenic cytokines including TGF-β. Similarly, monocytes/macrophages may also be a source of fibrogenic cytokines in myelofibrosis.

8. Conclusion

In the last decade the classical hypothesis that acute and chronic inflammation preceded pulmonary fibrosis has fallen out of favour, but as we have discussed in this chapter inflammation is strongly implicated in fibrogenesis in animal models and in other fibrotic human diseases. Our understanding of the role of inflammation in IPF remains incomplete but must not be discounted on the basis of failed response to immunosuppressant therapy. UIP represents the end point of a number of fibrotic conditions including asbestos related

interstitial lung disease, hypersensitivity pneumonitis and connective tissue diseases. It should be considered that IPF may have an asymptomatic stage in which inflammation plays an important part with UIP representing a self perpetuating universal fibrotic end point.

Animal models of pulmonary fibrosis have provided insight into fibrogenesis however they do not truly parallel human disease and therefore conclusions must be drawn with caution. However, they do provide a useful tool for generating hypotheses that can be investigated in human subjects. The relatively low prevalence of IPF in the population and our poor understanding of the disease course pose challenges for good quality clinical research resulting in many studies having sample sizes that are too small to draw firm conclusions. With the development of research networks facilitating multicentre collaboration it is essential that the role of inflammation continues to be investigated in order to improve our understanding of the interplay between inflammation and fibrosis in the lung.

9. References

Adamson, I.Y. (1976). Pulmonary toxicity of bleomycin. *Environ Health Perspect*, 16, pp.(119-126),

Alarcon-Riquelme, M.E., Moller, G., & Fernandez, C. (1991). The effects of interleukins 4 and 5 on the differentiation of B cells from (NZB x NZW)F1 mice. *Scand J Immunol*, 33, 2, pp.(119-129),

Anderson, A.L., Sporici, R., Lambris, J., Larosa, D., & Levinson, A.I. (2006). Pathogenesis of B-cell superantigen-induced immune complex-mediated inflammation. *Infect Immun*, 74, 2, pp.(1196-1203),

Anscher, M.S., Thrasher, B., Zgonjanin, L., Rabbani, Z.N., Corbley, M.J., Fu, K., Sun, L., Lee, W.C., Ling, L.E., & Vujaskovic, Z. (2008). Small molecular inhibitor of transforming growth factor-beta protects against development of radiation-induced lung injury. *Int J Radiat Oncol Biol Phys*, 71, 3, pp.(829-837),

Aquino-Galvez, A., Perez-Rodriguez, M., Camarena, A., Falfan-Valencia, R., Ruiz, V., Montano, M., Barrera, L., Sada-Ovalle, I., Ramirez, R., Granados, J., Pardo, A., & Selman, M. (2009). MICA polymorphisms and decreased expression of the MICA receptor NKG2D contribute to idiopathic pulmonary fibrosis susceptibility. *Hum Genet*, 125, 5-6, pp.(639-648),

Ask, K., Martin, G.E.M., Bonniaud, P., Kolb, M., & Gauldie, J. (2006). Strategies targeting fibrosis in pulmonary disease. *Drug Discovery Today: Therapeutic Strategies*, 3, 3, pp.(389-394),

Balbi, B., Cosulich, E., Risso, A., Sacco, O., Balzano, E., & Rossi, G.A. (1987). The interstitial lung disease associated with rheumatoid arthritis: evidence for imbalance of helper T-lymphocyte subpopulations at sites of disease activity. *Bull Eur Physiopathol Respir*, 23, 3, pp.(241-247),

Baran, C.P., Opalek, J.M., McMaken, S., Newland, C.A., O'Brien, J.M., Jr., Hunter, M.G., Bringardner, B.D., Monick, M.M., Brigstock, D.R., Stromberg, P.C., Hunninghake, G.W., & Marsh, C.B. (2007). Important roles for macrophage colony-stimulating factor, CC chemokine ligand 2, and mononuclear phagocytes in the pathogenesis of pulmonary fibrosis. *Am J Respir Crit Care Med*, 176, 1, pp.(78-89),

Barazzone-Argiroffo, C., Muzzin, P., Donati, Y.R., Kan, C.D., Aubert, M.L., & Piguet, P.F. (2001). Hyperoxia increases leptin production: a mechanism mediated through endogenous elevation of corticosterone. *Am J Physiol Lung Cell Mol Physiol*, 281, 5, pp.(L1150-L1156),

Barbarin, V., Nihoul, A., Misson, P., Arras, M., Delos, M., Leclercq, I., Lison, D., & Huaux, F. (2005). The role of pro- and anti-inflammatory responses in silica-induced lung fibrosis. *Respir Res*, 6, pp.(112-

Bernstein, R.M., Morgan, S.H., Chapman, J., Bunn, C.C., Mathews, M.B., Turner-Warwick, M., & Hughes, G.R. (1984). Anti-Jo-1 antibody: a marker for myositis with interstitial lung disease. *Br Med J (Clin Res Ed)*, 289, 6438, pp.(151-152),

Bjoraker, J.A., Ryu, J.H., Edwin, M.K., Myers, J.L., Tazelaar, H.D., Schroeder, D.R., & Offord, K.P. (1998). Prognostic significance of histopathologic subsets in idiopathic pulmonary fibrosis. *Am J Respir Crit Care Med*, 157, 1, pp.(199-203),

Bolster, M.B., Ludwicka, A., Sutherland, S.E., Strange, C., & Silver, R.M. (1997). Cytokine concentrations in bronchoalveolar lavage fluid of patients with systemic sclerosis. *Arthritis Rheum*, 40, 4, pp.(743-751),

Bournazos, S., Bournazou, I., Murchison, J.T., Wallace, W.A., McFarlane, P., Hirani, N., Simpson, A.J., Dransfield, I., & Hart, S.P. (2010). Fcgamma receptor IIIb (CD16b) polymorphisms are associated with susceptibility to idiopathic pulmonary fibrosis. *Lung*, 188, 6, pp.(475-481),

Bournazos, S., Bournazou, I., Murchison, J.T., Wallace, W.A., McFarlane, P., Hirani, N., Simpson, A.J., Dransfield, I., & Hart, S.P. (2011). Copy number variation of FCGR3B is associated with susceptibility to idiopathic pulmonary fibrosis. *Respiration*, 81, 2, pp.(142-149),

Bouros, D., Wells, A.U., Nicholson, A.G., Colby, T.V., Polychronopoulos, V., Pantelidis, P., Haslam, P.L., Vassilakis, D.A., Black, C.M., & du Bois, R.M. (2002). Histopathologic subsets of fibrosing alveolitis in patients with systemic sclerosis and their relationship to outcome. *Am J Respir Crit Care Med*, 165, 12, pp.(1581-1586),

Bousse-Kerdiles, M.C., Martyre, M.C., & Samson, M. (2008). Cellular and molecular mechanisms underlying bone marrow and liver fibrosis: a review. *Eur Cytokine Netw*, 19, 2, pp.(69-80),

Bucala, R., Spiegel, L.A., Chesney, J., Hogan, M., & Cerami, A. (1994). Circulating fibrocytes define a new leukocyte subpopulation that mediates tissue repair. *Mol Med*, 1, 1, pp.(71-81),

Campbell, D.A., Poulter, L.W., Janossy, G., & du Bois, R.M. (1985). Immunohistological analysis of lung tissue from patients with cryptogenic fibrosing alveolitis suggesting local expression of immune hypersensitivity. Thorax, 40, 6, pp.(405-411),

Canney, P.A. & Dean, S. (1990). Transforming growth factor beta: a promotor of late connective tissue injury following radiotherapy? *Br J Radiol*, 63, 752, pp.(620-623),

Carre, P.C., Mortenson, R.L., King, T.E., Jr., Noble, P.W., Sable, C.L., & Riches, D.W. (1991). Increased expression of the interleukin-8 gene by alveolar macrophages in idiopathic pulmonary fibrosis. A potential mechanism for the recruitment and activation of neutrophils in lung fibrosis. *J Clin Invest*, 88, 6, pp.(1802-1810),

Chapman, J.R., Charles, P.J., Venables, P.J., Thompson, P.J., Haslam, P.L., Maini, R.N., & Turner Warwick, M.E. (1984). Definition and clinical relevance of antibodies to nuclear ribonucleoprotein and other nuclear antigens in patients with cryptogenic fibrosing alveolitis. *Am Rev Respir Dis*, 130, 3, pp.(439-443),

Chiang, C.S., Liu, W.C., Jung, S.M., Chen, F.H., Wu, C.R., McBride, W.H., Lee, C.C., & Hong, J.H. (2005). Compartmental responses after thoracic irradiation of mice: strain differences. *Int J Radiat Oncol Biol Phys*, 62, 3, pp.(862-871),

Chilosi, M., Poletti, V., Zamo, A., Lestani, M., Montagna, L., Piccoli, P., Pedron, S., Bertaso, M., Scarpa, A., Murer, B., Cancellieri, A., Maestro, R., Semenzato, G., & Doglioni, C. (2003). Aberrant Wnt/beta-catenin pathway activation in idiopathic pulmonary fibrosis. *Am J Pathol*, 162, 5, pp.(1495-1502),

Chow, F.Y., Nikolic-Paterson, D.J., Ma, F.Y., Ozols, E., Rollins, B.J., & Tesch, G.H. (2007). Monocyte chemoattractant protein-1-induced tissue inflammation is critical for the development of renal injury but not type 2 diabetes in obese db/db mice. *Diabetologia*, 50, 2, pp.(471-480),

Christensen, P.J., Goodman, R.E., Pastoriza, L., Moore, B., & Toews, G.B. (1999). Induction of lung fibrosis in the mouse by intratracheal instillation of fluorescein isothiocyanate is not T-cell-dependent. *Am J Pathol*, 155, 5, pp.(1773-1779),

Cool, C.D., Groshong, S.D., Rai, P.R., Henson, P.M., Stewart, J.S., & Brown, K.K. (2006). Fibroblast foci are not discrete sites of lung injury or repair: the fibroblast reticulum. *Am J Respir Crit Care Med*, 174, 6, pp.(654-658),

Crystal, R.G., Fulmer, J.D., Roberts, W.C., Moss, M.L., Line, B.R., & Reynolds, H.Y. (1976). Idiopathic pulmonary fibrosis. Clinical, histologic, radiographic, physiologic, scintigraphic, cytologic, and biochemical aspects. *Ann Intern Med*, 85, 6, pp.(769-788),

Davidsson, J., Paulsson, K., & Johansson, B. (2005). Multicolor fluorescence in situ hybridization characterization of cytogenetically polyclonal hematologic malignancies. *Cancer Genet Cytogenet*, 163, 2, pp.(180-183),

Davis, S.D., Yankelevitz, D.F., & Henschke, C.I. (1992). Radiation effects on the lung: clinical features, pathology, and imaging findings. *AJR Am J Roentgenol*, 159, 6, pp.(1157-1164),

DeRemee, R.A., Harrison, E.G., Jr., & Andersen, H.A. (1972). The concept of classic interstitial pneumonitis-fibrosis (CIP-F) as a clinicopathologic syndrome. *Chest*, 61, 3, pp.(213-220),

Dobashi, N., Fujita, J., Murota, M., Ohtsuki, Y., Yamadori, I., Yoshinouchi, T., Ueda, R., Bandoh, S., Kamei, T., Nishioka, M., Ishida, T., & Takahara, J. (2000a). Elevation of anti-cytokeratin 18 antibody and circulating cytokeratin 18: anti-cytokeratin 18 antibody immune complexes in sera of patients with idiopathic pulmonary fibrosis. *Lung*, 178, 3, pp.(171-179),

Dobashi, N., Fujita, J., Ohtsuki, Y., Yamadori, I., Yoshinouchi, T., Kamei, T., Tokuda, M., Hojo, S., Bandou, S., Ueda, Y., & Takahara, J. (2000b). Circulating cytokeratin 8:anti-cytokeratin 8 antibody immune complexes in sera of patients with pulmonary fibrosis. *Respiration*, 67, 4, pp.(397-401),

Douglas, W.W., Ryu, J.H., & Schroeder, D.R. (2000). Idiopathic pulmonary fibrosis: Impact of oxygen and colchicine, prednisone, or no therapy on survival. *Am J Respir Crit Care Med*, 161, 4 Pt 1, pp.(1172-1178),

Dreisin, R.B., Schwarz, M.I., Theofilopoulos, A.N., & Stanford, R.E. (1978). Circulating immune complexes in the idiopathic interstitial pneumonias. *N Engl J Med*, 298, 7, pp.(353-357),

du Bois, R.M. (2002). The genetic predisposition to interstitial lung disease: functional relevance. *Chest*, 121, 3 Suppl, pp.(14S-20S),

Duffield, J.S., Forbes, S.J., Constandinou, C.M., Clay, S., Partolina, M., Vuthoori, S., Wu, S., Lang, R., & Iredale, J.P. (2005). Selective depletion of macrophages reveals distinct, opposing roles during liver injury and repair. *J Clin Invest*, 115, 1, pp.(56-65),

Edelson, J.D., Hyland, R.H., Ramsden, M., Chamberlain, D.W., Kortan, P., Meindok, H.O., Klein, M.H., Braude, A.C., Lee, P., & Rebuck, A.S. (1985). Lung inflammation in scleroderma: clinical, radiographic, physiologic and cytopathological features. *J Rheumatol*, 12, 5, pp.(957-963),

Ehrenstein, M.R. & Isenberg, D.A. (1992). Hypergammaglobulinaemia and autoimmune rheumatic diseases. *Ann Rheum Dis*, 51, 11, pp.(1185-1187),

Eisenberg, H. (1982). The interstitial lung diseases associated with the collagen-vascular disorders. *Clin Chest Med*, 3, 3, pp.(565-578),

Ellman, P. & Ball, R.E. (1948). Rheumatoid disease with joint and pulmonary manifestations. *Br Med J*, 2, 4583, pp.(816-820),

Emura, M., Nagai, S., Takeuchi, M., Kitaichi, M., & Izumi, T. (1990). In vitro production of B cell growth factor and B cell differentiation factor by peripheral blood mononuclear cells and bronchoalveolar lavage T lymphocytes from patients with idiopathic pulmonary fibrosis. *Clin Exp Immunol*, 82, 1, pp.(133-139),

Epperly, M.W., Guo, H., Gretton, J.E., & Greenberger, J.S. (2003). Bone marrow origin of myofibroblasts in irradiation pulmonary fibrosis. *Am J Respir Cell Mol Biol*, 29, 2, pp.(213-224),

Erlinger, R., Rauh, G., Behr, J., Schumacher, U., Welsch, U., & Zollner, N. (1991). Similar frequency of autoantibodies against pneumocytes type II and Clara cells in patients with interstitial lung diseases and healthy persons. *Klin Wochenschr*, 69, 7, pp.(297-302),

Fisher, C.E., Ahmad, S.A., Fitch, P.M., Lamb, J.R., & Howie, S.E. (2005). FITC-induced murine pulmonary inflammation: CC10 up-regulation and concurrent Shh expression. *Cell Biol Int*, 29, 10, pp.(868-876),

Flaherty, K.R., Travis, W.D., Colby, T.V., Toews, G.B., Kazerooni, E.A., Gross, B.H., Jain, A., Strawderman, R.L., Flint, A., Lynch, J.P., & Martinez, F.J. (2001). Histopathologic variability in usual and nonspecific interstitial pneumonias. *Am J Respir Crit Care Med*, 164, 9, pp.(1722-1727),

Garcia, J.G., James, H.L., Zinkgraf, S., Perlman, M.B., & Keogh, B.A. (1987). Lower respiratory tract abnormalities in rheumatoid interstitial lung disease. Potential role of neutrophils in lung injury. *Am Rev Respir Dis*, 136, 4, pp.(811-817),

Gauldie, J., Kolb, M., & Sime, P.J. (2002). A new direction in the pathogenesis of idiopathic pulmonary fibrosis? *Respir Res*, 3, pp.(1-

Gay, S., Jones, R.E., Jr., Huang, G.Q., & Gay, R.E. (1989). Immunohistologic demonstration of platelet-derived growth factor (PDGF) and sis-oncogene expression in scleroderma. *J Invest Dermatol*, 92, 2, pp.(301-303),

Geddes, D.M., Webley, M., Brewerton, D.A., Turton, C.W., Turner-Warwick, M., Murphy, A.H., & Ward, A.M. (1977). alpha 1-antitrypsin phenotypes in fibrosing alveolitis and rheumatoid arthritis. *Lancet*, 2, 8047, pp.(1049-1051),

Giaid, A., Michel, R.P., Stewart, D.J., Sheppard, M., Corrin, B., & Hamid, Q. (1993). Expression of endothelin-1 in lungs of patients with cryptogenic fibrosing alveolitis. *Lancet*, 341, 8860, pp.(1550-1554),

Gilligan, D.M., O'Connor, C.M., Ward, K., Moloney, D., Bresnihan, B., & FitzGerald, M.X. (1990). Bronchoalveolar lavage in patients with mild and severe rheumatoid lung disease. *Thorax*, 45, 8, pp.(591-596),

Goldberg, R.B. (2009). Cytokine and cytokine-like inflammation markers, endothelial dysfunction, and imbalanced coagulation in development of diabetes and its complications. *J Clin Endocrinol Metab*, 94, 9, pp.(3171-3182),

Gordon, D.A., Stein, J.L., & Broder, I. (1973). The extra-articular features of rheumatoid arthritis. A systematic analysis of 127 cases. *Am J Med*, 54, 4, pp.(445-452),

Gross, N.J. (1977). Pulmonary effects of radiation therapy. *Ann Intern Med*, 86, 1, pp.(81-92),

Grotendorst, G.R., Okochi, H., & Hayashi, N. (1996). A novel transforming growth factor beta response element controls the expression of the connective tissue growth factor gene. *Cell Growth Differ*, 7, 4, pp.(469-480),

Haddad, R. & Massaro, D. (1968). Idiopathic diffuse interstitial pulmonary fibrosis (fibrosing alveolitis), atypical epithelial proliferation and lung cancer. *Am J Med*, 45, 2, pp.(211-219),

Harrison, N.K., Glanville, A.R., Strickland, B., Haslam, P.L., Corrin, B., Addis, B.J., Lawrence, R., Millar, A.B., Black, C.M., & Turner-Warwick, M. (1989). Pulmonary involvement in systemic sclerosis: the detection of early changes by thin section CT scan, bronchoalveolar lavage and 99mTc-DTPA clearance. *Respir Med*, 83, 5, pp.(403-414),

Harrison, N.K., Myers, A.R., Corrin, B., Soosay, G., Dewar, A., Black, C.M., du Bois, R.M., & Turner-Warwick, M. (1991). Structural features of interstitial lung disease in systemic sclerosis. *Am Rev Respir Dis*, 144, 3 Pt 1, pp.(706-713),

Haslam, P.L., Thompson, B., Mohammed, I., Townsend, P.J., Hodson, M.E., Holborow, E.J., & Turner-Warwick, M. (1979). Circulating immune complexes in patients with cryptogenic fibrosing alveolitis. *Clin Exp Immunol*, 37, 3, pp.(381-390),

Hayman, L.D. & Hunt, R.E. (1952). Pulmonary fibrosis in generalized scleroderma; report of a case and review of the literature. *Dis Chest*, 21, 6, pp.(691-704),

Heinen, E. & Tsunoda, R. (1987). Microenvironments for B-cell production and stimulation. *Immunol Today*, 8, pp.(142-144),

Helene, M., Lake-Bullock, V., Zhu, J., Hao, H., Cohen, D.A., & Kaplan, A.M. (1999). T cell independence of bleomycin-induced pulmonary fibrosis. *J Leukoc Biol*, 65, 2, pp.(187-195),

Hengstman, G.J., van Venrooij, W.J., Vencovsky, J., Moutsopoulos, H.M., & van Engelen, B.G. (2000). The relative prevalence of dermatomyositis and polymyositis in Europe exhibits a latitudinal gradient. *Ann Rheum Dis*, 59, 2, pp.(141-142),

Hjelmstrom, P. (2001). Lymphoid neogenesis: de novo formation of lymphoid tissue in chronic inflammation through expression of homing chemokines. *J Leukoc Biol*, 69, 3, pp.(331-339),

Hodgson, U., Tukiainen, P., & Laitinen, T. (2005). The polymorphism C5507G of complement receptor 1 does not explain idiopathic pulmonary fibrosis among the Finns. *Respir Med*, 99, 3, pp.(265-267),

Hubbard, R., Venn, A., Lewis, S., & Britton, J. (2000). Lung cancer and cryptogenic fibrosing alveolitis. A population-based cohort study. *Am J Respir Crit Care Med*, 161, 1, pp.(5-8),

Hunninghake, G.W. & Fauci, A.S. (1979). Pulmonary involvement in the collagen vascular diseases. *Am Rev Respir Dis*, 119, 3, pp.(471-503),

Hutyrova, B., Pantelidis, P., Drabek, J., Zurkova, M., Kolek, V., Lenhart, K., Welsh, K.I., du Bois, R.M., & Petrek, M. (2002). Interleukin-1 gene cluster polymorphisms in sarcoidosis and idiopathic pulmonary fibrosis. *Am J Respir Crit Care Med*, 165, 2, pp.(148-151),

Ikezoe, J., Johkoh, T., Kohno, N., Takeuchi, N., Ichikado, K., & Nakamura, H. (1996). High-resolution CT findings of lung disease in patients with polymyositis and dermatomyositis. *J Thorac Imaging*, 11, 4, pp.(250-259),

Inoshima, I., Kuwano, K., Hamada, N., Hagimoto, N., Yoshimi, M., Maeyama, T., Takeshita, A., Kitamoto, S., Egashira, K., & Hara, N. (2004). Anti-monocyte chemoattractant protein-1 gene therapy attenuates pulmonary fibrosis in mice. *Am J Physiol Lung Cell Mol Physiol*, 286, 5, pp.(L1038-L1044),

Iyonaga, K., Miyajima, M., Suga, M., Saita, N., & Ando, M. (1997). Alterations in cytokeratin expression by the alveolar lining epithelial cells in lung tissues from patients with idiopathic pulmonary fibrosis. *J Pathol*, 182, 2, pp.(217-224),

Jakubzick, C., Choi, E.S., Joshi, B.H., Keane, M.P., Kunkel, S.L., Puri, R.K., & Hogaboam, C.M. (2003). Therapeutic attenuation of pulmonary fibrosis via targeting of IL-4- and IL-13-responsive cells. *J Immunol*, 171, 5, pp.(2684-2693),

Jansen, H.M., Schutte, A.J., Elema, J.D., Giessen, M.V., Reig, R.P., Leeuwen, M.A., Sluiter, H.J., & The, T.H. (1984). Local immune complexes and inflammatory response in patients with chronic interstitial pulmonary disorders associated with collagen vascular diseases. *Clin Exp Immunol*, 56, 2, pp.(311-320),

Johnston, C.J., Williams, J.P., Okunieff, P., & Finkelstein, J.N. (2002). Radiation-induced pulmonary fibrosis: examination of chemokine and chemokine receptor families. *Radiat Res*, 157, 3, pp.(256-265),

Kacani, L., Sprinzl, G.M., Erdei, A., & Dierich, M.P. (1999). Interleukin-15 enhances HIV-1-driven polyclonal B-cell response in vitro. *Exp Clin Immunogenet*, 16, 3, pp.(162-172),

Kahaleh, M.B. (1991). Endothelin, an endothelial-dependent vasoconstrictor in scleroderma. Enhanced production and profibrotic action. *Arthritis Rheum*, 34, 8, pp.(978-983),

Kakugawa, T., Yokota, S., Mukae, H., Kubota, H., Sakamoto, N., Mizunoe, S., Matsuoka, Y., Kadota, J., Fujii, N., Nagata, K., & Kohno, S. (2008). High serum concentrations of autoantibodies to HSP47 in nonspecific interstitial pneumonia compared with idiopathic pulmonary fibrosis. *BMC Pulm Med*, 8, pp.(23-

Kanamori, H., Matsubara, T., Mima, A., Sumi, E., Nagai, K., Takahashi, T., Abe, H., Iehara, N., Fukatsu, A., Okamoto, H., Kita, T., Doi, T., & Arai, H. (2007). Inhibition of MCP-1/CCR2 pathway ameliorates the development of diabetic nephropathy. *Biochem Biophys Res Commun*, 360, 4, pp.(772-777),

Karupiah, G., Sacks, T.E., Klinman, D.M., Fredrickson, T.N., Hartley, J.W., Chen, J.H., & Morse, H.C., III. (1998). Murine cytomegalovirus infection-induced polyclonal B cell activation is independent of CD4+ T cells and CD40. *Virology*, 240, 1, pp.(12-26),

Keane, M.P., Belperio, J.A., Burdick, M.D., & Strieter, R.M. (2001). IL-12 attenuates bleomycin-induced pulmonary fibrosis. *Am J Physiol Lung Cell Mol Physiol*, 281, 1, pp.(L92-L97),

Keane, M.P., Belperio, J.A., Moore, T.A., Moore, B.B., Arenberg, D.A., Smith, R.E., Burdick, M.D., Kunkel, S.L., & Strieter, R.M. (1999). Neutralization of the CXC chemokine, macrophage inflammatory protein-2, attenuates bleomycin-induced pulmonary fibrosis. *J Immunol*, 162, 9, pp.(5511-5518),

Keane, M.P., Strieter, R.M., & Belperio, J.A. (2005). Mechanisms and mediators of pulmonary fibrosis. *Crit Rev Immunol*, 25, 6, pp.(429-463),

King, T.E., Albera, C., Bradford, W.Z., Costabel, U., Hormel, P., Lancaster, L., Noble, P.W., Sahn, S.A., Szwarcberg, J., Thomeer, M., Valeyre, D., & du Bois, R.M. (2009). Effect of interferon gamma-1b on survival in patients with idiopathic pulmonary fibrosis (INSPIRE): a multicentre, randomised, placebo-controlled trial. *Lancet*, 374, 9685, pp.(222-228), 0140-6736

Konig, G., Luderschmidt, C., Hammer, C., Adelmann-Grill, B.C., Braun-Falco, O., & Fruhmann, G. (1984). Lung involvement in scleroderma. *Chest*, 85, 3, pp.(318-324),

Korfhagen, T.R., Swantz, R.J., Wert, S.E., McCarty, J.M., Kerlakian, C.B., Glasser, S.W., & Whitsett, J.A. (1994). Respiratory epithelial cell expression of human transforming growth factor-alpha induces lung fibrosis in transgenic mice. *J Clin Invest*, 93, 4, pp.(1691-1699),

Kubistova, Z., Mrazek, F., Lympany, P.A., Lagan, A.L., Arakelyan, A., Kriegova, E., Welsh, K.I., Kolek, V., Zatloukal, J., Hutyrova, B., du Bois, R.M., & Petrek, M. (2008). The CR1 C5507G polymorphism is not involved in susceptibility to idiopathic pulmonary fibrosis in two European populations. *Tissue Antigens*, 72, 5, pp.(483-486),

Latsi, P., Pantelidis, P., Vassilakis, D., Sato, H., Welsh, K.I., & du Bois, R.M. (2003). Analysis of IL-12 p40 subunit gene and IFN-gamma G5644A polymorphisms in Idiopathic Pulmonary Fibrosis. *Respir Res*, 4, pp.(6-

Leask, A., Denton, C.P., & Abraham, D.J. (2004). Insights into the molecular mechanism of chronic fibrosis: the role of connective tissue growth factor in scleroderma. *J Invest Dermatol*, 122, 1, pp.(1-6),

Lee, C.G., Cho, S.J., Kang, M.J., Chapoval, S.P., Lee, P.J., Noble, P.W., Yehualaeshet, T., Lu, B., Flavell, R.A., Milbrandt, J., Homer, R.J., & Elias, J.A. (2004). Early growth response gene 1-mediated apoptosis is essential for transforming growth factor beta1-induced pulmonary fibrosis. *J Exp Med*, 200, 3, pp.(377-389),

Lopes-Virella, M.F., Carter, R.E., Gilbert, G.E., Klein, R.L., Jaffa, M., Jenkins, A.J., Lyons, T.J., Garvey, W.T., & Virella, G. (2008). Risk factors related to inflammation and endothelial dysfunction in the DCCT/EDIC cohort and their relationship with nephropathy and macrovascular complications. *Diabetes Care*, 31, 10, pp.(2006-2012),

Lown, J.W. & Sim, S.K. (1977). The mechanism of the bleomycin-induced cleavage of DNA. *Biochem Biophys Res Commun*, 77, 4, pp.(1150-1157),

Ludwicka, A., Trojanowska, M., Smith, E.A., Baumann, M., Strange, C., Korn, J.H., Smith, T., Leroy, E.C., & Silver, R.M. (1992). Growth and characterization of fibroblasts obtained from bronchoalveolar lavage of patients with scleroderma. *J Rheumatol*, 19, 11, pp.(1716-1723),

Magro, C.M., Waldman, W.J., Knight, D.A., Allen, J.N., Nadasdy, T., Frambach, G.E., Ross, P., & Marsh, C.B. (2006). Idiopathic pulmonary fibrosis related to endothelial injury and antiendothelial cell antibodies. *Hum Immunol*, 67, 4-5, pp.(284-297),

Marchal-Somme, J., Uzunhan, Y., Marchand-Adam, S., Valeyre, D., Soumelis, V., Crestani, B., & Soler, P. (2006). Cutting edge: nonproliferating mature immune cells form a novel type of organized lymphoid structure in idiopathic pulmonary fibrosis. *J Immunol*, 176, 10, pp.(5735-5739),

Martinot, J.B., Wallaert, B., Hatron, P.Y., Francis, C., Voisin, C., & Sibille, Y. (1989). Clinical and subclinical alveolitis in collagen vascular diseases: contribution of alpha 2-macroglobulin levels in BAL fluid. *Eur Respir J*, 2, 5, pp.(437-443),

Matsui, T., Inui, N., Suda, T., & Chida, K. (2008). Anti-endothelial cell antibodies in patients with interstitial lung diseases. *Respir Med*, 102, 1, pp.(128-133),

Matyszak, M.K., Citterio, S., Rescigno, M., & Ricciardi-Castagnoli, P. (2000). Differential effects of corticosteroids during different stages of dendritic cell maturation. *Eur J Immunol*, 30, 4, pp.(1233-1242),

McDonald, S., Rubin, P., Chang, A.Y., Penney, D.P., Finkelstein, J.N., Grossberg, S., Feins, R., & Gregory, P.K. (1993). Pulmonary changes induced by combined mouse beta-interferon (rMuIFN-beta) and irradiation in normal mice--toxic versus protective effects. *Radiother Oncol*, 26, 3, pp.(212-218),

Meliconi, R., Bestagno, M., Sturani, C., Negri, C., Galavotti, V., Sala, C., Facchini, A., Ciarrocchi, G., Gasbarrini, G., & Astaldi Ricotti, G.C. (1989). Autoantibodies to DNA topoisomerase II in cryptogenic fibrosing alveolitis and connective tissue disease. *Clin Exp Immunol*, 76, 2, pp.(184-189),

Michalski, J.P., McCombs, C.C., Scopelitis, E., Biundo, J.J., Jr., & Medsger, T.A., Jr. (1986). Alpha 1-antitrypsin phenotypes, including M subtypes, in pulmonary disease associated with rheumatoid arthritis and systemic sclerosis. *Arthritis Rheum*, 29, 5, pp.(586-591),

Moeller, A., Rodriguez-Lecompte, J.C., Wang, L., Gauldie, J., & Kolb, M. (2006). Models of pulmonary fibrosis. *Drug Discovery Today: Disease Models*, 3, 3, pp.(243-249),

Montes, C.L., Acosta-Rodriguez, E.V., Merino, M.C., Bermejo, D.A., & Gruppi, A. (2007). Polyclonal B cell activation in infections: infectious agents' devilry or defense mechanism of the host? *J Leukoc Biol*, 82, 5, pp.(1027-1032),

Moore, B.B. & Hogaboam, C.M. (2008). Murine models of pulmonary fibrosis. *Am J Physiol Lung Cell Mol Physiol*, 294, 2, pp.(L152-L160),

Moore, B.B., Murray, L., Das, A., Wilke, C.A., Herrygers, A.B., & Toews, G.B. (2006). The role of CCL12 in the recruitment of fibrocytes and lung fibrosis. *Am J Respir Cell Mol Biol*, 35, 2, pp.(175-181),

Moore, B.B., Paine, R., III, Christensen, P.J., Moore, T.A., Sitterding, S., Ngan, R., Wilke, C.A., Kuziel, W.A., & Toews, G.B. (2001). Protection from pulmonary fibrosis in the absence of CCR2 signaling. *J Immunol*, 167, 8, pp.(4368-4377),

Morgan, G.W. & Breit, S.N. (1995). Radiation and the lung: a reevaluation of the mechanisms mediating pulmonary injury. *Int J Radiat Oncol Biol Phys*, 31, 2, pp.(361-369),

Muggia, F.M., Louie, A.C., & Sikic, B.I. (1983). Pulmonary toxicity of antitumor agents. *Cancer Treat Rev*, 10, 4, pp.(221-243),

Nakatani-Okuda, A., Ueda, H., Kashiwamura, S., Sekiyama, A., Kubota, A., Fujita, Y., Adachi, S., Tsuji, Y., Tanizawa, T., & Okamura, H. (2005). Protection against bleomycin-induced lung injury by IL-18 in mice. *Am J Physiol Lung Cell Mol Physiol*, 289, 2, pp.(L280-L287),

Nakos, G., Adams, A., & Andriopoulos, N. (1993). Antibodies to collagen in patients with idiopathic pulmonary fibrosis. *Chest*, 103, 4, pp.(1051-1058),

Nash, J.R., McLaughlin, P.J., Butcher, D., & Corrin, B. (1993). Expression of tumour necrosis factor-alpha in cryptogenic fibrosing alveolitis. *Histopathology*, 22, 4, pp.(343-347),

Owens, G.R., Paradis, I.L., Gryzan, S., Medsger, T.A., Jr., Follansbee, W.P., Klein, H.A., & Dauber, J.H. (1986). Role of inflammation in the lung disease of systemic sclerosis: comparison with idiopathic pulmonary fibrosis. *J Lab Clin Med*, 107, 3, pp.(253-260),

Pan, L.H., Ohtani, H., Yamauchi, K., & Nagura, H. (1996). Co-expression of TNF alpha and IL-1 beta in human acute pulmonary fibrotic diseases: an immunohistochemical analysis. *Pathol Int*, 46, 2, pp.(91-99),

Pantelidis, P., Fanning, G.C., Wells, A.U., Welsh, K.I., & du Bois, R.M. (2001). Analysis of tumor necrosis factor-alpha, lymphotoxin-alpha, tumor necrosis factor receptor II, and interleukin-6 polymorphisms in patients with idiopathic pulmonary fibrosis. *Am J Respir Crit Care Med*, 163, 6, pp.(1432-1436),

Park, J., Kim, D.S., Shim, T.S., Lim, C.M., Koh, Y., Lee, S.D., Kim, W.S., Kim, W.D., Lee, J.S., & Song, K.S. (2001). Lung cancer in patients with idiopathic pulmonary fibrosis. *Eur Respir J*, 17, 6, pp.(1216-1219),

Parsons, B.L. (2008). Many different tumor types have polyclonal tumor origin: evidence and implications. *Mutat Res*, 659, 3, pp.(232-247),

Pesci, A., Bertorelli, G., Manganelli, P., & Ambanelli, U. (1986). Bronchoalveolar lavage analysis of interstitial lung disease in CREST syndrome. *Clin Exp Rheumatol*, 4, 2, pp.(121-124),

Phan, S.H., Thrall, R.S., & Ward, P.A. (1980). Bleomycin-induced pulmonary fibrosis in rats: biochemical demonstration of increased rate of collagen synthesis. *Am Rev Respir Dis*, 121, 3, pp.(501-506),

Piguet, P.F. (1990). Is "tumor necrosis factor" the major effector of pulmonary fibrosis? *Eur Cytokine Netw*, 1, 4, pp.(257-258),

Piguet, P.F. (2003). Inflammation in idiopathic pulmonary fibrosis. *Am J Respir Crit Care Med*, 167, 7, pp.(1037-

Piguet, P.F. & Vesin, C. (1994). Pulmonary platelet trapping induced by bleomycin: correlation with fibrosis and involvement of the beta 2 integrins. *Int J Exp Pathol*, 75, 5, pp.(321-328),

Piguet, P.F., Vesin, C., Grau, G.E., & Thompson, R.C. (1993). Interleukin 1 receptor antagonist (IL-1ra) prevents or cures pulmonary fibrosis elicited in mice by bleomycin or silica. *Cytokine*, 5, 1, pp.(57-61),

Raghu, G., Brown, K.K., Costabel, U., Cottin, V., du Bois, R.M., Lasky, J.A., Thomeer, M., Utz, J.P., Khandker, R.K., McDermott, L., & Fatenejad, S. (2008). Treatment of idiopathic pulmonary fibrosis with etanercept: an exploratory, placebo-controlled trial. *Am J Respir Crit Care Med*, 178, 9, pp.(948-955),

Renzoni, E., Lympany, P., Sestini, P., Pantelidis, P., Wells, A., Black, C., Welsh, K., Bunn, C., Knight, C., Foley, P., & du Bois, R.M. (2000). Distribution of novel polymorphisms of the interleukin-8 and CXC receptor 1 and 2 genes in systemic sclerosis and cryptogenic fibrosing alveolitis. *Arthritis Rheum*, 43, 7, pp.(1633-1640),

Riha, R.L., Yang, I.A., Rabnott, G.C., Tunnicliffe, A.M., Fong, K.M., & Zimmerman, P.V. (2004). Cytokine gene polymorphisms in idiopathic pulmonary fibrosis. *Intern Med J*, 34, 3, pp.(126-129),

Riva, S., Nolli, M.L., Lutz, M.B., Citterio, S., Girolomoni, G., Winzler, C., & Ricciardi-Castagnoli, P. (1996). Bacteria and bacterial cell wall constituents induce the production of regulatory cytokines in dendritic cell clones. *J Inflamm*, 46, 2, pp.(98-105),

Rivero, A., Mora, C., Muros, M., Garcia, J., Herrera, H., & Navarro-Gonzalez, J.F. (2009). Pathogenic perspectives for the role of inflammation in diabetic nephropathy. *Clin Sci (Lond)*, 116, 6, pp.(479-492),

Roberts, S.N., Howie, S.E., Wallace, W.A., Brown, D.M., Lamb, D., Ramage, E.A., & Donaldson, K. (1995). A novel model for human interstitial lung disease: hapten-driven lung fibrosis in rodents. *J Pathol*, 176, 3, pp.(309-318),

Rolfe, M.W., Kunkel, S.L., Standiford, T.J., Chensue, S.W., Allen, R.M., Evanoff, H.L., Phan, S.H., & Strieter, R.M. (1991). Pulmonary fibroblast expression of interleukin-8: a model for alveolar macrophage-derived cytokine networking. *Am J Respir Cell Mol Biol*, 5, 5, pp.(493-501),

Rossi, G.A., Bitterman, P.B., Rennard, S.I., Ferrans, V.J., & Crystal, R.G. (1985). Evidence for chronic inflammation as a component of the interstitial lung disease associated with progressive systemic sclerosis. *Am Rev Respir Dis*, 131, 4, pp.(612-617),

Rube, C.E., Uthe, D., Schmid, K.W., Richter, K.D., Wessel, J., Schuck, A., Willich, N., & Rube, C. (2000). Dose-dependent induction of transforming growth factor beta (TGF-beta) in the lung tissue of fibrosis-prone mice after thoracic irradiation. *Int J Radiat Oncol Biol Phys*, 47, 4, pp.(1033-1042),

Saito, F., Tasaka, S., Inoue, K., Miyamoto, K., Nakano, Y., Ogawa, Y., Yamada, W., Shiraishi, Y., Hasegawa, N., Fujishima, S., Takano, H., & Ishizaka, A. (2008). Role of interleukin-6 in bleomycin-induced lung inflammatory changes in mice. *Am J Respir Cell Mol Biol*, 38, 5, pp.(566-571),

Samet, J.M. (2000). Does idiopathic pulmonary fibrosis increase lung cancer risk? *Am J Respir Crit Care Med*, 161, 1, pp.(1-2),

Schwarz, M.I. (1992). Pulmonary and cardiac manifestations of polymyositis-dermatomyositis. *J Thorac Imaging*, 7, 2, pp.(46-54),

Sibille, Y., Martinot, J.B., Polomski, L.L., Wallaert, B., Demusis, M., Rankin, J.A., Voisin, C., & Gee, J.B. (1990). Phagocyte enzymes in bronchoalveolar lavage from patients with pulmonary sarcoidosis and collagen vascular disorders. *Eur Respir J*, 3, 3, pp.(249-256),

Silver, R.M., Metcalf, J.F., & Leroy, E.C. (1986). Interstitial lung disease in scleroderma. Immune complexes in sera and bronchoalveolar lavage fluid. *Arthritis Rheum*, 29, 4, pp.(525-531),

Silver, R.M., Metcalf, J.F., Stanley, J.H., & Leroy, E.C. (1984). Interstitial lung disease in scleroderma. Analysis by bronchoalveolar lavage. *Arthritis Rheum*, 27, 11, pp.(1254-1262),

Sime, P.J., Xing, Z., Graham, F.L., Csaky, K.G., & Gauldie, J. (1997). Adenovector-mediated gene transfer of active transforming growth factor-beta1 induces prolonged severe fibrosis in rat lung. *J Clin Invest*, 100, 4, pp.(768-776),

Smith, R.E., Strieter, R.M., Zhang, K., Phan, S.H., Standiford, T.J., Lukacs, N.W., & Kunkel, S.L. (1995). A role for C-C chemokines in fibrotic lung disease. *J Leukoc Biol*, 57, 5, pp.(782-787),

Snider, G.L., Celli, B.R., Goldstein, R.H., O'Brien, J.J., & Lucey, E.C. (1978). Chronic interstitial pulmonary fibrosis produced in hamsters by endotracheal bleomycin. Lung volumes, volume-pressure relations, carbon monoxide uptake, and arterial blood gas studied. *Am Rev Respir Dis*, 117, 2, pp.(289-297),

Southcott, A.M., Jones, K.P., Li, D., Majumdar, S., Cambrey, A.D., Pantelidis, P., Black, C.M., Laurent, G.J., Davies, B.H., Jeffery, P.K., & . (1995). Interleukin-8. Differential expression in lone fibrosing alveolitis and systemic sclerosis. *Am J Respir Crit Care Med*, 151, 5, pp.(1604-1612),

Springer, T.A. (1990). Adhesion receptors of the immune system. *Nature*, 346, 6283, pp.(425-434),

Stack, B.H., Choo-Kang, Y.F., & Heard, B.E. (1972). The prognosis of cryptogenic fibrosing alveolitis. *Thorax*, 27, 5, pp.(535-542),

Steen, V.D., Owens, G.R., Fino, G.J., Rodnan, G.P., & Medsger, T.A., Jr. (1985). Pulmonary involvement in systemic sclerosis (scleroderma). *Arthritis Rheum*, 28, 7, pp.(759-767),

Stevenson, P.G. & Doherty, P.C. (1999). Non-antigen-specific B-cell activation following murine gammaherpesvirus infection is CD4 independent in vitro but CD4 dependent in vivo. *J Virol*, 73, 2, pp.(1075-1079),

Strieter, R.M. & Mehrad, B. (2009). New mechanisms of pulmonary fibrosis. *Chest*, 136, 5, pp.(1364-1370),

Sugarman, B.J., Aggarwal, B.B., Hass, P.E., Figari, I.S., Palladino, M.A., Jr., & Shepard, H.M. (1985). Recombinant human tumor necrosis factor-alpha: effects on proliferation of normal and transformed cells in vitro. *Science*, 230, 4728, pp.(943-945),

Szapiel, S.V., Elson, N.A., Fulmer, J.D., Hunninghake, G.W., & Crystal, R.G. (1979). Bleomycin-induced interstitial pulmonary disease in the nude, athymic mouse. *Am Rev Respir Dis*, 120, 4, pp.(893-899),

Takizawa, H., Hidaka, N., Akiyama, K., Hisatomi, T., Kosuda, T., Ishimitsu, T., Miyachi, S., & Nishiwaki, M. (1985). [Clinicopathological studies on interstitial lung disease in polymyositis-dermatomyositis]. *Nihon Kyobu Shikkan Gakkai Zasshi*, 23, 5, pp.(528-536),

Tazelaar, H.D., Viggiano, R.W., Pickersgill, J., & Colby, T.V. (1990). Interstitial lung disease in polymyositis and dermatomyositis. Clinical features and prognosis as correlated with histologic findings. *Am Rev Respir Dis*, 141, 3, pp.(727-733),

Thrall, R.S., McCormick, J.R., Jack, R.M., McReynolds, R.A., & Ward, P.A. (1979). Bleomycin-induced pulmonary fibrosis in the rat: inhibition by indomethacin. *Am J Pathol*, 95, 1, pp.(117-130),

Turner-Warwick, M. & Doniach, D. (1965). Auto-Antibody Studies In Interstitial Pulmonary Fibrosis. *Br Med J*, 1, 5439, pp.(886-891),

Vasakova, M., Striz, I., Dutka, J., Slavcev, A., Jandova, S., Kolesar, L., & Sulc, J. (2007a). Cytokine gene polymorphisms and high-resolution-computed tomography score in idiopathic pulmonary fibrosis. *Respir Med*, 101, 5, pp.(944-950),

Vasakova, M., Striz, I., Slavcev, A., Jandova, S., Dutka, J., Terl, M., Kolesar, L., & Sulc, J. (2007b). Correlation of IL-1alpha and IL-4 gene polymorphisms and clinical parameters in idiopathic pulmonary fibrosis. *Scand J Immunol*, 65, 3, pp.(265-270),

Vozenin-Brotons, M.C., Milliat, F., Sabourin, J.C., de Gouville, A.C., Francois, A., Lasser, P., Morice, P., Haie-Meder, C., Lusinchi, A., Antoun, S., Bourhis, J., Mathe, D., Girinsky, T., & Aigueperse, J. (2003). Fibrogenic signals in patients with radiation enteritis are associated with increased connective tissue growth factor expression. *Int J Radiat Oncol Biol Phys*, 56, 2, pp.(561-572),

Wallace, W.A., Howie, S.E., Krajewski, A.S., & Lamb, D. (1996). The immunological architecture of B-lymphocyte aggregates in cryptogenic fibrosing alveolitis. *J Pathol*, 178, 3, pp.(323-329),

Wallaert, B., Bart, F., Aerts, C., Ouaissi, A., Hatron, P.Y., Tonnel, A.B., & Voisin, C. (1988). Activated alveolar macrophages in subclinical pulmonary inflammation in collagen vascular diseases. *Thorax*, 43, 1, pp.(24-30),

Weaver, A.L., Divertie, M.B., & Titus, J.L. (1968). Pulmonary scleroderma. *Dis Chest*, 54, 6, pp.(490-498),

Weiland, J.E., Garcia, J.G., Davis, W.B., & Gadek, J.E. (1987). Neutrophil collagenase in rheumatoid interstitial lung disease. *J Appl Physiol*, 62, 2, pp.(628-633),

Whittington, H.A., Freeburn, R.W., Godinho, S.I., Egan, J., Haider, Y., & Millar, A.B. (2003). Analysis of an IL-10 polymorphism in idiopathic pulmonary fibrosis. *Genes Immun*, 4, 4, pp.(258-264),

Whyte, M., Hubbard, R., Meliconi, R., Whidborne, M., Eaton, V., Bingle, C., Timms, J., Duff, G., Facchini, A., Pacilli, A., Fabbri, M., Hall, I., Britton, J., Johnston, I., & Di Giovine, F. (2000). Increased risk of fibrosing alveolitis associated with interleukin-1 receptor antagonist and tumor necrosis factor-alpha gene polymorphisms. *Am J Respir Crit Care Med*, 162, 2 Pt 1, pp.(755-758),

Yarnold, J. & Brotons, M.C. (2010). Pathogenetic mechanisms in radiation fibrosis. *Radiother Oncol*, 97, 1, pp.(149-161),

Yoshida, S., Akizuki, M., Mimori, T., Yamagata, H., Inada, S., & Homma, M. (1983). The precipitating antibody to an acidic nuclear protein antigen, the Jo-1, in connective tissue diseases. A marker for a subset of polymyositis with interstitial pulmonary fibrosis. *Arthritis Rheum*, 26, 5, pp.(604-611),

Yousem, S.A., Colby, T.V., & Carrington, C.B. (1985). Lung biopsy in rheumatoid arthritis. *Am Rev Respir Dis*, 131, 5, pp.(770-777),

Zhang, K., Gharaee-Kermani, M., Jones, M.L., Warren, J.S., & Phan, S.H. (1994). Lung monocyte chemoattractant protein-1 gene expression in bleomycin-induced pulmonary fibrosis. *J Immunol*, 153, 10, pp.(4733-4741),

Zhu, Z., Zheng, T., Lee, C.G., Homer, R.J., & Elias, J.A. (2002). Tetracycline-controlled transcriptional regulation systems: advances and application in transgenic animal modeling. *Semin Cell Dev Biol*, 13, 2, pp.(121-128),

Zorzetto, M., Ferrarotti, I., Trisolini, R., Lazzari, A.L., Scabini, R., Novo, M., De Silvestri, A., Patelli, M., Martinetti, M., Cuccia, M., Poletti, V., Pozzi, E., & Luisetti, M. (2003). Complement receptor 1 gene polymorphisms are associated with idiopathic pulmonary fibrosis. *Am J Respir Crit Care Med*, 168, 3, pp.(330-334),

IntechOpen

IntechOpen



Inflammatory Diseases - Immunopathology, Clinical and Pharmacological Bases

Edited by Dr Mahin Khatami

ISBN 978-953-307-911-0
Hard cover, 396 pages
Publisher InTech
Published online 10, February, 2012
Published in print edition February, 2012

This book is a collection of comprehensive reviews contributed by experts in the diverse fields of acute and chronic inflammatory diseases, with emphasis on current pharmacological and diagnostic options. Interested professionals are also encouraged to review the contributions made by experts in a second related book entitled "Inflammation, Chronic Diseases and Cancer"; it deals with immunobiology, clinical reviews, and perspectives of the mechanisms of immune inflammatory responses that are involved in alterations of immune dynamics during the genesis, progression and manifestation of a number of inflammatory diseases and cancers, as well as perspectives for diagnosis, and treatment or prevention of these disabling and potentially preventable diseases, particularly for the growing population of older adults around the globe.

How to reference

In order to correctly reference this scholarly work, feel free to copy and paste the following:

Michael G. Crooks, Imran Aslam and Simon P. Hart (2012). Inflammation and Pulmonary Fibrosis, Inflammatory Diseases - Immunopathology, Clinical and Pharmacological Bases, Dr Mahin Khatami (Ed.), ISBN: 978-953-307-911-0, InTech, Available from: http://www.intechopen.com/books/inflammatory-diseases-immunopathology-clinical-and-pharmacological-bases/the-role-of-inflammation-in-pulmonary-fibrosis

INTECH
open science | open minds

InTech Europe
University Campus STeP Ri
Slavka Krautzeka 83/A
51000 Rijeka, Croatia
Phone: +385 (51) 770 447
Fax: +385 (51) 686 166
www.intechopen.com

InTech China
Unit 405, Office Block, Hotel Equatorial Shanghai
No.65, Yan An Road (West), Shanghai, 200040, China
中国上海市延安西路65号上海国际贵都大饭店办公楼405单元
Phone: +86-21-62489820
Fax: +86-21-62489821

© 2012 The Author(s). Licensee IntechOpen. This is an open access article distributed under the terms of the Creative Commons Attribution 3.0 License, which permits unrestricted use, distribution, and reproduction in any medium, provided the original work is properly cited.