

We are IntechOpen, the world's leading publisher of Open Access books Built by scientists, for scientists

6,900

Open access books available

186,000

International authors and editors

200M

Downloads

Our authors are among the

154

Countries delivered to

TOP 1%

most cited scientists

12.2%

Contributors from top 500 universities



WEB OF SCIENCE™

Selection of our books indexed in the Book Citation Index
in Web of Science™ Core Collection (BKCI)

Interested in publishing with us?
Contact book.department@intechopen.com

Numbers displayed above are based on latest data collected.
For more information visit www.intechopen.com



Conjunctival Intraepithelial Neoplasia – Clinical Presentation, Diagnosis and Treatment Possibilities

Valentín Huerva¹ and Francisco J. Ascaso²

¹Department of Ophthalmology,
Universitary Hospital "Arnau de Vilanova" and IRB, Lleida

²Department of Ophthalmology,
"Lozano Blesa" University Clinic Hospital, Zaragoza,
Spain

1. Introduction

Conjunctival tumors are one of the most frequent tumors of the eye and adnexa. They comprise a large variety of conditions, from benign lesions such as papilloma to malignant lesions such as epidermoid carcinoma or melanoma which may threaten visual function and patient's life if not diagnosed early. Although conjunctival tumors may arise from any type of the conjunctival cells, epithelial and melanocytic are the most frequent origins. Epithelial tumors account for a third to half of all tumors, with a higher prevalence in countries with larger actinic exposure. Approximately 40% of the tumors have an epithelial origin and 64.5% of them were pre-cancerous lesions (Saornil et al, 2009). The clinical differentiation between pre-cancerous benign and malign lesions is difficult, requiring a biopsy for a definitive diagnosis.

Squamous neoplasia of the conjunctiva /cornea is a rare malignancy of conjunctival limbal stem cells, and the management of this malignancy may affect the ultimate outcome. The clinical distinction of squamous conjunctival neoplasia from other amelanocytic conjunctival tumors is based on certain clinical features of the tumor, and its correct management requires an understanding of normal anatomy and histology of the cornea and conjunctiva, as well as knowledge of the principles of tumor management.

Conjunctiva is a thin and flexible mucous membrane that extends from the internal surface of the eyelids to the fornix and anterior ocular surface up to the corneoscleral limbus. Histologically, conjunctiva is similar to other mucous membranes and comprises a non-keratinized stratified epithelium having two or more layers over the stroma formed by fibrovascular connective tissue containing vessels, nervous and lymphatic tissue. Basal layer of epithelium comprises melanocytes which produces melanine and inject it in the surrounding cells. Throughout the length of epithelium we can observe cup-shaped cells in charge of producing the mucoid component of the lacrimal film. These cells are called *goblet cells*.

1.1 Definition of Ocular Surface Squamous Neoplasias (OSSN)

Squamous cell neoplasia may occur as a localized lesion confined to the surface epithelium (conjunctival intraepithelial neoplasia) or as a more invasive squamous cell carcinoma that has broken through the basement membrane and invaded the underlying stroma (Shields & Shields, 2004).

Currently, the accepted term for the localized variety is conjunctival intraepithelial neoplasia (CIN). However, other authors prefer the terms dysplasia (mild, moderate, or severe) and carcinoma-in-situ. Where there are no longer normal surface cells then the process may be termed carcinoma-in-situ. Those cases where the cornea is invaded by the process are usually called conjunctiva-cornea intraepithelial neoplasia (CCIN). Squamous neoplasia constitutes the most frequent primary malignancy of the ocular surface.

1.1.1 Conjunctival Intraepithelial Neoplasia (CIN)

CIN is confined to the epithelium by definition. The term CIN was suggested in 1978, according with the general pathologic classification of intraepithelial tumors developed for cervical intraepithelial neoplasia (Pizzarello & Jakobiec, 1978). CIN includes previous terms referred to this epithelial neoplasia such as: Bowen's disease, Bowenoid epithelioma, intraepithelial epithelioma, intraepithelioma, dysplasia and carcinoma in situ (CIS).

Subjective symptoms referred by the patients include: foreign body sensation, redness, irritation, and a growth on the ocular surface (Giaconi & Karp, 2003).

Clinically, CIN appears as a fleshy, sessile or minimally elevated lesion usually at limbus in the interpalpebral fissure and less commonly in the forniceal or tarsal conjunctiva (Shields & Shields, 2004). The limbal lesion may extend for a variable distance into the epithelium of the adjacent cornea. A white plaque (leukoplakia) may occur on the surface of the lesion due to secondary hyperkeratosis.

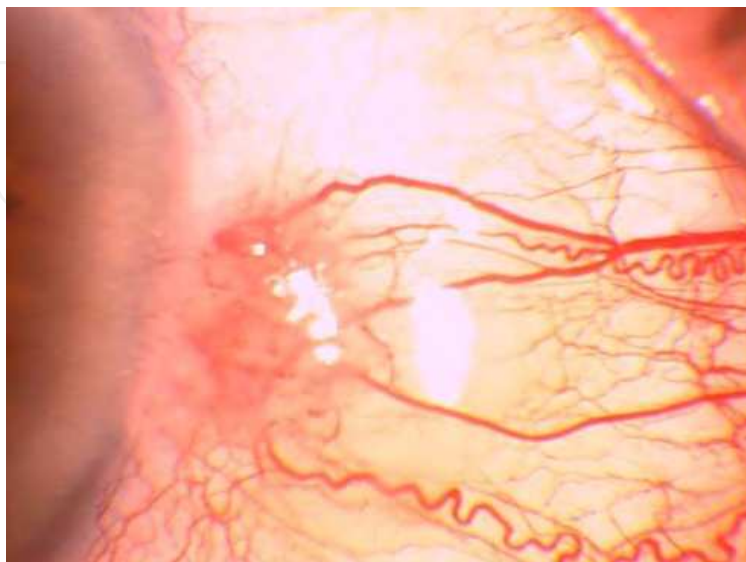


Fig. 1. Conjunctival intraepithelial neoplasia showing corneal invasion.

1.1.2 Squamous Cell Carcinoma (SCC)

Squamous cell carcinoma is characterized by an extension of abnormal epithelial cells through the basement membrane to gain access to the conjunctival stroma (Shields & Shields, 2004). Clinically, invasive squamous cell carcinoma is similar to CIN; however, it may be larger and more elevated than CIN. Even though the cells of invasive squamous cell carcinoma gain access to the blood vessels and lymphatic channels, regional and distant metastases are both rather uncommon. Clinically it is very difficult to distinguish between CIN and SCC (Erie et al, 1986). In many occasions it is necessary to perform a biopsy.

1.2 Incidence

OSSN accounts for only 5% of all ocular malignancies (Lee & Hirts, 1995). CIN is the most common conjunctival malignancy (Grossniklaus et al, 1987). CIN occurred more commonly in pale-skinned groups than in more pigmented people, with an increased incidence in males (75%) vs females (25%), and a mean age of 60 years (Grossniklaus et al, 1987). OSSN associated with human immunodeficiency virus (HIV) is seen at younger ages (average 35 years), usually not in a bulbar location, and is more aggressive from a clinical point of view. Its incidence can vary from 0.13 to 1.9/100.000 inhabitants (Lee & Hirts, 1995), (Giaconi & Karpp, 2003), (Saornil et al, 2009). OSSN incidence varies geographically, increasing with closer distance to the equator. For example, Uganda has 1.2 cases/100.000 persons/year compared to the United Kingdom with less than 0.02 cases/100.000 persons/year. This might suggest a role of ultraviolet light exposure in the etiology of these tumors. US data indicate an incidence of 0.03/100.000 people/year, with a 6-fold increase in association with HIV infection (Sun et al, 1997), (Verma et al, 2008). The lesions are more common in males and elderly, with the majority occurring at the limbus. In Africa the incidence is changing. The tumor is more common, aggressive, more frequent in young persons, especially women (Ateenyi-Agaba, 1995). This is related with the coexistence of pandemic AIDS and exposition to the human papillomavirus (HPV) and ultraviolet radiations. Africa has the highest prevalence of HPV infection in the world (with more than 25 % of women from 15 to 74 years affected), followed by South America (14.3%), Asia (8.7%) and Europe (5.2%) (Clifford, 2005). A study in the Kampala Cancer Registry in Uganda showed an increase from 6 cases of OSSN/1.000.000 persons per year between 1970 and 1988 to 35 cases/1.000.000 persons per year in 1992 (Ateenyi-Agaba, 1995). In Australia, a study found that 78.5% of affected people were male with a mean age of 60 years (Lee & Hirst, 1997). Similarly, another study in United Kingdom showed that the 77% were male, being 69% of them older than 60 years (McKelvie et al, 2002). Nevertheless, a study in Zimbabwe found that a 70% of patients were young women with a mean age of 35 years (Pola et al, 2003), while in South Africa mean age was 37 years (Mahomed & Chetty, 2002). A study in Tanzania showed that the 45.8% of 168 conjunctival biopsies were OSSN (Poole, 1999).

2. Etiologic factors for CIN

To date, CIN etiology remains unclear. The most probably explanation may be multifactorial causes. There are many known factors which may contribute to the development of these neoplasias.

The first one is the age, with an average of 60 years (Lee & Hirst, 1995). However, it ranges from 4 to 90 years. The second factor attributed is the UV light exposure (Lee et al, 1994). This justify a higher prevalence of CIN in the ecuatorial areas, as we have previously commented. The exposition to the petroleum products, heavy cigarrete smoking, light hair and ocular pigmentation have also been associated (Napora et al, 1990).

Younger patients affected by Xeroderma pigmentosum (Herle et al, 1991) and HIV may show a higher incidence (Karp et al, 1996). The majority of CIN cases reported in Africa are HIV-positive: 71% in Uganda, 86% in Malawi (Waddell, et al 1996), 70.6% in South Africa (Mahomed & Chetty 2002) and 92.3% in Zimbabwe (Porges & Groisman 2003). On the other hand, the prevalence of CIN in a HIV-positive population in Kenya was 7.8% (Chisi et al, 2006). These findings suggest that CIN is a marker for HIV infection. OSSN in HIV/AIDS patients presents at a younger age (35-40 years old) than in HIV-negative patients (Timm et al, 2004). Additionally, malignancy seems to be more aggressive in HIV/AIDS patients (Kaimbo 1998). It is unclear whether immunosuppression or HIV itself plays a role in this pathogenesis. Although it has been speculated about the role of HIV in conjunctival squamous cell carcinoma in immunosuppression and activation of oncogenic viruses such as HPV in the conjunctiva, thus far only oral and anogenital HPV has been shown to occur more frequently in HIV-positive patients (Verma et al, 2008). Immunosuppression itself may contribute to the carcinogenesis. Several studies have also demonstrated an association between immunosuppression secondary to HIV infection and increased risk of cervical intraepithelial neoplasia (Palefsky, 1991).

The role of HPV remains also unclear in the etiology of CIN. It has been proved the causal relationship between HPV type 16 and 18 and uterine cervical carcinoma (Scott et al, 2002), (Giaconi & Karp, 2003), (Verma et al, 2008). However, multiple studies worldwide have failed to document an unequivocal association of HPV with conjunctival squamous cell carcinoma (Tuppurainen, 1992), (Eng et al, 2002). A small study of CIN has demonstrated mRNA from the *E6* region of HPV, which signals actively transcribed virus (Scott et al 2002). Furthermore, this study in United States demonstrated the lack of such mRNA from normal conjunctivas, whereas African case series have revealed a high prevalence of HPV DNA in clinically normal conjunctivas for HPV 6 and 11, but not HPV 16 and 18 were found (Verma et al, 2008). In controversy HPV types 16 and 18 may be detected in CIN, in non neoplastic lesions and in apparently healthy conjunctiva (Karcioglu & Issa, 1997). Another study in Thailand concluded that solar elastosis is more frequently founded in OSSN cases than in controls, and HPV DNA was not found in any of the specimens (Tulvatana et al, 2003). HPV 5 and 8 were the most common in nearly half of OSSN in a series recently reported in Uganda (Ateenyi-Agaba, et al 2010). The frequency was the same in infected VIH than in non infected VIH. HPV 5 is not reported in caucasian CIN. HPV 16 and 18 may considerer as disease of sexual transmission whereas HPV 5 may appear by other possible vias. It has been shown in cervical cancer that the high risk variants HPV 16 and HPV 18 lead to carcinogenesis by inactivating tumor suppressor gene products *p53* and *Rb* in the host with the viral oncoproteins E6 and E7, respectively (Verma et al, 2008). Furthermore, integration of viral sequences into the host genome leads to the constitutive expression of E6/E7 in transformed cervical cells. HPV 5 show highest downregulation of basal interleukin-8 secretion in primary human keratinocytes. This may weaken the response to UV-induced

damage and consecutively mutations. Given the conflicting association studies, it appears that UV-B radiation plays a much greater role than HPV in the etiology of CIN (Verma et al, 2008).

3. Clinical presentation of CIN

The clinical presentation of CIN may be variable. There are many different pictures on the ocular surface that constitute a CIN. The subjective symptoms may be also variable in intensity. Apart from the presence of a growth or mass in their ocular surface, patients may complain no symptoms. Size, color and growth may be variable in each case. The presence of a red eye make, sometimes, that the patient was treated as a conjunctivitis. Foreign body sensation, redness, or irritation may be referred many times. CIN is characterized by a slowly progressive course with low malignant potential. In general, two forms of CIN have been described: nodular (or well localized) and diffuse. The diffuse type is less common and very difficult to diagnose in early stages. This situation may be similar to a chronic conjunctivitis and its surgical treatment may result complicated because clinical borders of the lesion may be indistinguishable (Lee & Hirst, 1995), (Giacconi & Karp, 2003).

The typical location of this slow-growing lesion is the interpalpebral limbus, but it may also arise in the forniceal and palpebral conjunctiva. Limbal lesions may spread onto the cornea. The abnormal corneal epithelium has a frosted appearance with fringed borders and usually demonstrates diffuse punctate staining. Flat or elevated, the lesion may appear relatively translucent, gelatinous, or pearly white. Secondary hyperkeratosis over the surface of the lesion may give rise to a white plaque-like appearance clinically named leukoplakia. Often, there are surrounding corkscrew-like vascular tufts. Pigmentation may be seen and the lesion may be clinically misdiagnosed as melanoma (Shields et al, 2008).

The percentages of CIN that develops into SCC have not been reported in the literature. In cases of SCC the tumor may reach to eye globe, the orbit and cranial extension, with vision loss due to a enucleation or exenteration (Lopez-Garcia et al, 2000). Up to 4% rates of metastasis to cervical lymph nodes have been reported, while metastases to distance are less common (Bhattacharyya et al, 1997). There is not a particular symptomatology for every macroscopic form of CIN. Some of the characteristic forms of presentation of precancerous and malignant lesions are described:

3.1 Precancerous lesions: Actinic keratosis and conjunctival keratotic plaque

Both lesions, impossible to differentiate clinically, consist in a white plaque on the limbal or bulbar conjunctiva, in the exposed interpalpebral conjunctiva. They have a low grade of proliferation and very few possibilities to convert into CIN or SCC. Definitive diagnosis consisted in the histological study (Mauriello et al 1996), (Shields et al, 2004).

3.2 Leucoplakic lesions

Leucoplakia (white plaque) consist in a conjunctival lesion, generally at the limbus, which may be round or irregular. A process of keratosis is involved (Shields & Shields, 2008). These lesion may also extend onto the cornea. Likewise, leukoplakic lesions may appear

onto a very diffuse CIN (Huerva et al, 2006). Extensive leukoplakia should raise suspicion of invasive SCC (Shields & Shields, 2008).

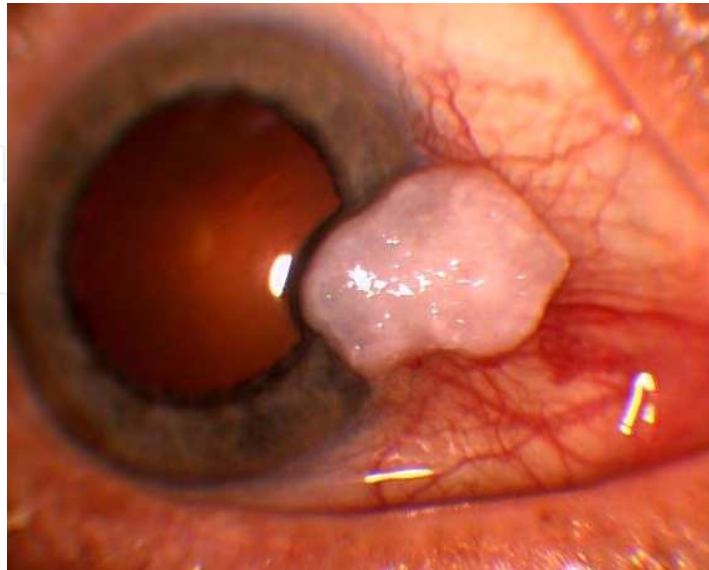


Fig. 2. Leukoplakic CIN, occupying conjunctiva, limbus and cornea at the interpalpebral fissure. Histopatology showed complete dysplasia of the epithelium.

3.3 Papillomatous lesions

CIN may developed simulating a sessile papilloma. The lesion consist in a fleshy red appearance owing numerous fine vascular channels that ramify throughtout the stroma beneath the epithelial surface of the lesion (Shields & Shields, 2008). The presence of displasic epithelial cells helps to the differential diagnosis between papilloma and CIN. In rare occasions papillomas may developed into a CIN.

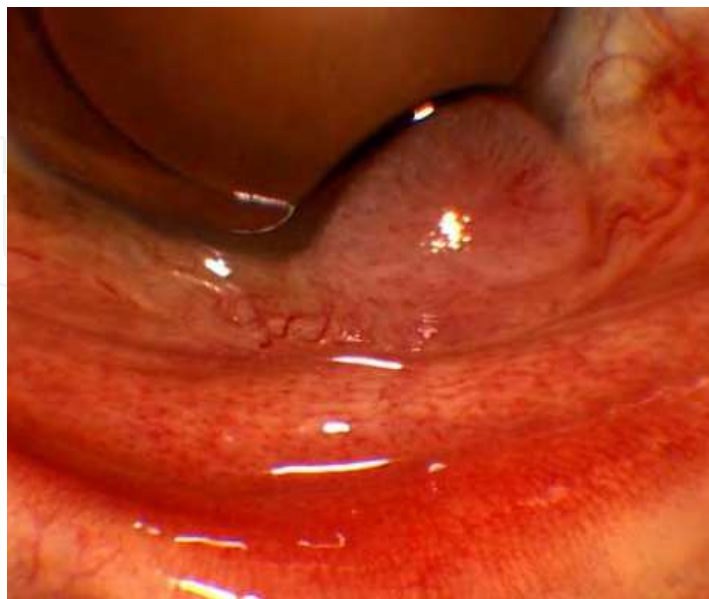

Fig. 3. CIN with papillomatous appearance at the exposed interpalpebral fissure affecting the limbus.

3.4 Fleshly lesions

Clinically, CIN appears as a fleshy, sessile, or minimally elevated lesion usually at the limbus in the interpalpebral fissure and less commonly in the forniceal or palpebral conjunctiva. The size of extension may be variable in each case. The presence of redness may simulate an inflammation. Extensive cases consist in a red gelatinous mass with vascular dilatations that may invade superior and nasal bulbar conjunctiva, including the caruncula, inferior conjunctiva and fornix invading tarsal conjunctiva and even corneal extension. Plaques of leukoplakia may also be present. (Erie et al, 1986), (Shields & Shields, 2004), (Huerva et al, 2006).

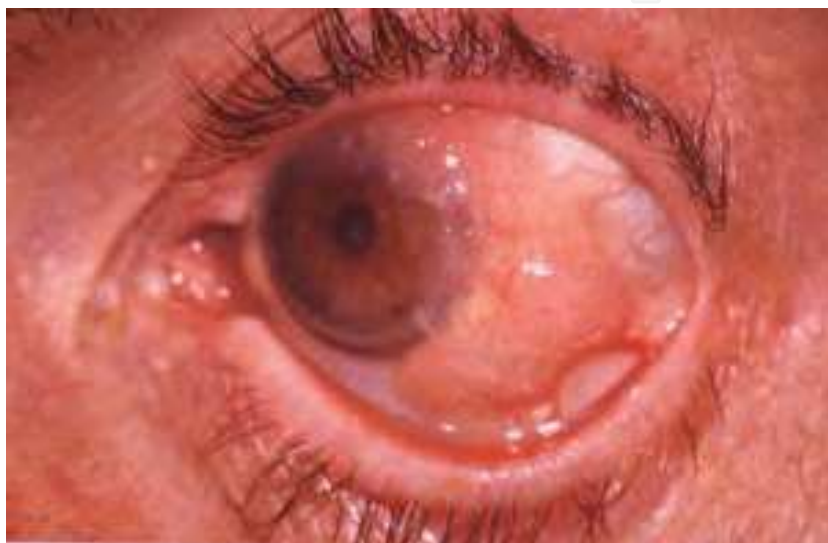

Fig. 4. Fleshy nodular gelatinous mass involving bulbar conjunctiva and limbus.

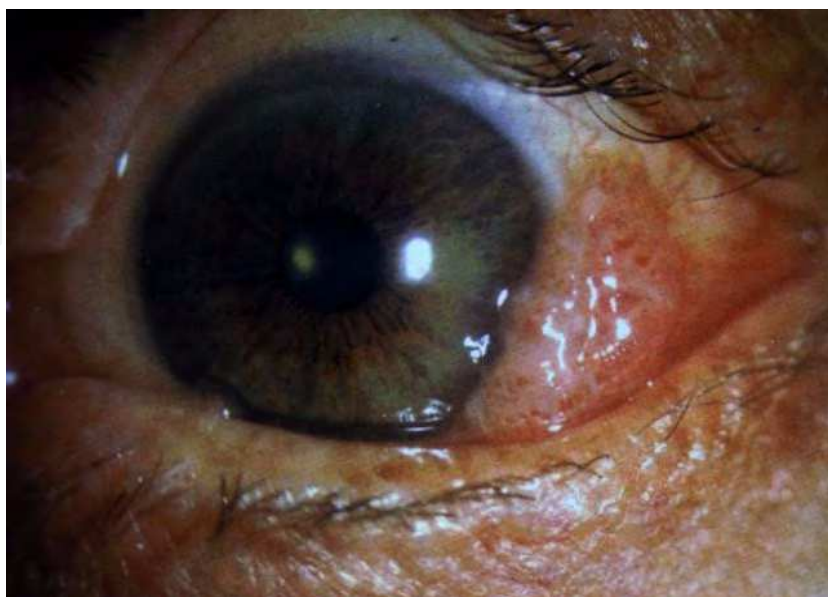


Fig. 5. Fleshy nodular mass at the interpalpebral bulbar conjunctiva.

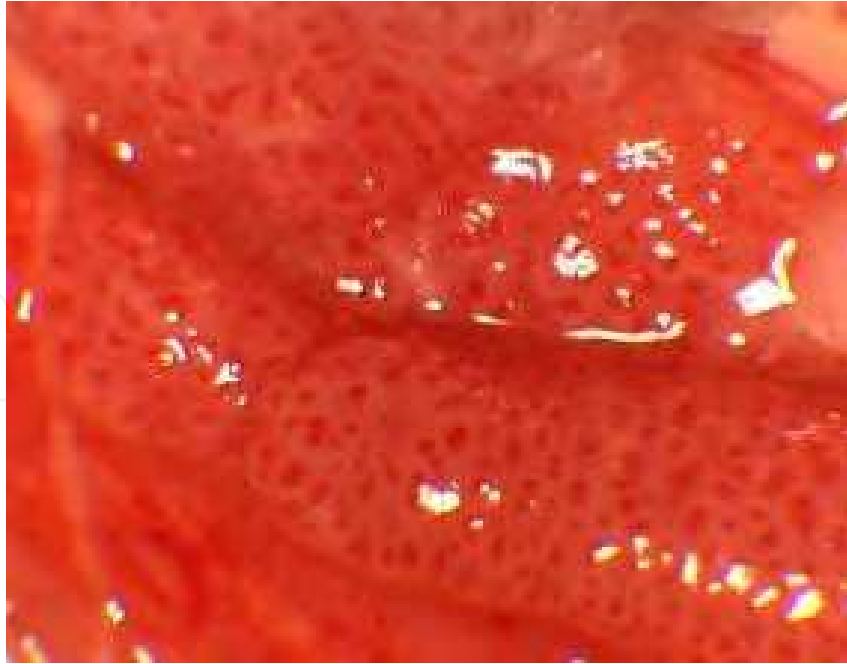


Fig. 6. Fleshy diffuse CIN affecting the inferior fornix resembling a chronic conjunctivitis.

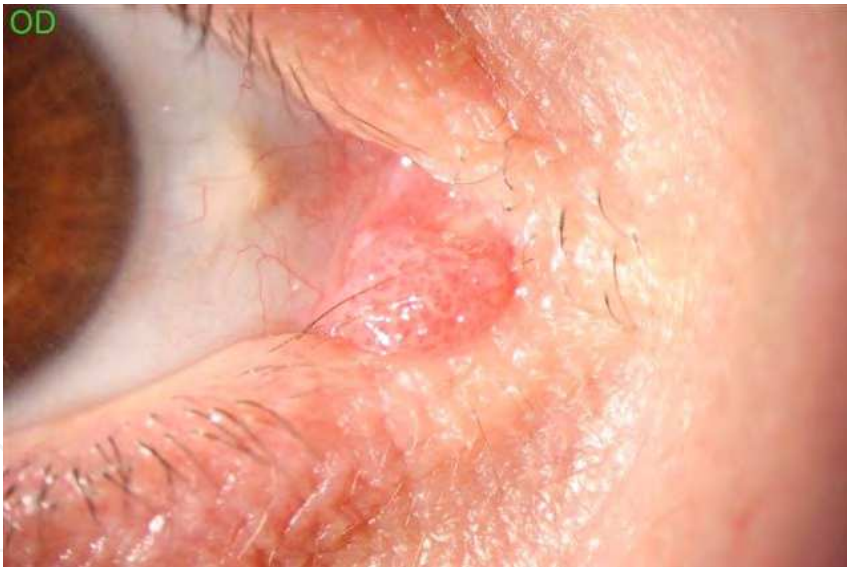


Fig. 7. Nodular fleshy CIN at the caruncle.

3.5 Corneal invasion (Conjunctiva-Cornea Intraepithelial Neoplasia) (CCIN)

This condition is called when the fleshy or papillomatous CIN lesions invading the superficial cornea. The lesions are well documented at the limbus occupying different degrees. Generally, in the extensive cases the cornea may be invaded (Huerva et al, 2006). The form of invasion may be variable: nodular, frothy vascular irregular extension and pedunculated and may simulate other conjunctival lesions as a pterigium or pannus (Shields & Shields, 2008).

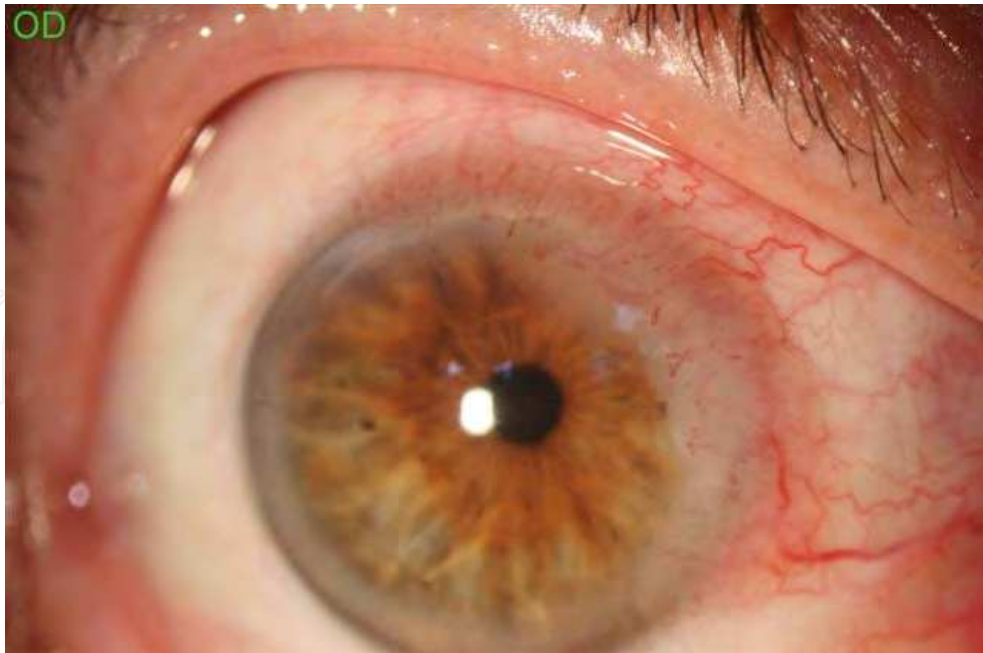

Fig. 8. CCIN: dysplasia in 180 degrees at the corneoscleral limbus resembling a corneal pannus.

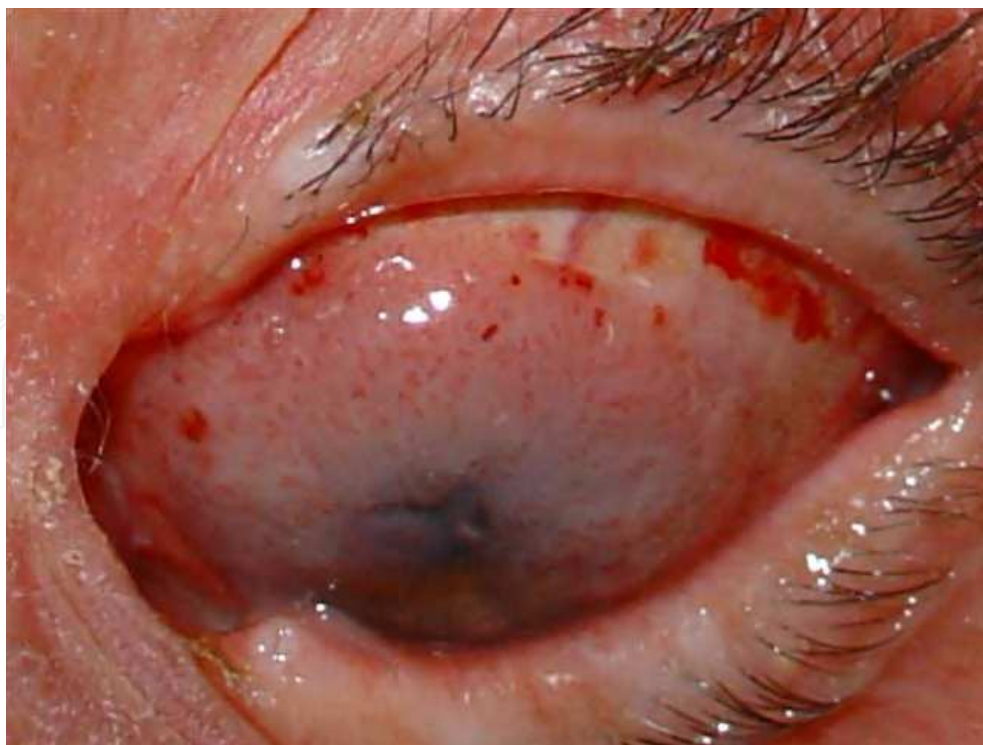

Fig. 9. CCIN. The tumor invade almost 3/4 size of the corneal surface.

3.6 Squamous cell carcinoma

Clinical presentation of invasive SCC is the same that the CIN. As the CIN, it is frequently observed at the interpalpebral region. Definitive diagnosis is only histopathologic (Shields & Shields, 2008).

There are some different histological types with very aggressive potential effect. Mucoepidermoid or adenoid SSC has an epidermal component and variable quantities of mucin. It often presents with inflammatory signs (Mauriello et al, 1997). Spindle cell SCC is composed by pleomorphic spindle cells. Both are very aggressive with high potential of ocular invasion and distant metastases (Shields & Shields, 2008).

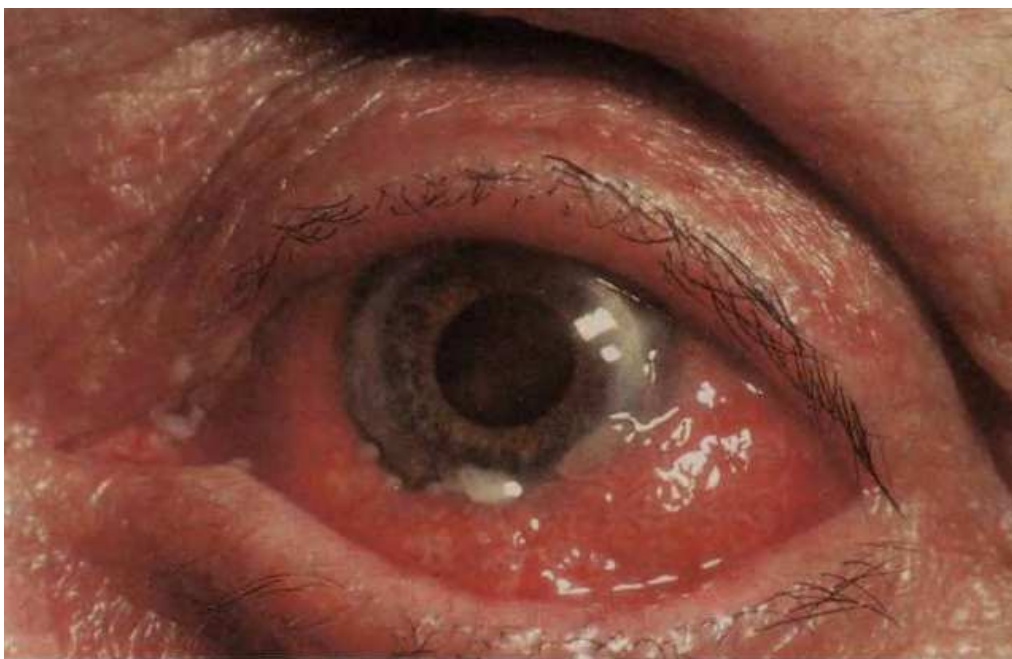

Fig. 10. Diffuse SCC involving the whole bulbar conjunctiva. Leukoplakic plaques are also present. Chronic conjunctivitis may be misdiagnosed. It clinically resembles a diffuse CIN. For definitive diagnosis a incisional biopsy is necessary.

4. Diferential diagnosis

Clinical differentiation between CIN and other limbal lesions is based on characteristic clinical features (Erie et al, 1986). However, it is generally admitted that the grade of dysplasia cannot be consistently determined on clinical inspection alone (Lee & Hirts, 1995). The main differential diagnoses for localized CIN include pinguecula, pterygium and squamous papilloma. The differential diagnosis of conjunctival amelanotic tumors includes CIN, invasive SCC, malignant melanoma and a variety of benign described entities, which include squamous papilloma, solar elastosis and epithelial hyperplasia, keratosis or reactive

atypia. Conjunctival pseudoepitheliomatous hyperplasia, keratoacantoma, and conjunctival hereditary benign intraepithelial dyskeratosis may be also considered in CIN differential diagnosis (Shields & Shields, 2008). In these cases the hyperkeratosis and inflammatory cells are present in the histologic samples. Solar elastosis is a pathognomonic sign in the pathological diagnosis of degenerative diseases of the conjunctiva such as pingueculae and pterygium. In a study, the clinical diagnosis of OSSN may be accurate in 89.5% of the cases (Tulwatana et al, 2003). Solar elastosis was found in 53.3% of OSSN cases compared to 3.3% of matched controls. Solar elastosis has also been identified as a risk factor for OSSN (Tulwatana et al, 2003). On this basis, the clinical diagnosis alone cannot distinguish benign conjunctival limbal tumors from OSSN or reliably exclude, albeit an uncommon diagnosis, amelanotic malignant melanoma. The difficulty in distinguishing clinically between pterygium and CIN was illustrated in a histopathological review of 533 cases of pterygium, in which 9.8% were shown to have evidence of dysplasia (Hirst et al, 2009). The capacity of a clinician to distinguish between grades of CIN, or between CIN and invasive SCC, is also limited (Rudkin et al, 2011). Clinical diagnosis of CIN may be increased by the use of exfoliation or impression cytology. However, histopathology of the excised tumor is the only reliable diagnostic method and it is generally accepted to be the most appropriate approach to lesions presumed to be CIN. The main hazard of clinical misdiagnosis of an excised benign limbal lesion is exposing the patient to unnecessary surgery. For an experienced ocular oncologist, the misdiagnosis of localized limbal OSSN occurs in 10.5% of cases (Rudkin et al, 2011).

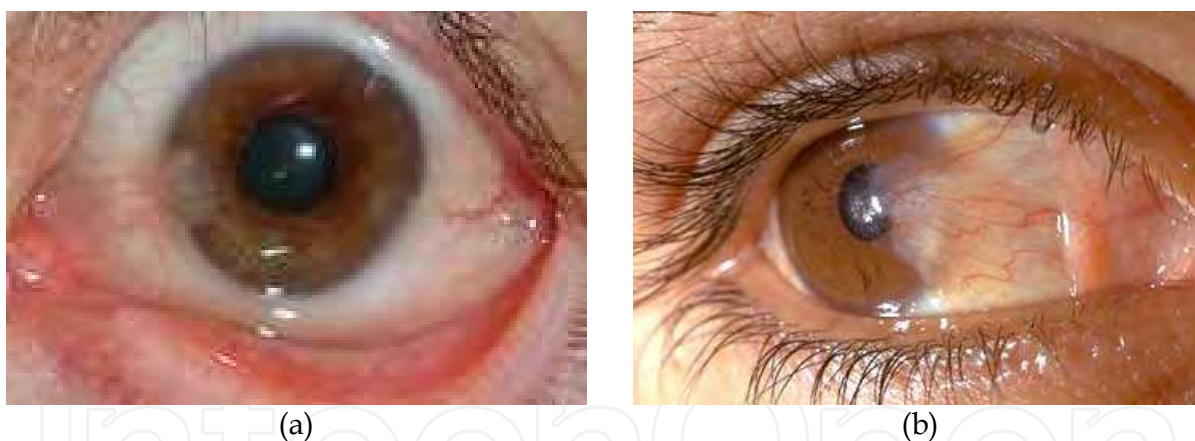


Fig. 11. Images of Pterigium (a,b) with corneal invasion may resembling in some a cases a CIN. On the other hand in already of 10 % of the cases may show epithelial conjunctival atypia.

5. Impression cytology in diagnosis of CIN

The management of ocular surface neoplasia depends on the ability to distinguish between benign, preinvasive, and invasive lesions. However, follow-up of suspicious lesions by repeated biopsies may cause complications such as scarring, lid deformity, limbal deficiency, and patient discomfort.

As it has been described, the clinical appearance of the lesion may be suggestive of CIN. However, a tissue biopsy is necessary to confirm the diagnosis. Because many patients with

primary or recurrent CIN may be treated with topical chemotherapy without surgical excision of the lesion, impression cytology has been used to confirm the diagnosis without performing histological evaluation of the excisional biopsy. Impression cytology is a simple technique for removing one to three superficial layers of the epithelium by applying collecting devices, either cellulose acetate filter papers or Biopore membrane device. Rates of positivity between 77 and 80% have been reported (Nolan et al, 1994), (Tole et al, 2001). The disadvantage is that the superficial nature of the sample, which sometimes only contains keratinized cells, may be falsely negative. Cytological assessment does not provide enough information regarding the deepest structure of the lesion, in particular, evidence of invasion. Abundance of surface keratin may make sampling inaccurate. Another limitation is that impression cytology may not distinguish *in situ* from minimally invasive disease, because only superficial cells are collected in the method. However, high-grade dysplasia in OSSN cytology findings have a high correlation with histology findings, and the presence of abundance dysplastic cells in cytology suggest preinvasive or invasive disease in subsequent histology (Tananuvat et al, 2008). Although impression cytology have a high sensitivity for the diagnosis of ocular surface squamous neoplasia, including CIN, there are still cases in which impression cytology yields false negative results. The keratotic surface of the lesion or the presence of dysplastic cells deep within the epithelium are the reason for these false negative results. Repeated consecutive applications of the collecting filter paper to the surface of CIN by approaching the deeper epithelium may result in higher sensitivity of the technique to confirm the diagnosis (Kheirkhah et al, 2011). For the diagnosis of CIN, the second and third applications of impression cytology may be significantly more sensitive than the first application. Consecutive repeated applications of the filter paper resulted in a significant higher sensitivity due to access to deeper epithelium. Keratinizing CIN lesions may result in a false negative impression cytology test due to the small number of cells present in the sample. It seems that keratinization leads to more false negative results at first application and repeated sampling in this population of CIN cases is more likely to result in subsequent positive due to the progressive elimination of the keratotic material.

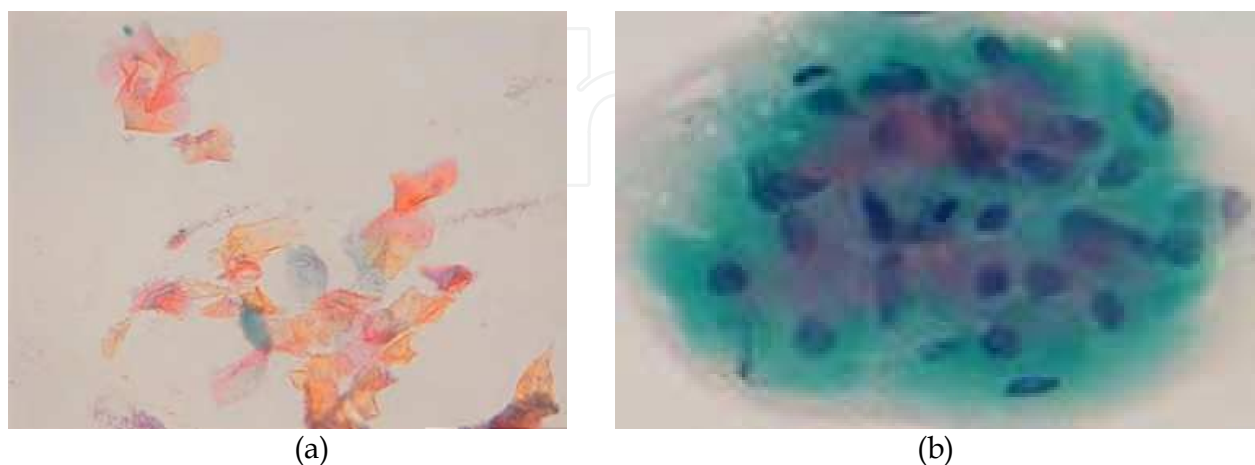


Fig. 12. Impression cytology from a CIN. Papanicolaou staining. A. False negative for CIN, squamous superficial keratinized material (a). Atypical dysplastic squamous cells from a CIN. Some pleomorphic and hiperchromatic nuclei (b).

In conclusion, repeated consecutive applications of impression cytology will lead to a more significant sensitivity for diagnosis in eyes with CIN, thereby obviating the need for excisional biopsy. An additional advantage of impression cytology is the preservation of limbal stem cells, which are located in the basal layer of the limbal epithelium and are responsible for renewal of corneal epithelium throughout life. In most cases of OSSN, the lesions affect predominantly the limbus and have a tendency to recur. Moreover, the technique may be used in the follow-up of patients after treatment to determine the recurrence of the disease, as well as the effects of treatment such as topical chemotherapy.

6. Histopathological findings

The definitive term of CIN or SCC corresponds to the histologic study. When the abnormal conjunctival epithelial cellular proliferation involves only partially the epithelium thickness is classified as mild CIN, a condition also called mild or moderate dysplasia. When it affects full thickness epithelium it is called severe CIN, a condition also called severe dysplasia. In these cases there may be an intact surface layer of cells. Where there are no longer normal surface cells then the process is termed carcinoma-in-situ. Histopathologically, mild CIN (dysplasia) is characterized by a partial thickness replacement of the surface epithelium by abnormal epithelial cells which lack of normal maturation. Severe CIN (severe dysplasia) is characterized by a nearly full-thickness replacement of the epithelium by similar cells. Carcinoma-in-situ represents full thickness replacement by abnormal epithelial cells (Shields & Shields, 2004). Squamous cell carcinoma is an extension of abnormal epithelial cells through the basement membrane to gain access to the conjunctival stroma and have grown in sheets or cords into the stromal tissue. A rare variant of squamous cell carcinoma of the conjunctiva is the mucoepidermoid carcinoma wich presents abundant mucous-secretory cells within cysts. Another rare variety is the spindle cell variant of squamous cell carcinoma that is likewise aggressive. Histopathologically, invasive squamous cell carcinoma is characterized by malignant squamous cell that have violated the basement membrane

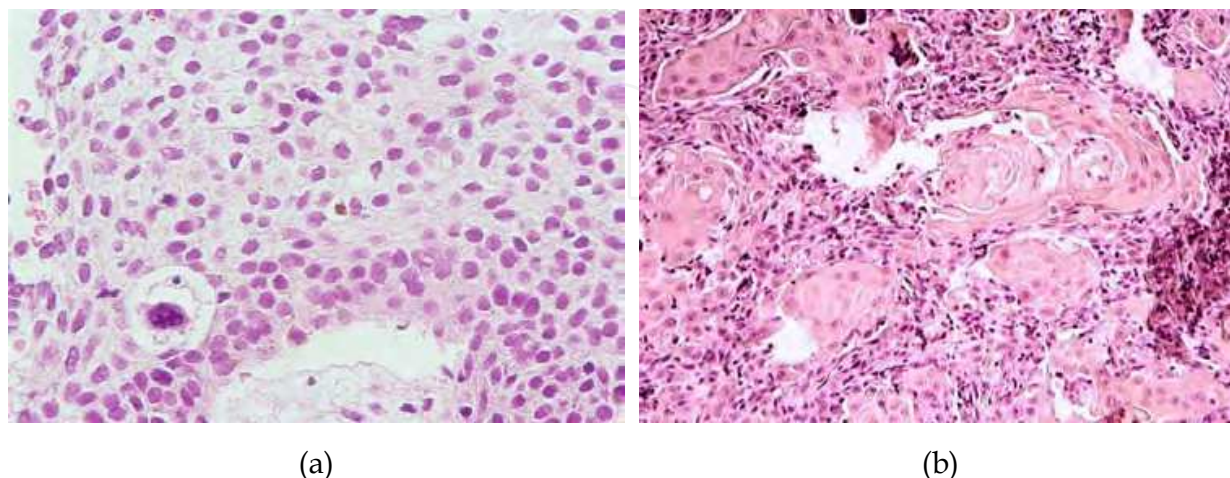


Fig. 13. Histological specimens. (a): CIN Grade 3. Total replacement of the epithelium by dysplastic cells. Hematoxylin-eosin x 40. (b): SCC, Displastic cell islets of squamous cells after invading the basement membrane, presence of keratotic perls. Hematoxylin-eosin x 10.

(Shields & Shields, 2004). According to the definition, CIN may be classified in four stages (Kheirkhah et al, 2011):

- **CIN grade I:** mild dysplasia limited to the basal one third of the thickness of the corneal or conjunctival epithelium.
- **CIN grade II:** moderate dysplasia confined to the basal two thirds of the corneal or conjunctival epithelium.
- **CIN grade III:** or SCC in situ: severe dysplasia that may involve the entire thickness of the corneal or conjunctival epithelium without invading the basement membrane.
- **Invasive SCC:** severe dysplasia with invasion through the basement membrane.

7. Human Papilloma Virus (HPV) detection

As it has been described in the chapter of etiologic factors, the presence of HPV in cases of CIN remains controversial. DNA of HPV may be detectable by in situ hybridization. HPV types 16 and 18, commonly detectable, in uterine cervix may also be detectable in CIN. However, in non neoplastic lesions and in apparently healthy conjunctiva it may also be detectable (Karcioglu & Issa, 1997). In African case series there is a high prevalence of DNA HPV 6 and 11, but not HPV 16 and 18 (Verma et al, 2008). On the other hand, in a series reported recently in Uganda, HPV 5 and 8 were the most common in nearly half of OSSN (Ateenyi-Agaba, et al, 2010). We have detected the presence of DNA HPV type 11. It is possible that different HPV associated to other risk factors may contribute to the development of CIN.

The presence of DNA HPV is not strictly necessary in the diagnosis of CIN. However, when it is possible its determination may clarify the role of these different types of virus in the development of CIN.

8. Staging for conjunctival intraepithelial neoplasia

CIN constitutes a localized malignant situation that, in absence of treatment, may growth progressively with possible transformation into SCC. It develops rarely metastases at distance or produces ocular, orbital or intracranial invasion. The clinical TNM classification of the conjunctival carcinoma is as follows (McGowan, 2009) :

Clinical classification (TNM):

Primary tumor (T)

TX Primary tumor cannot be assessed

T0 No evidence of primary tumor

Tis Carcinoma *in situ*

T1 Tumor 5 mm or less in greatest dimension

T2 Tumor more than 5 mm. in greatest dimension, without invasion of adjacent structures

T3 Tumor invades adjacent structures (excluding the orbit)

T4 Tumor invades the orbit with or without further extension

T4a Tumor invades orbital soft tissues, without bone invasion

T4b Tumor invades bone

T4c Tumor invades adjacent paranasal sinuses

T4d Tumor invades brain

Regional lymph nodes (N)

NX Regional lymph nodes cannot be assessed

N0 No regional lymph node metastasis

N1 Regional lymph node metastasis

Distant metastasis (M)

MX Distant metastasis cannot be assessed

M0 No distant metastasis

M1 Distant metastasis

According to this classification with the difference of clinical appearance, the cases of CIN may be: Tis, T1 or T2, N0 and M0.

9. Treatment

The management of CIN or SCC of the conjunctiva varies with the extent or recurrence of the lesion.

9.1 Surgical treatment

While the extent of the lesion determines the management of lesions in the limbal area involves alcohol epitheliectomy for the corneal component and partial lamellar scleroconjunctivectomy, with wide margins (4-5 mm) for the conjunctival component followed by freeze-thaw cryotherapy to the remaining adjacent bulbar conjunctiva (The no touch technique) (Shields & Shields, 2004). In some cases, microscopically controlled excision (Mohs surgery) may be performed at the time of surgery to ensure tumor free margins (Buus et al, 1994). Those tumors in the forniceal region can be managed by wide local resection and cryotherapy. Following surgical excision, large conjunctival defects may be successfully reconstructed with transpositional conjunctival flaps, free conjunctival grafts, oral mucosal grafts, and amniotic membrane grafts (Gündüz et al, 2006). In all cases, the full conjunctival component along with the underlying Tenon's fascia should be excised using the "no touch technique". A thin lamella of underlying sclera should be removed, in the limbal region, when the tumor is adherent to the globe. Intraoperative mitomycin-C (MMC) application has also been combined with excision of ocular surface neoplasia to prevent postoperative recurrences (Siganos et al, 2002). However, studies show a 53%

recurrence rate in pathologic studies which revealed involved margins and a 5% recurrence rate when clear margins are confirmed (Erie et al, 1986). In extensive lesions, surgical excision is difficult, and additional procedures have been employed. Extensive resections in very extensive CIN may produce a limbal stem deficiency (Huerva et al, 2006). Adjuvant radiation has the potential complications of cataracts, scleral necrosis, corneal rupture, scarring of the cornea and conjunctiva, moderate to severe conjunctivitis, and loss of eyelashes (Giaconi & Karp, 2003). For those patients with extensive tumors or those tumors that are recurrent, treatment with topical mitomycin C, 5-fluorouracil, or interferon alfa 2b have been employed.

9.2 Topical chemotherapy

Topical chemotherapy has a number of advantages over surgical approach. It enables to treat the entire ocular surface and is not dependent upon surgical margins. Primary treatment with a chemotherapeutic agent avoids potential complications of surgery, which can include scarring of the conjunctiva and cornea, limbal stem cell failure and incomplete excision of the lesion. Topical chemotherapies may be preferred over surgery by some patients, and when the patient refuse surgery, topical chemotherapies have been successfully used as primary treatment.

9.2.1 Topical mitomycin C (MMC)

For tumors with extensive involvement, where surgical removal bears significant risks for postoperative problems, topical MMC should have been considered for a long time. Topical MMC 0.02% or 0.04% 4 times daily in 7 to 14-day for two cycles (Shields & Shields, 2004) have been successfully employed for preoperative chemoreduction and to manage recurrent and residual tumors following surgical resection (Shields et al, 2002), (Frucht-Pery et al, 2002), (Shields et al, 2005). MMC had been effectively used to treat primary CIN, with reported success rates between 85% (Wilson et al, 1997) and 100% (Frucht-Pery & Rozenmam, 1994), (Ramos-Lopez et al, 2004). Another large study has shown topical MMC to be an efficient treatment of most, but not all cases, of CIN. Tumor regrowth occurred in approximately 17% of cases (Frucht-Pery et al, 1997). To avoid possible complications, the lacrimal punctal occlusion is mandatory during topical treatment. Chemoreduction with MMC cycles reduced the tumor size, especially in the surrounding thinner portions, and allowed for a subsequent limited surgical excision in all cases (Shields et al, 2005). Possible complications with topical MMC include superficial punctate epitheliopathy (Shields & Shields, 2004), conjunctival hyperemia, pain, allergy, corneal-scleral, melting disturbance of tear film stability, goblet cell loss, squamous metaplasia and limbal stem cells depletion (Frucht-Pery & Rozenmam, 1994), (Wilson et al, 1997), (Dogru et al, 2003), (Dudney & Malecha, 2004), (Khong & Muecke, 2006). Edema and endothelial apoptosis have been observed in experimental models (Chang, 2004). MMC toxicity seems to be dose dependent, occurring with the repetition of treatment cycles. Chemoreduction with topical MMC, followed by interferon alfa 2b (1 million IU/mL) 4 times daily, is an effective treatment in extensive CIN cases where surgical resection with safety margins is infeasible and corneal extension resection and the repetitive cycles of MMC adjunctive could cause a depletion of limbal stem cells and other commented side effects on the ocular surface (Huerva et al,

2006). In a follow-up of 18 months, topical Cyclosporine A (0,05%) combined with topical low dose of MMC (0,01%) four times a day for 12 weeks after positive margins following surgical excision showed no recurrence of the tumor (Tunc & Erbilin, 2006). In these cases Cyclosporine A has been employed by the antineovascular effect on the ocular surface.

9.2.2 5-Fluoracil (5-FU)

Other treatment options in the management of CIN include 5-fluorouracil (5-FU). However, compared with MMC, the experience with this alternative treatment is limited. Topical 1% 5-FU drops used 4 times daily for 2 to 4 days for each cycle and repeated at 30 to 45 day intervals have been reported. Following initial treatment, 4 patients were disease-free with a mean follow-up of 18.5 months. Of the 3 patients with tumor recurrence, 2 remained tumor-free following additional topical 5-FU treatment and 1 patient had a persistent tumor despite additional treatment with 5-FU and became tumor-free following treatment with topical MMC (Yeatts et al, 2000). No adverse reactions to pulsed treatment were reported. Another study using topical 1% 5-FU drops 4 times daily for 4 weeks in 8 eyes with recurrent, incompletely excised, and untreated conjunctival OSSN showed complete clinical regression at 3 months in all cases. OSSN recurred in 1 patient at 6 months but this was successfully treated with another course of 5-FU (Midena et al, 2000). Transient toxic keratoconjunctivitis that was noticeable with this treatment. Short-term complications include lid toxicity in 52% of patients, keratopathy in 11% and epiphora in 5% (Rudkin et al, 2010).

9.2.3 Interferon (INF) alpha 2b

Topical MMC and 5-fluorouracil have been used to reduce recurrence rates when used as an adjunct to surgical excision and as a primary treatment; however, their use can be associated with marked ocular surface toxicity. Topical (1.000.000 IU/ ml/ four times a day) or subconjunctival INF alfa 2b (3 million IU/ml/ weekly) have been employed to treat CIN. In general, topical INF alpha-2b is well tolerated. Subconjunctival administration presents more side effects as flu-like symptoms (fatigue, fever, myalgias, malaise) and mild liver disturbances (Huerva & Mangues, 2008). Local conjunctival injection and follicular conjunctivitis are the most frequently reported side effects (Schechter et al, 2002) after topical administration. Redness and increase of CIN volume without ocular discomfort have been reported in a case (Huerva et al, 2007). Fine, diffuse, clear epithelial microcysts in the cornea after instillation of topical interferon a-2b have recently documented in other case (Aldave & Nguyen, 2007).

Topical INF alpha 2-b, sometimes combined with subconjunctival INF alpha 2-b, seems to be effective as primary treatment for CIN, in recurrent cases, and also in retreatment after recurrence when INF has been used previously for a short period of time (Huerva & Mangues, 2008). Approximately, 9% of CIN treated with subconjunctival and/or topical INF alpha 2b showed recurrences, and 33 % of them were successfully retreated with topical INF alpha 2b (Huerva & Magues, 2008). Another one (16,6%) achieved complete remission after intraperioperative MMC (Hawkins et al, 1999). For INF alpha 2b topical treatment, the average time to complete tumor response is 11 weeks (range 2-59). For INF alpha 2b

subconjunctival and topical treatment, the average time to complete tumor response is 5.5 weeks (range 2-12), (Huerva & Mangues, 2008). Previous studies found the same observation (Karp et al, 2001). The time to clinical resolution using topical INF alpha 2-b was longer (11.6 weeks) than the combined intralesional and topical interferon (4.5 weeks), but that INF alpha 2b treatment involved fewer side effects. In general, it seems that the disadvantage with topical treatment is the long duration. We must emphasize the importance of long term follow-up for CIN patients because recurrences can occur anywhere from 33 days to 11.5 years (Tabin et al, 1997), although most recurrent CIN occurs within 2 years of initial excision (Schechter et al, 2005).

Many surgeons add adjunctive topical therapy to their surgical regimens for larger lesions (Stone et al, 2005). However, all sizes of lesions could be treated with topical INF alpha as the primary treatment because it is an effective, non-invasive treatment alternative to surgery that increases quality of life with low costs (Huerva et al, 2006), (Huerva et al, 2007), (Huerva et al, 2009). Actually, no clear consensus on the best way to manage the disorder has been established, because long-term, well designed studies are still needed. However, two recent studies have addressed the above questions and confirmed the effectiveness of this topical therapy for CIN. The first study (Schechter, et al, 2008) demonstrated total resolution of the tumor in 96.4% of cases treated with INF alfa 2b with a mean follow-up of 42.4 months. The second study (Sturges et al, 2008) demonstrated that topical treatment with INF and surgical excision have the same effectiveness as primary treatment for CIN for a mean follow-up of 35.6 months. The authors concluded that topical IFN alfa-2b and aggressive surgical excision can be considered equally effective as first choice for treating CIN. Topical INF alfa-2b has some advantages over conventional excision, including the reduction of risk to loose limbar stem cells secondary to surgical trauma and, thus, compromising the integrity of the ocular surface. This therapeutic mode can be recommended particularly for patients who reject any type of surgery, or mentally retarded patients in whom surgery is complicated as well as extended cases where an aggressive excision could cause the loss of limbar stem cells (Huerva, 2008).

Topical INF or subconjunctival INF remains a controversial issue. A recent report (Karp et al, 2010) concluded that subconjunctival 0.5 ml injection of 3 million IU IFN alfa 2b is a viable medical alternative for the treatment of ocular surface squamous neoplasia (OSSN) with a mean duration of follow-up of 55 months. The authors state that the advantages of perilesional INF alfa 2b injection include more rapid tumor resolution, ensured compliance, and perhaps more direct delivery to the tumor site when compared with topical INF drops. However, some patients may be apprehensive about receiving injections around the eye and may prefer eyedrops. A single weekly injection of INF may have better compliance than 4 eye-drops per day dosing for a mean of three months in many patients. Direct delivery to the tumor site may occur in well-localized lesions, while annular lesions or multifocal disease requires injection over the entire involved area, increasing the risk of conjunctival hemorrhage. By contrast, topical therapy is delivered to the entire ocular surface and has very good success rates. Topical therapy could be recommended for patients who reject any surgical procedure or those who are apprehensive about injections.

Weekly subconjunctival Pegilated INF alpha 2b might be an alternative in resistant cases of CIN or recurrent conjunctival papillomatosis avoiding a mutilating surgery (Tseng, 2009), (Karp et al, 2010).

9.2.4 Other treatment possibilities

Other treatment options in the management of conjunctival OSSN include topical retinoids, cidofovir and photodynamic therapy (PDT). Topical unguent of trans-reinoic acid (0,01%) showed complete resolution of CIN in 20% of cases, whereas 40% showed only partial response (España et al, 2003). This treatment may be then only adjuvant to surgery

Regression of diffuse conjunctival CIN was demonstrated following a 6 week course of topical cidofovir eyedrops (2.5 mg/ml) with later residual lesion after surgical excision (Sherman et al, 2002).

Following PDT, using verteporfin, a complete clinical CIN regression, supported with angiographic evidence, has been reported at 1 month, without any recurrence for a mean follow-up of 8.6 months (Barbazetto et al, 2004). Likewise, histopathological evidence showing tumor regression following treatment with PDT in a patient with in situ CIN has been reported (Sears et al, 2008).

10. References

- Aldave AJ, Nguyen A. Ocular surface toxicity associated with topical interferon a-2b. *Br J Ophthalmol* 2007;91: 1087-88.
- Ateenyi-Agaba C. Conjunctival squamous cell carcinoma associated with HIV infection in Kampala, Uganda. *Lancet* 1995; 345: 695-96.
- Ateenyi-Agaba C, Franceschi S, wabwire-Mangen F et al. Human papillomavirus infection and squamous cell carcinoma of the conjunctiva. *Br J Cancer* 2010; 102: 262-67.
- Bahattacharyya N, Wenokur RK, Rubin PA. Metastasis of squamous cell carcinoma of the conjunctiva. Case report and review of the literature. *Am J Otolaryngol* 1997; 18: 217-19.
- Barbazetto IA, Lee TC, Abramson DH. Treatment of conjunctival squamous cell carcinoma with photodynamic therapy. *Am J Ophthalmol* 2004; 138: 183-89.
- Buus DR, Tse DT, Folberg R, Buuns DR. Microscopically controlled excision of conjunctival squamous cell carcinoma. *Am J Ophthalmol* 1994; 117: 97-102.
- Chang SW. Early corneal edema following topical application of mitomycin-C. *J Cataract Refract Surg* 2004; 30: 1742-50.
- Chisi SK, Kollmann MKH, Karimurio J. Conjunctival squamous cell carcinoma in patients with Human Immunodeficiency Virus infection seen at two hospitals in Kenya. *East African Med J* 2006; 83: 267-70.
- Clifford GM, Gallus S, Herrero R, Munoz N, Snijders PJF, Vaccarella S, et al. Worldwide distribution of human papillomavirus types in cytologically normal women in the International Agency for Research on Cancer HPV prevalence surveys: a pooled analysis. *Lancet* 2005; 366: 991-98.

- Dogru M, Erturk H, Shimazaki J, Tsubota K, Gul M. Tear function and ocular surface changes with topical mitomycin (MMC) treatment for primary corneal intraepithelial neoplasia. *Cornea* 2003; 22: 627-39.
- Dudney BW, Malecha MA. Limbal stem cell deficiency following topical mitomycin C treatment of conjunctival-corneal intraepithelial neoplasia. *Am J Ophthalmol* 2004; 137: 950-51.
- Eng HL, Lin TM, Chen SY, et al. Failure to detect human papillomavirus DNA in malignant epithelial neoplasms of conjunctiva by polymerase chain reaction. *Am J Clin Pathol* 2002;117: 429-36.
- Erie JC, Campbell RJ, Leisegang TJ. Conjunctival and corneal intraepithelial and invasive neoplasia. *Ophthalmology* 1986; 93:176-83.
- Espana EM, Chodosh J, Mateo AJ, Di Pascuale MA, Tseng SC. Topical retinoids as a noninvasive treatment of conjunctival intraepithelial neoplasia. *Microcirugía Ocular* 2003, nº4: 1-7.
- Frucht-Pery J, Rozenmam Y. Mitomycin C therapy for corneal intraepithelial neoplasia. *Am J Ophthalmol* 1994; 117: 164-68.
- Frucht-Pery J, Sugar J, Baum J et al. Mitomycin C treatment for conjunctival-corneal intraepithelial neoplasia: a multicenter experience. *Ophthalmology* 1997; 104: 2085-93.
- Frucht-Pery J, Rozenman Y, Pe'er J. Topical mitomycin-C for partially excised conjunctival squamous cell carcinoma. *Ophthalmology* 2002; 109: 548-52.
- Giaconi JA, Karp CL. Current treatment options for conjunctival and corneal intraepithelial neoplasia. *Ocul Surf* 2003;1: 66-73.
- Grossniklaus HE, Green WR, Luckenbach M, Chan CC. Conjunctival lesions in adults. A clinical and histopathologic review. *Cornea* 1987; 6:78-116.
- Gündüz K, Uçakhan OO, Kanpolat A, Günalp I. Nonpreserved human amniotic membrane transplantation for conjunctival reconstruction after excision of extensive ocular surface neoplasia. *Eye* 2006; 20: 351-57.
- Hawkins AS, Yu J, Hamming NA, Rubenstein JB. Treatment of recurrent conjunctival papillomatosis with mytomycin C. *Am J Ophthalmol* 1999; 128:638-40.
- Herle RW, Durso F, Metzler JP, Varsa EW. Epibulbar squamous cell carcinomas in brothers with xeroderma pigmentosa. *J Pediatr Ophthalmol Strabismus* 1991; 28. 350-53.
- Hirst LW, Axelsen RA, Schwab I. Pterygium and associated ocular surface squamous neoplasia. *Arch Ophthalmol* 2009; 127: 31-2.
- Huerva V, Mateo AJ, Manges I, Jurjo C. Short-term mitomycin C followed by long-term interferon alpha 2 β for conjunctiva-cornea intraepithelial neoplasia. *Cornea* 2006; 25:1220-23.
- Huerva V, Sánchez MC, Manges I. Tumor-volume increase at beginning of primary treatment with topical interferon alpha 2-beta in a case of conjunctiva-cornea intraepithelial neoplasia. *J Ocul Pharmacol Ther* 2007;23:143-45.
- Huerva V, Manges I. Treatment of conjunctival squamous neoplasias with interferon alpha 2b. *J Fr Ophtalmol* 2008; 31: 317-25.
- Huerva V. Topical interferon alfa-2b or surgical excision for primary treatment of conjunctiva-cornea intraepithelial neoplasia. *Arch Soc Esp Oftalmol* 2009; 84: 5-6


- Huerva V, Mangués I, Schoenenberger JA. Interferon alpha 2b eyedrops as treatment of conjunctival intraepithelial neoplasia. *Farm Hosp* 2009; 33: 335-36.
- Kaimbo WA, Kaimbo D, Parys-Van Ginderdeuren R, Missotten L. Conjunctival squamous cell carcinoma and intraepithelial neoplasia in AIDS patients in Congo Kinshasa. *Bull Soc Belge Ophtalmol* 1998; 268: 135-41.
- Karcioglu ZA, Issa TM. Human papillomavirus in neoplastic and non-neoplastic conditions of the external eye. *Br J Ophthalmol* 1997; 81: 595-598.
- Karp CL, Scott IU, Chang TS, Pflugfelder SC. Conjunctival intraepithelial neoplasia: a possible marker for human immunodeficiency virus infection ?. *Arch Ophthalmol* 1996; 114: 257-61.
- Karp CL, Moor JK, Rosa RH Jr. Treatment of conjunctival and corneal intraepithelial neoplasia with topical interferon alpha-2b. *Ophthalmology* 2001; 108: 1093-98.
- Karp CL, Galor A, Chhabra S, Barnes SD, Alfonso EC. Subconjunctival/Perilesional recombinant interferon α 2b for ocular surface squamous neoplasia. *Ophthalmology* 2010; 117: 2241-46.
- Karp CL, Galor A, Lee Y, Yoo SH. Pegylated interferon alpha 2b for treatment of ocular surface squamous neoplasia: a pilot study. *Ocul Immunol Inflamm* 2010;18:254-60.
- Kheirkhah A, Mahbod M, Farzod F, Zavareh MK, Behrouz MJ, Hashemi H. Repeated applications of impression cytology to increase sensitivity for diagnosis of conjunctival intraepithelial neoplasia. *Br J Ophthalmol*. 2011 Apr 15. [Epub ahead of print].
- Khong JJ, Muecke J. Complications of mitomycin C therapy in 100 eyes with ocular surface neoplasia. *Br J Ophthalmol* 2006; 90: 819-22.
- Lee GA, Hirst LW. Ocular surface squamous neoplasia. *Surv Ophthalmol* 1995;39: 429-50.
- Lee GA, Williams G, Hirst LW, Green AC. Risk factors in the development of ocular surface epithelial dysplasia. *Ophthalmology* 1994; 101: 360-64.
- Lee GA, Hirst LW. Retrospective study of ocular surface squamous neoplasia. *Austr New Zealand J Ophthalmol* 1997; 25: 269-76.
- López García JS, Elosúa de Juan I, González Morales ML, de Pablo Martín C, Alvarez Lledo J, Martínez Garchitorea J. Squamous cell carcinoma of the conjunctiva with orbital invasion. *Arch Soc Esp Oftalmol*. 2000;75: 637-41.
- Mahomed A, Chetty R. Human immunodeficiency virus infection, Bcl-2, p53 protein, and Ki-67 analysis in ocular surface squamous neoplasia. *Arch Ophthalmol* 2002; 12: 554-8.
- Mauriello JA Jr, Napolitano J, McLean IW. Actinic keratosis and dysplasia of the conjunctiva: a clinicopathological study of 45 cases. *Can J Ophthalmol* 1996; 30: 312-16.
- Mauriello JA, Abdelsalam A, McLean IW. Adenoid squamous carcinoma of the conjunctiva - a clinicopathological study of 14 cases. *Br J Ophthalmol* 1997; 81: 1001-05.
- McGowan HD. Squamous Neoplasia of the Conjunctiva: The New TNM Classification by the American Joint Committee on Cancer (AJCC). *Ophthalmology Rounds* 2009; 7 (1) : 130-38E.
- McKelvie PA, Daniell M, McNab A, Loughnan M, Santamaria JD. Squamous cell carcinoma of the conjunctiva: a series of 26 cases. *British J Ophthalmol* 2002; 86: 168-73.

- Midena E, Angeli CD, Valenti M, de Belvis V, Boccato P. Treatment of conjunctival squamous cell carcinoma with topical 5-fluorouracil. *Br J Ophthalmol* 2000; 84: 68-72.
- Napora C, Cohen EJ, Genvert GI, et al. Factors associated with conjunctival intraepithelial neoplasia: a case control study. *Ophthalmic Surg* 1990; 21: 27-30.
- Nolan GR, Hirst LW, Wright RG, et al. Application of impression cytology to the diagnosis of conjunctival neoplasms. *Diagn Cytopathol* 1994;11: 246-49.
- Palefsky JM. Human papillomavirus- associated anogenital neoplasia and other solid tumors in human immunodeficiency virus-infected individuals. *Curr Opin Oncol* 1991; 3: 881- 85.
- Pizzarello ID, Jakobiec FA (1978). Bowen's disease of the conjunctiva: a misnomer, In: *Ocular and adnexal tumors*, Jakobiec FA (ed), pp. (553-571), Al. Aesculapius, Birmingham.
- Pola EC, Masanganise R, Rusakaniko S. The trend of ocular surface squamous neoplasia among ocular surface tumour biopsies submitted for histology from Sekuru Kaguvi Eye Unit, Harare between 1996 and 2000. *Central African Journal of Medicine* 2003 ;49:1-4.
- Poole TR. Conjunctival squamous cell carcinoma in Tanzania. *British J Ophthalmol* 1999; 83: 177-9.
- Porges Y, Groisman GM. Prevalence of HIV with conjunctival squamous cell neoplasia in an African provincial hospital. *Cornea* 2003;22: 1-4.
- Ramos-Lopez JF, Martinez-Costa R, Cisneros-Lanuza AL, et. al. Treatment of conjunctival intraepithelial neoplasia with topical mitomycin C 0,02%. *Arch Soc Esp Oftalmol* 2004; 79: 375-78.
- Rudkin AK, Dodd T, Muecke JS. The differential diagnosis of localised amelanotic limbal lesions: a review of 162 consecutive excisions. *Br J Ophthalmol*. 2011; 95: 350-54.
- Schechter BA, Schrier A, Nagler RS, Smith EF, Velasquez GE. Regression of presumed primary conjunctival and corneal intraepithelial neoplasia with topical interferon alpha-2b. *Cornea* 2002; 21: 6-11.
- Schechter BA, Nagler RS, Schrier A. Recurrent intraepithelial neoplasia treatment. *Ophthalmology* 2005, 112:1319.
- Schechter BA, Koreishi AF, Karp CL, Feuer W. Long-term follow-up of conjunctival and corneal intraepithelial neoplasia treated with topical interferon alfa-2b. *Ophthalmology* 2008; 115: 1291-296.
- Saornil MA, Becerra E, Méndez MC, Blanco G. Conjunctival tumors. *Arch Soc Esp Oftalmol*. 2009; 84: 7-22.
- Scott IU, Karp CL, Nuovo GJ. Human papillomavirus 16 and 18 expression in conjunctival intraepithelial neoplasia. *Ophthalmology* 2002;109: 542-7.
- Sears KS, Rundle PR, Mudhar HS, Rennie IG. The effects of photodynamic therapy on conjunctival in situ squamous cell carcinoma--a review of the histopathology. *Br J Ophthalmol* 2008; 92: 716-17.
- Sherman MD, Feldman KA, Farahmand SM, Margolis TP. Treatment of conjunctival squamous cell carcinoma with topical cidofovir. *Am J Ophthalmol* 2002; 134: 432-33.

- Shields CL, Naseripour M, Shields JA: Topical mitomycin C for extensive, recurrent conjunctival-corneal squamous cell carcinoma. *Am J Ophthalmol* 2002; 133: 601-06.
- Shields CL, Shields JA. Tumors of the conjunctiva and cornea. *Surv Ophthalmol* 2004; 49: 3-24.
- Shields CL, Demirci H, Karatza E, et al. Clinical survey of 1643 melanocytic and nonmelanocytic tumors of the conjunctiva. *Ophthalmology* 2004; 111: 1747-54.
- Shields CL, Demirci H, Marr BP, et al. Chemoreduction with topical Mytomycin C prior to resection of extensive squamous cell carcinoma of the conjunctiva. *Arch Ophthalmol* 2005; 123: 109-13.
- Shields CL, Manchandia A, Subbiah R, Eagle RC Jr, Shields JA. Pigmented squamous cell carcinoma in situ of the conjunctiva in 5 cases. *Ophthalmology* 2008; 115: 1673-78.
- Shields JA, Shields CL. (2008). *Eyelid, Conjunctival, and Orbital Tumors*. Wolters Kluwer, Lippincott, Williams & Wilkins, Philadelphia.
- Siganos CS, Kozobolis VP, Christodoulakis EV. The intraoperative use of mitomycin-C in excision of ocular surface neoplasia with or without limbal autograft transplantation. *Cornea*.2002; 21:12-16.
- Stone DU, Butt AL, Chodosh J. Ocular surface squamous neoplasia. *Cornea* 2005; 24:297-300.
- Sturges A, Butt AL, Lai JE, Chodosh J. Topical interferon or surgical excision for the management of primary ocular surface squamous neoplasia. *Ophthalmology* 2008; 115: 1297-1302.
- Sun EC, Fears TR, Goedert JJ. Epidemiology of squamous cell conjunctival cancer. *Cancer Epidemiol Biomarkers Prev*. 1997;6: 73-77.
- Tabin G, Levin S, Snibson G, Loughnan M, Taylor H. Late recurrences and the necessity for long-term follow-up in corneal and conjunctival intraepithelial neoplasia. *Ophthalmology* 1997; 104:485-92.
- Tananuvat N, Lertprasertsuk N, Mahanupap P, Noppanakeepong P. Role of Impression Cytology in Diagnosis of Ocular Surface Neoplasia. *Cornea* 2008; 27: 269-74.
- Timm A, Stropahl G, Schittowski M, et al. Association of malignant tumors of the conjunctiva and HIV infection in Kinshasa (D.R. Congo). First results. *Ophthalmologie* 2004; 101:1011-16.
- Tole D, Meckelvie P, Daniell M. Reliability of impression cytology for the diagnosis of ocular surface squamous neoplasia employing the Biopore membrane. *Br J Ophthalmol*. 2001;85: 154-58.
- Tseng SH. Conjunctival papilloma. *Ophthalmology* 2009; 116: 1013.
- Tulwatana W, Bhattarakosol P, Sansopha L, et al. Risk factors for conjunctival squamous cell neoplasia: a matched case-control study. *Br J Ophthalmol* 2003; 87: 396-98.
- Tunc M, Erbilin E. Topical Cyclosporine-A combined with Mitomycin C for conjunctival and corneal squamous cell carcinoma. *Am J Ophthalmol* 2006; 142: 673-75.
- Tuppurainen K, Raninen A, Kosunen O, et al. Squamous cell carcinoma of the conjunctiva. Failure to demonstrate HPV DNA by in situ hybridization and polymerase chain reaction. *Acta Ophthalmol (Copenh)* 1992; 70: 248-54.
- Verma V, Defan, S, Sieving P, Chan CC. The role of infectious agents in the etiology of ocular adnexal neoplasia. *Surv Ophthalmol*. 2008; 53: 312-331.

- Waddell KM, Lewallen S, Lucas SB, Atenyi-Agaba C, Herrington CS, Liomba G. Carcinoma of the conjunctiva and HIV infection in Uganda and Malawi.. *Br J Ophthalmol* 1996;80: 503-8.
- Wilson MW, Hungerford JL, George SM, Madreperla SA. Topical Mitomycin C for the treatment of conjunctival and corneal epithelial dysplasia and neoplasia. *Am J Ophthalmol* 1997; 124: 303-11.
- Yeatts RP, Engelbrecht NE, Curry CD, Ford JG, Walter KA. 5-Fluorouracil for the treatment of intraepithelial neoplasia of the conjunctiva and cornea. *Ophthalmology* 2000; 107:2190-95.

IntechOpen



Intraepithelial Neoplasia

Edited by Dr. Supriya Srivastava

ISBN 978-953-307-987-5

Hard cover, 454 pages

Publisher InTech

Published online 08, February, 2012

Published in print edition February, 2012

The book "Intraepithelial neoplasia" is till date the most comprehensive book dedicated entirely to preinvasive lesions of the human body. Created and published with an aim of helping clinicians to not only diagnose but also understand the etiopathogenesis of the precursor lesions, the book also attempts to identify its molecular and genetic mechanisms. All of the chapters contain a considerable amount of new information, with an updated bibliographical list as well as the latest WHO classification of intraepithelial lesions that has been included wherever needed. The text has been updated according to the latest technical advances. This book can be described as concise, informative, logical and useful at all levels discussing thoroughly the invaluable role of molecular diagnostics and genetic mechanisms of the intraepithelial lesions. To make the materials easily digestible, the book is illustrated with colorful images.

How to reference

In order to correctly reference this scholarly work, feel free to copy and paste the following:

Valentín Huerva and Francisco J. Ascaso (2012). Conjunctival Intraepithelial Neoplasia – Clinical Presentation, Diagnosis and Treatment Possibilities, Intraepithelial Neoplasia, Dr. Supriya Srivastava (Ed.), ISBN: 978-953-307-987-5, InTech, Available from: <http://www.intechopen.com/books/intraepithelial-neoplasia/conjunctival-intraepithelial-neoplasia-clinical-presentation-diagnosis-and-treatment-possibilities>

INTECH
open science | open minds

InTech Europe

University Campus STeP Ri
Slavka Krautzeka 83/A
51000 Rijeka, Croatia
Phone: +385 (51) 770 447
Fax: +385 (51) 686 166
www.intechopen.com

InTech China

Unit 405, Office Block, Hotel Equatorial Shanghai
No.65, Yan An Road (West), Shanghai, 200040, China
中国上海市延安西路65号上海国际贵都大饭店办公楼405单元
Phone: +86-21-62489820
Fax: +86-21-62489821

© 2012 The Author(s). Licensee IntechOpen. This is an open access article distributed under the terms of the [Creative Commons Attribution 3.0 License](#), which permits unrestricted use, distribution, and reproduction in any medium, provided the original work is properly cited.

IntechOpen

IntechOpen