9

Relevance of Autoantibodies for the Classification and Pathogenesis of Neurological Diseases

Simone Mader[1], Benjamin Obholzer[2] and Markus Reindl[1]
[1]*Clinical Department of Neurology, Innsbruck Medical University*
[2]*University of Innsbruck*
Austria

1. Introduction

In the last decade research on autoantibodies in neurological diseases of the central nervous system (CNS) has been very successful. An increasing number of autoantibodies and their target antigens have been detected, supporting stratification of patients and enabling specific treatment. The detection of autoantibodies depends on the assay used, as antibody binding requires the native conformation of the antigen. Although cumulative data is suggesting an important role of B cells and antibodies in Multiple Sclerosis (MS), numerous studies failed to identify specific biomarkers for MS (Figure 1). Even though several clinical, immunological and radiological studies tried to discover risk factors for disease progression, it remains an open issue to predict the individual disease course. However, recently autoantibodies have been discovered in some rare CNS demyelinating disease closely resembling MS (Table 1). Particularly Neuromyelitis Optica (NMO) gained enormous interest due to the discovery of autoantibodies targeting the water channel protein aquaporin-4 (AQP4) (Lennon et al., 2004; Lennon et al., 2005), which is expressed on astrocytic endfeet at the blood brain barrier (Nicchia et al., 2004) (Figure 1). This inflammatory demyelinating disease represents itself with optic neuritis and longitudinally extensive transverse myelitis (Wingerchuk et al., 1999) and was long considered as a severe variant of MS. Due to the detection and validation of this highly sensitive and specific biomarker, NMO is now regarded as a separate disease entity to MS. Consequently, the anti-AQP4 antibody serostatus was included into the diagnostic criteria of NMO (Jarius et al., 2007; Wingerchuk et al., 2007). Compared to MS, patients with NMO have a worse prognosis and require different treatment strategies according to the dominant humoral immunopathogenesis. With the advent of anti-AQP4 antibodies as biomarkers in NMO spectrum disorders (NMOSD), different NMO antibody assays have been developed, whereby cell based assays using the M23 isoform of AQP4 yield highest sensitivity (Takahashi et al., 2007; Waters & Vincent, 2008; Mader et al., 2010). Despite the high percentage of anti-AQP4 IgG positive NMO patients, various studies described a lack of these autoantibodies in a cohort of NMO patients, which we will critically discuss in this chapter. It remains an open question whether these patients form their own subgroup of NMO patients or if the antibodies are not detected due to a sensitivity problem of the applied assays. Moreover, we will address

the relevance of autoantibodies for the classification of neurological diseases and discuss novel findings of a potential involvement of T cells in NMO.

	MS	NMO	ADEM
Prevalence	100 / 100,000	1 / 100,000	1 / 100,000
Female : Male ratio	3 : 1	9 : 1	1 : 2
Disease onset	20-30 years	40 years	Childhood
Disease course	Relapsing-remitting progressive	Relapsing-remitting	Monophasic, recurrent
Clinical symptoms	Variable	Optic neuritis, myelitis	Encephalopathy, multifocal
Brain MRI	Multiple white matter lesions	Normal or atypical for MS	Multifocal large bilateral lesions
Spinal MRI	Short-segment (<3) lesions	Long-segment (>3) lesions	Confluent
CSF IgG OCB +	Frequent (>90%)	Rarely	Rarely
Relapse treatment	Intravenous high-dose methylprednisolone, plasma exchange		
Interval treatment	IFN-ß, GA, Tysabri, Fingolimod, AZT	AZT + steroids, Rituximab	None
Environmental triggers	Infections, Vitamin-D, smoking	Unknown	Infection, vaccination
Diagnostic marker		AQP4-IgG	MOG-IgG

Table 1. Important human inflammatory demyelinating diseases. IFN-ß = interferon-beta, GA = glatiramer acetate, AZT = azathioprine, MRI = Magnetic resonance imaging, OCB = oligoclonal bands.

Controversial results regarding the detection of autoantibodies to myelin oligodendrocyte glycoprotein (MOG) in patients with MS have confused researchers for several years. Latest findings showed increased anti-MOG antibody titers in a subgroup of patients with acute disseminated encephalomyelitis (ADEM) and childhood MS, but not in adult MS (O'Connor et al., 2007; Brilot et al., 2009; Di Pauli et al., 2011; Lalive et al., 2011). The target antigen MOG is expressed on the outer surface of the myelin sheath (Figure 1) and can only be detected using cell based assays expressing MOG on their surface. Early stratification from MS is of great relevance as ADEM is usually a self-limiting disease. However, due to the high number of anti-MOG antibody negative ADEM patients, early diagnosis remains challenging in some cases.

An early detection of autoantibodies to the NMDA (*N*-methyl *D*-aspartate) receptor is crucial in anti-NMDA-receptor encephalitis, an acute form of encephalitis, which can have a neuropsychiatric presentation, seizures, dyskinesias or autonomic instability (Dalmau et al., 2007). This disease is potentially reversible if it is recognized and treated as early as possible. In paraneoplastic courses a removal of the tumour is mandatory, but NMDA-receptor encephalitis can also be non-paraneoplastic and affect both genders. Detection of antibodies to the neuronal cell surface antigen NMDA-receptor (NMDA-R, Figure 1) in serum of patients supported a better understanding of the disease pathomechanism. In this chapter we will report on the latest findings of autoantibodies in CNS diseases, primarily focusing on anti-AQP4 antibodies in NMO, the relevance of anti-MOG antibodies in ADEM and MS and antibodies to NMDA-R in anti-NMDA-receptor encephalitis.

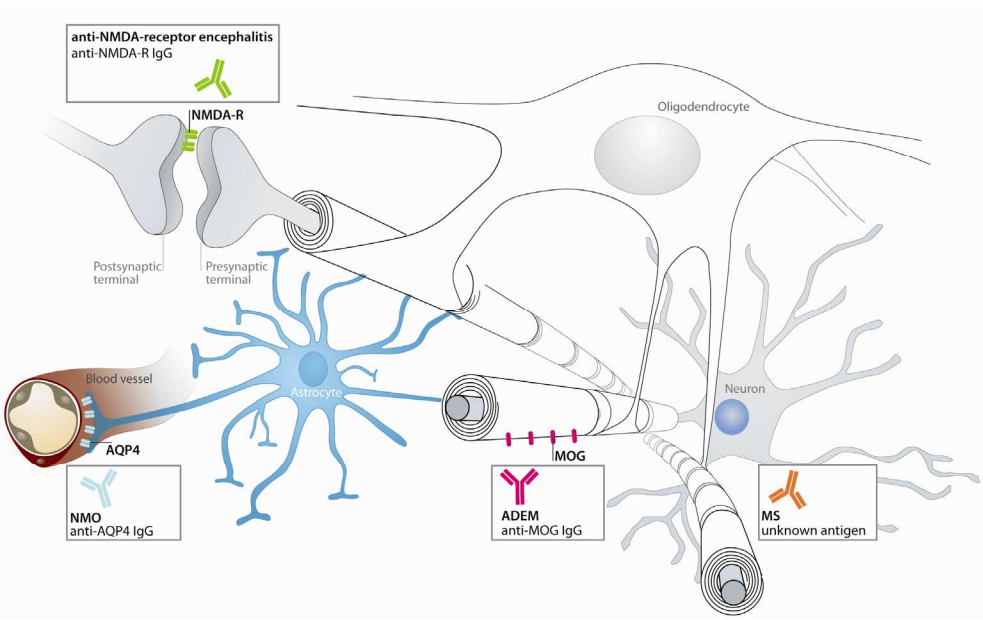

Fig. 1. Discovery of autoantibodies and their target antigens in different CNS diseases.

2. B cells and antibodies in MS

MS is the most frequent inflammatory demyelinating disease in young adults with a high risk of future disability and a heterogeneous clinical presentation (Noseworthy et al., 2000). Approximately 2.5 million people are affected, experiencing different disease courses. In the majority of patients (85-90%), the disease follows a relapsing–remitting course (RR-MS), characterized by acute relapses and subsequent complete or incomplete remission (Sospedra & Martin, 2005). RR-MS patients often convert into a secondary progressive disease course (SP-MS) (Sospedra & Martin, 2005). In contrast, a minority of patients suffer from the primary-progressive disease course (PP-MS, 10-15%) with a steady disease progression (Sospedra & Martin, 2005). Although the etiology of MS remains unresolved, currently it is believed that components of the myelin sheath are attacked by autoreactive T cells involving the cellular and humoral immune system (Sospedra & Martin, 2005). This infiltration of inflammatory cells within the CNS results in inflammation, thus leading to demyelination of the myelin sheaths, which cover the nerve fibers. Brain MRI shows typically multiple white matter lesions, with frequent development of new lesions. In the last decade, increasing research is focusing on the relevance of B cells and antibodies in MS, investigating their role and contribution in the initiation and propagation of inflammatory demyelinating processes at different disease stages (Figure 2).

In at least a subset of MS patients, pathogenic antibodies are believed to cause demyelination and axonal loss. This resulted in an extensive research in order to identify the still unknown target antigen. The detection of intrathecal IgG synthesis and the occurrence of oligoclonal bands (OCB) in the CSF of more than 90% of MS patients supports the impact

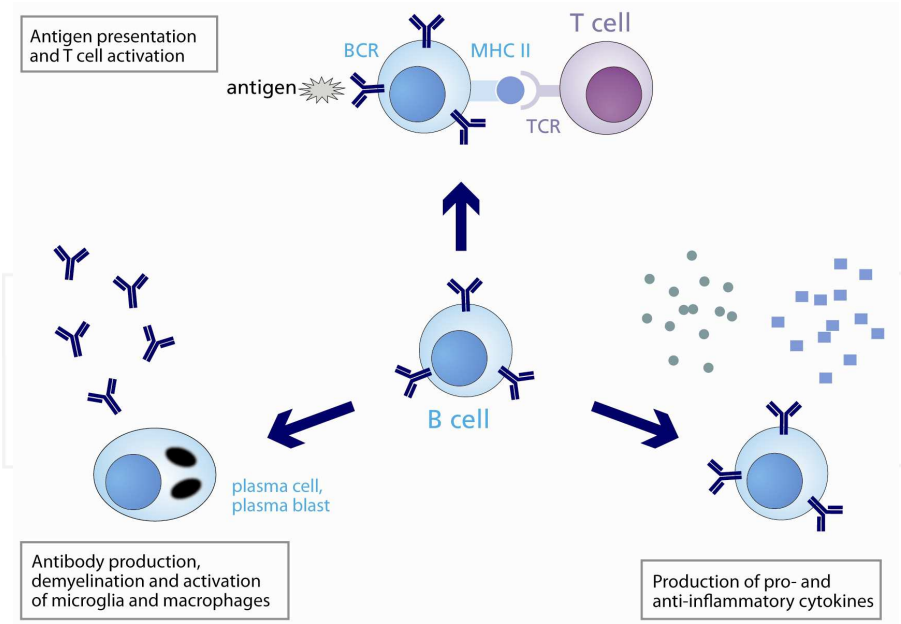

Fig. 2. Increasing evidence suggests an important role of B cells in MS. Currently, research is focusing on their relevance for antigen presentation and T cell activation, production of cytokines and antibodies.

of humoral immune responses in the pathogenesis of MS (Kabat et al., 1948). This seminal finding in 1948 is still an immunological hallmark for the disease, with the incorporation of OCB as diagnostic marker for MS (Freedman et al., 2005). However, OCBs are not unique for MS, as they are commonly detected in infectious diseases (Freedman et al., 2005), underlining the urgent need for specific biomarkers. A central role for B cells in the disease pathology can be attributed to studies showing a deposition of antibodies and complement in acute MS lesions (Lucchinetti et al., 2000) and histopathological studies confirming an antibody mediated demyelination (Lucchinetti et al., 1996; Storch et al., 1998) . Furthermore, clonally expanded B lymphocytes were discovered in chronic MS plaques and in the CSF of MS patients (Qin et al., 1998; Colombo et al., 2000; Owens et al., 2003). Latest studies highlight the role of B cells in the disease pathogenesis, as B cell depletion with the chimeric anti-CD20 monoclonal antibody rituximab had an impact on reduced inflammatory brain lesions in MS patients (Hauser et al., 2008). Nevertheless, there is a lack of unique biomarkers for MS, although numerous studies have focused on the presence of autoantibodies against potential antigens of the myelin sheath (Figure 3) and infectious agents in serum and CSF of patients (Reindl et al., 2006).

2.1 Anti-MOG antibodies and MS

One promising potential candidate as target antigen for MS is the myelin oligodendrocyte glycoprotein (MOG), a CNS specific antigen, which has been studied for several decades now. This transmembrane protein is localized on the outer membrane of myelin sheaths and oligodendrocytes (Figure 3) (Brunner et al., 1989).

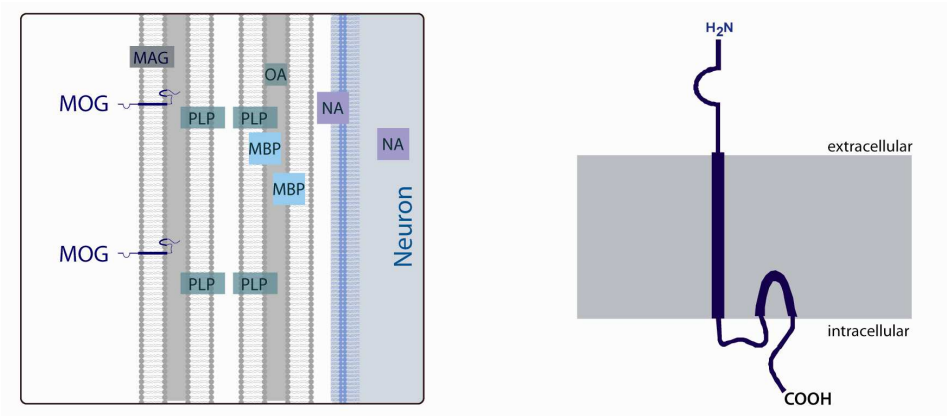

Fig. 3. MOG is expressed on the outer myelin surface.

Anti-MOG antibodies are pathogenic *in vitro* (Kerlero de Rosbo et al., 1990) and *in vivo*, as immunization with the MOG protein induces severe experimental autoimmune encephalomyelitis (EAE), which is commonly used as animal model for MS (Linington et al., 1993; Amor et al., 1994; Adelmann et al., 1995; Genain et al., 1995; Weissert et al., 1998). Immunization of MOG in adjuvant or adoptive transfer of activated myelin-specific T cells results in a MS like pathology in EAE (Goverman, 2009). Anti-MOG antibodies are proposed to augment disease severity by enhancing T cell and macrophage initiated demyelination (Zhou et al., 2006). In addition to their relevance in animal models, anti-MOG autoantibodies were discovered in active MS brain lesions (Genain et al., 1999), yet their presence in the CSF and serum of MS patients remains controversial and there are ongoing studies trying to solve these conflicting outcomes (Reindl et al., 2006). Following a publication of our group showing that increased serum anti-MOG and anti-MBP IgM antibodies in patients with clinically isolated syndrome (CIS), the most common first manifestation of MS, predict early conversion to clinically definite MS (Berger et al., 2003), numerous other studies were performed with correlations ranging from highly significant (Greeve et al., 2007; Tomassini et al., 2007), significant in a subanalysis (Rauer et al., 2006; Kuhle et al., 2007a) or not significant at all (Rauer et al., 2006; Kuhle et al., 2007a; Kuhle et al., 2007b). Possible explanations for this controversy could be linked to discrepancies in antibody assays, study designs and the investigated populations (Bar-Or & Antel, 2008). Former studies used mainly Western Blot, ELISA and liquid phase assays for the analysis of anti-MOG antibodies, which detect primarily linear epitopes of the MOG protein or partially refolded MOG. These assays were performed using bacterially expressed fragments of the MOG protein (MOG^{1-125}). However, binding of pathogenic serum anti-MOG antibodies might require native MOG with its posttranslational modifications. As the commonly used Western Blot and ELISA techniques led to inconsistent results, new assays were developed detecting conformational epitopes of MOG. Therefore, cell-based assays were used reflecting the correct formation and glycosylation of native MOG in the human CNS. Increased levels of autoantibodies to native MOG were observed in MS patients during relapse and in SP-MS, compared to patients in remission and controls when performing an ELISA coated with native MOG expressed by eukaryotic cells (Gaertner et al., 2004). A higher frequency of antibodies to native MOG was detected using cell lines expressing full

length human MOG (Lalive et al., 2006; Zhou et al., 2006). Although both studies used cell based assays, the frequency of anti-MOG antibodies within the MS disease course varied in both studies. Lalive and colleges reported increased titers of serum anti-MOG antibodies in patients with CIS, RR-MS and to a smaller extend in SP-MS, but not in healthy controls or PP-MS patients (Lalive et al., 2006). This is in contrast to a study of Zhou, observing the highest frequency of pathogenic autoantibodies to MOG in PP-MS patients using a flow cytometry-based assay. Moreover, Zhou and colleges demonstrated a pathogenic role of human anti-MOG antibodies *in vitro* and *in vivo* following injection into susceptible rat models (Zhou et al., 2006). Summarizing, the relevance of anti-MOG antibodies in MS remains controversial. Latest findings using a novel tetramer radioimmunoassay indicated the presence of conformation dependent anti-MOG antibodies is a subset of pediatric patients with acute disseminated encephalomyelitis (ADEM) and pediatric MS, but rarely in adult onset MS (O'Connor et al., 2007).

2.2 High titer anti-MOG antibodies in ADEM patients

ADEM is a rarely occurring inflammatory demyelinating disease of the CNS, brain and spinal cord, with an unknown relationship to MS. In patients with ADEM, acute or subacute multifocal large bilateral white matter lesions, frequently involving deep grey matter regions are accompanied by the occurrence of encephalopathy (Mikaeloff et al., 2004; Krupp et al., 2007). Although guidelines have been published to support the diagnosis of ADEM, diagnosis can be complicated, as exact diagnostic criteria are missing. Thus, the incidence remains to be investigated. Some publications suggest a prevalence rate of 0.8 per 100,000 affected patients per year (Leake et al., 2004). Whereas some reports describe no gender predisposition (Dale et al., 2000; Leake et al., 2004), most studies indicate a slight male preponderance in ADEM patients (Pavone et al., 2010). Although the majority of patients with ADEM follow a monophasic disease course, recently recurrent or multiphasic forms have been described with a lower incidence rate (Rust, 2000; Hynson et al., 2001). ADEM commonly occurs after a vaccination (post-vaccination encephalomyelitis) or infection (post-infection encephalomyelitis). In a study of Tenembaum, analyzing 84 pediatric ADEM patients, neurological disturbances occurred in 74% of patients following vaccination or infection (Tenembaum et al., 2002). ADEM is more often described in pediatric patients and juveniles (Leake et al., 2004), however, adult cases have also been reported (Schwarz et al., 2001). In contrast to the persistent disease course of MS, 57-89% of ADEM patients show complete recovery (Dale et al., 2000; Tenembaum et al., 2002). Furthermore, acute treatment with corticosteroids, immunoglobulins and plasma exchange often results in amelioration of ADEM patients, for which reason a biomarker is of high relevance in order to stratify MS and ADEM. Primarily at disease onset, ADEM can be misdiagnosed as CIS (Mikaeloff et al., 2007). The International Consensus criteria of 2007 can serve as guidelines for diagnosing CIS or ADEM (Krupp et al., 2007). Recently, a retrospective study was published analyzing the role of MRI in 28 children with MS and 20 ADEM patients (Callen et al., 2009). Herby, Callen et al. demonstrated a lower age of onset for ADEM patients compared to pediatric MS. This study invented new MRI diagnostic criteria to help differentiating RR-MS from monophasic ADEM at disease onset, yielding a high sensitivity (81%) and specificity (95%) (Callen et al., 2009). Contrary to MS which is typically associated with the development of new lesions, ADEM lesions usually resolve or show residual findings (Kesselring et al., 1990). Therefore, a follow-up MRI within a time period not shorter than 6 months is helpful for diagnosis (Kesselring et al., 1990). Analysis of CSF can support the diagnosis, as OCB are

infrequently detected in patients with ADEM (Stuve et al., 2005; Franciotta et al., 2008), yet a biomarker with high specificity is warranted. Recently, ADEM has attracted rising interest due to the discovery of anti-MOG autoantibodies in a subset of patients (O'Connor et al., 2007). In their study, O`Connor and colleges used a tetramer radioimmunoassay and detected serum antibodies directed to folded MOG tetramer in patients with ADEM in higher concentrations compared to adult MS cases (O'Connor et al., 2007). This observation was confirmed by several other publications (Brilot et al., 2009; Di Pauli et al., 2011; Lalive et al., 2011). Serum antibodies to native MOG were most commonly reported in pediatric ADEM patients. Although, a recent study of our group detected native MOG autoantibodies predominantly in children, we additionally observed few adult anti-MOG antibody positive ADEM cases (Di Pauli et al., 2011). Furthermore, we performed longitudinal analysis of anti-MOG antibodies and showed that a decrease of anti-MOG antibodies in ADEM patients was associated with a more favorable clinical outcome (Di Pauli et al., 2011). Anti-MOG IgG was detected in the CSF of high titer seropositive patients, suggesting a rather peripheral production of antibodies directed to MOG (Di Pauli et al., 2011). Even though anti-MOG antibodies might support the diagnosis of ADEM in a subset of patients, additional biomarkers are warranted for the remaining large proportion of anti-MOG antibody negative ADEM patients. Furthermore, the relevance of ADEM specific high titer anti-MOG antibodies for disease pathogenesis should be further analyzed.

3. Anti-AQP4 autoantibodies in NMO

NMO is a rare devastating inflammatory demyelinating disease of the CNS. In former times it was believed to be a severe variant of MS, the most common neurological disease in young adults. In contrast to MS, it has several unique features (Table 1). NMO is characterized by the occurrence of optic neuritis (ON) and longitudinally extensive transverse myelitis (LETM) extending over three or more vertebral segments (Wingerchuk et al., 1999; Cree, 2008), which can lead to blindness and paraplegia within several years of disease onset (Wingerchuk et al., 1999; Wingerchuk & Weinshenker, 2003). Furthermore, NMO commonly follows a more aggressive disease course compared to MS and has a high rate of morbidity and mortality in patients who receive no special treatment (Wingerchuk & Weinshenker, 2003). Especially at disease onset, the diagnosis can be complicated by a long lasting time interval between the occurrence of LETM and ON. Whereas OCB are detected in the CSF of approximately 90% of MS patients (Kabat et al., 1948), they are rarely or transiently present in patients with NMO (0-37%) (Wingerchuk et al., 1999). In addition, the diagnosis of NMO can be supported by the detection of CSF pleocytosis (>50 $x10^6$ white blood cell count /L) during acute relapses (Zaffaroni, 2004), which is not indicative for MS. Originally, NMO was described in 1894 by Eugene Devic and Gault as acute monophasic disorder with simultaneous occurrence of ON and LETM (Minagar et al., 2002). Due to a tremendous increase in the scientific interest for this disease, many aspects from the original view of NMO have changed. Nowadays, NMO is characterized as a mainly relapsing disease (80-90%), with a minority of patients suffering from a monophasic course (Wingerchuk et al., 2007; Sellner et al., 2010). Whereas NMO was initially described by a lack of brain MRI lesions, MS-atypical brain lesions are found in some NMO patients primarily at sites of high AQP4 expression (Pittock et al., 2006). However, a negative brain MRI at disease onset is not indicative for MS (Jarius et al., 2008b). The explosive rise in the field of NMO research was mainly due to the discovery of NMO-IgG autoantibodies, mostly IgG1,

in serum of NMO patients, but not in classical MS or any other controls (Lennon et al., 2004). This marvelous achievement is attributed to Vanda Lennon and her group, discovering one year later the AQP4 water channel protein as target antigen of NMO autoantibodies (Lennon et al., 2004; Lennon et al., 2005). This transmembrane channel protein constitutes an essential part of the blood brain barrier due to its localization in pericapillary endfeet processes and ependymal cells facing the ventricles (Figure 1) (Nielsen et al., 1997; Rash et al., 1998; Nicchia et al., 2004). The discovery and validation of this highly specific biomarker resulted in the incorporation of the anti-AQP4 antibody serostatus in the diagnostic criteria of NMO, achieving high sensitivity (99%) and specificity (90%) (Jarius et al., 2007; Wingerchuk et al., 2007) (Table 2).

Absolute criteria	**Supportive criteria**
1. Optic neuritis	1. Brain MRI atypical for MS
2. Acute myelitis	2. Spinal cord MRI with contiguous T2-weighted signal abnormality extending over 3 or more vertebral segments
	3. Anti-AQP4 IgG seropositive status

Table 2. Revised diagnostic criteria of NMO (Wingerchuk et al., 2007). Definite NMO requires fulfillment of both absolute criteria and of two of the 3 supportive criteria.

Since the discovery of anti-AQP4 IgG, NMO is considered as a separate disease entity with an unknown relationship to MS. Thus, the detection of anti-AQP4 antibodies facilitates an early stratification of NMO and MS, which is highly important due to the different treatment recommendations. Compared to MS, NMO patients have a worse prognosis and require distinct treatment strategies due to the dominant humoral immunopathogenesis. Whereas immunomodulatory therapies are frequently applied for treating MS, immunosuppressive treatment is more promising for NMO (Sellner et al., 2010). Interferon beta (IFN-ß) and glatiramer acetate (GA) were shown to be beneficial in MS, whereas in NMO patients these drugs have an ineffective or even deleterious effect (Papeix et al., 2007; Warabi et al., 2007). Acute attacks are commonly treated by a combination of corticosteroids and immunosuppressive agents. Plasma exchange or treatment with rituximab can prevent NMO attacks in patients not responding to corticosteroids (Cree et al., 2005; Watanabe et al., 2007; Jacob et al., 2008; Bonnan et al., 2009).

3.1 NMO epidemiology and genetic factors

Limited reports are published concerning the epidemiology of NMO in different ethnic groups (Kira, 2006; Cabrera-Gomez et al., 2009; Collongues et al., 2010), and thus the incidence and prevalence of NMO remains unknown. Some studies indicate a prevalence of one per 100,000 patients (Cabre, 2009; Cabrera-Gomez et al., 2009), however these studies use different antibody assays. Presumably, a proportion of patients remains to be falsely diagnosed as severe variant of MS. Available data suggest a higher incidence in non-Caucasian countries, especially in Latin American, East Asian and African populations compared to Northern European countries (Osuntokun, 1971; Kira et al., 1996; Papais-Alvarenga et al., 2002). NMO occurs up to nine times more often in women than in men

(Wingerchuk et al., 2007), with a median age of onset at around 40 years (Wingerchuk et al., 2007). Female patients were far more likely to develop the recurrent disease course (Wingerchuk, 2009), yet the gender had no impact on the type or severity of initial attacks, recovery from initial attacks, relapse frequency or disease related mortality (Wingerchuk, 2009). A genetic predisposition for NMO was recently indicated by some case reports, which are mainly based on studies of sibling pairs and a parent-child case (Mirsattari et al., 2001; Rivera & Cabrera, 2001; Braley & Mikol, 2007; Cabrera-Gomez et al., 2009). Furthermore, 12 pedigrees of NMO patients with a total number of 25 patients were recently analyzed by Mattiello and his group, resulting in 3% familial NMO cases in patients with clinical definite NMO (Matiello et al., 2010). This number might be larger when also including patients with high risk NMO, as the disease can have a heterogeneous presentation (Pellkofer et al., 2009).

3.2 Anti-AQP4 antibodies as biomarkers for NMO-spectrum disorders

With the advent of anti-AQP4 antibodies as biomarkers in NMOSD (Lennon et al., 2004; Lennon et al., 2005), various NMO antibody assays have been developed (Lennon et al., 2004; Lennon et al., 2005; Paul et al., 2007; Takahashi et al., 2007; Marignier et al., 2008; Waters & Vincent, 2008; Mader et al., 2010). The choice of assay is crucial for the identification of NMO IgG autoantibodies in serum and CSF samples of patients. The first assay describing the presence of NMO autoantibodies applied an indirect immunofluorescence (IF) assay with a composite substrate of adult mouse cerebellum sections (Lennon et al., 2004). This assay was described by the group of Vanda Lennon, achieving 58-73% sensitivity and 91-100% specificity for NMO. One year later the AQP4 water channel protein was detected as target antigen using human embryonic kidney cells (HEK) transfected with human AQP4 (Lennon et al., 2005). The establishment of cell based assays using transfected HEK cells resulted in an even higher sensitivity than the tissue based IF assays, resembling most likely the native conformation of the AQP4 protein (Takahashi et al., 2006; Takahashi et al., 2007; Mader et al., 2010). For this purpose, the cells were transfected with the AQP4 protein fused to a green fluorescence protein. After addition of the NMO samples, the bound anti-AQP4 antibodies were detected using a secondary antibody. Positive samples were visualized by a co-staining of NMO IgG (red) with the AQP4 expressing cells (green), as demonstrated in Figure 4 (Takahashi et al., 2006; Mader et al., 2010).

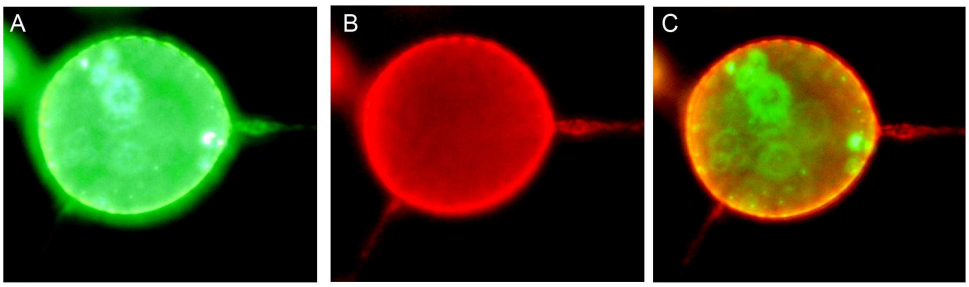

Fig. 4. Detection of an anti-AQP4 IgG seropositive patient with our live cell staining IF assay (Mader et al., 2010). Human anti-AQP4 IgG (red, B) in patient`s serum bind to the AQP4-EmGFP transfected cells (green, A), resulting in co-localisation (merge, C).

This assay has the advantage of determining titer values of NMO antibody positive patients by serial dilutions of serum samples until loss of signal. However, the relevance of these titer levels remains controversial. As the AQP4 transmembrane protein is either expressed as full length M1 or as 23 amino acid shorter M23 AQP4 (Figure 5) (Neely et al., 1999; Furman et al., 2003), many studies lack the information regarding the usage of the AQP4 isoform. Recently, our group demonstrated that anti-AQP4 antibodies primarily target the shorter M23 AQP4 isoform, whereas antibodies to full length AQP4 were developed with increasing disease duration and number of relapses (Mader et al., 2010). For this purpose we used a live cell staining IF assay with transiently transfected HEK cells, resulting in 97% sensitivity for NMO and 65% for high risk NMO, with a specificity of 100% compared to controls (Mader et al., 2010). Our assay showed different staining patterns for M1 and M23 AQP4 transfected cells (Mader et al., 2010). In contrast to M1 AQP4, M23 AQP4 forms orthogonal arrays of particles (Figure 5 B), which are currently believed to be potential targets of antibody binding (Nicchia et al., 2009). Consequently the NMO IF assay yields highest sensitivity when using cell-based assay with M23 AQP4 transfected cells.

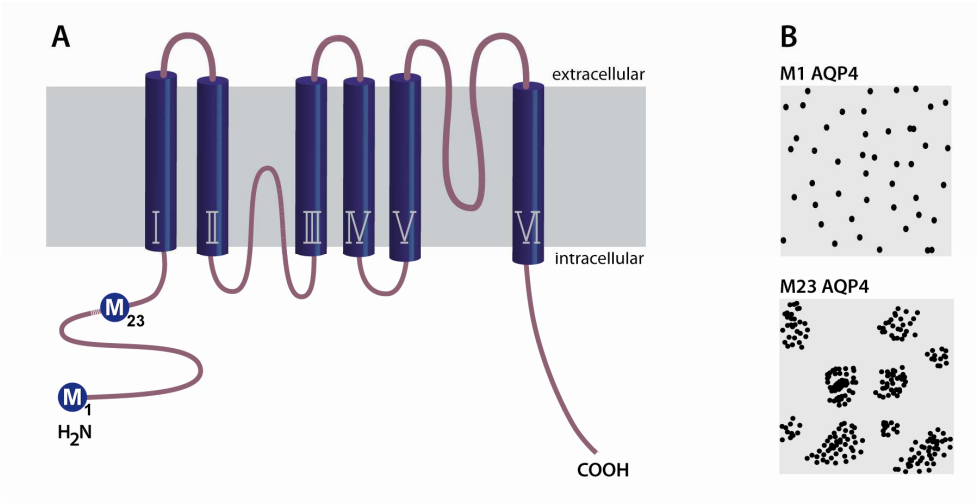

Fig. 5. Structure (A) and expression pattern (B) of the M1 and M23 AQP4 isoforms.

3.3 "Anti-AQP4 seronegative NMO"

The terminus "anti-AQP4 seronegative NMO" should be handled with care, as several factors contribute to the antibody serostatus. A broad range of antibody assays is available resulting in diverse sensitivity and specificity. Consequently, the percentage of seronegative NMO patients is fluctuating depending on the methodology approach. Cell-based assays using the M1 or M23 AQP4 isoform have an impact on the number of seronegative NMO patients. A negative antibody status might be credited to an administered therapy prior to testing. A depletion of antibodies below a detectable threshold could explain a negative serostatus. Although, anti-AQP4 antibodies have been detected up to ten years before disease onset (Nishiyama et al., 2009), we have analyzed a small number of patients who were initially negative for NMO IgG and turned out to be low titer positive in longitudinal

samples (unpublished results). For this reasons, one has to be careful when dealing with the term "seronegative NMO". Moreover, seronegative NMO might resemble another disease course with overlapping clinical features. Particularly, pediatric NMO can present itself with diverse clinical features, and therefore stratification from MS can be difficult especially at disease onset (Lotze et al., 2008). The diagnosis might further be supported by analyzing CSF of patients. Recently, glial fibrillar acidic protein (GFAP), a marker of astrocytic damage, was shown to be significantly elevated in the CSF of NMO patients compared to classical MS (Misu et al., 2009), however this increase was primarily detectable during relapse (Misu et al., 2009). In conclusion, the anti-AQP4 antibody serostatus should be repeatedly analyzed in NMOSD using highly sensitive and specific cell based assays. The absence of anti-AQP4 antibodies over a long time interval indicates a different disease pathomechanism compared to patients with "AQP4 autoimmune channelopathy". Consequently ongoing research should focus on the discovery of new biomarkers for anti-AQP4 seronegative patients with NMO.

3.4 NMO-spectrum disorders

Apart from clinical definite NMO, anti-AQP4 IgG antibodies are frequently detected in limited forms of NMO (Wingerchuk et al., 2007). These patients do not fulfill the complete diagnostic criteria of NMO, but harbor a high risk of developing clinically definite NMO (Pittock et al., 2008; Mader et al., 2010). Therefore, NMO and high risk NMO patients represent the group of NMOSD, suffering either from monophasic bilateral or recurrent ON or LETM (idiopathic, isolated or recurrent) (Wingerchuk et al., 2007). Currently NMO IgG positive patients with recurrent ON were shown to have a poor visual outcome and were more likely to develop NMO in a longitudinal study (Matiello et al., 2008). Anti-AQP4 IgG seropositivity predicted a relapse in patients with a first episode of LETM event extending over three or more vertebral segments (Weinshenker et al., 2006). In 50% of these anti-AQP4 IgG seropositive LETM patients either ON occurred or LETM relapsed within half a year (Weinshenker et al., 2006). Furthermore, anti-AQP4 antibodies have been frequently detected in systemic autoimmune disorders presenting themselves with ON or LETM, such as neuropsychiatric systemic lupus erythematosus (SLE), Sjogren's syndrome, myasthenia gravis or thyroiditis (Wingerchuk et al., 2007). However, anti-AQP4 antibodies were detected exclusively in systemic autoimmune disorders in combination with NMO or High Risk NMO symptoms. The presence of anti-AQP4 antibodies could indicate a coexistence of systemic autoimmune disorders with NMO (Pittock et al., 2008; Wandinger et al., 2010), rather than an epiphenomenon (Pittock et al., 2008; Wandinger et al., 2010), yet their relationship remains unidentified.

3.5 Serum titer levels of anti-AQP4 IgG antibodies

The role of serum anti-AQP4 antibody titers remains controversially described. Takahashi and his group showed an involvement of AQP4-IgG antibody titers in disease pathogenesis, detecting a correlation with spinal cord lesion length (Takahashi et al., 2006). This study analyzed 148 serum samples of Japanese patients including 35 patients with NMO-spectrum disorders and demonstrated elevated AQP4-IgG titer levels in patients with permanent complete blindness, LETM and extensive or large cerebral lesions (Takahashi et al., 2006). In addition, a longitudinal study of eight NMO-IgG

positive patients reported a correlation of serum anti-AQP4 Ig with clinical disease activity (Jarius et al., 2008a), demonstrating a threefold intra-individual increase of AQP4 IgG titers during relapse, which was not accompanied by other serum antibodies (Takahashi et al., 2006). Some papers suggest an effect of treatment on antibody titers, showing a reduction of NMO antibody titer levels after immunosuppressive treatment (Takahashi et al., 2006; Jarius et al., 2008a). Recently, an increase of anti-AQP4 antibody titers was described in one NMO patient following immunomodulatory treatment with IFN-ß (Palace et al., 2010). Applying conventional immunosuppressive therapy, the antibody titers decreased again in this patient (Palace et al., 2010), high lightening the importance of an early stratification of MS and NMO.

3.6 AQP4-IgM antibodies

Although, IgM antibodies binding to AQP4 were described at NMO lesion sites (Lucchinetti et al., 2002; Roemer et al., 2007), their role in the disease course remains unresolved. Most studies investigating autoantibodies against AQP4 refer to IgG antibodies. We addressed this issue in a recent study analyzing IgG and IgM antibodies directed to M23 AQP4 in serum of patients with NMO-spectrum disorders and in other disease groups using a live cell staining IF assay (Mader et al., 2010). In contrast to NMO IgG, which was exclusively detected in 97% of NMO patients and 65% of suspected NMO, M23 IgM antibodies were elevated in NMO (27%) and high risk NMO (12%). However, IgM antibodies to M23 AQP4 were additionally present in NMO IgG seronegative patients with isolated myelitis, MS (4%) and OND (4%). Furthermore, titer levels were much lower for IgM than for IgG AQP4. Antibodies of subtype IgM that bind to full length AQP4 were present in 10% of NMO and 8% of High Risk NMO, but not in any controls (Mader et al., 2010). This is in accordance with a study of Jarius et al. detecting IgM antibodies in almost 10% of NMO patients (4 /42) but not in any controls (Jarius et al., 2010a). Larger studies are warranted to further analyze anti-AQP4 IgG and IgM double positive patients. As anti-AQP4 IgM antibodies are more potent to activate the complement cascade, it would be tempting to further investigate the clinical parameters of anti-AQP4 IgM positive patients with NMOSD.

3.7 Cerebrospinal fluid anti-AQP4 antibodies

Several studies are available concerning anti-AQP4 antibodies in serum samples of patients with NMO-spectrum disorders. In contrast, few studies focused on the presence and relevance of NMO antibodies in the CSF (Takahashi et al., 2007; Klawiter et al., 2009; Jarius et al., 2010b; Dujmovic et al., 2011). Klawiter and colleges reported the presence of CSF anti-AQP4 antibodies in three seronegative NMO patients (Klawiter et al., 2009), which could not be reproduced in other publications. Recently, Jarius et al., detected CSF anti-AQP4 antibodies in NMO-IgG seropositive patients exceeding anti-AQP4 antibody serum titers ≥ 1:250, but not in anti-AQP4 antibody negative patients (Jarius et al., 2010b). In cooperation with Dujmovic we analyzed the temporal dynamics of CSF anti-AQP4 antibodies in 12 patients with NMOSD (Dujmovic et al., 2011). Thereby, we could show that longitudinal CSF anti-AQP4 IgG correlated with clinical parameters. CSF AQP4-IgG were present in patients with high serum titers and correlated with spinal MRI lesion length and CSF parameters. Moreover, clinical improvement was associated with a decrease in CSF, but not serum, anti-AQP4 IgG titers. Summarizing, CSF AQP4-IgG were associated with clinical activity and neuroinflammation (Dujmovic et al., 2011).

3.8 Pathogenic role of anti-AQP4 antibodies and T cells in NMO

In order to address the pathogenic relevance of anti-AQP4 antibodies, several *in vitro* and *in vivo* studies have been performed so far. Tissue sections showed the distribution of anti-AQP4 antibodies and products of complement activation surrounding hyalinized blood vessels in a rosette-like pattern (Lucchinetti et al., 2002). This deposition of NMO antibodies and complement on astrocytes at the glia limitans was accompanied by a loss of the AQP4 water channel protein (Lennon et al., 2004; Roemer et al., 2007). The cytotoxic effect of anti-AQP4 antibodies has been demonstrated in several studies so far (Jarius et al., 2008b; Hinson et al., 2009; Sabater et al., 2009; Kinoshita et al., 2010). The binding of the anti-AQP4 antibody led to an activation of the classical complement cascade, resulting in lysis of NMO antibody opsonized and AQP4-transfected cells and astrocytes (Jarius et al., 2008b). The pathogenic role of anti-AQP4 antibodies has been further supported by several *in vivo* studies using rat and mouse models (Bennett et al., 2009; Bradl et al., 2009; Kinoshita et al., 2009; Saadoun et al., 2010). Therefore, NMO-IgG antibodies were purified from the plasma exchange material of AQP4-IgG positive and negative NMO patients, MS patients and control subjects and then injected into animal models (Bradl et al., 2009). Three studies demonstrated the formation of NMO-like lesions in Lewis rats following injection of isolated human NMO-IgG in the presence of acute T cell mediated CNS inflammation (Bennett et al., 2009; Bradl et al., 2009; Kinoshita et al., 2009). In contrast, Saadoun proved the formation of NMO like lesions after injection of NMO-IgG into mouse brain only in the presence of complement, thus by-passing the damage of the blood brain barrier (Saadoun et al., 2010). In order to confirm that the NMO like pathology in the animals was due to the anti-AQP4 IgG and not based on other antibodies in the plasma exchange material, pre-absorption experiments using cells expressing AQP4 were performed (Bradl et al., 2009). This pre-absorption experiment resulted in a massive decrease of lesion size and was associated with less astrocytic damage, confirming the pathogenicity of anti-AQP4 autoantibodies (Bradl et al., 2009). As anti-AQP4 antibodies are not sufficient to induce NMO like lesions without support of T cells (Bradl et al., 2009) and/or complement (Saadoun et al., 2010), the role of T cell mediated immune responses against AQP4 is currently an issue of interest (Nelson et al., 2010; Kalluri et al., 2011; Pohl et al., 2011). Supporting evidence for a possible pathogenic role of T cells comes from observations showing no formation of NMO like lesions in immature rats after injection of anti-AQP4 autoantibodies, although these animals posses a leaky blood brain barrier (Bradl et al., 2009). Latest findings by Pohl et al. showed that AQP4 specific T cells are capable of inducing brain inflammation mainly in astrocytic glia limitans and therefore enable an entry of anti-AQP4 autoantibodies (Pohl et al., 2011). As anti-AQP4 antibodies are detectable more than ten years before disease onset (Nishiyama et al., 2009), the time point when these antibodies lead to NMO symptoms remains unresolved. It is tempting to speculate that anti-AQP4 antibodies are not harmful if they circulate peripherally and as long as they are excluded from the blood brain barrier. Whether a large amount of anti-AQP4 autoantibodies is necessary for the patients to develop symptoms remains to be investigated. Having access to the blood brain barrier, anti-AQP4 autoantibodies bind to their target antigen and result in complement activation. This leads to vascular hyalinization, necrosis, demyelination and axonal injury (Wingerchuk et al., 2007). The titer levels seem to have an impact on the disease pathogenesis as antibodies in the CSF are only detectable in high titer seropositive patients (Jarius et al., 2010b; Dujmovic et al., 2011). Latest findings indicated an influx of systemically produced anti-AQP4

antibodies through the area postrema (Popescu et al., 2011). This was supported by findings of patients suffering from intractable vomiting and nausea as initial symptoms of NMO (Popescu et al., 2011).

4. NMDA-receptor encephalomyelitis

4.1 Anti-NMDA-receptor encephalitis

The role of autoantibodies to the ionotropic NMDA (N-methyl-D-aspartate) glutamate receptor (NMDA-R; Figure 6) is well established in limbic encephalitis (Graus et al., 2010; Vincent et al., 2010; Dalmau et al., 2011).

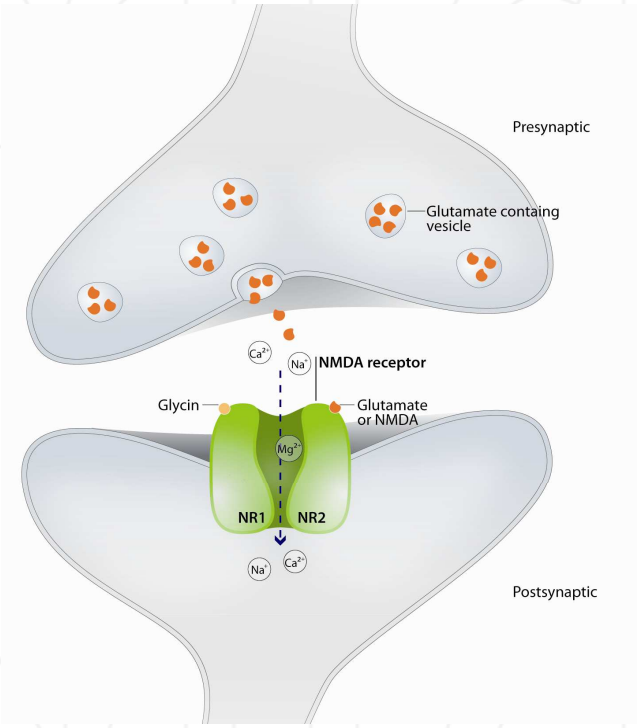

Fig. 6. NMDA-receptor expression on the postsynaptic terminal of neurons.

These novel autoantibodies were first described by Dalmau et al. in serum samples of young women presenting with a subacute-onset encephalopathy often associated with movement disorders and an underlying ovarian teratoma (Dalmau et al., 2007; Dalmau et al., 2008). The presence of neuronal tissue expressing NMDA-R within the tumour was thought to trigger the production of paraneoplastic autoantibodies. However, the origin of the autoantibodies remains unresolved, as recent publications reported numerous of non-teratoma associated cases. Among some adults, most of these non-paraneoplastic NMDA-R encephalitis cases occurred in children (Dale et al., 2009; Florance et al., 2009; Irani et al., 2010). Anti-NMDA-R encephalitis is associated with a strong female predominance (female:male ratio is 8:1) occurring primarily at a median age of 23 years (Dalmau et al., 2008).

The characteristic symptoms of anti-NMDA-R positive patients are of prominent psychiatric and behavioral nature, including rapid memory loss, seizures, abnormal movements (dyskinesias), hypoventilation and autonomic instability. This disease usually progresses from initial neuropsychiatric symptoms into a state of unresponsiveness with catatonic features, commonly associated with abnormal movements, and autonomic- and breathing instability. Additionally, most patients show prodomal symptoms such as headache, fever, nausea, vomiting, diarrhea or upper respiratory-tract symptoms. Brain MRI data show no or only minor changes which usually occur transiently despite severity of symptoms. Concerning CSF parameters, 60% of patients show OCB and mild lymphocyte pleocytosis (Dalmau et al., 2011). Interestingly, intrathecal NMDA-R antibody synthesis was observed in a majority of patients and CSF titer levels were more likely to correlate with clinical severity, compared to serum titers (Dalmau et al., 2008; Dale et al., 2009; Florance et al., 2009; Irani et al., 2010).

Although the disease can be lethal in some rare cases and despite the severity of the symptoms, more than 70% of patients recover after treatment and less than 30% of patients show incomplete recovery with memory, cognitive and motor deficits. Treatment options include immunotherapy (corticosteroids, intravenous immunoglobulin or plasma exchange) and/or tumor removal with the aim to reduce anti-NMDA-R autoantibody levels. Recent studies showed that antibodies to the NMDA-R were predominantly of the IgG1 subclass and are able to activate complement on NMDA-R expressing human embryonic kidney cells (Irani et al., 2010). However, the role of complement activation remains controversial as other findings indicated a complement-independent mode of action. Several studies have addressed the issue regarding the binding site of the autoantibodies and possible functional consequences on the targeted NMDA-R. Dalmau et al. described the NR1 isoform or NR1/NR2 heterodimers of the NMDA-R as recognition site of anti-NMDA-R antibodies (Dalmau et al., 2011). Providing further insight into the mode of action, *in vitro* and *in vivo* studies nicely demonstrated that antibodies from patients with anti-NMDA-R encephalitis caused a rapid and reversible loss of surface NMDA-R by antibody-mediated capping and internalization, resulting in abrogation of NMDA-R-mediated synaptic function (Dalmau et al., 2008; Hughes et al., 2010).

Thus, similar to the role of anti-AQP4 IgG antibodies in NMO, anti-NMDA-R antibodies helped to define a new clinical syndrome, anti-NMDA receptor encephalitis (Dalmau et al., 2011).

4.2 Anti-NMDA receptor antibodies in neuropsychiatric SLE

Several reports confirmed the presence of autoantibodies to NMDA-R, particularly the NR2 isoform, in the majority of patients with neuropsychiatric SLE (DeGiorgio et al., 2001; Emmer et al., 2006; Hanly et al., 2006; Kowal et al., 2006; Lapteva et al., 2006; Arinuma et al., 2008; Fragoso-Loyo et al., 2008). These autoantibodies were not only detected in serum, but also in the CSF and brain parenchyma of some SLE patients. Furthermore, CSF titers correlate with neuropsychiatric symptoms. In SLE, anti-NMDA-R antibodies were demonstrated to bind to a small peptide (DWEYS) present in the extracellular, amino-terminal domain of NR2A and NR2B subunits (DeGiorgio et al., 2001; Gielen et al., 2009). Injection of murine or human monoclonal antibodies against this peptide into the hippocampus and cerebral cortex of mice resulted in local loss of neurons and induced activation of caspase-3 in cultured human and murine neurons (DeGiorgio et al., 2001; Kowal et al., 2006; Gielen et al., 2009). Furthermore, several experimental studies in mice

demonstrated a causal relationship between anti-NMDA-R autoantibodies with impairment in cognition and behavior (Diamond et al., 2009). A recent study provided evidence of a positive modulating effect on receptor function by low concentrations of anti-NMDA-R antibodies, resulting in an increase of NMDA-R mediated excitatory postsynaptic potentials. However, at high concentrations, these antibodies promote excitotoxicity through enhanced mitochondrial permeability transition. These findings might be an explanation for the either transient or permanent neuropsychiatric clinical course observed in SLE patients. In conclusion, antibodies to the NR2 isoform of NMDA-R could play an important role in the pathogenesis of neuropsychiatric lupus.

Many studies focusing on the detection of antibodies to the NMDA-R NR2A and NR2B subunits in SLE have used the ELISA technique. It is now essential that studies regarding antibody specificity in patient serum/CSF are confirmed using live cell-based assays expressing native NMDA-R or single subunits.

4.3 Anti-NMDA receptor antibodies in inflammatory demyelinating diseases

Interestingly, antibodies against NMDA-type glutamate receptors were also detected in both serum and CSF of patients with NMOSD (Ishikawa et al., 2007; Kruer et al., 2010). As previously described, the discovery of anti-AQP4 IgG antibodies in the serum of patients with NMOSD enables an early diagnosis and specific treatment of the disease. Despite the high percentage of AQP4-IgG seropositive NMO patients, several studies report on AQP4-IgG seronegative NMO patients who, however, show no differences in their clinical presentation. It might well be that AQP4-IgG seronegative patients represent a distinct subgroup of NMO patients, in whom the disease is triggered by other autoantibodies, such as antibodies to NMDA-R or yet unknown targets. So far, in literature there is a lack of information regarding the presence of anti-NMDA-R antibodies in other CNS demyelinating diseases, such as MS. Up to now, one case report speculates on a possible association of the rarely occurring epileptic seizures in MS (Catenoix et al., 2010) with anti-NMDA-R antibody seropositivity (Johnston et al., 2010).

5. Conclusion

The discovery of autoantibodies in different CNS diseases can support an early diagnosis and treatment monitoring. Moreover, antibodies can contribute to a better understanding of the disease pathogenesis. However, an antibody seronegative result should be handled with care, as this can be linked to the assay methodology, study population or to therapeutic intervention. In contrast to the high sensitivity and specificity of anti-AQP4 autoantibodies in NMO patients, antibodies to MOG are discovered "only" in a subgroup of ADEM patients. Hence, there is a lack of a specific biomarker for more than half of patients diagnosed with ADEM. Future studies focusing on these seronegative patients might facilitate a reclassification of CNS diseases through the identification of novel biomarkers. Finally, antibodies to NMDA-R are highly specific for NMDA-receptor encephalitis, whereas their role in other neurological diseases has to be confirmed by specific assays.

6. Acknowledgment

The authors wish to thank the ARGE NMO Austria for excellent co-operation and Kathrin Schanda and Viktoria Gredler for their help and encouragement. This work was financially supported by Innsbruck Medical University and the Austrian MS society.

7. References

Adelmann, M., Wood, J., Benzel, I., Fiori, P., Lassmann, H., Matthieu, J.M., Gardinier, M.V., Dornmair, K., and Linington, C. (1995). The N-terminal domain of the myelin oligodendrocyte glycoprotein (MOG) induces acute demyelinating experimental autoimmune encephalomyelitis in the Lewis rat. *J Neuroimmunol*, 63, 1, Dec, 17-27.

Amor, S., Groome, N., Linington, C., Morris, M.M., Dornmair, K., Gardinier, M.V., Matthieu, J.M., and Baker, D. (1994). Identification of epitopes of myelin oligodendrocyte glycoprotein for the induction of experimental allergic encephalomyelitis in SJL and Biozzi AB/H mice. *J Immunol*, 153, 10, Nov 15, 4349-4356.

Arinuma, Y., Yanagida, T., and Hirohata, S. (2008). Association of cerebrospinal fluid anti-NR2 glutamate receptor antibodies with diffuse neuropsychiatric systemic lupus erythematosus. *Arthritis and rheumatism*, 58, 4, Apr, 1130-1135.

Bar-Or, A., and Antel, J. (2008). Cross-reactivity between epidemiology and immunology in multiple sclerosis. *Neurology*, 71, 15, Oct 7, 1132-1133.

Bennett, J.L., Lam, C., Kalluri, S.R., Saikali, P., Bautista, K., Dupree, C., Glogowska, M., Case, D., Antel, J.P., Owens, G.P., Gilden, D., Nessler, S., Stadelmann, C., and Hemmer, B. (2009). Intrathecal pathogenic anti-aquaporin-4 antibodies in early neuromyelitis optica. *Ann Neurol*, 66, 5, Nov, 617-629.

Berger, T., Rubner, P., Schautzer, F., Egg, R., Ulmer, H., Mayringer, I., Dilitz, E., Deisenhammer, F., and Reindl, M. (2003). Antimyelin antibodies as a predictor of clinically definite multiple sclerosis after a first demyelinating event. *N Engl J Med*, 349, 2, Jul 10, 139-145.

Bonnan, M., Valentino, R., Olindo, S., Mehdaoui, H., Smadja, D., and Cabre, P. (2009). Plasma exchange in severe spinal attacks associated with neuromyelitis optica spectrum disorder. *Mult Scler*, 15, 4, Apr, 487-492.

Bradl, M., Misu, T., Takahashi, T., Watanabe, M., Mader, S., Reindl, M., Adzemovic, M., Bauer, J., Berger, T., Fujihara, K., Itoyama, Y., and Lassmann, H. (2009). Neuromyelitis optica: pathogenicity of patient immunoglobulin in vivo. *Ann Neurol*, 66, 5, Nov, 630-643.

Braley, T., and Mikol, D.D. (2007). Neuromyelitis optica in a mother and daughter. *Arch Neurol*, 64, 8, Aug, 1189-1192.

Brilot, F., Dale, R.C., Selter, R.C., Grummel, V., Kalluri, S.R., Aslam, M., Busch, V., Zhou, D., Cepok, S., and Hemmer, B. (2009). Antibodies to native myelin oligodendrocyte glycoprotein in children with inflammatory demyelinating central nervous system disease. *Ann Neurol*, 66, 6, Dec, 833-842.

Brunner, C., Lassmann, H., Waehneldt, T.V., Matthieu, J.M., and Linington, C. (1989). Differential ultrastructural localization of myelin basic protein, myelin/oligodendroglial glycoprotein, and 2',3'-cyclic nucleotide 3'-phosphodiesterase in the CNS of adult rats. *J Neurochem*, 52, 1, Jan, 296-304.

Cabre, P. (2009). Environmental changes and epidemiology of multiple sclerosis in the French West Indies. *J Neurol Sci*, 286, 1-2, Nov 15, 58-61.

Cabrera-Gomez, J.A., Kurtzke, J.F., Gonzalez-Quevedo, A., and Lara-Rodriguez, R. (2009). An epidemiological study of neuromyelitis optica in Cuba. *J Neurol*, 256, 1, Jan, 35-44.

Callen, D.J., Shroff, M.M., Branson, H.M., Li, D.K., Lotze, T., Stephens, D., and Banwell, B.L. (2009). Role of MRI in the differentiation of ADEM from MS in children. *Neurology*, 72, 11, Mar 17, 968-973.

Catenoix, H., Marignier, R., Ritleng, C., Dufour, M., Mauguiere, F., Confavreux, C., and Vukusic, S. (2010). Multiple sclerosis and epileptic seizures. *Multiple sclerosis (Houndmills, Basingstoke, England)*, Sep 22.

Collongues, N., Marignier, R., Zephir, H., Papeix, C., Blanc, F., Ritleng, C., Tchikviladze, M., Outteryck, O., Vukusic, S., Fleury, M., Fontaine, B., Brassat, D., Clanet, M., Milh, M., Pelletier, J., Audoin, B., Ruet, A., Lebrun-Frenay, C., Thouvenot, E., Camu, W., Debouverie, M., Creange, A., Moreau, T., Labauge, P., Castelnovo, G., Edan, G., Le Page, E., Defer, G., Barroso, B., Heinzlef, O., Gout, O., Rodriguez, D., Wiertlewski, S., Laplaud, D., Borgel, F., Tourniaire, P., Grimaud, J., Brochet, B., Vermersch, P., Confavreux, C., and de Seze, J. (2010). Neuromyelitis optica in France: a multicenter study of 125 patients. *Neurology*, 74, 9, Mar 2, 736-742.

Colombo, M., Dono, M., Gazzola, P., Roncella, S., Valetto, A., Chiorazzi, N., Mancardi, G.L., and Ferrarini, M. (2000). Accumulation of clonally related B lymphocytes in the cerebrospinal fluid of multiple sclerosis patients. *J Immunol*, 164, 5, Mar 1, 2782-2789.

Cree, B. (2008). Neuromyelitis optica: diagnosis, pathogenesis, and treatment. *Curr Neurol Neurosci Rep*, 8, 5, Sep, 427-433.

Cree, B.A., Lamb, S., Morgan, K., Chen, A., Waubant, E., and Genain, C. (2005). An open label study of the effects of rituximab in neuromyelitis optica. *Neurology*, 64, 7, Apr 12, 1270-1272.

Dale, R.C., de Sousa, C., Chong, W.K., Cox, T.C., Harding, B., and Neville, B.G. (2000). Acute disseminated encephalomyelitis, multiphasic disseminated encephalomyelitis and multiple sclerosis in children. *Brain*, 123 Pt 12, Dec, 2407-2422.

Dale, R.C., Irani, S.R., Brilot, F., Pillai, S., Webster, R., Gill, D., Lang, B., and Vincent, A. (2009). N-methyl-D-aspartate receptor antibodies in pediatric dyskinetic encephalitis lethargica. *Annals of neurology*, 66, 5, Nov, 704-709.

Dalmau, J., Gleichman, A.J., Hughes, E.G., Rossi, J.E., Peng, X., Lai, M., Dessain, S.K., Rosenfeld, M.R., Balice-Gordon, R., and Lynch, D.R. (2008). Anti-NMDA-receptor encephalitis: case series and analysis of the effects of antibodies. *Lancet neurology*, 7, 12, Dec, 1091-1098.

Dalmau, J., Lancaster, E., Martinez-Hernandez, E., Rosenfeld, M.R., and Balice-Gordon, R. (2011). Clinical experience and laboratory investigations in patients with anti-NMDAR encephalitis. *Lancet neurology*, 10, 1, Jan, 63-74.

Dalmau, J., Tuzun, E., Wu, H.Y., Masjuan, J., Rossi, J.E., Voloschin, A., Baehring, J.M., Shimazaki, H., Koide, R., King, D., Mason, W., Sansing, L.H., Dichter, M.A., Rosenfeld, M.R., and Lynch, D.R. (2007). Paraneoplastic anti-N-methyl-D-aspartate receptor encephalitis associated with ovarian teratoma. *Annals of neurology*, 61, 1, Jan, 25-36.

DeGiorgio, L.A., Konstantinov, K.N., Lee, S.C., Hardin, J.A., Volpe, B.T., and Diamond, B. (2001). A subset of lupus anti-DNA antibodies cross-reacts with the NR2 glutamate receptor in systemic lupus erythematosus. *Nature medicine*, 7, 11, Nov, 1189-1193.

Di Pauli, F., Mader, S., Rostasy, K., Schanda, K., Bajer-Kornek, B., Ehling, R., Deisenhammer, F., Reindl, M., and Berger, T. (2011). Temporal dynamics of anti-MOG antibodies in CNS demyelinating diseases. *Clin Immunol*, 138, 3, Mar, 247-254.

Diamond, B., Huerta, P.T., Mina-Osorio, P., Kowal, C., and Volpe, B.T. (2009). Losing your nerves? Maybe it's the antibodies. *Nat Rev Immunol*, 9, 6, Jun, 449-456.

Dujmovic, I., Mader, S., Schanda, K., Deisenhammer, F., Stojsavljevic, N., Kostic, J., Berger, T., Drulovic, J., and Reindl, M. (2011). Temporal dynamics of cerebrospinal fluid anti-aquaporin-4 antibodies in patients with neuromyelitis optica spectrum disorders. *J Neuroimmunol*, Feb 10.

Emmer, B.J., van der Grond, J., Steup-Beekman, G.M., Huizinga, T.W., and van Buchem, M.A. (2006). Selective involvement of the amygdala in systemic lupus erythematosus. *PLoS Med*, 3, 12, Dec, e499.

Florance, N.R., Davis, R.L., Lam, C., Szperka, C., Zhou, L., Ahmad, S., Campen, C.J., Moss, H., Peter, N., Gleichman, A.J., Glaser, C.A., Lynch, D.R., Rosenfeld, M.R., and Dalmau, J. (2009). Anti-N-methyl-D-aspartate receptor (NMDAR) encephalitis in children and adolescents. *Annals of neurology*, 66, 1, Jul, 11-18.

Fragoso-Loyo, H., Cabiedes, J., Orozco-Narvaez, A., Davila-Maldonado, L., Atisha-Fregoso, Y., Diamond, B., Llorente, L., and Sanchez-Guerrero, J. (2008). Serum and cerebrospinal fluid autoantibodies in patients with neuropsychiatric lupus erythematosus. Implications for diagnosis and pathogenesis. *PloS one*, 3, 10, e3347.

Franciotta, D., Columba-Cabezas, S., Andreoni, L., Ravaglia, S., Jarius, S., Romagnolo, S., Tavazzi, E., Bergamaschi, R., Zardini, E., Aloisi, F., and Marchioni, E. (2008). Oligoclonal IgG band patterns in inflammatory demyelinating human and mouse diseases. *J Neuroimmunol*, 200, 1-2, Aug 30, 125-128.

Freedman, M.S., Thompson, E.J., Deisenhammer, F., Giovannoni, G., Grimsley, G., Keir, G., Ohman, S., Racke, M.K., Sharief, M., Sindic, C.J., Sellebjerg, F., and Tourtellotte, W.W. (2005). Recommended standard of cerebrospinal fluid analysis in the diagnosis of multiple sclerosis: a consensus statement. *Arch Neurol*, 62, 6, Jun, 865-870.

Furman, C.S., Gorelick-Feldman, D.A., Davidson, K.G., Yasumura, T., Neely, J.D., Agre, P., and Rash, J.E. (2003). Aquaporin-4 square array assembly: opposing actions of M1 and M23 isoforms. *Proc Natl Acad Sci U S A*, 100, 23, Nov 11, 13609-13614.

Gaertner, S., de Graaf, K.L., Greve, B., and Weissert, R. (2004). Antibodies against glycosylated native MOG are elevated in patients with multiple sclerosis. *Neurology*, 63, 12, Dec 28, 2381-2383.

Genain, C.P., Cannella, B., Hauser, S.L., and Raine, C.S. (1999). Identification of autoantibodies associated with myelin damage in multiple sclerosis. *Nature medicine*, 5, 2, Feb, 170-175.

Genain, C.P., Nguyen, M.H., Letvin, N.L., Pearl, R., Davis, R.L., Adelman, M., Lees, M.B., Linington, C., and Hauser, S.L. (1995). Antibody facilitation of multiple sclerosis-like lesions in a nonhuman primate. *The Journal of clinical investigation*, 96, 6, Dec, 2966-2974.

Gielen, M., Siegler Retchless, B., Mony, L., Johnson, J.W., and Paoletti, P. (2009). Mechanism of differential control of NMDA receptor activity by NR2 subunits. *Nature*, 459, 7247, Jun 4, 703-707.

Goverman, J. (2009). Autoimmune T cell responses in the central nervous system. *Nat Rev Immunol*, 9, 6, Jun, 393-407.

Graus, F., Saiz, A., and Dalmau, J. (2010). Antibodies and neuronal autoimmune disorders of the CNS. *J Neurol*, 257, 4, Apr, 509-517.

Greeve, I., Sellner, J., Lauterburg, T., Walker, U., Rosler, K.M., and Mattle, H.P. (2007). Anti-myelin antibodies in clinically isolated syndrome indicate the risk of multiple sclerosis in a Swiss cohort. *Acta Neurol Scand*, 116, 4, Oct, 207-210.

Hanly, J.G., Robichaud, J., and Fisk, J.D. (2006). Anti-NR2 glutamate receptor antibodies and cognitive function in systemic lupus erythematosus. *J Rheumatol*, 33, 8, Aug, 1553-1558.

Hauser, S.L., Waubant, E., Arnold, D.L., Vollmer, T., Antel, J., Fox, R.J., Bar-Or, A., Panzara, M., Sarkar, N., Agarwal, S., Langer-Gould, A., and Smith, C.H. (2008). B-cell depletion with rituximab in relapsing-remitting multiple sclerosis. *N Engl J Med*, 358, 7, Feb 14, 676-688.

Hinson, S.R., McKeon, A., Fryer, J.P., Apiwattanakul, M., Lennon, V.A., and Pittock, S.J. (2009). Prediction of neuromyelitis optica attack severity by quantitation of complement-mediated injury to aquaporin-4-expressing cells. *Arch Neurol*, 66, 9, Sep, 1164-1167.

Hughes, E.G., Peng, X., Gleichman, A.J., Lai, M., Zhou, L., Tsou, R., Parsons, T.D., Lynch, D.R., Dalmau, J., and Balice-Gordon, R.J. (2010). Cellular and synaptic mechanisms of anti-NMDA receptor encephalitis. *J Neurosci*, 30, 17, Apr 28, 5866-5875.

Hynson, J.L., Kornberg, A.J., Coleman, L.T., Shield, L., Harvey, A.S., and Kean, M.J. (2001). Clinical and neuroradiologic features of acute disseminated encephalomyelitis in children. *Neurology*, 56, 10, May 22, 1308-1312.

Irani, S.R., Bera, K., Waters, P., Zuliani, L., Maxwell, S., Zandi, M.S., Friese, M.A., Galea, I., Kullmann, D.M., Beeson, D., Lang, B., Bien, C.G., and Vincent, A. (2010). N-methyl-D-aspartate antibody encephalitis: temporal progression of clinical and paraclinical observations in a predominantly non-paraneoplastic disorder of both sexes. *Brain : a journal of neurology*, 133, Pt 6, Jun, 1655-1667.

Ishikawa, N., Tajima, G., Hyodo, S., Takahashi, Y., and Kobayashi, M. (2007). Detection of autoantibodies against NMDA-type glutamate receptor in a patient with recurrent optic neuritis and transient cerebral lesions. *Neuropediatrics*, 38, 5, Oct, 257-260.

Jacob, A., Weinshenker, B.G., Violich, I., McLinskey, N., Krupp, L., Fox, R.J., Wingerchuk, D.M., Boggild, M., Constantinescu, C.S., Miller, A., De Angelis, T., Matiello, M., and Cree, B.A. (2008). Treatment of neuromyelitis optica with rituximab: retrospective analysis of 25 patients. *Arch Neurol*, 65, 11, Nov, 1443-1448.

Jarius, S., Aboul-Enein, F., Waters, P., Kuenz, B., Hauser, A., Berger, T., Lang, W., Reindl, M., Vincent, A., and Kristoferitsch, W. (2008a). Antibody to aquaporin-4 in the long-term course of neuromyelitis optica. *Brain*, 131, Pt 11, Nov, 3072-3080.

Jarius, S., Franciotta, D., Bergamaschi, R., Wildemann, B., and Wandinger, K.P. (2010a). Immunoglobulin M antibodies to aquaporin-4 in neuromyelitis optica and related disorders. *Clin Chem Lab Med*, 48, 5, May, 659-663.

Jarius, S., Franciotta, D., Paul, F., Ruprecht, K., Bergamaschi, R., Rommer, P.S., Reuss, R., Probst, C., Kristoferitsch, W., Wandinger, K.P., and Wildemann, B. (2010b). Cerebrospinal fluid antibodies to aquaporin-4 in neuromyelitis optica and related disorders: frequency, origin, and diagnostic relevance. *J Neuroinflammation*, 7, 52.

Jarius, S., Paul, F., Franciotta, D., Aktas, O., Hohlfeld, R., Zipp, F., and Vincent, A. (2007). Revised diagnostic criteria for neuromyelitis optica--incorporation of NMO-IgG status. *Nat Clin Pract Neurol*, 3, 5, May, E1.

Jarius, S., Paul, F., Franciotta, D., Waters, P., Zipp, F., Hohlfeld, R., Vincent, A., and Wildemann, B. (2008b). Mechanisms of disease: aquaporin-4 antibodies in neuromyelitis optica. *Nature clinical practice*, 4, 4, Apr, 202-214.

Johnston, J., Ali, K., Pearson, O.R., Rickards, C., and Vincent, A. (2010). POI14 Multiple sclerosis: a potential association with anti-N-methyl-d-aspartate receptor encephalitis. *J Neurol Neurosurg Psychiatry*, 81, 11, Nov, e56.

Kabat, E.A., Glusman, M., and Knaub, V. (1948). Quantitative estimation of the albumin and gamma globulin in normal and pathologic cerebrospinal fluid by immunochemical methods. *Am J Med*, 4, 5, May, 653-662.

Kalluri, S.R., Rothhammer, V., Staszewski, O., Srivastava, R., Petermann, F., Prinz, M., Hemmer, B., and Korn, T. (2011). Functional characterization of aquaporin-4 specific T cells: towards a model for neuromyelitis optica. *PLoS One*, 6, 1, e16083.

Kerlero de Rosbo, N., Honegger, P., Lassmann, H., and Matthieu, J.M. (1990). Demyelination induced in aggregating brain cell cultures by a monoclonal antibody against myelin/oligodendrocyte glycoprotein. *J Neurochem*, 55, 2, Aug, 583-587.

Kesselring, J., Miller, D.H., Robb, S.A., Kendall, B.E., Moseley, I.F., Kingsley, D., du Boulay, E.P., and McDonald, W.I. (1990). Acute disseminated encephalomyelitis. MRI findings and the distinction from multiple sclerosis. *Brain*, 113 (Pt 2), Apr, 291-302.

Kinoshita, M., Nakatsuji, Y., Kimura, T., Moriya, M., Takata, K., Okuno, T., Kumanogoh, A., Kajiyama, K., Yoshikawa, H., and Sakoda, S. (2009). Neuromyelitis optica: Passive transfer to rats by human immunoglobulin. *Biochemical and biophysical research communications*, 386, 4, Sep 4, 623-627.

Kinoshita, M., Nakatsuji, Y., Kimura, T., Moriya, M., Takata, K., Okuno, T., Kumanogoh, A., Kajiyama, K., Yoshikawa, H., and Sakoda, S. (2010). Anti-aquaporin-4 antibody induces astrocytic cytotoxicity in the absence of CNS antigen-specific T cells. *Biochem Biophys Res Commun*, 394, 1, Mar 26, 205-210.

Kira, J. (2006). [Epidemiology of multiple sclerosis in Japanese: with special reference to opticopsinal multiple sclerosis]. *Rinsho Shinkeigaku*, 46, 11, Nov, 859-862.

Kira, J., Kanai, T., Nishimura, Y., Yamasaki, K., Matsushita, S., Kawano, Y., Hasuo, K., Tobimatsu, S., and Kobayashi, T. (1996). Western versus Asian types of multiple

sclerosis: immunogenetically and clinically distinct disorders. *Ann Neurol*, 40, 4, Oct, 569-574.

Klawiter, E.C., Alvarez, E., 3rd, Xu, J., Paciorkowski, A.R., Zhu, L., Parks, B.J., Cross, A.H., and Naismith, R.T. (2009). NMO-IgG detected in CSF in seronegative neuromyelitis optica. *Neurology*, 72, 12, Mar 24, 1101-1103.

Kowal, C., Degiorgio, L.A., Lee, J.Y., Edgar, M.A., Huerta, P.T., Volpe, B.T., and Diamond, B. (2006). Human lupus autoantibodies against NMDA receptors mediate cognitive impairment. *Proceedings of the National Academy of Sciences of the United States of America*, 103, 52, Dec 26, 19854-19859.

Kruer, M.C., Koch, T.K., Bourdette, D.N., Chabas, D., Waubant, E., Mueller, S., Moscarello, M.A., Dalmau, J., Woltjer, R.L., and Adamus, G. (2010). NMDA receptor encephalitis mimicking seronegative neuromyelitis optica. *Neurology*, 74, 18, May 4, 1473-1475.

Krupp, L.B., Banwell, B., and Tenembaum, S. (2007). Consensus definitions proposed for pediatric multiple sclerosis and related disorders. *Neurology*, 68, 16 Suppl 2, Apr 17, S7-12.

Kuhle, J., Lindberg, R.L., Regeniter, A., Mehling, M., Hoffmann, F., Reindl, M., Berger, T., Radue, E.W., Leppert, D., and Kappos, L. (2007a). Antimyelin antibodies in clinically isolated syndromes correlate with inflammation in MRI and CSF. *J Neurol*, 254, 2, Feb, 160-168.

Kuhle, J., Pohl, C., Mehling, M., Edan, G., Freedman, M.S., Hartung, H.P., Polman, C.H., Miller, D.H., Montalban, X., Barkhof, F., Bauer, L., Dahms, S., Lindberg, R., Kappos, L., and Sandbrink, R. (2007b). Lack of association between antimyelin antibodies and progression to multiple sclerosis. *N Engl J Med*, 356, 4, Jan 25, 371-378.

Lalive, P., Hausler, M., Maurey, H., Mikaeloff, Y., Tardieu, M., Wiendl, H., Schroeter, M., Hartung, H., Kieseier, B., and Menge, T. (2011). Highly reactive anti-myelin oligodendrocyte glycoprotein antibodies differentiate demyelinating diseases from viral encephalitis in children. *Mult Scler*, 17, 3, Mar, 297-302.

Lalive, P.H., Menge, T., Delarasse, C., Della Gaspera, B., Pham-Dinh, D., Villoslada, P., von Budingen, H.C., and Genain, C.P. (2006). Antibodies to native myelin oligodendrocyte glycoprotein are serologic markers of early inflammation in multiple sclerosis. *Proceedings of the National Academy of Sciences of the United States of America*, 103, 7, Feb 14, 2280-2285.

Lapteva, L., Nowak, M., Yarboro, C.H., Takada, K., Roebuck-Spencer, T., Weickert, T., Bleiberg, J., Rosenstein, D., Pao, M., Patronas, N., Steele, S., Manzano, M., van der Veen, J.W., Lipsky, P.E., Marenco, S., Wesley, R., Volpe, B., Diamond, B., and Illei, G.G. (2006). Anti-N-methyl-D-aspartate receptor antibodies, cognitive dysfunction, and depression in systemic lupus erythematosus. *Arthritis and rheumatism*, 54, 8, Aug, 2505-2514.

Leake, J.A., Albani, S., Kao, A.S., Senac, M.O., Billman, G.F., Nespeca, M.P., Paulino, A.D., Quintela, E.R., Sawyer, M.H., and Bradley, J.S. (2004). Acute disseminated encephalomyelitis in childhood: epidemiologic, clinical and laboratory features. *Pediatr Infect Dis J*, 23, 8, Aug, 756-764.

Lennon, V.A., Kryzer, T.J., Pittock, S.J., Verkman, A.S., and Hinson, S.R. (2005). IgG marker of optic-spinal multiple sclerosis binds to the aquaporin-4 water channel. *The Journal of experimental medicine*, 202, 4, Aug 15, 473-477.

Lennon, V.A., Wingerchuk, D.M., Kryzer, T.J., Pittock, S.J., Lucchinetti, C.F., Fujihara, K., Nakashima, I., and Weinshenker, B.G. (2004). A serum autoantibody marker of neuromyelitis optica: distinction from multiple sclerosis. *Lancet*, 364, 9451, Dec 11-17, 2106-2112.

Linington, C., Berger, T., Perry, L., Weerth, S., Hinze-Selch, D., Zhang, Y., Lu, H.C., Lassmann, H., and Wekerle, H. (1993). T cells specific for the myelin oligodendrocyte glycoprotein mediate an unusual autoimmune inflammatory response in the central nervous system. *Eur J Immunol*, 23, 6, Jun, 1364-1372.

Lotze, T.E., Northrop, J.L., Hutton, G.J., Ross, B., Schiffman, J.S., and Hunter, J.V. (2008). Spectrum of pediatric neuromyelitis optica. *Pediatrics*, 122, 5, Nov, e1039-1047.

Lucchinetti, C., Bruck, W., Parisi, J., Scheithauer, B., Rodriguez, M., and Lassmann, H. (2000). Heterogeneity of multiple sclerosis lesions: implications for the pathogenesis of demyelination. *Ann Neurol*, 47, 6, Jun, 707-717.

Lucchinetti, C.F., Bruck, W., Rodriguez, M., and Lassmann, H. (1996). Distinct patterns of multiple sclerosis pathology indicates heterogeneity on pathogenesis. *Brain Pathol*, 6, 3, Jul, 259-274.

Lucchinetti, C.F., Mandler, R.N., McGavern, D., Bruck, W., Gleich, G., Ransohoff, R.M., Trebst, C., Weinshenker, B., Wingerchuk, D., Parisi, J.E., and Lassmann, H. (2002). A role for humoral mechanisms in the pathogenesis of Devic's neuromyelitis optica. *Brain*, 125, Pt 7, Jul, 1450-1461.

Mader, S., Lutterotti, A., Di Pauli, F., Kuenz, B., Schanda, K., Aboul-Enein, F., Khalil, M., Storch, M.K., Jarius, S., Kristoferitsch, W., Berger, T., and Reindl, M. (2010). Patterns of antibody binding to aquaporin-4 isoforms in neuromyelitis optica. *PloS one*, 5, 5, e10455.

, R., De Seze, J., Vukusic, S., Durand-Dubief, F., Zephir, H., Vermersch, P., Cabre, P., Cavillon, G., Honnorat, J., and Confavreux, C. (2008). NMO-IgG and Devic's neuromyelitis optica: a French experience. *Mult Scler*, 14, 4, May, 440-445.

Matiello, M., Kim, H.J., Kim, W., Brum, D.G., Barreira, A.A., Kingsbury, D.J., Plant, G.T., Adoni, T., and Weinshenker, B.G. (2010). Familial neuromyelitis optica. *Neurology*, 75, 4, Jul 27, 310-315.

Matiello, M., Lennon, V.A., Jacob, A., Pittock, S.J., Lucchinetti, C.F., Wingerchuk, D.M., and Weinshenker, B.G. (2008). NMO-IgG predicts the outcome of recurrent optic neuritis. *Neurology*, 70, 23, Jun 3, 2197-2200.

Mikaeloff, Y., Adamsbaum, C., Husson, B., Vallee, L., Ponsot, G., Confavreux, C., Tardieu, M., and Suissa, S. (2004). MRI prognostic factors for relapse after acute CNS inflammatory demyelination in childhood. *Brain*, 127, Pt 9, Sep, 1942-1947.

Mikaeloff, Y., Caridade, G., Husson, B., Suissa, S., and Tardieu, M. (2007). Acute disseminated encephalomyelitis cohort study: prognostic factors for relapse. *Eur J Paediatr Neurol*, 11, 2, Mar, 90-95.

Minagar, A., Alexander, J.S., Fowler, M.R., Long, A.C., and Kelley, R.E. (2002). Devic disease: clinical course, pathophysiology, and management. *Pathophysiology*, 9, 1, Oct, 33.

Mirsattari, S.M., Johnston, J.B., McKenna, R., Del Bigio, M.R., Orr, P., Ross, R.T., and Power, C. (2001). Aboriginals with multiple sclerosis: HLA types and predominance of neuromyelitis optica. *Neurology*, 56, 3, Feb 13, 317-323.

Misu, T., Takano, R., Fujihara, K., Takahashi, T., Sato, S., and Itoyama, Y. (2009). Marked increase in cerebrospinal fluid glial fibrillar acidic protein in neuromyelitis optica: an astrocytic damage marker. *J Neurol Neurosurg Psychiatry*, 80, 5, May, 575-577.

Neely, J.D., Christensen, B.M., Nielsen, S., and Agre, P. (1999). Heterotetrameric composition of aquaporin-4 water channels. *Biochemistry*, 38, 34, Aug 24, 11156-11163.

Nelson, P.A., Khodadoust, M., Prodhomme, T., Spencer, C., Patarroyo, J.C., Varrin-Doyer, M., Ho, J.D., Stroud, R.M., and Zamvil, S.S. (2010). Immunodominant T cell determinants of aquaporin-4, the autoantigen associated with neuromyelitis optica. *PLoS One*, 5, 11, e15050.

Nicchia, G.P., Mastrototaro, M., Rossi, A., Pisani, F., Tortorella, C., Ruggieri, M., Lia, A., Trojano, M., Frigeri, A., and Svelto, M. (2009). Aquaporin-4 orthogonal arrays of particles are the target for neuromyelitis optica autoantibodies. *Glia*, 57, 13, Oct, 1363-1373.

Nicchia, G.P., Nico, B., Camassa, L.M., Mola, M.G., Loh, N., Dermietzel, R., Spray, D.C., Svelto, M., and Frigeri, A. (2004). The role of aquaporin-4 in the blood-brain barrier development and integrity: studies in animal and cell culture models. *Neuroscience*, 129, 4, 935-945.

Nielsen, S., Nagelhus, E.A., Amiry-Moghaddam, M., Bourque, C., Agre, P., and Ottersen, O.P. (1997). Specialized membrane domains for water transport in glial cells: high-resolution immunogold cytochemistry of aquaporin-4 in rat brain. *J Neurosci*, 17, 1, Jan 1, 171-180.

Nishiyama, S., Ito, T., Misu, T., Takahashi, T., Kikuchi, A., Suzuki, N., Jin, K., Aoki, M., Fujihara, K., and Itoyama, Y. (2009). A case of NMO seropositive for aquaporin-4 antibody more than 10 years before onset. *Neurology*, 72, 22, Jun 2, 1960-1961.

Noseworthy, J.H., Lucchinetti, C., Rodriguez, M., and Weinshenker, B.G. (2000). Multiple sclerosis. *N Engl J Med*, 343, 13, Sep 28, 938-952.

O'Connor, K.C., McLaughlin, K.A., De Jager, P.L., Chitnis, T., Bettelli, E., Xu, C., Robinson, W.H., Cherry, S.V., Bar-Or, A., Banwell, B., Fukaura, H., Fukazawa, T., Tenembaum, S., Wong, S.J., Tavakoli, N.P., Idrissova, Z., Viglietta, V., Rostasy, K., Pohl, D., Dale, R.C., Freedman, M., Steinman, L., Buckle, G.J., Kuchroo, V.K., Hafler, D.A., and Wucherpfennig, K.W. (2007). Self-antigen tetramers discriminate between myelin autoantibodies to native or denatured protein. *Nature medicine*, 13, 2, Feb, 211-217.

Osuntokun, B.O. (1971). The pattern of neurological illness in tropical Africa. Experience at Ibadan, Nigeria. *J Neurol Sci*, 12, 4, Apr, 417-442.

Owens, G.P., Ritchie, A.M., Burgoon, M.P., Williamson, R.A., Corboy, J.R., and Gilden, D.H. (2003). Single-cell repertoire analysis demonstrates that clonal expansion is a prominent feature of the B cell response in multiple sclerosis cerebrospinal fluid. *J Immunol*, 171, 5, Sep 1, 2725-2733.

Palace, J., Leite, M.I., Nairne, A., and Vincent, A. (2010). Interferon Beta treatment in neuromyelitis optica: increase in relapses and aquaporin 4 antibody titers. *Arch Neurol*, 67, 8, Aug, 1016-1017.

Papais-Alvarenga, R.M., Miranda-Santos, C.M., Puccioni-Sohler, M., de Almeida, A.M., Oliveira, S., Basilio De Oliveira, C.A., Alvarenga, H., and Poser, C.M. (2002). Optic neuromyelitis syndrome in Brazilian patients. *J Neurol Neurosurg Psychiatry*, 73, 4, Oct, 429-435.

Papeix, C., Vidal, J.S., de Seze, J., Pierrot-Deseilligny, C., Tourbah, A., Stankoff, B., Lebrun, C., Moreau, T., Vermersch, P., Fontaine, B., Lyon-Caen, O., and Gout, O. (2007). Immunosuppressive therapy is more effective than interferon in neuromyelitis optica. *Mult Scler*, 13, 2, Mar, 256-259.

Paul, F., Jarius, S., Aktas, O., Bluthner, M., Bauer, O., Appelhans, H., Franciotta, D., Bergamaschi, R., Littleton, E., Palace, J., Seelig, H.P., Hohlfeld, R., Vincent, A., and Zipp, F. (2007). Antibody to Aquaporin 4 in the Diagnosis of Neuromyelitis Optica. *PLoS Med*, 4, 4, Apr 17, e133.

Pavone, P., Pettoello-Mantovano, M., Le Pira, A., Giardino, I., Pulvirenti, A., Giugno, R., Parano, E., Polizzi, A., Distefano, A., Ferro, A., Pavone, L., and Ruggieri, M. (2010). Acute disseminated encephalomyelitis: a long-term prospective study and meta-analysis. *Neuropediatrics*, 41, 6, Dec, 246-255.

Pellkofer, H.L., Suessmair, C., Schulze, A., Hohlfeld, R., and Kuempfel, T. (2009). Course of neuromyelitis optica during inadvertent pregnancy in a patient treated with rituximab. *Mult Scler*, 15, 8, Aug, 1006-1008.

Pittock, S.J., Lennon, V.A., de Seze, J., Vermersch, P., Homburger, H.A., Wingerchuk, D.M., Lucchinetti, C.F., Zephir, H., Moder, K., and Weinshenker, B.G. (2008). Neuromyelitis optica and non organ-specific autoimmunity. *Arch Neurol*, 65, 1, Jan, 78-83.

Pittock, S.J., Weinshenker, B.G., Lucchinetti, C.F., Wingerchuk, D.M., Corboy, J.R., and Lennon, V.A. (2006). Neuromyelitis optica brain lesions localized at sites of high aquaporin 4 expression. *Arch Neurol*, 63, 7, Jul, 964-968.

Pohl, M., Fischer, M.T., Mader, S., Schanda, K., Kitic, M., Sharma, R., Wimmer, I., Misu, T., Fujihara, K., Reindl, M., Lassmann, H., and Bradl, M. (2011). Pathogenic T cell responses against aquaporin 4. *Acta Neuropathol*, Apr 6.

Popescu, B.F., Lennon, V.A., Parisi, J.E., Howe, C.L., Weigand, S.D., Cabrera-Gomez, J.A., Newell, K., Mandler, R.N., Pittock, S.J., Weinshenker, B.G., and Lucchinetti, C.F. (2011). Neuromyelitis optica unique area postrema lesions: Nausea, vomiting, and pathogenic implications. *Neurology*, Mar 2.

Qin, Y., Duquette, P., Zhang, Y., Talbot, P., Poole, R., and Antel, J. (1998). Clonal expansion and somatic hypermutation of V(H) genes of B cells from cerebrospinal fluid in multiple sclerosis. *The Journal of clinical investigation*, 102, 5, Sep 1, 1045-1050.

Rash, J.E., Yasumura, T., Hudson, C.S., Agre, P., and Nielsen, S. (1998). Direct immunogold labeling of aquaporin-4 in square arrays of astrocyte and ependymocyte plasma membranes in rat brain and spinal cord. *Proc Natl Acad Sci U S A*, 95, 20, Sep 29, 11981-11986.

Rauer, S., Euler, B., Reindl, M., and Berger, T. (2006). Antimyelin antibodies and the risk of relapse in patients with a primary demyelinating event. *J Neurol Neurosurg Psychiatry*, 77, 6, Jun, 739-742.

Reindl, M., Khalil, M., and Berger, T. (2006). Antibodies as biological markers for pathophysiological processes in MS. *J Neuroimmunol*, 180, 1-2, Nov, 50-62.

Rivera, V.M., and Cabrera, J.A. (2001). Aboriginals with multiple sclerosis: HLA types and predominance of neuromyelitis optica. *Neurology*, 57, 5, Sep 11, 937-938.

Roemer, S.F., Parisi, J.E., Lennon, V.A., Benarroch, E.E., Lassmann, H., Bruck, W., Mandler, R.N., Weinshenker, B.G., Pittock, S.J., Wingerchuk, D.M., and Lucchinetti, C.F. (2007). Pattern-specific loss of aquaporin-4 immunoreactivity distinguishes neuromyelitis optica from multiple sclerosis. *Brain*, 130, Pt 5, May, 1194-1205.

Rust, R.S. (2000). Multiple sclerosis, acute disseminated encephalomyelitis, and related conditions. *Semin Pediatr Neurol*, 7, 2, Jun, 66-90.

Saadoun, S., Waters, P., Bell, B.A., Vincent, A., Verkman, A.S., and Papadopoulos, M.C. (2010). Intra-cerebral injection of neuromyelitis optica immunoglobulin G and human complement produces neuromyelitis optica lesions in mice. *Brain*, 133, Pt 2, Feb, 349-361.

Sabater, L., Giralt, A., Boronat, A., Hankiewicz, K., Blanco, Y., Llufriu, S., Alberch, J., Graus, F., and Saiz, A. (2009). Cytotoxic effect of neuromyelitis optica antibody (NMO-IgG) to astrocytes: an in vitro study. *J Neuroimmunol*, 215, 1-2, Oct 30, 31-35.

Schwarz, S., Mohr, A., Knauth, M., Wildemann, B., and Storch-Hagenlocher, B. (2001). Acute disseminated encephalomyelitis: a follow-up study of 40 adult patients. *Neurology*, 56, 10, May 22, 1313-1318.

Sellner, J., Boggild, M., Clanet, M., Hintzen, R.Q., Illes, Z., Montalban, X., Du Pasquier, R.A., Polman, C.H., Sorensen, P.S., and Hemmer, B. (2010). EFNS guidelines on diagnosis and management of neuromyelitis optica. *Eur J Neurol*, 17, 8, Aug, 1019-1032.

Sospedra, M., and Martin, R. (2005). Immunology of multiple sclerosis. *Annual review of immunology*, 23, 683-747.

Storch, M.K., Piddlesden, S., Haltia, M., Iivanainen, M., Morgan, P., and Lassmann, H. (1998). Multiple sclerosis: in situ evidence for antibody- and complement-mediated demyelination. *Ann Neurol*, 43, 4, Apr, 465-471.

Stuve, O., Nessler, S., Hartung, H.P., Hemmer, B., Wiendl, H., and Kieseier, B.C. (2005). [Acute disseminated encephalomyelitis. Pathogenesis, diagnosis, treatment, and prognosis]. *Nervenarzt*, 76, 6, Jun, 701-707.

Takahashi, T., Fujihara, K., Nakashima, I., Misu, T., Miyazawa, I., Nakamura, M., Watanabe, S., Ishii, N., and Itoyama, Y. (2006). Establishment of a new sensitive assay for anti-

human aquaporin-4 antibody in neuromyelitis optica. *Tohoku J Exp Med*, 210, 4, Dec, 307-313.

Takahashi, T., Fujihara, K., Nakashima, I., Misu, T., Miyazawa, I., Nakamura, M., Watanabe, S., Shiga, Y., Kanaoka, C., Fujimori, J., Sato, S., and Itoyama, Y. (2007). Anti-aquaporin-4 antibody is involved in the pathogenesis of NMO: a study on antibody titre. *Brain*, 130, Pt 5, May, 1235-1243.

Tenembaum, S., Chamoles, N., and Fejerman, N. (2002). Acute disseminated encephalomyelitis: a long-term follow-up study of 84 pediatric patients. *Neurology*, 59, 8, Oct 22, 1224-1231.

Tomassini, V., De Giglio, L., Reindl, M., Russo, P., Pestalozza, I., Pantano, P., Berger, T., and Pozzilli, C. (2007). Anti-myelin antibodies predict the clinical outcome after a first episode suggestive of MS. *Mult Scler*, 13, 9, Nov, 1086-1094.

Vincent, A., Irani, S.R., and Lang, B. (2010). The growing recognition of immunotherapy-responsive seizure disorders with autoantibodies to specific neuronal proteins. *Curr Opin Neurol*, 23, 2, Apr, 144-150.

Wandinger, K.P., Stangel, M., Witte, T., Venables, P., Charles, P., Jarius, S., Wildemann, B., Probst, C., Iking-Konert, C., and Schneider, M. (2010). Autoantibodies against aquaporin-4 in patients with neuropsychiatric systemic lupus erythematosus and primary Sjogren's syndrome. *Arthritis Rheum*, 62, 4, Apr, 1198-1200.

Warabi, Y., Matsumoto, Y., and Hayashi, H. (2007). Interferon beta-1b exacerbates multiple sclerosis with severe optic nerve and spinal cord demyelination. *J Neurol Sci*, 252, 1, Jan 15, 57-61.

Watanabe, S., Nakashima, I., Misu, T., Miyazawa, I., Shiga, Y., Fujihara, K., and Itoyama, Y. (2007). Therapeutic efficacy of plasma exchange in NMO-IgG-positive patients with neuromyelitis optica. *Mult Scler*, 13, 1, Jan, 128-132.

Waters, P., and Vincent, A. (2008). Detection of anti-aquaporin-4 antibodies in neuromyelitis optica: current status of the assays. *Int MS J*, 15, 3, Sep, 99-105.

Weinshenker, B.G., Wingerchuk, D.M., Vukusic, S., Linbo, L., Pittock, S.J., Lucchinetti, C.F., and Lennon, V.A. (2006). Neuromyelitis optica IgG predicts relapse after longitudinally extensive transverse myelitis. *Ann Neurol*, 59, 3, Mar, 566-569.

Weissert, R., Wallstrom, E., Storch, M.K., Stefferl, A., Lorentzen, J., Lassmann, H., Linington, C., and Olsson, T. (1998). MHC haplotype-dependent regulation of MOG-induced EAE in rats. *The Journal of clinical investigation*, 102, 6, Sep 15, 1265-1273.

Wingerchuk, D.M. (2009). Neuromyelitis optica: effect of gender. *J Neurol Sci*, 286, 1-2, Nov 15, 18-23.

Wingerchuk, D.M., Hogancamp, W.F., O'Brien, P.C., and Weinshenker, B.G. (1999). The clinical course of neuromyelitis optica (Devic's syndrome). *Neurology*, 53, 5, Sep 22, 1107-1114.

Wingerchuk, D.M., Lennon, V.A., Lucchinetti, C.F., Pittock, S.J., and Weinshenker, B.G. (2007). The spectrum of neuromyelitis optica. *Lancet Neurol*, 6, 9, Sep, 805-815.

Wingerchuk, D.M., and Weinshenker, B.G. (2003). Neuromyelitis optica: clinical predictors of a relapsing course and survival. *Neurology*, 60, 5, Mar 11, 848-853.

Zaffaroni, M. (2004). Cerebrospinal fluid findings in Devic's neuromyelitis optica. *Neurol Sci*, 25 Suppl 4, Nov, S368-370.

Zhou, D., Srivastava, R., Nessler, S., Grummel, V., Sommer, N., Bruck, W., Hartung, H.P., Stadelmann, C., and Hemmer, B. (2006). Identification of a pathogenic antibody response to native myelin oligodendrocyte glycoprotein in multiple sclerosis. *Proceedings of the National Academy of Sciences of the United States of America*, 103, 50, Dec 12, 19057-19062.

INTECH

INTECH

Autoimmune Disorders - Current Concepts and Advances from Bedside to Mechanistic Insights

Edited by Dr. Fang-Ping Huang

ISBN 978-953-307-653-9
Hard cover, 614 pages
Publisher InTech
Published online 14, November, 2011
Published in print edition November, 2011

Autoimmune disorders are caused due to break down of the immune system, which consequently fails in its ability to differentiate "self" from "non-self" in the context of immunology. The diseases are intriguing, both clinically and immunologically, for their diversified clinical phenotypes and complex underlying immunological mechanisms. This book offers cutting-edge information on some of the specific autoimmune disease phenotypes, respective diagnostic and prognostic measures, classical and new therapeutic options currently available, pathogenesis and underlying mechanisms potentially involved, and beyond. In the form of Open Access, such information is made freely available to clinicians, basic scientists and many others who will be interested regarding current advances in the areas. Its potential readers will find many of the chapters containing in-depth analysis, interesting discussions and various thought-provoking novel ideas.

How to reference

In order to correctly reference this scholarly work, feel free to copy and paste the following:

Simone Mader, Benjamin Obholzer and Markus Reindl (2011). Relevance of Autoantibodies for the Classification and Pathogenesis of Neurological Diseases, Autoimmune Disorders - Current Concepts and Advances from Bedside to Mechanistic Insights, Dr. Fang-Ping Huang (Ed.), ISBN: 978-953-307-653-9, InTech, Available from: http://www.intechopen.com/books/autoimmune-disorders-current-concepts-and-advances-from-bedside-to-mechanistic-insights/relevance-of-autoantibodies-for-the-classification-and-pathogenesis-of-neurological-diseases

INTECH
open science | open minds

InTech Europe
University Campus STeP Ri
Slavka Krautzeka 83/A
51000 Rijeka, Croatia
Phone: +385 (51) 770 447
Fax: +385 (51) 686 166
www.intechopen.com

InTech China
Unit 405, Office Block, Hotel Equatorial Shanghai
No.65, Yan An Road (West), Shanghai, 200040, China
中国上海市延安西路65号上海国际贵都大饭店办公楼405单元
Phone: +86-21-62489820
Fax: +86-21-62489821