

# We are IntechOpen, the world's leading publisher of Open Access books Built by scientists, for scientists

6,900

Open access books available

186,000

International authors and editors

200M

Downloads

Our authors are among the

154

Countries delivered to

TOP 1%

most cited scientists

12.2%

Contributors from top 500 universities



WEB OF SCIENCE™

Selection of our books indexed in the Book Citation Index  
in Web of Science™ Core Collection (BKCI)

Interested in publishing with us?  
Contact [book.department@intechopen.com](mailto:book.department@intechopen.com)

Numbers displayed above are based on latest data collected.  
For more information visit [www.intechopen.com](http://www.intechopen.com)



# The Importance of Venous and Renal Anomalies for Surgical Repair of Abdominal Aortic Aneurysms

Roberto Jiménez and Francisco Morant  
*Hospital General Universitario de Alicante  
 Spain*

## 1. Introduction

The presence of venous and renal anomalies can create technical difficulties during aortoiliac surgery, and the patients are most likely to suffer severe bleeding, thus the surgeon must be alert to detect these anomalies and to treat them correctly to avoid severe injuries.

## 2. Classification

The most frequent anomalies that can complicate abdominal aortic aneurysms (AAA) repair are:

Major venous anomalies:

Renal vein anomalies:

- Retroaortic left renal vein type I or II.
- Circumaortic left renal vein.

Inferior vena cava vein anomalies:

- Left-sided inferior vena cava or cava vein transposition
- Double inferior vena cava: type I, II or III, right double cava.
- Marsupial cava or preaortic iliac venous confluence.
- Preureteral inferior vena cava, retrocaval ureter or circumcaval ureter.
- Inferior vena cava malposition, anterior or posterior.
- Agenesis of inferior vena cava.

Genitourinary anomalies:

Fusion anomalies:

- Horseshoe kidney: frequently fusion of inferior poles, exceptionally fusion of superior pole with inferior pole, or fusion of both superior poles.
- Pancake kidney, lump kidney or pelvic horseshoe kidney: fusion of both poles.

Position anomalies, renal ectopia:

Congenital pelvic kidneys:

- Unilateral or bilateral pelvic kidneys.
- Crossed kidney with fusion.
- Crossed kidney without fusion.

Unilateral crossed kidney with contralateral agenetic kidney.  
 Bilaterally crossed kidneys.  
 Acquired pelvis kidneys (renal transplant).  
 Multiple renal arteries, veins or ureters.

### 3. Epidemiology

#### 3.1 Major venous anomalies

Congenital venous abnormalities in the retroperitoneal space are relatively infrequent and, under normal circumstances, asymptomatic, but have clinical importance in aortoiliac surgery. These anomalies have a low prevalence, the type I retroaortic left renal vein (LRV), with an incidence of 0.3–0.9% joining the inferior vena cava (IVC) in orthotopic position; the type II LRV that joins the IVC lower, at L4–L5 has an incidence of 0.4–0.9%; circumaortic LRV (0.5–1.4%); duplication of IVC (0.2–3%) and left-sided IVC (0.2–0.5%) (Aljabri et al., 2001; Bass et al., 2000).

The prevalence of marsupial cava in humans cannot be predicted, but it is probably very rare because only sporadic cases are described in literature, and studies of inferior cava anomalies do not even cite.

Retrocaval ureter is reported to be in 0,06–0,017% of autopsy materials. The incidence is greater in males than in females, with a ratio of 2,8:1 (Uthappa et al., 2002).

Agenesis of the IVC has an incidence of 0.0005% to 1% in the general population (Simon et al., 2006).

#### 3.2 Genitourinary anomalies

Horseshoe kidney is a renal fusion anomaly estimated to be present in 0,25–0,6% of the population. It is twice as common in males as in females, while abdominal aortic aneurysm (AAA) occurs in 2% of the elderly. Horseshoe kidney associated with AAA is rare: it is found in only 0.12% of the patients that undergo AAA repair (Eze, et al., 1998; Makita et al., 2009; Yamamoto et al., 2006).

The pancake kidney also called fused pelvic kidney, is rare respect to other forms of ectopia, and its incidence cannot be estimated from the literature (Eckes & Lawrence, 1997; Krohn et al., 1999).

The incidence of congenital pelvic kidney has been estimated to be in 0,3%, due to an absence of migration of metanephros, and is the most frequent kidney ectopia. Crossed renal ectopia is an uncommon genitourinary anomaly, detected in 1 of 7000 autopsies. (Krohn et al., 1999; Marone et al., 2008 ; Morales & Greenberg, 2009 ; Sebe et al., 2004 ; Yano et al., 2003).

The prevalence of abdominal aortic aneurysm in patients with renal transplant is 1.01 to 6.7%. *De novo* AAA develops in the transplant population in younger subjects and has faster enlargement, suggesting that haemodialysis length, hypertension, dyslipidaemia and steroid therapy may play a role (Kaskarelis et al., 2006; Lepäntalo et al., 1999).

Multiple renal arteries are relatively frequent (15 to 30%), the incidence of a single additional renal artery is 23,2% and is more common on the left side (27,6%) and in males (33,1%) (Natsis et al., 2010).

### 4. Anatomy and etiology

IVC results of a complex embryological process between the sixth and tenth weeks of gestation. Three pairs of primitive veins: postcardinal, subcardinal and supracardinal veins,

appear in this order and form the four segments of the adult IVC: hepatic, suprarenal, renal and infrarenal (Fig.1).

The postcardinal veins appear first on the posterior aspect of the embryo. These veins regress, except for the distal aspects which became the iliac bifurcation. The subcardinal veins then appear anterior and medial to the postcardinal veins. The right subcardinal vein remains to form the suprarenal inferior vena cava, while the left subcardinal vein completely regresses. Subsequently, the supracardinal veins appear dorsally to the subcardinal veins. The left supracardinal vein then regresses, and the right supracardinal vein forms the infrarenal inferior vena cava (Minniti & Procacci 2002).

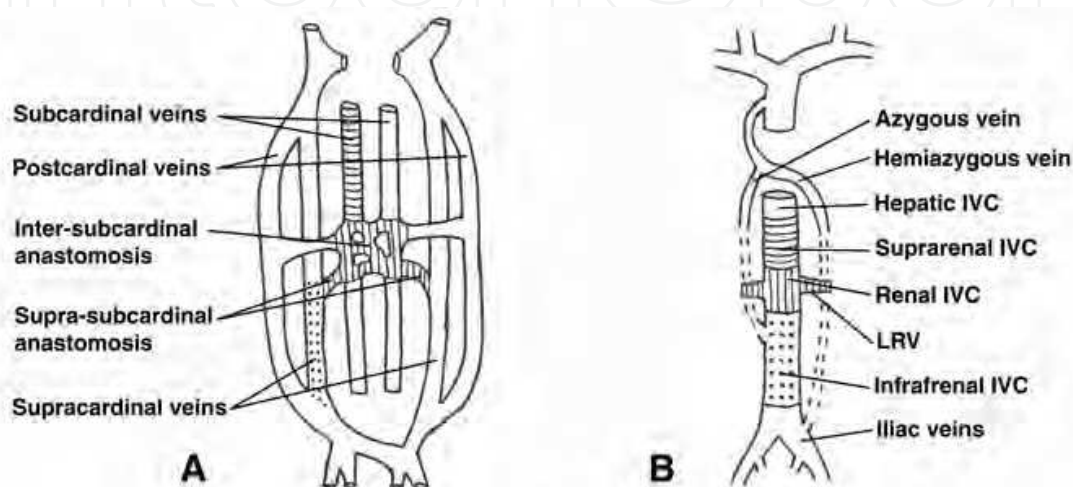


Fig. 1. Embryologic derivation of the inferior vena cava from 6-8 weeks of gestation (A) to the adult (B). IVC: inferior vena cava, LRV: left renal vein.

The most frequent anomalies are detected in the renal and infrarenal IVC, and there are some types of variants.

#### 4.1 Retroaortic left renal vein

The vein crosses the aorta in posterior face instead of the anterior face like normally. There are two types (Karkos et al., 2001; Kraus et al., 2003):

In the *retroaortic LRV type I* the ventral preaortic limb of the renal venous collar is obliterated and the dorsal limb remains on the contrary of the normal evolution, joining the IVC in an orthotopic position at the level of the renal arteries (Fig. 2A).

In the *retroaortic LRV type II* the dorsal limb is detected in a lower position, at L4-L5, behind the aorta, and joins the IVC, gonadal or ascending lumbar veins (Fig. 2B).

#### 4.2 Circumaortic left renal vein

In the circumaortic LRV, both the preaortic and retroaortic limb of the venous collar persists. There is a periaortic venous ring like in the embryonic state (Karkos et al., 2001) (Fig. 2C).

#### 4.3 Transposition or left-sided inferior vena cava

Transposition or left-sided IVC develops from the persistence of the left instead of the right supracardinal vein, which occurs in the normal evolution. The left-sided infrarenal IVC typically joins the LRV, before it crosses the aorta to form a normal right-sided suprarenal IVC.

Probably it could be subclassified in *complete left-sided IVC*, if there is a preaortic trunk lying in front of the aorta and connected to the normal right suprarenal IVC (Fig. 3A) or *incomplete left-sided IVC* if this vein empties into the left renal vein (Fig. 3B). A complete transposition of the IVC to the left with hemiazygous continuation is extremely rare (Guray et al., 2004).

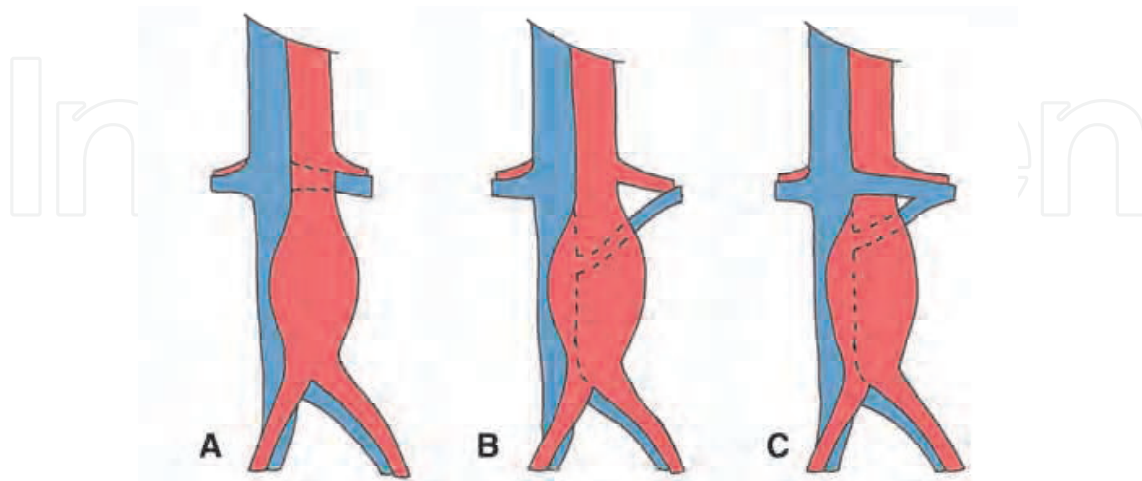


Fig. 2. Left renal vein anomalies. A, Retroaortic left renal vein type I. B, Retroaortic left renal vein type II. C, Circumaortic left renal vein

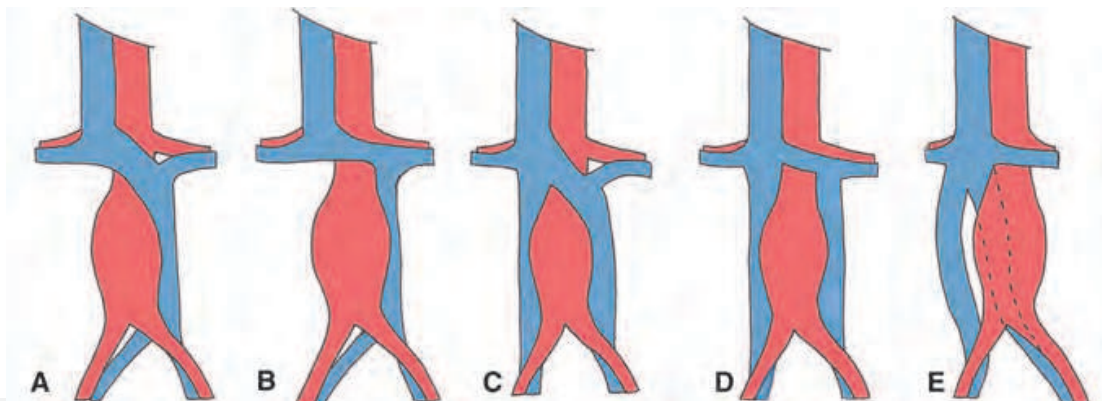


Fig. 3. Inferior vena cava (IVC) anomalies. A, Transposition or left-sided IVC. B, Left-sided IVC (incomplete). C, Duplication of the IVC. D, Double IVC (incomplete). E, Right-sided double IVC.

#### 4.4 Double inferior vena cava

In the double IVC, both left and right supracardinal veins persist. The renal segment of the IVC develops from the right suprasubcardinal and postsubcardinal anastomoses, and the infrarenal segment develops from the right supracardinal vein. Persistence of both supracardinal veins results in duplication of the IVC. (Palit & Deb, 2002).

The left iliac vein ascends as duplicated left IVC and usually drains into the left renal vein, which then crosses anterior to the aorta and joins the right IVC in a normal fashion, *incomplete double IVC* (Fig. 3D) (Ng & Ng, 2009).

It is possible that the left IVC does not drain into the left renal vein, but after receiving the left renal vein it continues with a major preaortic trunk that travels obliquely and empties

into the right IVC, *complete double IVC* (Fig. 3C). In contrast to the typical case of infrarenal duplication where the left IVC is quite smaller than the right IVC and empties into the left renal vein, there are several cases that involved the preaortic trunk, and the complete duplication of IVC could be subclassified into three types (Natsis et al., 2010):

Type I or major duplication: comprises two bilaterally symmetrical trunks and a preaortic trunk of the same caliber.

Type II or minor duplication: comprises two bilaterally symmetrical trunks, but smaller than the preaortic trunk.

Type III or asymmetric duplication: comprises small left IVC, larger right IVC and even larger preaortic trunk.

In the *right-sided double IVC* it is speculated that both of them are derived from the right supracardinal and subcardinal veins. Embryologically, the ventral vessel originates from the right subcardinal vein, whereas the dorsal vessel originates from the right supracardinal vein. (Sénécaïl et al., 2004 ; Nagashima et al., 2006 ; Ng & Ng, 2009).

In the double right IVC the left iliac vein crosses the midline behind or in front the aorta and ascends as double IVC, then joining at the renal level (Fig. 3E). There is a ventral-dorsal relationship between the two vessels. The right gonadal vein drains into the ventral vessel in majority of cases and into the IVC between the renal venous confluence and the confluence of the two vessels in other cases. (Nagashima et al., 2006; Tagliafico et al., 2007).

#### 4.5 Marsupial cava or preaortic venous confluence

At fifth week embryo, three paired veins are roughly symmetrical (posterocardinal, supracardinal and subcardinal). At eighth week, a complex venous plexus appears in the lumbar region, with consolidation of various anastomoses between posterocardinal and supracardinal veins and with further development of circumumbilicous venous rings, which surround the future common iliac arteries on each side. By the tenth week, the ventral portion of the venous rings normally disappears. The persistence of a ventral anastomosis between interposterocardinal and supracardinal veins and the regression of the dorsal venous pathways gives rise to the preaortic common iliac veins confluence later on in fetal life (Natsis et al., 2003).

In this rare anomaly the normally right-sided inferior vena cava arise from an iliac vein confluence located anteriorly to the right common iliac artery and the aortic bifurcation rather than posteriorly (Fig. 4A) (Shindo et al., 1999).

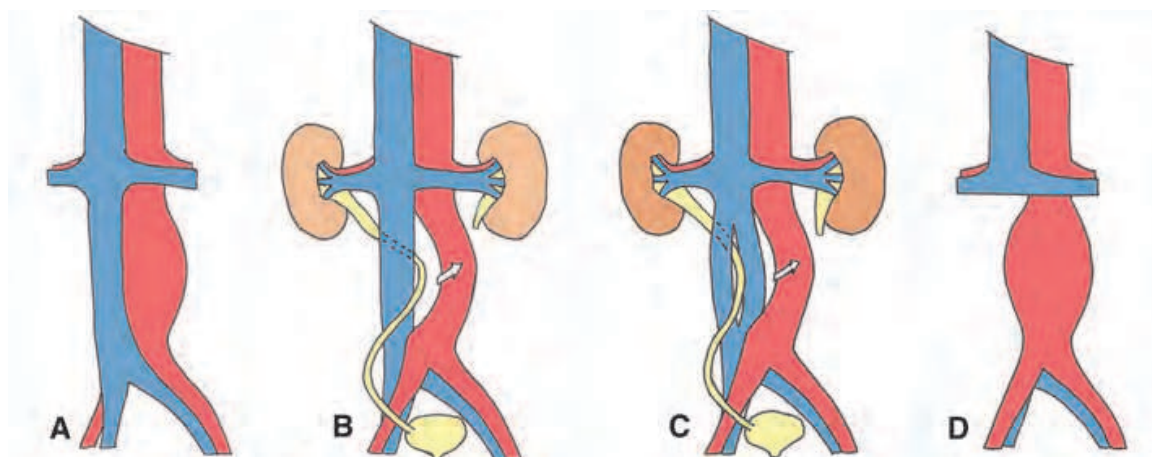


Fig. 4. Inferior vena cava (IVC) anomalies. A, Marsupial cava or preaortic venous confluence. B, Retrocaval ureter or pre-ureteric IVC. C, Transcaval ureter or periureteral venous ring. D Agnesis of infrarenal IVC.

Because such an anterior position of IVC is typical in most marsupials, as stated by McClure and Huntington in 1929, compared with the posterior position present in placental mammals, it is used the term “marsupial cava” (Schiavetta et al., 1998).

#### 4.6 Retrocaval ureter or circumcaval ureter

The embryological significance of the retrocaval ureter is, strictly speaking, an anomaly affecting the IVC and not the ureter. In embryology, the IVC normally develops from a plexus of fetal veins. The posterior cardinal and subcardinal veins lie ventrally, and the supracardinal veins lie dorsally. The left supracardinal veins and the lumbar portion of the right posterior cardinal vein atrophy and the subcardinal veins become the internal gonadal veins. A definitive right-sided IVC forms from the right supracardinal vein. If the postcardinal vein in the lumbar portion fails to atrophy and becomes the right-side IVC, the ureter is trapped dorsally to it. This occurs because the right postcardinal vein is positioned ventral to ureter in the definitive inferior vena cava, so the developing right ureter courses behind to the IVC.

Retrocaval ureter almost invariably involves the right side. In this uncommon venous anomaly the right ureter courses posterior to the IVC and partially encircles it. Right ureter's courses wings medially over pedicle of L3/4, passes behind the IVC, then exits anteriorly between IVC and aorta returning to its normal position, and produces varying degrees of proximal hydroureteronephrosis (Fig. 4B).

Bateson and Atkinson distinguished two types of retrocaval ureter according to the radiological appearance and site of ureteral narrowing (Uthappa et al., 2002; Shindo et al., 1999):

*In type I (low loop)*, the ureter crosses behind the IVC at the level of the third lumbar vertebra and has a fish hook-shaped (S-shaped) deformity of the ureter. Marked hydronephrosis is seen in over 50% of patients.

*In type II (high loop)*, the renal pelvis and upper ureter lie horizontally, and the retrocaval segment of the ureter is at the same level as the renal pelvis. The retrograde pyelogram shows a “sickle shape” of the involved ureter, generally with mild hydronephrosis. Type II is less common at around 10% of all cases.

Occasionally exits the *transcaval ureter or periureteral venous ring* and may cause ureteral obstruction (Fig. 4C) (Dillon, November 1991).

#### 4.7 Inferior vena cava malposition, anterior or posterior

There has been described malposition of the inferior vena cava, anteriorly to an AAA or posterior at it. (Chauduri, 2011).

#### 4.8 Agenesis of inferior vena cava

Agenesis of the IVC is often used to describe three different entities (Ruggeri et al., 2001):

- *Absence of the suprarenal IVC* results from failure to form the right subcardinal vein. The hepatic segment drains directly into the right atrium, and the blood from the infrarenal IVC returns to the heart through the azygos and hemiazygos veins.
- *Absence of the infrarenal IVC* with preservation of the suprarenal segment implies a failure of the development of the right supracardinal vein (Fig. 4D).
- *Absence of the entire IVC*, suggests that all three paired vein systems failed to develop properly.

#### 4.9 Horseshoe kidney

The renal system is developed from three structures that follow in time: pronephros, mesonephros and metanephros. The embryologic kidneys ascend cranially and receive blood from multiple arteries of common iliac arteries and media sacra artery; the renal artery is formed later in the third month. If the migration does not happen it gives the pelvic kidney, and if a fusion occurs, gives the horseshoe kidney.

The normally separate left and right metanephric blastemas fuse prior to migration and rotation, resulting in a fused mass. During the development of the kidney, if the metanephric masses come into contact or fuse and their normal medial rotation is interrupted, the anomalous *horseshoe kidney* come about. The renal masses ascend in the abdomen; however, the renal isthmus that lies anterior to the aorta stops its cephalic migration at the level of the inferior mesenteric artery, giving an isthmus that lies over the distal aorta above the bifurcation.

There is a fusion at inferior poles of the kidneys at the midline in 90% of cases, with the majority of each kidney lying on its own side of the spine. The isthmus connecting the lower poles contains usually functional parenchyma but may be a fibrous band and is located anterior to the aorta and IVC and posterior to the inferior mesenteric artery. The renal pelvis is usually rotated anteriorly and ureters arise anteriorly or laterally, because the horseshoe kidney, similarly to the pelvic kidney cannot rotate (Fig. 5A).

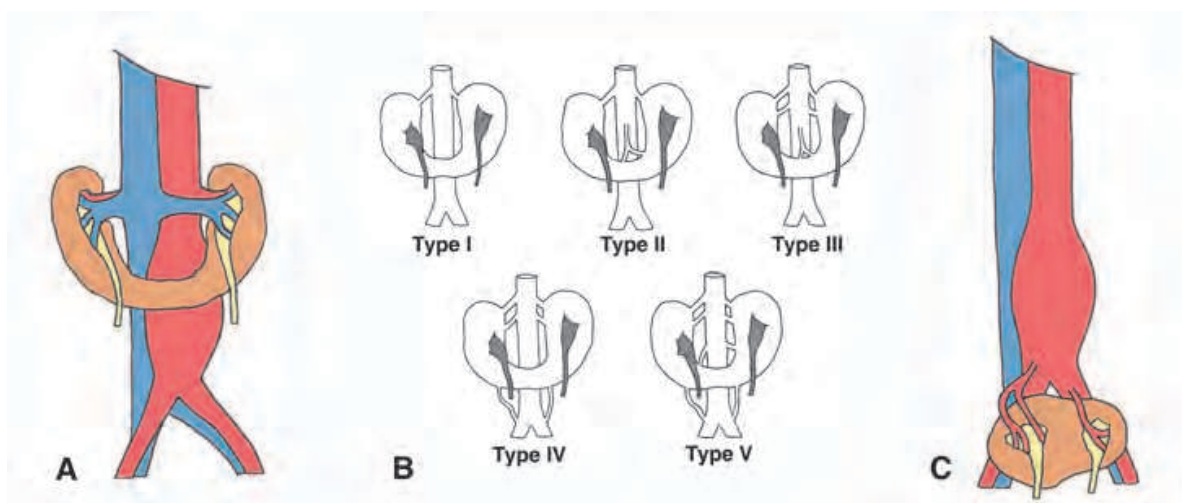


Fig. 5. Renal fusion anomalies. A, Horseshoe kidney. B, Vascularization of horseshoe kidney: type I, II, III, IV and V. C, Pancake kidney.

The blood supply to the horseshoe kidney can be quite variable, especially in the isthmus and lower poles. The abnormalities of blood supply have been reported in 60% to 74% of patients with horseshoe kidneys and frequently the isthmus and lower poles frequently have their own accessory renal artery from the aorta or iliac arteries. (Makita et al., 2009)

Different classifications exist for variable arterial blood supply in horseshoe kidney, like that proposed by Eisendrath (Fig. 5B) (Ruppert et al., 2004):

Type I: one renal artery for each side of the horseshoe kidney, 20% of cases.

Type II: one renal artery for each side with an aortic branch to the isthmus, 30%.

Type III: two arteries for each side and one renal isthmus artery, 15%.

Type IV: two arteries for each side with one or more arising from iliac arteries, including the isthmus branch, 15%.



Type V: multiple renal arteries originating from the aorta and mesenteric and iliac arteries, 20%. Anatomically, the blood supply to the horseshoe kidney is controlled segmentally by the accessory arteries, and the collateral blood flow between the segments is minimum. The occurrence of the renal ischemia was as high as 74% and is recommended reconstructing the accessory artery whenever its diameter is 2 mm or more. (Makita et al., 2009).

The renal vein anatomy is normal, with two renal veins each from left and right portions of the horseshoe kidney draining into the cava in a standard position.

#### **4.10 Pancake kidney or fused pelvic kidney**

Although the embryologic development of pancake kidney has not been fully elucidated, it is thought that it arrests in the early stages of rotation and migration. The renal blastemas are completely fused at 4-8 week embryos, and consequently fails to migrate in a cephalic direction, leaving it in a pelvic location that is usually at or below the aortic bifurcation. (Eze et al., 1998).

As its name implies, there is complete fusion of renal parenchyma without the presence of an isthmus giving an irregularly lobulated kidney, which is nearly circular in outline. The kidney is normally located at the level of the aortic bifurcation and gives rise to two collecting systems from his anterior surface that join the bladder in the normal anatomic position. Various cases from literature report two, three or four renal arteries that supply the kidney from the aorta, the right or the left common iliac arteries. The only assumption one should make is that the renal blood supply will be variable in number and position of renal arteries and can often involve the distal aorta and iliac arteries. The venous drainage systems could be variable to the iliac vein and proximal vena cava (Fig. 5C). (Eze et al., 1998).

#### **4.11 Congenital pelvic kidney**

A pelvic kidney occurs when the blastema in the 5 to 7 week embryo inexplicably fails to ascend normally.

By definition, a pelvic kidney is located under a flat level between the two iliac crests. Left pelvic kidneys are more common than right ones. Adding variety to the anatomy is the fact that the pelvic kidney does not rotate medially, so its hilum is ventrally located. There is usually a normal short ureter entering the bladder on the ipsilateral side (Sebe et al., 2004).

It is possible to affirm that in pelvic position, the renal arteries are multiple in the most cases, much more frequent than in orthotopic position, where is evaluated a 30%. Whenever is a single renal artery (49% of cases), it originates systematically from the aortic bifurcation. When the renal arteries are double, in 40% cases, a branch is originated from aortic bifurcation, and the second branch can emanate from the ipsilateral or the contralateral common iliac artery or from internal iliac artery. In case of three or four arteries (11% of cases), a branch comes from aortic bifurcation and the others branches from iliac axis ipsilateral and contralateral. Rarely, blood supply is guaranteed by feeding arteries originating from inferior mesenteric arteries. In definitive, if there are multiple renal arteries (in more than 50% of cases), one of the branches originates systematically from aortic bifurcation, and the other branches come from ipsilateral iliac axis and more rarely from contralateral iliac axis. The venous vascularization of pelvic kidneys is never described. The pelvic renal veins are multiples and small caliber. They drain in the IVC and in ipsilateral common iliac vein (Fig. B) (Marone et al., 2008; Sebe et al., 2004).

The *single pelvic kidney* represents failure of ascent of the existing normal kidney beyond the true pelvis in combination with a congenital absence of the contralateral kidney (Morales & Greenberg 2005).

#### 4.12 Acquired pelvis kidney (renal transplant)

The corpse kidney is situated in the pelvis, with anastomosis in iliac arteries and veins (Fig. 6C).

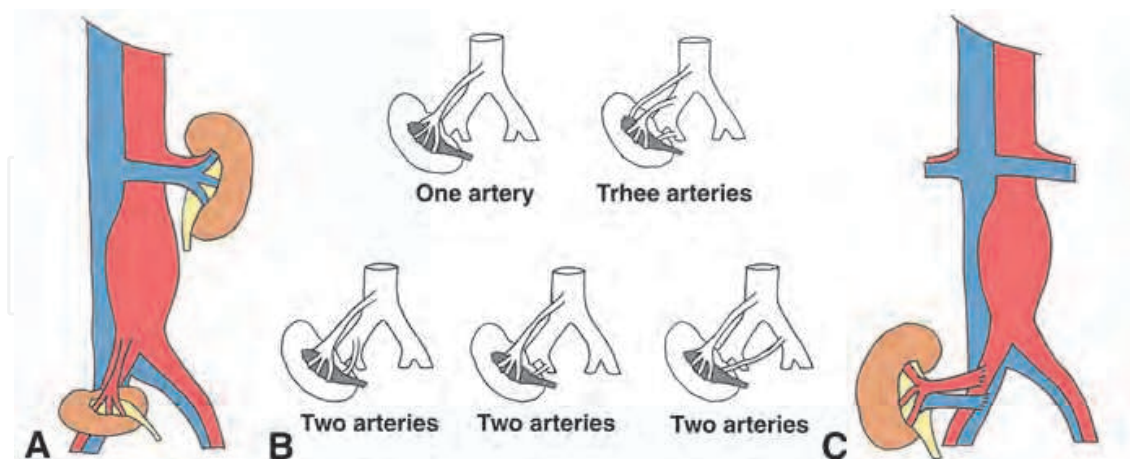


Fig. 6. Pelvic kidney. A, Congenital pelvic kidney. B, Vascularization of congenital pelvic kidney: one, two or three arteries. C, Acquired pelvic kidney (renal transplant).

#### 4.13 Crossed renal ectopia

Causes may involve faulty development of the ureteric buds, vascular obstruction to the ascent of the kidneys, and environmental factors.

The ectopic kidney crosses the midline and lies contralateral to its normal position, and usually is fused to the normal kidney, so is called crossed fused ectopia. The ureter of the ectopic kidney crosses the midline to enter the bladder at its normal position. This type of kidney is most often malrotated (ventral helium) and situated below the normal kidney. The anomaly is more common in male patients, and frequently involves the left kidney.

The blood supply to the kidneys is from the aorta or the iliac arteries, and the number of renal arteries varies. Venous drainage may also be abnormal, but because venous structures are not involved in aortic surgery, there have been no reports regarding this. This anomaly can be classified into four types (Fig. 7): *Type A, crossed ectopia with fusion; type B, crossed ectopia without fusion; type C, solitary crossed ectopia; and type D, bilaterally crossed ectopia.* Type A is seen most frequently, and the other three types much less commonly. In this anomaly, the kidneys, including the nonectopic kidney, have an anomalous blood supply. (Yano et al., 2003)

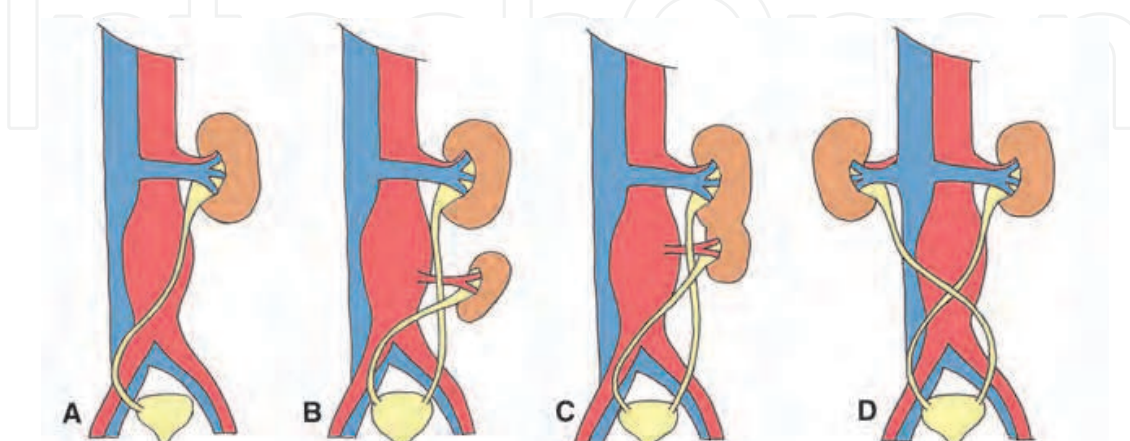


Fig. 7. Crossed renal ectopia. A, Solitary crossed kidney. B, Crossed kidney without or C, with fusion. D, Bilaterally crossed kidney.

#### 4.14 Multiple renal arteries or renal veins

Renal arteries are derived from the embryonic mesonephric arteries. Regression of these arteries results in persistence of single mesonephric artery and formation of a single renal artery. Displasia of the mesonephric arteries gives rise to *multiple renal arteries* (Natsis et al., 2010).

*Multiple renal veins* are more frequent on the right side presumably due to the fact that the right postsubcardinal anastomosis does not regress, but participates in the formation of the renal segment of the IVC. As a consequence the dorsal renal vein may persist as well. On the contrary, the postsubcardinal anastomosis regresses on the left side and facilitates the regression of the left dorsal renal vein (Natsis et al., 2010).

The polar renal arteries are common, and usually of a small calibre, irrigating only a renal pole; double renal arteries is less frequent. Multiple renal veins can occur, but is less important because are not directly implied in aortic surgery.

### 5. Clinical

#### 5.1 Major venous anomalies

These anomalies are asymptomatic usually. If there is a case with AAA ruptured into a *retroaortic left renal vein* exit a clinical onset characterized by the unique syndrome: continuous abdominal bruit, abdominal and left flank pain with an associated pulsatile mass (Mansour triad) (Gabrielli et al., 2010).

Several cases report of thromboembolic events occurring in patient with *double IVC*. An increased incidence of thrombosis formation in double IVC has been seen, but the exact cause is unknown; some authors suggested that this may be related to the degree of narrowing of the vessel as it crosses the aorta. In patients who require IVC filter placement, separate filters are needed for both IVCs (Ng & Ng, 2009).

The *retrocaval ureter* or preureteral cava vein may give right flank pain, recurrent urinary tract infections, and microscopic or gross haematuria or hydronephrosis. There is a high incidence of calculi due to stasis. Hydronephrosis may be entirely silent without any symptoms, and the patients usually are in their third or fourth decades because of gradual development of hydronephrosis (Mahmood et al., 2005).

The *inferior vena cava malpositions, anterior or posterior* are asymptomatic being a finding in the preoperative CT.

Recent reports confirm that *agenesis of the IVC* play a role as a strong predisposing factor for the development of deep venous thrombosis in young adults. An inadequate blood return through collaterals may increase the venous blood pressure in the veins of the legs, favoring venous stasis and subsequent deep venous thrombosis. (Schneider et al., 2002)

#### 5.2 Genitourinary anomalies

Although about 1/3 of *horseshoe kidney* are asymptomatic, it can be complications like ureteropelvic junction obstruction with hydronephrosis, recurrent infections, recurrent calculus formation and increased incidence of Wilms tumors, transitional cell carcinoma and renal carcinoids.

The presence of a *pancake kidney* may predispose to recurrent urinary tract infection due to the short anomalous ureter that is prone to obstruction, but most of the reported cases are asymptomatic. (Eze et al., 1998).

In case of *pelvic kidney* there is a 32% of renovascular hypertension (Sebe et al., 2004)

## 6. Diagnostic

### 6.1 Major venous anomalies

Since computed tomography (CT) is routinely performed for the elective repair of AAA, usually these anatomical anomalies like *retroaortic LRV* (Fig. 8A y B), *circumaortic LRV* (Fig. 8C) and *left inferior vena cava* (Fig. 9A) are easily detected and the risk of the operation is minimized. CT has proven to be superior to ultrasound and phlebography for detecting IVC anomalies. Magnetic resonance imaging can be as effective as CT and avoids the risks of contrast nephropathy (Nishibe et al., 2004).

In emergency surgery for a ruptured AAA, diagnosed by ultrasound alone, venous anomalies may be injured during surgery resulting in serious bleeding. In case of a ruptured AAA a CT could be useful to detect venous and renal anomalies and to avoid severe injuries.

Radiologically, the presence of *double IVC* can be mistaken as a pathological lesion such as lymphadenopathy, or left periureteric dilatation. (Ng & Ng, 2009).

Characteristic computed tomography findings of *right double IVC* were a ventral-dorsal relationship between the two vessels and the unusual course of the left common iliac vein, passing ventral or dorsal to the aortic bifurcation or the right common iliac artery

The knowledge of variations like *marsupial cava* is especially important to surgeons, because it may cause problems in differential diagnosis from adenopathy.

The CT and the MRI are the most efficacious and least invasive method of confirm diagnosis of *retrocaval ureter*. Other entities that may produce medial deviation of the ureter include retroperitoneal fibrosis and retroperitoneal mass. (Uthappa et al., 2002).

Retrograde pyelogram or iv urogram may show marked dilatation of the right pelvicalyceal system and proximal ureter to the level of transverse process of L3 vertebra. In addition there is medial deviation of the ureter at the point of transition with the characteristic "S" shape. The distal few centimeters of the right ureter are of normal caliber.

Ultrasonography demonstrates the anatomy of the retrocaval ureter and is useful in follow-up patients for hydronephrosis, parenchymal atrophy, and nephrolithiasis. (Mahmood et al., 2005)

In *agenesis of the IVC* extensive collateral flow is observed, and the azygous and hemiazygous systems are particularly prominent; collaterals include the ascending lumbar veins, paravertebral venous plexus, and anterior abdominal wall veins.

The collateral circulation may simulate a paraspinal mass. The dilated azygous vein may be misinterpreted as a mediastinal mass on chest radiography, and the dilated collaterals in the abdomen could misinterpret as a enlarged pericaval lymph nodes in a CT abdominal, presumed a retroperitoneal lymphoma.

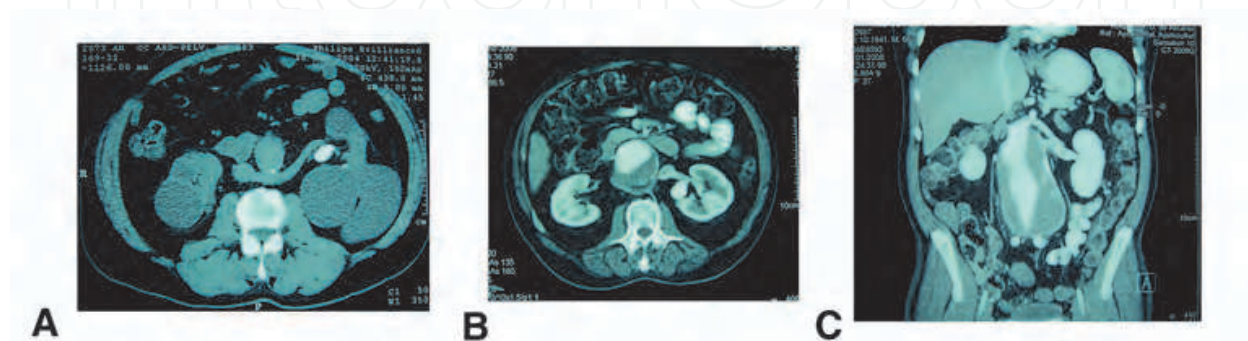


Fig. 8. Left renal vein (LRV) anomalies CT. A, Retroaortic left renal vein type I. B, Retroaortic LRV type II. C, Circumaortic LRV.

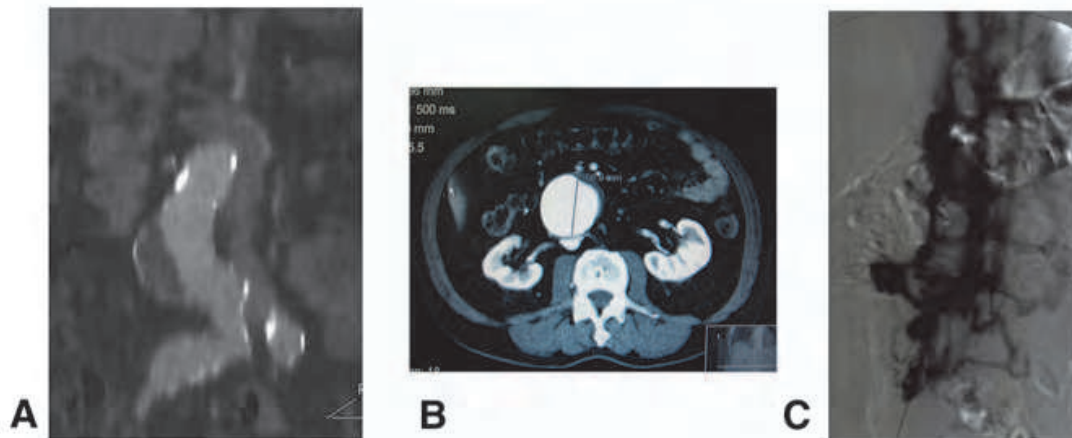


Fig. 9. Inferior vena cava (IVC) anomalies CT and arteriography. A, Left IVC. B, Posterior IVC. C, Agenesis of IVC.

### 6.2 Genitourinary anomalies

Preoperative knowledge of renal blood supply is of paramount importance to the vascular surgeon when working with anomalous kidneys. Abdominal aortic and iliac aneurysms are frequently repaired without routine preoperative angiographic examination; however, the presence of renal ectopia, often discovered by ultrasonographic or computed tomographic scanning, is a specific indication for preoperative angiographic examination.

With helical CT, adequate preoperative diagnosis of abdominal aortic aneurysm accompanied by *horseshoe kidney*, as well as determination of the arteries supplying the horseshoe kidney, are now easy. Such anatomy is important in determining the operative approach and procedure (Fig. 10A) (Makita et al., 2009; Yammamoto et al., 2006).

Renal scintigraphic scanning may also demonstrate whether the isthmus contains functioning tissue.

Computed tomography and magnetic resonance angiography allow providing information about both aortoiliac aneurysm anatomy and *pelvic kidney* (Fig 10B) feeding arteries and veins. Conventional intraarterial angiography is an invasive procedure but allows studying the renal artery anatomy with the highest sensitivity, identifying even small branches or accessory renal arteries that may be misdiagnosed with other techniques. Current technologies in the more recent angio-CT and angio-RM have significantly improved specificity and sensibility of these methods. In particular, the number and anatomical layout of the renal arteries should be established in advance of surgery, so that a surgical strategy for renal protection and arterial reimplantation can be formed. CT after the operation can disclose areas of renal infarction, suggesting that at least one renal artery originating from the aneurysm had been divided during the operation (Bui et al., 2007).

Duplex ultrasonography provide hemodynamic information such as alterations of peak systolic velocity that can occur in cases of severe kinking or dislocation of congenital pelvic kidney renal arteries in cases of huge associated aorto-iliac aneurysms.

Retrograde pyelography may provide further information about the path of the ureters and preoperative placement of ureteral catheter can enable the identification of an anomalous ureter.

There is renovascular hypertension in some cases, until 32%, but is difficult to diagnose in this cases with captopril isotopic gammagraphy. In hypertensive patients, preoperative

base-line and captopril radionuclide renographic study may reveal the renovascular nature of the hypertension. It is possible that preoperatively hypertensive patients had postoperative captopril-renogram and serum creatinine levels returned to normal and were discharged without blood pressure medication (Hanif et al., 2005, Marone et al., 2008).

In *crossed renal ectopia* retrograde pyelography may provide further information about the path of ureters. Because arteries not identified at preoperative arteriography are occasionally found at surgery, too much confidence should not be placed on preoperative evaluation. To minimize the risk for complications, it also could be placed a ureteral catheter for intraoperative identification (Yano et al., 2003).

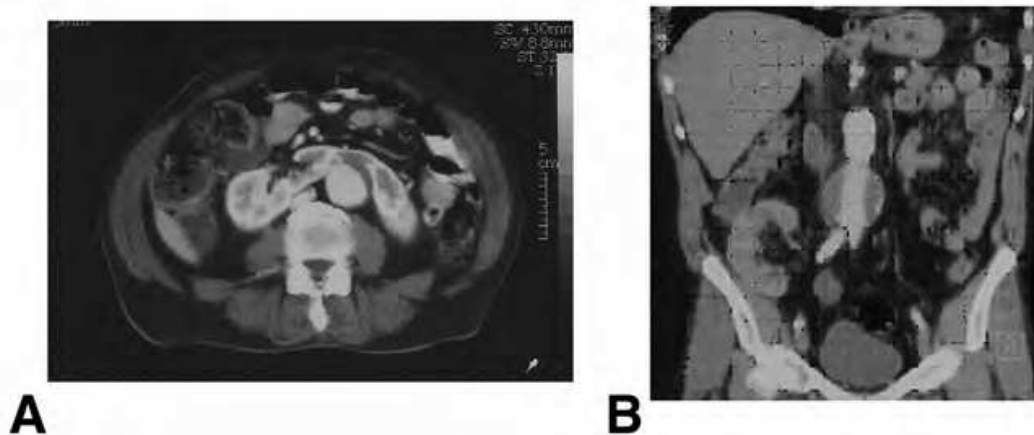


Fig. 10. Genitourinary anomalies. A, Horseshoe kidney. B, Renal transplant.

## 7. Treatment

### 7.1 Retroaortic left renal vein

Exposure of the proximal aorta and performing the proximal graft anastomosis is the major technical problem associated with anomalies of the renal vein or IVC; an adequate control of the aneurysm neck can be achieved through a midline transperitoneal approach minimizing the retroaortic dissection and avoiding to encircle the aorta. Unlike other authors, we do not believe a left retroperitoneal approach is necessary. Clamping the aorta is feasible above or below a retroaortic LRV type I. (Shindo et al., 2000).

During the control of the patient's lumbar arteries from within the open sac of the aneurysm, there is a risk of damage especially in the case of retroaortic LRV type II. The vein can be damaged with the posterior stitches, resulting in severe bleeding or in the formation of a graft- LRV fistula. To avoid this, whenever possible, is better applying lumbar artery clips outside the AAA with visual control.

Sometimes it is necessary to ligate the normal LRV to control aneurysm's neck. Whenever LRV ligating is necessary, it should be performed close to the IVC in order to preserve the gonadal and adrenal veins that normally empty into the LRV, and thus maintain the left venous renal draining.

There has been described ruptured AAA with fistula to the retroaortic left renal vein, resolved with open surgery. Furthermore, the proximity of the arteriovenous fistula to the renal arteries increased the risk of endoleak type I because it influenced the sealing and fixation zone of the stent graft even more. (Gabrielli et al., 2010).

### 7.2 Left-sided inferior vena cava

Some authors prefer a left retroperitoneal approach in case of a left-sided IVC, which may be safer when preparing the perirenal aorta. A transperitoneal approach with division of the aberrant IVC as it crosses the aorta with subsequent anastomosis also has been suggested. Nevertheless, an adequate control of the aneurysmal neck can be achieved through a midline transperitoneal approach with sufficient cava mobilization (Fig. 11). There has been described an AAA with horseshoe kidney and left-sided inferior vena cava, resolved with open surgery (Evers et al., 2007; Giglia & Thompson 2004; Radermecker et al., 2008).

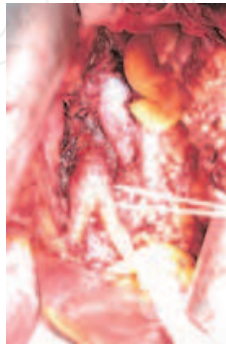

Fig. 11. Surgery image, left inferior vena cava and aortobifemoral bypass.

### 7.3 Double inferior vena cava

It has been suggested that the transperitoneal approach rather than retroperitoneal one should be adopted for patients with an abdominal aortic aneurysm and concomitant double IVC (Ng & Ng 2009). (Nagashima et al., 2006).

### 7.4 Marsupial cava or preaortic venous confluence

During elective surgery for AAA, the presence of this rare anomaly can be managed with little additional risk through the use of a long midline incision and transperitoneal route. With a careful blunt dissection of the right common iliac artery bifurcation, it is possible to gain distal control without mobilizing the caval confluence, which results strictly adherent to aorta. On the contrary, this anomaly is very troublesome if the distal aorta and right common iliac artery are approached retroperitoneally from the patient's right side (Schiavetta et al., 1998).

During emergency surgery, the priority of gaining quick control of the aorta and the iliac arteries through the retroperitoneal hematoma may lead to injury to major venous structures, excessive hemorrhage, and subsequent death. The inflammatory AAA poses another problem since an abdominal vein could be buried in the fibrosis, the preoperative mapping is important.

### 7.5 Retrocaval ureter

The retrocaval ureter can be inadvertently injured or ligated during aortoiliac surgery. Therefore, it is useful to identify such anomaly preoperatively. Ureteral stent (double J) may be helpful for stenting and drainage avoiding urine leakage and urosepsis.

Conservative treatment is necessary to those patients who have mild hydronephrosis without obvious symptoms, infection, worsening renal function, or stone formation. Ureteroureteral reanastomosis anterior to the vena cava with resection of the retrocaval

segment is the widely favorite standard treatment; this reanastomosis can be done without resection of the retrocaval segment. Laparoscopic or retroperitoneoscopic ureterolysis and reconstruction of retrocaval ureter become popular in recent years with satisfactory success rate (Nagraj et al., 2006; Li et al., 2010).

#### **7.6 Inferior vena cava malposition, anterior or posterior**

Again is important identify these alteration of normal position of the vena cava due to not injury it during aortic surgery. With careful technique it could not be a problem.

#### **7.7 Agenesis of inferior vena cava**

The agenetic or hipoplastic cava vein difficult AAA dissection due the big collaterals with risk of haemorrhage. In the postoperative period may led deep venous thrombosis.

Patients with these venous anomalies, inflammatory AAA as well as elderly patients are at particularly high risk and could be candidates for endovascular procedures.

#### **7.8 Horseshoe kidney**

Horseshoe kidneys pose more technical difficulties because they limit access to the distal aorta and besides they are usually supplied by multiple renal arteries arising from the aorta, the AAA itself, or the iliac arteries. Although the retroperitoneal approach is recommended, the majority of authors describe the transperitoneal approach for most routine cases involving horseshoe kidney and abdominal aortic aneurysm. A retroperitoneal approach can need an adjunctive right iliac incision to facilitate clamping and manipulation of a right iliac aneurysm. The isthmus of the horseshoe kidney should not be divided unless it is thin and atrophic. Rather, the aortic graft usually can be tunneled beneath the kidney if the aorta is approached anteriorly. After resection of the isthmus, however, there are possibilities of hemorrhage, of formation of a hematoma in the retroperitoneum, or of vascular prosthesis infection associated with urine leakage (Makita et al., 2009; Yamamoto et al., 2006).

Cold perfusion is useful for renal preservation during temporary ischemia. Care must be taken, however, to revascularize the major arteries by reimplantation. Preoperative arteriography facilitates identification of these branches, but careful intraoperative dissection and inspection are required to avoid injury. Ligation of a small accessory artery diverging from an aneurysm did not affect postoperative renal functions. An accessory artery with a diameter of more than 2 mm requires reconstruction (Makita et al., 2009; Stroosma et al., 2001).

In the emergency setting the transperitoneal approach, less frequent re-anastomosis of renal arteries arising from the aneurysm, and more frequent separation of the renal isthmus were preferred to a retroperitoneal approach without separation of the isthmus, since the need for rapid vascular control lowered the threshold for division of the renal arteries and isthmus. (Stroosma et al., 2001).

In pluripathologic patients there are a high surgical risk and could be candidates for endovascular procedures. Endovascular aortic repair (EVAR) is feasible despite predictable technical difficulties (angulated neck, iliac aneurysm and occlusion) and the possibility of renal impairment. In patients with ruptured AAA and horseshoe kidney the EVAR treatment should be strongly considered (Chaudhuri, 2011; Saadi et al., 2008).

In presence of blood supply type I and II, according to Eisendrath, EVAR is preferable to open aneurysm repair in any patient in whom EVAR is technically feasible, if renal retention



values are normal. Non predominant accessory renal artery less than 3 mm in diameter providing the isthmus with blood can be covered without any problems. In the case of dominant accessory renal artery greater than 3 mm in diameter, we recommend diagnostic use of selective angiography to determine what proportion of the horseshoe kidney and how much parenchyma is supplied by the accessory renal artery. When a blood supply types III and IV exist, it must be decided on the basis of each case whether EVAR is feasible. In our view, type V cannot be repaired with EVAR (Galiñanes et al., 2011; Radermercker et al., 2004; Ruppert et al., 2004).

### 7.9 Pancake kidney

The presence of a large, relatively fixed renal mass impairs anterior transperitoneal access to the pelvic vessels, thus can be a successful repair via retroperitoneal procedures. The retroperitoneal approach, avoids the renal isthmus, collecting system, and venous anomalies. In addition, it provides direct access to the abdominal aorta, the hypogastric arteries, and its branches. The pancake kidney has no isthmus, and therefore dissection and retraction is the only means of exposure, with dissection of the kidney and gentle retraction the exposure was adequate without endangering the kidney, its blood supply and collecting system. Division of the parenchyma of the pancake kidney presents potential problems such as postoperative urinary leakage, renal vascular compromise, and eventual renal failure. If the aneurysm extends into the iliac arteries, aneurysmectomy poses a significant threat to renal salvage since complete mobilization of the pancake kidney is required with the attendant risk of vascular or parenchymal injury (Krohn et al., 1999).

Anomalous renal masses invariably have aberrant vasculature including abnormal venous drainage. Exanguinating hemorrhage can occur with inadvertent venous injury, but this can be avoided by careful dissection around the pancake kidney. Renal blood must be preserved, as the sacrifice of any renal artery can result in renal necrosis and loss of renal function. In other cases, the renal arteries may arise from the aneurysm itself requiring reimplantation or bypass grafting or may be temporarily occluded to perform the aneurysm repair. The renal warm ischemia time and period of increased cardiac afterload were shortened by first performing the iliac artery anastomosis (Eze et al., 1998).

A variety of techniques are available that can be used to minimize the ischemic injury to the renal parenchyma:

Mannitol has been shown to be an affective scavenger of oxygen derived free radicals through its inhibition of thromboxane synthesis. It has been recommended as a standard precaution before aortic cross clamping in patient undergoing aneurysmectomy also with forced diuresis with furosemide. Low-dose dopamine has also been used for its renal protective effects. Dopamine is used intraoperatively and postoperatively to maximize renal vasodilatation. (Krohn et al., 1999)

The renal parenchyma can be preserved with the use of in situ cold perfusion (4°C) with lactated Ringer's or Collin's solution. To further diminish the effects of ischemia and reperfusion, selective renal perfusion techniques can also be used during aortic cross-clamping in specific cases, including the use of a variety of shunts and temporary bypass (Eckes & Lawrence, 1997).

### 7.10 Congenital pelvic kidney

In the majority of patients with a congenital pelvic kidney who underwent open repair developed significant, albeit largely transient, rises in creatinine value. Typically, this initial

rise of creatinine levels is followed by a complete or near complete recovery which is consistent with that natural history of acute tubular necrosis (ATN). A preprocedure elevation of creatinine likely puts the patient at a higher risk for clinically apparent ATN postprocedure because of diminished functional renal reserve. (Bui et al., 2007).

In spite of all techniques for protection the pelvic kidney during aorta reconstruction ATN is common after surgery and tends to resolve within two weeks. Whether an episode of transient ATN shortens transplanted kidney life span is unknown, but we think is prudent to take reasonable steps to minimize ATN without adding complications to the procedure.

The risk factors currently associated with postoperative ATN include (1) the pelvic kidney constituting all functioning renal mass (congenital solitary pelvic kidney, renal transplant); (2) more than two anastomoses required to revascularize the kidney (e. g., reimplantation or bypass of the pelvic renal artery); (3) an elevated creatinine preoperatively; (4) poor collaterals such as occluded lumbar, inferior mesenteric artery, or internal iliac arteries or a measured aortic sac backpressure of <35 mm Hg; and (5) estimated aortic cross-clamp time for more than 50 min. (Bui et al., 2007).

Different mechanisms may plausibly be involved in renal function impairment, mainly related to malperfusion of congenital pelvic kidney such as aneurysm distal embolization, kinking of the renal artery, hemodynamic effects of abnormal pulsatility, and in the case of large lesions, due to depression of the renal parenchyma, renal veins, and the ureter and/or ureteropelvic junction. (Marone et al., 2008)

Renal function is more susceptible to ischemia in patients undergoing elective AAA repair who have transplanted kidneys than in patients with ectopic congenital pelvic kidneys. Except for patients with congenital solitary pelvic kidney, good results with congenital pelvic kidney should be expected as these patients had a normal kidney above the AAA that was not at risk of ischemic injury. Without the advantage of pre and postoperative nuclear renal isotope scans to assess excretion and flow, it is difficult to assess the degree of acute tubular necrosis in the congenital pelvic kidney in a patient with normal contralateral kidney.

Unlike a transplanted pelvic kidney, the congenital pelvic kidney may have a single renal artery, but their origin may be displaced to the distal aorta or even iliac arteries; or may have multiple renal arteries, one which may originate from the diseased distal aorta, requiring reimplantation. In cases of iliac aneurysm, it may be needed to reimplant the renal artery. If during aortic cross-clamping an ischemic discoloration of a segment of the kidney is observed that indicates the lack of a collateral vascular supply and the necessity of reimplanting the artery that supply that segment (Bui et al., 2007).

In case of renovascular hypertension refractory at treatment with an atrophic pelvic kidney it could be needed a nephrectomy for better hypertension control with less drugs (Sebe et al., 2004).

Because of the presence of congenital pelvic kidney, the renal function may be affected by intraoperative renal ischemia after aortic aneurysm repair and several methods of renal protection to prevent renal ischemic injury have been previously reported. These methods of renal preservation, also used during abdominal aneurysmectomy in renal transplant patients, can be divided in various groups: pharmacological systemic renal protection, in situ perfusion with hypothermic crystalloid solution, use of a temporary shunt and double proximal clamping technique, the use of perfusion with pump oxygenator or ex vivo perfusion are abandoned. In appropriate candidates, EVAR may be considered.

1. Systemic renal protection. The expansion of plasmatic volume with preoperative hydration and the intraoperative administration of furosemide and mannitol or dopamine to obtain forced diuresis before cross-clamping, reduce the risk of kidney loss, or acute tubular necrosis. These methods are safe and effective and can represent a good choice if associated to a fast aortic reconstruction.
2. In situ cooling techniques. To preserve renal function during supra-renal clamping for a longer time (60 to 90 min), it is possible to use selective infusions of bolus of cold (4°C) lactate Ringer's solution that can be repeated every 20 minutes or continuously infused to reduce the temperature of the kidney to 15-18°C. Some authors added 6-methylprednisolone and mannitol to this solution. Topical cooling kidney packing with ice slush is a complementary action in these cases. (Marone et al., 2008).
3. Temporary shunts. Temporary bypasses or shunts are performed from the axillary or subclavian artery or from the abdominal aorta above the aneurysm, or less frequently from the left atrial cavity or ascending aorta to the iliac or femoral vessels. A temporary extra-anatomic shunt maintains renal perfusion when conventional AAA repair is required. A shunt with partial extracorporeal circulation and pulsatile cold blood perfusion needs systemic anticoagulation; a shunt with centrifugal pump or a Gott shunt (heparin coated) does not need anticoagulation. However, all these procedures entail possible intimal arterial dissection or embolization and may increase the risk of haemorrhagic or infectious complications (Hanif et al., 2005; Maeda et al., 2009; Martin-Conejero et al., 2003).
4. Clamping and anastomoses techniques. The double proximal clamping technique, described by Lacombe offers a potential sufficient protection for medium time (less than 60 min) using backflow by lumbar, inferior mesenteric, and iliac arteries during completion of proximal aortic anastomosis. This technique involves completely dividing the aortic neck proximally between two clamps. The aortic back pressure after aortic cross-clamping is between 35 and 60 mm Hg, and experimentally, a renal blood flow under a low arterial pressure of only 25 mm Hg is adequate for organ survival (Lacombe, 1991, 2008)

Once the proximal anastomosis is complete, the sac can be opened and the distal anastomosis is performed while the pelvic kidney is perfused by retrograde flow from the ipsilateral internal and femoral arteries. The absence of a valid collateral circulation and the presence of a short proximal neck limit the use of this alternative. Some authors have pointed out that having two clamps together makes the proximal anastomosis more difficult. This technique has been modified by Hollis et al. to use a vascular stapler to avoid the distal clamp. The short proximal aortic neck may require placing the distal clamp across the proximal aneurysm sac. This compression of the sac could potentially lead to significant embolization. (Bui et al., 2007).

When using a bifurcated graft, performing the distal before the proximal anastomosis is another described technique for limiting clamp time. By taking the graft limb ipsilateral to the pelvic kidney and anastomosing it distal to the kidney on the external iliac artery, this anastomosis can be done without interrupting the normal aortoiliac flow to the pelvic kidney. Warm kidney ischemic time is then limited to the time it takes to do the proximal aortic anastomosis only.

5. Extracorporeal pump. Finally, another technical approach to this pathology is the renal perfusion using a femoral vein to femoral artery bypass using extracorporeal

oxygenation. This method offers a reliable protection but requires a perfusionist, a pump-oxygenation, and a groin incision for retrograde cannulation of the femoral artery and vein. The technique of *ex vivo* renal perfusion has been abandoned because of the risks of removing the transplant (Marone et al., 2008).

In suitable aneurysm candidates, the use of an endovascular graft can also be considered for treatment in patients with congenital pelvic kidneys. Endovascular repair obviates the need for renal protection as warm ischemic time is limited to ballooned graft placement. This is also especially attractive for high-risk patients with multiple comorbidities who otherwise may not tolerate open repair. Contrast load and excessive manipulation of the donor artery in renal allograft patients, however, need to be minimized in order to achieve optimal outcomes. However, there is a risk of vascular damage at the graft anastomotic site, so, if implant dislocation occurs, graft thrombosis may happen (Bui et al., 2007; Bertoni et al., 2010; Morales et al., 2009)

The decision to implant a bifurcated or an aorto-uni-iliac device depends on the anatomical characteristics of the aneurysm. The bifurcated stent graft maintains in-line flow to the renal transplant. The larger delivery system for the main body of the graft can be inserted *via* the contralateral iliac artery. On the other hand, the aorto-uni-iliac system has the potential disadvantages of an extra-anatomic approach, such as anastomotic stenosis, graft occlusion, and a small risk of crossover graft infection (Leon et al., 2009; Sadat et al., 2010).

In conclusion, to preserve renal function during open repair, various methods have been previously reported, but no procedure has been clearly considered the therapeutic gold standard. The congenital pelvic kidney is associated with a normal and functional contralateral kidney, so protective measures need not to be drastic. In our experience, the forced intraoperative diuresis with mannitol and furosemide and the main pelvic kidneys arteries selective perfusion with hypothermic lactate ringer solution, associated to a fast surgical technique, have proven to be safe and effective. (Marone et al., 2008).

### **7.11 Crossed renal ectopia**

A ureteral stent can be placed preoperatively to prevent ureter intraoperative injury as a marker of the abnormal ureter. This shows that the ureter crosses the midline, and enters the bladder at its normal anatomic location. (Yano et al., 2003).

### **7.12 Acquired pelvic kidney (renal transplant)**

The incidence of acute renal failure after aortic surgery in renal transplant patients has ranged from 1 to 8% in elective cases, and in patients with mild or moderate degree of renal dysfunction the morbidity rates are higher than in patients with normal renal function. Given the lack of collateralization of renal allograft, they are more susceptible to ischemic injury than congenital pelvic kidneys (Favi et al., 2005).

The aortic clamp during AAA repair may cause ischemia of the renal graft and diverse procedures have been performed to preserve the function of the transplanted organ. These methods are similar like described in congenital pelvic kidney. Successful surgical repair of AAA in patients with a transplanted kidney has been reported without any form of renal transplant protection, with judicious clamping and rapid anastomosis, although the warm ischemia time of the allograft should not take longer than 60 min. This option could be made difficult by the possibility of finding a very diseased calcific or malacious aortic wall due to dialysis and immunosuppressive therapy (Sckelly et al., 2002).

Standard open surgery without adjunctive shunts or bypasses remains a viable treatment option for these patients. Renal ischemia during aortic cross-clamping can be effectively reduced by cold graft perfusion and local hypothermia. In addition, the potential risk of atheromatous embolization to the transplanted kidney is less than for other temporary procedures of shunt or bypass. The endovascular technique may be used for patients who meet the anatomical criteria for endovascular repair and are at high risk for a conventional operation (Ailawadi et al., 2003; Khanmoradi et al., 2004; Karkos et al., 2006; Kokotsakis et al., 2009). The fever before EVAR in a kidney transplant patient is not always synonymous with infection; it may be a postimplantation syndrome. (Regidor et al., 2009). It has been described an aortoiliac aneurysm resection and reconstruction with allograft together with simultaneous kidney transplantation as a one-stage procedure with good results. Also it has been described an aortic stent-graft explantation in a kidney transplant recipient (Hughes et al., 2009; Matia et al., 2008, 2009).

### 7.13 Multiple renal arteries

Accessory renal arteries can also be found during careful dissection of the aorta, usually arising more anteriorly than the normal lateral renal artery orifices. Those that are sufficiently large to supply distinct areas of renal parenchyma should be reimplanted onto the aortic graft if they arise from the AAA. This is facilitated by excising a surrounding collar (Carrel patch) of associated aortic wall along with the orifice.

## 8. Conclusion

Although uncommon, anatomical anomalies may lead to difficult situations and life-threatening bleeding. A preoperative CT is useful in the patients undergoing an AAA repair. Familiarity with these anomalies and safe operative technique is needed to avoid fatal complications. Endovascular techniques play an important role in AAA cases with venous and genitourinary anomalies if the patient has serious comorbidities and has adequate anatomical conditions in neck and iliac arteries.

## 9. Acknowledgment

To Carol, Celia and Miguel, for their patient and understanding.

## 10. References

- Ailawadi G, Bedi A, Williams DM, Stanley JC & Upchurch GR. Endovascular treatment of aortic aneurysms in patients with renal transplants. *Journal of Vascular Surgery* Vol.37, No.3, (March 2003), pp. 693-6, ISSN 0741-5214.
- Aljabri B, McDonald PS, Satin R, Stein LS, Obrand DI & Steinmetz OK. Incidence of major venous and renal anomalies relevant to aortoiliac surgery as demonstrated by computed tomography. *Annals of Vascular Surgery* Vol.15, No 6, (November 2001), pp. 615-618, ISSN 0890-5096.
- Bass JE, Redwine MD, Kramer LA, Huynh PT & Harris JH. Spectrum of congenital anomalies of the inferior vena cava: cross-sectional imaging findings. *Radiographics* Vol.20, No.3, (May 2000), pp. 639-652, ISSN 0271-5333.

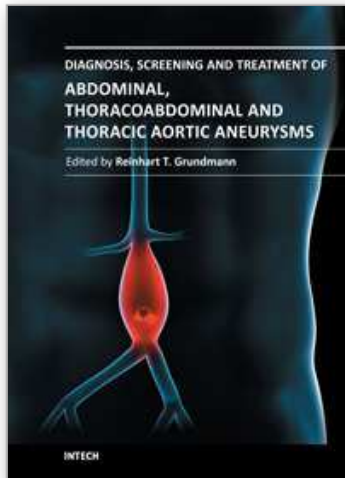
- Bertoni HG, Girela G, Peirano M, Leguizamón JH, de la Vega A, Barone HD, Nutley M, Zhang Z, Douville Y & Guidoin R. A branched, balloon-deployable, aortomonoiliac stent-graft for treatment of AAA in a patient with a solitary intrapelvic kidney. *Journal Endovascular Therapy*, Vol.17, No.2, (April 2010), pp 261-5, ISSN 1526-6028.
- Bui TD, Wilson SE, Gordon IL, Fujitani RM, Carson J & Montgomery RS. Renal function after elective infrarenal aortic aneurysm repair in patients with pelvic kidneys. *Annals of Vascular Surgery*, Vol.21, No.2, (March-April 2007), pp 143-148, ISSN 0890-5096.
- Chaudhuri A. Exclusion of an infrarenal AAA with coincident horseshoe kidney and renovascular anomalies is feasible using a standard stent-graft. *European Journal of Vascular and Endovascular Surgery*, In press, available on line 25 February 2011, (Epub ahead of print), ISSN 1078-5884.
- Dillon EH, Camputarò C. Nonobstructing periureteric venous ring: diagnosis with conventional and three-dimensional reconstruction CT. *American Journal of Roentgenology*, Vol.157, No. 5 (November 1991), pp 997-998. ISSN 0361-803X.
- Evers DJ, Stoot JH & Breslau RJ. Symptomatic abdominal aortic aneurysm with inferior vena cava malposition. *Acta Chirurgica Belgica*, Vol.107, No.6, (November-December 2007), pp 693-4, ISSN 0001-5458.
- Eckes D & Lawrence P. Bilateral iliac artery aneurysm and pancake kidney: a case report. *Journal of Vascular Surgery*, Vol.25, No.5, (May 1997), pp 927-30, ISSN 0741-5214.
- Eze AR, White JV, Pathak AS & Grabowski MW. Pancake kidney: a renal anomaly complicating aortic reconstruction. *Annals of Vascular Surgery*, Vol.12, No.3, (May 1998), pp 278-281, ISSN 0890-5096.
- Favi E, Citterio F, Tondolo V, Chirico A, Brescia A, Romagnoli J & Castagneto M. Abdominal aortic aneurysm in renal transplant recipients. *Transplantation Proceedings* Vol.37, No.6, (July-August 2005), pp. 2488-90, ISSN 0041-1345.
- Gabrielli R, Rosati MS, Siani A & Marcucci G. Preoperative evaluation of retroperitoneal venous system anomalies during abdominal aortic aneurysm rupture. *Interactive Cardiovascular and Thoracic Surgery*, Vol.12, No.2, (February 2011), pp 278-80, ISSN 1569-9293.
- Galiñanes EL, Quick J, Nichols WK, Ross CB, Faizer R & Morris ME. Horseshoe kidney and inflammatory abdominal aortic aneurysm. 2011, *Annals of Vascular Surgery*, in press, available on-line 27 January 2011, (Epub ahead of print), ISSN 0890-5096.
- Giglia JS & Thompson JK. Repair of a thoracoabdominal aortic aneurysm in the presence of a left-sided inferior vena cava. *Journal of Vascular Surgery* Vol.40, No.1, (July 2004), pp. 161-163, ISSN 0741-5214.
- Guray Y, Yelgec NS, Guray U, Yılmaz MB, Boyacı A & Korkmaz S. Left sided or transposed inferior vena cava ascending as hemiazygos vein and draining into the coronary sinus via persistent left superior vena cava: case report. *International Journal of Cardiology* Vol. 93, No.3-4, (February 2004), pp. 293-295, ISSN 0167-5273.
- Hanif MA, Chandrasekar R & Blair SD. Pelvic kidney and aortoiliac aneurysm, a rare association, case report and literature review. *European Journal of Vascular and Endovascular Surgery*, Vol.30, No.5, (November 2005), pp 531-533, ISSN 1078-5884.
- Hughes JD, Leon LR Jr & Goshima KR. Aortic stent-graft explantation in a kidney transplant recipient. *Annals of Vascular Surgery*, Vol.23, No.4, (July-August 2009), pp 535.e21-6, ISSN 0890-5096.
- Karkos CD, Bruce IA, Thomson GJL & Lambert ME. Retroaortic left renal vein and its implications in abdominal aortic surgery. *Annals of Vascular Surgery* Vol.15, No.6, (November 2001), pp. 703-708, ISSN 0890-5096.
- Karkos CD, McMahon G, Fishwick G, Lambert K, Bagga A & McCarthy MJ. Endovascular abdominal aortic aneurysm repair in the presence of a kidney transplant:

- therapeutic considerations. *Cardiovascular and Interventional radiology* Vol.29, No.2, (March 2006), pp. 284-88, ISSN 0174-1551.
- Kaskarelis IS, Koukoulaki M, Cappas I & Karkatzia F et al. Successful endovascular repair of ruptured abdominal aortic aneurysm in a renal transplant recipient. *Cardiovascular and interventional radiology* Vol.29, No.2, (April 2006), pp 279-283, ISSN 0174-1551.
- Khanmoradi K, Brewster DC, Haddad FF & Cho SI. Endovascular repair of abdominal aortic aneurysm in a kidney transplant with 4-year follow-up. *Surgery* Vol.136, No.1, (July 2004), pp. 103, ISSN 1530-0358
- Kokotsakis J, Kaskarelis I, Koukoulaki M, Athansasiou T, Skouteli E, Vougas V, Lioulias A & Drakopoulos S. Entire stent grafting of the thoracoabdominal aorta in a renal transplant recipient subsequent to extra-anatomical bypasses of the main abdominal vessels. *Annals of Thoracic Surgery*, Vol.87, No.2, (February 2009), pp 623-5, ISSN 0003-4975.
- Kraus GJ & Goerzer HG. MR-angiographic diagnosis of an aberrant retroaortic left renal vein and review of the literature. *Clinical Imaging* Vol.27, No.2, (March-April 2003), pp. 132-134, ISSN 0899-7071.
- Krohn DL, Sanchez LA, Wain RA & Veith FJ. Repair of bilateral common iliac artery aneurysms coexisting with a pelvic horseshoe kidney. *Annals of Vascular Surgery*, Vol.13, No.6, (November 1999), pp 625-628, ISSN 0741-5214.
- Lacombe M. Aortoiliac surgery in renal transplant patients. *Journal of Vascular Surgery*, Vol.13, No.5, (May 1991), pp 712-718, ISSN 0741-5214.
- Lacombe M. Surgical treatment of aortoiliac aneurysms in renal transplant patients. *Journal of Vascular Surgery*, Vol.48, No.2, (August 2008), pp 291-5, ISSN 0741-5214.
- Leon LR, Glazer ES, Hughes JD, Bui TD, Psalms SB & Goshima KR. Aortoiliac aneurysm repair in kidney transplant recipients. *Vascular Endovascular Surgery*, Vol.43, No.1, (February-March 2009), pp 30-45, ISSN 1538-5744.
- Lepántalo M, Biancai F, Edgren J, Eklund B & Salmela K. Treatment options in the management of abdominal aortic aneurysm in patients with renal transplant. *European Journal of Vascular and Endovascular Surgery* Vol.18, No.2, (August 1999), pp. 176-8, ISSN 1078-5884.
- Li HZ, Ma X, Qi L, Shi TP Wang BJ & Zhang X. Retroperitoneal laparoscopic ureteroureterostomy for retrocaval ureter: report of 10 cases and literature review. *Urology* Vol.76, No.4, (October 2010), pp 873-6, ISSN 0090-4295.
- Maeda T, Watanabe N & Muraki S. Abdominal aortic aneurysm repair in a renal transplant recipient using a femoral v-a bypass. *Annals of Thoracic and Cardiovascular Surgery*, Vol.15, No.6, (December 2009), pp 415-417, ISSN 1341-1098.
- Mahmood M, Tandon V, Dwivedi US & Singh PB. Retrocaval ureter: a rare entity in the spectrum of upper tract obstruction. *JK-practitioner* Vol.12, No.1, (January-March 2005), pp 24-25, ISSN 0971-8834.
- Makita S, Yoshizaki T & Tabuchi N. A case of abdominal aortic aneurysm with horseshoe kidney. *Annals of Thoracic and Cardiovascular Surgery*, Vol.15, No.2, (April 2009), pp 15:129-132, ISSN 1341-1098.
- Marone EM, Tshomba Y, Brioschi C, Calliari FM & Chiesa R. Aortoiliac aneurysm associated with congenital pelvis kidney: a short series of successful open repairs under hypothermic selective renal perfusion. *Journal of Vascular Surgery*, Vol.47, No.3, (March 2008), pp 638-44, ISSN 0741-5214.
- Martin-Conejero A, Serrano-Hernando FJ, Reina-Gutierrez T, Rial-Horcajo R, Ponce-Cano AI & Blanco-Cañibano E. Surgery for aortoiliac aneurysm after kidney transplant. *Transplantations Proceedings*, Vol.35, No.8, (December 2003), pp 2953-7, ISSN 0041-1345.

- Matia I, Adamec M, Varga M, Janousek L, Lipar K & Viklicky O. Aortoiliac reconstruction with allograft and kidney transplantation as one-stage procedure: long-term results. *European Journal of Vascular and Endovascular Surgery*, Vol.35, No.3, (March 2008), pp 353-7, ISSN 1078-5884.
- Matia I, Pirk J, Lipar K & Adamec M. Successful surgical treatment of multilevel aortic aneurysms combined with renal transplantation. *Journal of Vascular Surgery*, Vol.50, No.1, (July 2009), pp 198-201, ISSN 0741-5214.
- Minniti S & Procacci C. Congenital anomalies of the vena cava: embryological origin, imaging features and report of three new variants. *European Radiology* Vol.12, No.8, (August 2002), pp. 2040-2055, ISSN 0938-7994.
- Morales JP & Greenberg RK. Customised stent graft for complex thoracoabdominal aneurysm associated with congenital pelvic kidney. *European Journal of Vascular and Endovascular Surgery*, Vol.37, No.5, (May 2009), pp 557-559, ISSN 1078-5884 .
- Nagashima T, Lee j, Andoh K, Itoh T, Tanohata K, Arai M & Inoue T. Right double inferior vena cava: report of 5 cases and literature review. *Journal of Computer Assisted Tomography*, Vol.30, No.4, (July-August 2006), pp 642-5, ISSN 0363-8715.
- Nagraj HK, Kishore TA & Nagalaskshmi S. Transperitoneal laparoscopic approach for retrocaval ureter. *Journal of Minimal Access Surgery*, Vol.2, No.2(April-June 2006), pp 81-82, ISSN 0972-9941.
- Natsis K, Iordache G, Xepulias P & Tsikaras P. Preaortic iliac venous confluence. Marsupial vena cava. Case report. *Morphologie*, Vol.87, No.277, (June 2003), pp 21-23, ISSN 1286-0115.
- Natsis K, Apostolidis S, Noussios G, Papathanasiou E, Kyriazidou A & Vyzas V. Duplication of the inferior vena cava: anatomy, embryology and classification proposal. *Anatomical Science International*, Vol.85, No.1, (March 2010), pp 56-60, ISSN 1447-6959.
- Ng WT & Ng SSM. Double inferior vena cava: a report of three cases. *Singapore Medical Journal*, Vol.50, No.6, (June 2009), pp 211-13, ISSN 0037-5675.
- Nishibe T, Sato M, Kondo Y, Kaneko K, Muto A, Hoshino R, Kobayashi Y, Yamashita M & Ando M. Abdominal aortic aneurysm with left-sided inferior vena cava. Report of a case. *International Angiology* Vol.23 No.4, (December 2004), pp. 400-402, ISSN 0392-9590.
- Palit S & Deb S. A rare presentation of double inferior vena cava with anomalous pattern of azygos and hemiazygos venous system: a case report. *Journal of the Anatomical Society of India*, Vol.51, No.1, (June 2002), pp 65-67, ISSN 0021-9967.
- Radermecker MA, Van Damme H, Kerzmann A, Creemers E & Limet R. Association of abdominal aortic aneurysm, horseshoe kidneys, and left-sided inferior vena cava: report of two cases. *Journal of Vascular Surgery*, Vol.47, No.3, (March 2008), pp 645-8, ISSN 0741-5214.
- Regidor D, Ahijado FJ, Muñoz MA, Romero M, Roca A, Diaz-Tejeiro R, Leal I & Conde JL. Postimplantation syndrome in a kidney transplant patient: fever is not always synonymous with infection. *Transplantations Proceedings*, Vol.41, No.10, (December 2009), pp 4202-4, ISSN 0041-1345.
- Ruggeri M, Tosetto A, Castaman G & Rodeghiero F. Congenital absence of the inferior vena cava: a rare risk factor for idiopathic deep vein thrombosis. *Lancet* Vol.357, No.9254, (February 10, 2001), pp. 441, ISSN 0140-6736.
- Ruppert V, Umscheid T, Rieger J, Schmedt CG, Mussack T, Steckmeier B & Stelter WJ. Endovascular aneurysm repair: Treatment of choice for abdominal aortic aneurysm coincident with horseshoe kidney? Three case reports and review of literature. *Journal of Vascular Surgery*, Vol.40, No.2, (August 2004), pp 367-70, ISSN 0741-5214.



- Saadi EK, Dussin LH, Moura L & Zago AJ. Endovascular repair of an abdominal aortic aneurysm in patient with horseshoe kidney: a case report. *Revista Brasileira de Cirurgia Cardiovascular*, Vol.23, No.3, (July-September 2008), pp 425-428, ISSN 0102-7638.
- Sadat U, Huguet EL & Varty K. Abdominal aortic aneurysm surgery in renal, cardiac and hepatic transplant recipients. *European Journal of Vascular and Endovascular Surgery*, Vol.40, No.4, (October 2010), pp 443-9, ISSN 1078-5884.
- Schiavetta A, Cerruti R, Cantello C & Patrone P. Marsupial cava and ruptured abdominal aortic aneurysm. *Journal of Vascular Surgery*, Vol.28, No.4, (October 1998), pp 719-22, ISSN 0741-5214.
- Schneider JG, Eynatten MV, Dugi KA, Duex M & Nawroth PP. Recurrent deep venous thrombosis caused by congenital interruption of the inferior vena cava and heterozygous factor V Leiden mutation. *Journal of Internal Medicine* Vol.252, No.3, (September 2002), pp. 276-280, ISSN 1365-2796.
- Sebe P, Chemla E, Varkarakis J & Latrémouille C. Variations anatomiques de la vascularisation des reins pelviens: à propos d'un cas et revue de la littérature. *Morphologie*, Vol.88, No.280, (April 2004), pp 24-26, ISSN 1286-0115.
- Sénécaïl B, Josseume T, Boeuf J, Hebert T, Waizi R & Nonent M. Right-sided duplication of the inferior vena cava. *Morphologie*, Vol.88, No.283, (December 2004), pp 183-7, ISSN 1286-0115.
- Shindo S, Kobayashi M, Kaga S, Hurukawa H, Kubota K, Kojima A, Ijori K, Ishimoto T, Kamiya K & Tada Y. Retrocaval ureter and preaortic iliac venous confluence in a patient with an abdominal aortic aneurysm. *Surgical and Radiologic Anatomy*, Vol.21, No.2, (May 1999), pp 147-9, ISSN 0930-1038.
- Shindo S, Kubota K, Kojima A, Iyori K, Ishimoto T, Kobayashi M, Kamiya K & Tada Y. Anomalies of inferior vena cava and left renal vein: risk in aortic surgery. *Annals of Vascular Surgery*, Vol.14, No.4, (November 2000), pp 393-6, ISSN 0890-5096.
- Simon RW, Amann-Vesti BR, Pfammatter T & Koppensteiner R. Congenital absence of the inferior vena cava: a rare risk factor for idiopathic deep-vein thrombosis. *Journal of vascular Surgery* Vol.44, No.2, (August 2006), pp. 416, ISSN 0741-5214.
- Skelly CL, Farmer AM, Curi MA, Meyerson SL, Davidovitch RS, Woo DH & Schwartz LB. Aortic reconstruction in patients with functioning renal allograft. *Annals of Vascular Surgery* Vol.16, No.6, (November 2002), pp. 779-83, ISSN 0890-5096.
- Stroosma OB, Koostra G & Schurink GW. Management of aortic aneurysm in the presence of a horseshoe kidney. *British Journal of Surgery*, Vol.88, No.4, (April 2001), pp 500-9 ISSN 1365-2168.
- Tagliafico A, Capaccio E, Rosenberg I, Martinoli C & Derchi LE. Double right inferior vena cava associated with an anomalous venous ring encircling the right common iliac artery: report of a case with CT and US. *European Journal of Radiology Extra*, Vol.65, No.3, (December 2007), pp 111-115, ISSN 0720-048X.
- Uthappa MC, Anthony D & Allen C. Retrocaval ureter: MR appearances. *The British Journal of Radiology*, Vol.75, No.890, (February 2002), pp 177-179, ISSN 0007-1285.
- Yamamoto N, Mohri M, Kato G, Oki A & Tedoriya T. Isthmus of a horseshoe kidney overlying a ruptured abdominal aortic aneurysm: a case report. *Annals of Thoracic and Cardiovascular Surgery*, Vol.12, No.2, (April 2006), pp 149-51, ISSN 1341-1098.
- Yano H, Konagai N, Maeda M, Itoh M, Kuwabara A, Kudou T & Ishimaru S. Abdominal aortic aneurysm associated with crossed renal ectopia without fusion: case report and literature review. *Journal of Vascular Surgery*, Vol.37, No.5, (May 2003), pp 1098-102, ISSN 0741-5214.



## **Diagnosis, Screening and Treatment of Abdominal, Thoracoabdominal and Thoracic Aortic Aneurysms**

Edited by Prof. Reinhart Grundmann

ISBN 978-953-307-466-5

Hard cover, 414 pages

**Publisher** InTech

**Published online** 12, September, 2011

**Published in print edition** September, 2011

This book considers mainly diagnosis, screening, surveillance and treatment of abdominal, thoracoabdominal and thoracic aortic aneurysms. It addresses vascular and cardiothoracic surgeons and interventional radiologists, but also anyone engaged in vascular medicine. The high mortality of ruptured aneurysms certainly favors the recommendation of prophylactic repair of asymptomatic aortic aneurysms (AA) and therewith a generous screening. However, the comorbidities of these patients and their age have to be kept in mind if the efficacy and cost effectiveness of screening and prophylactic surgery should not be overestimated. The treatment recommendations which will be outlined here, have to regard on the one hand the natural course of the disease, the risk of rupture, and the life expectancy of the patient, and on the other hand the morbidity and mortality of the prophylactic surgical intervention. The book describes perioperative mortality after endovascular and open repair of AA, long-term outcome after repair, and the cost-effectiveness of treatment.

### **How to reference**

In order to correctly reference this scholarly work, feel free to copy and paste the following:

Roberto Jiménez and Francisco Morant (2011). The Importance of Venous and Renal Anomalies for Surgical Repair of Abdominal Aortic Aneurysms, *Diagnosis, Screening and Treatment of Abdominal, Thoracoabdominal and Thoracic Aortic Aneurysms*, Prof. Reinhart Grundmann (Ed.), ISBN: 978-953-307-466-5, InTech, Available from: <http://www.intechopen.com/books/diagnosis-screening-and-treatment-of-abdominal-thoracoabdominal-and-thoracic-aortic-aneurysms/the-importance-of-venous-and-renal-anomalies-for-surgical-repair-of-abdominal-aortic-aneurysms>

**INTECH**  
open science | open minds

### **InTech Europe**

University Campus STeP Ri  
Slavka Krautzeka 83/A  
51000 Rijeka, Croatia  
Phone: +385 (51) 770 447  
Fax: +385 (51) 686 166  
[www.intechopen.com](http://www.intechopen.com)

### **InTech China**

Unit 405, Office Block, Hotel Equatorial Shanghai  
No.65, Yan An Road (West), Shanghai, 200040, China  
中国上海市延安西路65号上海国际贵都大饭店办公楼405单元  
Phone: +86-21-62489820  
Fax: +86-21-62489821

© 2011 The Author(s). Licensee IntechOpen. This chapter is distributed under the terms of the [Creative Commons Attribution-NonCommercial-ShareAlike-3.0 License](#), which permits use, distribution and reproduction for non-commercial purposes, provided the original is properly cited and derivative works building on this content are distributed under the same license.

IntechOpen

IntechOpen